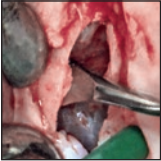

Crestal Window Sinus Elevation and Its Long-Term Clinical Outcomes



Carlo M. Soardi, MD, DDS¹
 Barbara Soardi, DDS¹
 Hom-Lay Wang, DDS, MS, PhD²

Sinus augmentation has been shown to be an effective methodology to augment a deficient maxillary sinus. However, there are many techniques a clinician can choose from. Historically, lateral window or crestal osteotome approaches were the most frequently discussed techniques. In this paper, a sinus floor elevation technique with crestal window sinus elevation was proposed to treat cases of extremely atrophic maxillae (remaining bone height ≤ 2 mm). A crestal window is opened for the sinus membrane to be detached from the bony walls. After the proper elevation and membrane detachment, human particulated allografts were placed via the crestal access window to elevate the sinus membrane. Primary closure was then achieved, and after 6 to 9 months of healing, implant placement was performed. From the long-term clinical outcome that was obtained, the authors concluded that crestal window sinus elevation is a procedure with predictable outcomes for elevation of a maxillary sinus floor less than 2 mm thick, with an average elevation height of 11.73 mm. Int J Periodontics Restorative Dent 2020;40:757–764. doi: 10.11607/prd.4292

The elevation of the sinus floor in oral surgery has been carried out for almost 40 years.^{1,2} A recent review of the literature concerning the elevation of the maxillary sinus has shown success in the high 90th percentile.^{3,4} The procedure very rarely failed,⁵ especially when using Wang and Katranji's Class B sinuses classification (basal original bone 5 to 9 mm).⁶

Some authors believe that failures result exclusively from the difficulty associated with obtaining good primary stability when an implant is placed into a low quantity of native bone.⁷ Others have recommended placing the implants at a later time if the floor thickness is less than 4 mm.⁸ However, there is currently no scientific evidence available to support either hypothesis. This is likely because the floor of such atrophic sinuses lacks hematic support, making it difficult to perform mucoperiosteal detachment during the elevation procedure. This may explain why the ≤ 3 mm of remaining crestal bone historically demonstrated a higher incidence of bone resorption/remodeling.^{9,10} If an implant is placed into such thin floors at the crestal level, it may become exposed after a few months of healing, resulting in a higher risk of developing peri-implantitis. Thus, the two-stage procedure is often recommended in extremely atrophic sinuses.

¹Private practice, Brescia, Italy.

²Department of Periodontics and Oral Medicine, University of Michigan School of Dentistry, Ann Arbor, Michigan, USA.

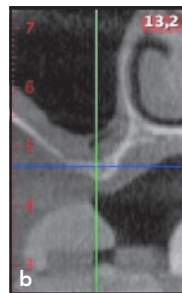
Correspondence to: Dr Hom-Lay Wang, Department of Periodontics and Oral Medicine, School of Dentistry, University of Michigan, 1011 North University Avenue, Ann Arbor, MI 48109-1078, USA. Fax: (734) 936-0374.
 Email: homlay@umich.edu

Submitted January 12, 2019; accepted March 7, 2019.

©2020 by Quintessence Publishing Co Inc.

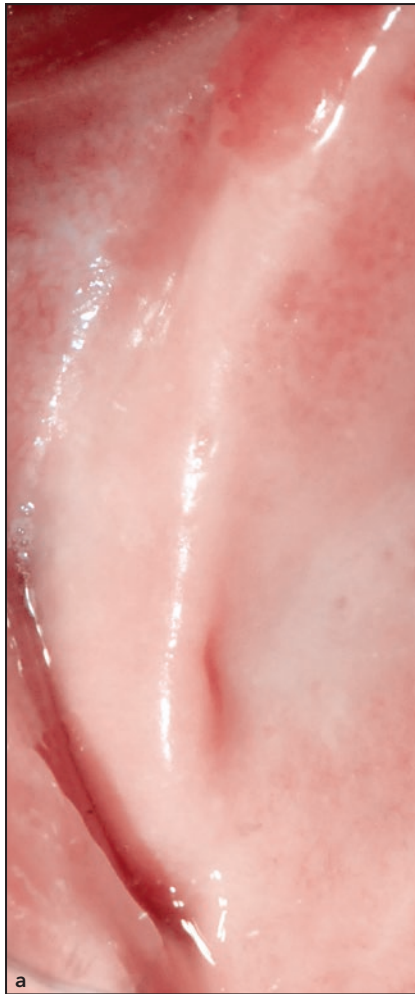

Fig 1 Presurgical (a) clinical occlusal and (b) cone beam computed tomographic views.



The sinus elevation procedure using crestal window approach was first proposed by Winter et al.¹¹ This technique was further modified by limiting indications only to patients with extremely atrophic maxillae (≤ 2 mm).¹² In that specific study, eight patients with 14 maxillary sinuses were treated with the crestal window sinus elevation (CWSE) technique and reported a 93% success rate.¹² Within the last 10 years, more than 200 cases were treated. Therefore, it was the purpose of this study to report long-term clinical outcomes of the CWSE technique.

Materials and Methods

The CWSE Technique

Incision

Presurgical views are shown in Fig 1. The incision is placed in the crestal area, slightly palatal, to ensure that the edges of the mucoperiosteal flap and the subsequent bone window are not aligned (Fig 2a). However, if the anatomical situation requires a significant shift towards the palate in order to obtain misalignment, it is preferable to leave the suture-line window in order to

facilitate sutures without causing suture dehiscence. Where possible, it is recommended to start with a straight incision from the tuberosity and to finish with a divergent releasing incision in the mesial aspect (Fig 2) to allow the wound to close without tension.

Detaching and Elevating the Mucoperiosteal Flap

Detaching and elevation must be done very gently in the vestibular and palatal areas in order to keep as much hematic support as possible and to minimize edema after surgery. The window can also be extended in the distomesial direction to minimize sinus membrane tension during membrane separation (Fig 2b).

Bone Window

A bone window can be opened using the same tools as for traditional lateral windows. In the present cases, a piezoelectric instrument was used to open the window 4 to 5 mm, but it can be extended to 7 mm (Fig 2c). This was needed in order to have a full view of the surgical field. Should sinus septa be present, the window can be cut in two, just as in a lateral window approach (Figs 2d and 2e).

Detaching and Elevating the Sinus Membrane

The instruments and the technique are the same as those used for the lateral window approach, but there are two advantages: The walls of the sinus are made more accessible with no need for undercuts; and under these conditions during the detachment phase, the internal tension of

the mucosa decreases, reducing the risk of breaking the sinus membrane. After the procedure, the sinus membrane is then detached from bony walls using sinus curettes (Figs 2f and 2g).

Grafting

No particular type of material is indicated concerning the quality of the graft. However, the use of particulate material is strongly recommended. When a crestal window is opened, the thickness of the floor must be considered equal to zero. Generally, implants are planned with a length of 12 to 13 mm in the posterior maxilla and therefore requires a vertical augmentation of about 14 to 15 mm. Anatomical studies mentioned in the relevant literature¹³ showed that an average of 3.5 cm³ of graft material is needed in order to obtain this result (Figs 2h to 2j). The cases presented here were all treated using mineralized human allograft (cancellous [20%] and cortical [80%] mixture; Puros, Zimmer Biomet), with a particulate size of 0.25 to 2 mm.¹⁴ Patients treated with other types of bone graft combinations were excluded from the study analysis. Resorbable collagen membrane (BioMend, Zimmer Biomet) was placed 3 mm beyond the crestal window all around to promote wound closure. In all cases, primary closure was obtained without tension using standard techniques (Fig 2k).

Second Surgical Time and Implant Placement

After a healing time of 6 to 9 months,^{9,12,15} a crestal mucoperiosteal flap is again raised exactly at

the original access point. The crestal bone window should have healed completely, and therefore implants now have a good mechanical stability and can be placed without major discomfort to the patient (Fig 3).

Case Series Documentation

After signing an informed consent form, 69 patients (36 men and 33 women, aged between 33 and 75 years) were treated by the same operator (C.S.) between 2009 and 2013. In total, 93 CWSEs were carried out, with 57 and 18 patients undergoing the unilateral and bilateral sinus elevations, respectively. Only patients who had undergone computed tomography (CT) or cone beam CT (CBCT) showing a sinus floor thickness ≤ 2 mm were included in the case series study. Patients who, after being treated, did not have a 5-year follow-up, were not included in this study. Furthermore, patients with psychiatric diseases, who were aged younger than 21, who had taken bisphosphonates in the 3 years preceding the study, who had taken drugs that may influence the bone metabolism, and/or who smoked more than 10 cigarettes a day were excluded from the study.

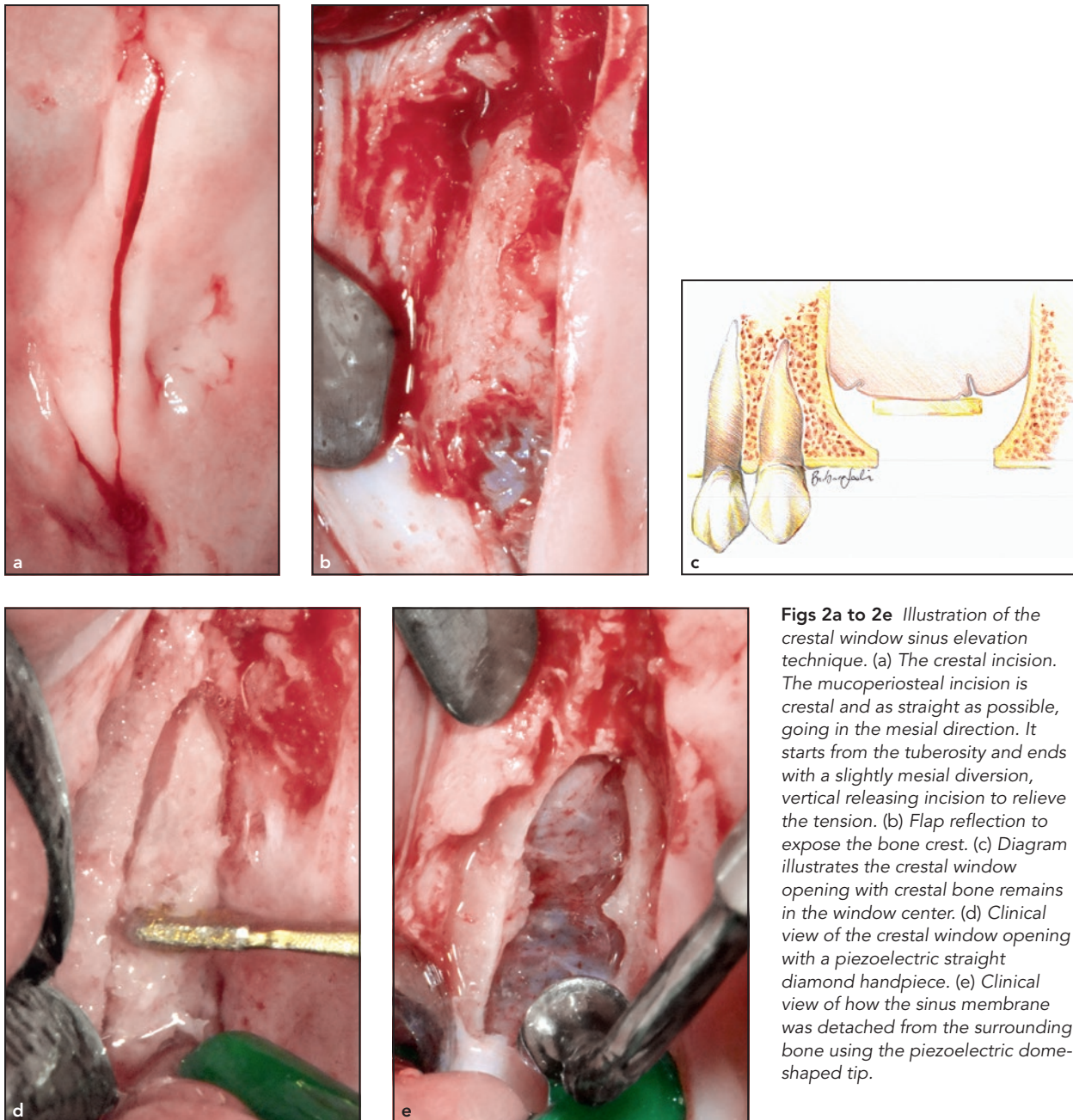
All cases were treated with the same approach as described above by the same surgeon (C.S.). After surgery, patients were prescribed with 1 g amoxicillin (Ratiopharm) twice a day for 6 to 7 days to control infection and 550 mg extra-strength Synflex (Recordati) as an analgesic to relieve patient discomfort.

Results

The evaluation of the residual regenerated bone was carried out using periapical radiographs (Fig 4)—panoramic or CBCT, depending on the patient and the situation—in order to obtain a reliable evaluation without overexposure to radiation. We observed that the bone between the implants showed a tendency towards repneumatization with the implants acting as tentpoles supporting the newly formed bone.¹⁶ The assessment of the residual regenerated bone height was made at the implant sites. It was observed that in 129 sites out of 140, the apical point of the regenerated bone coincided with the apex of the implant. In only 7 out of 93 augmented sinuses (11 out of 140 implant sites) did the authors observe an apical point of the regenerated bone slightly short (3 to 7 mm; average: 3.5 mm) of the apex of the implant.

Table 1 lists the outcome of 140 implant sites augmented via the CWSE approach. When compared to original sinus floor, which is equal to 0 following CWSE removal of all existing alveolar bone, the values obtained are considered the amount of bone augmentation.

Overall, two implants failed. One case was due to secondary sepsis caused by an endodontic problem. The case was then successfully corrected with a second operation 8 months later. The second case failed 3 years after due to occurrence of peri-implantitis. In order to prevent the damage from getting worse and spreading to other implants, the patient's existing



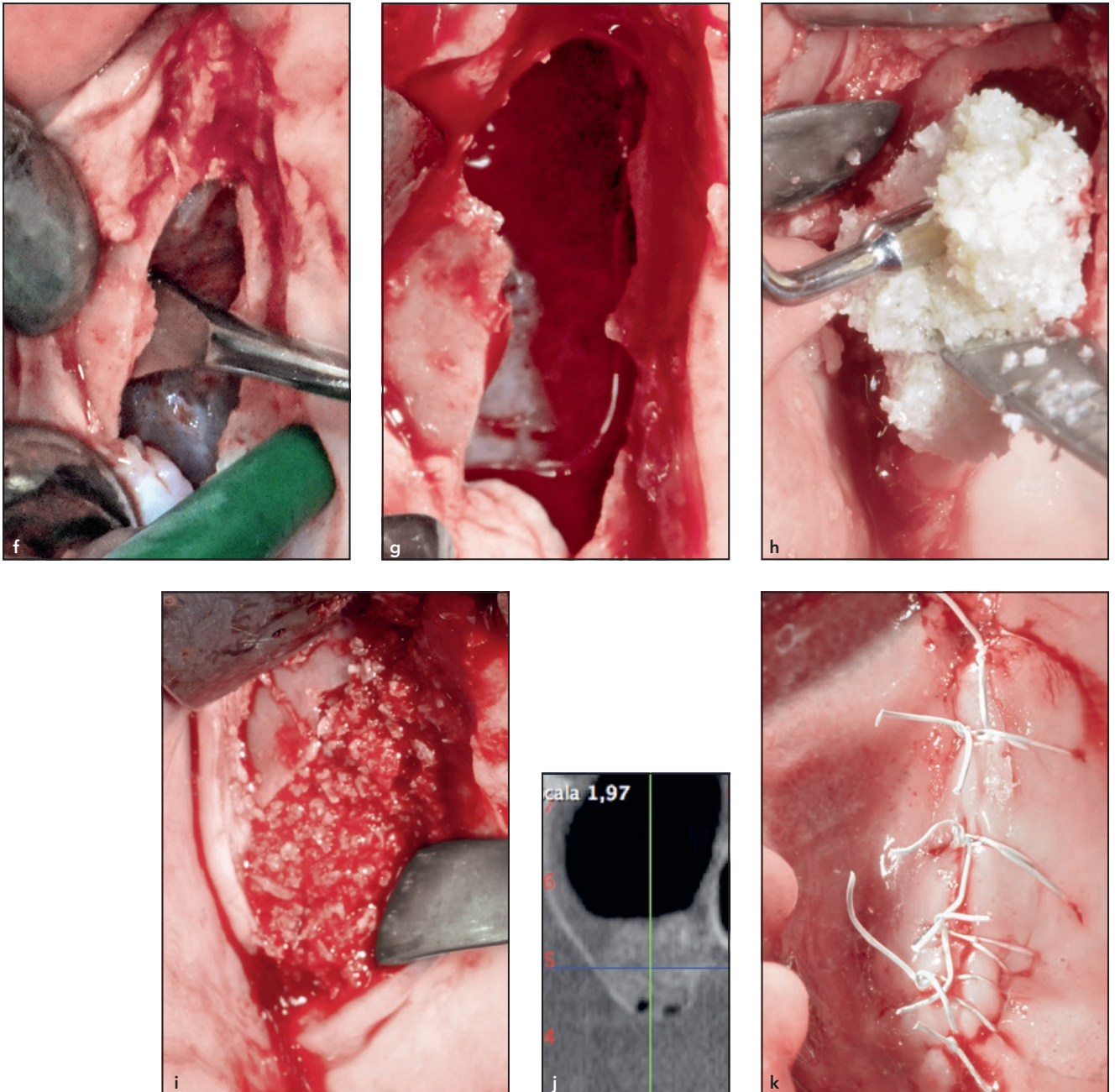
Figs 2a to 2e Illustration of the crestal window sinus elevation technique. (a) The crestal incision. The mucoperiosteal incision is crestal and as straight as possible, going in the mesial direction. It starts from the tuberosity and ends with a slightly mesial diversion, vertical releasing incision to relieve the tension. (b) Flap reflection to expose the bone crest. (c) Diagram illustrates the crestal window opening with crestal bone remains in the window center. (d) Clinical view of the crestal window opening with a piezoelectric straight diamond handpiece. (e) Clinical view of how the sinus membrane was detached from the surrounding bone using the piezoelectric dome-shaped tip.

implant was removed and replaced with a new implant.

Furthermore, 7 transitory orofacial fistulas resulting from the dehiscence of the sutures were also noted. These were treated as complications rather than failures, as 6 cases were managed by mechanical

debridement and saline irrigation and 1 case was treated with mechanical debridement and antibiotic ointment due to a slightly big opening wound. In all 7 cases, the fistulas closed after the application of protective Coe-Pack (GC America) and a prolonged healing time of 4 to 6

months. All complications were successfully resolved without any further surgical operation. Membrane perforations were noted in 14 cases, but these small perforations were successfully managed with an absorbable collagen membrane (BioMend) without further intervention.



Figs 2f to 2k (f) Sinus curettes were used to elevate the sinus membrane until it was (g) totally elevated and detached from the surrounding bone. (h) Mineralized human allograft (cancellous [20%] and cortical [80%] mixture with particle sizes of 0.25 to 2 mm; Puros, Zimmer Biomet) was placed to elevate the sinus. (i) Clinical view after sinus elevation with mineralized human allograft. (j) Postsurgical cone beam computed tomography showed that the sinus cavity was properly elevated to the required height (12 mm). (k) Sutured surgical site.

Twelve patients reported moderate discomfort after surgery. These resulted mainly from edema

and nose bleeding in the evening after surgery. However, 9 patients returned to work in the afternoon

after surgery and the remaining 3 healed uneventfully after 7 days.

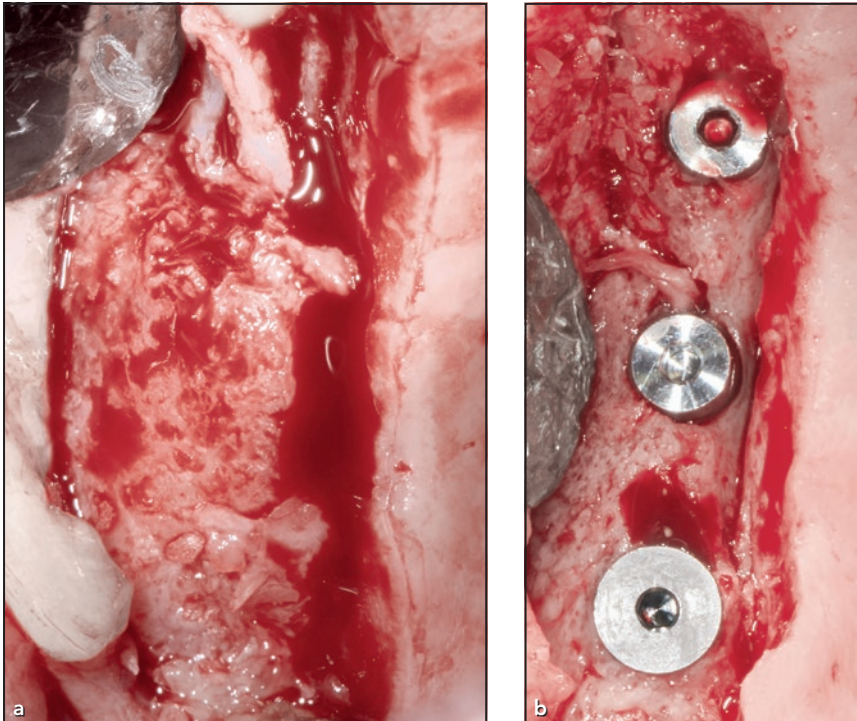


Fig 3 (left) (a) Six months after surgery, bone formation was seen at reentry. (b) Three implants were placed in the newly regenerated bone.

Fig 4 (below) Radiographic view of the prosthesis in place after 9 years.

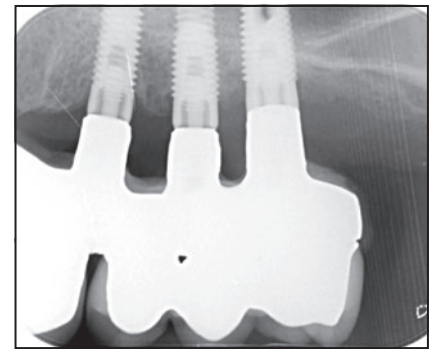


Table 1 Results from Crestal Window Sinus Elevation Technique

Sinuses, n (%)	93 (100)
Postoperative oro-antral fistulas	7 (5)
Postoperative discomfort	12 (8.5)
Implants, n	140
Total bone augmentation, n	
10 mm	37
11 mm	29
12 mm	31
13 mm	35
14 mm	2
15 mm	2
17 mm	3
18 mm	1
Average total bone augmentation, mm	11.73
Implant failures, n (%)	2 (1.42)

Discussion

At this moment, there is no consensus among implantologists regarding which sinus elevation technique (crestal or lateral window) provides

better predictable clinical outcomes with less trauma. The technique proposed here is a modification of Winter et al's¹¹ with two main differences: First, a Piezosurgery instrument (Mectron) is used to open the

window instead of a blade in order to minimize the risk of membrane perforation; and second, a delayed instead of simultaneous implant placement approach is used to provide adequate time for the graft to heal as well as to maintain space during healing. In summary, the CWSE technique proposed here captures both techniques' advantages by combining the traditional crestal approach,¹⁷ which is less invasive, along with the window access approach, which provides better clinical view and adequate hematic support for the graft. Additionally, the CWSE technique reduces the risk of causing damage to the posterior alveolar artery or other vascular structures. Furthermore, the three-wall bony defect (medial, lateral, and anterior) created in crest during CWSE provides a

favorable environment for the graft to mature.

The CWSE approach should only be applied to maxillary sinuses with a floor thickness ≤ 2 mm. The present data showed that a vertical height averaging 11.73 mm can be successfully achieved when this technique is adopted.

As stated above, the CWSE approach enables clinicians to have a view of the surgical field from the window to overcome the shortfall of the crestal approach. Although the lateral window is slightly more complex and surgically invasive, it provides a good visual access of the operating field with predictable, increased vertical augmentation results averaging 10 to 12 mm, as compared to the 3 to 5 mm average elevation height obtained from the crestal osteotome approach.^{18,19}

In addition, the CWSE provides minimal trauma, as noted in the crestal osteotome approach. The CWSE approach also allows the window to widen up to 6 or 7 mm if needed to gain a better view. With adequate primary implant stability and bone regeneration, implants usually can then be placed 6 to 8 months later. Therefore, CWSE may be a solution to many encountered problems of the traditional sinus elevation procedures, especially when the sinus floor thickness is less than 2 mm.

In this study, the authors opted to use the mineralized human allograft that combines 80% cortical bone and 20% cancellous bone, which provided both osteoconductive capacity and osteoinductive potential.¹⁴ Data from CWSE approach showed that mineralized

human bone allograft had been almost completely replaced by the newly formed bone.⁹ The resorption pattern of mineralized human bone allograft was due to the activity of the macrophage and osteoclast cells.³ Thus, the authors suggest using the proposed combination of human allograft when performing the CWSE technique. The CWSE in this study also had some failures (1.4%) when there was a limited amount of residual bone of less than 2 mm, between 2.2%⁵ and 8%, which is in line with literature.⁷

Also, it is important to keep in mind that unlike the lateral window approach, this procedure does not allow clinicians to see the sinus membrane. Thus, the anatomical structure must be recognized prior to the operation in order to avoid any potential complications, especially the detachment of membrane from bony wall via curettes, which rely on tactile feeling.²⁰ Furthermore, for patients with sinus septa or membrane perforation, the CWSE approach requires clinicians to operate with two or more window openings, as noted in the lateral window approach²¹ and membrane repair.²²

Conclusions

Within the limitations of the current long-term case series report, the authors concluded that CWSE is a predictable procedure for elevating the maxillary sinus floor less than 2 mm thick. On average, 11.73 mm of elevation height can be achieved with minimal pre- and postsurgical complications.

Acknowledgments

The authors have stated explicitly that there were no conflicts of interest in connection with this article.

References

1. Boyne PJ, James RA. Grafting of the maxillary sinus floor with autogenous marrow and bone. *J Oral Surg* 1980; 38:613–616.
2. Tatum H Jr. Maxillary and sinus implant reconstructions. *Dent Clin North Am* 1986;30:207–229.
3. Wallace SS, Froum SJ. Effect of maxillary sinus augmentation on the survival of endosseous dental implants. A systematic review. *Ann Periodontol* 2003;8: 328–343.
4. Del Fabbro M, Testori T, Francetti L, Weinstein R. Systematic review of survival rates for implants placed in the grafted maxillary sinus. *Int J Periodontics Restorative Dent* 2004;24:565–577.
5. Peleg M, Garg AK, Mazor Z. Predictability of simultaneous implant placement in the severely atrophic posterior maxilla: A 9-year longitudinal experience study of 2132 implants placed into 731 human sinus grafts. *Int J Oral Maxillofac Implants* 2006;21:94–102.
6. Wang HL, Katranji A. ABC sinus augmentation classification. *Int J Periodontics Restorative Dent* 2008;28:383–389.
7. Mardinger O, Nissan J, Chaushu G. Sinus floor augmentation with simultaneous implant placement in the severely atrophic maxilla: Technical problems and complications. *J Periodontol* 2007; 78:1872–1877.
8. Lundgren S, Cricchio G, Hallman M, Jungner M, Rasmusson L, Sennerby L. Sinus floor elevation procedures to enable implant placement and integration: Techniques, biological aspects and clinical outcomes. *Periodontol* 2000 2017;73:103–120.
9. Soardi CM, Spinato S, Zaffe D, Wang HL. Atrophic maxillary floor augmentation by mineralized human bone allograft in sinuses of different size: An histologic and histomorphometric analysis. *Clin Oral Implants Res* 2011;22:560–566.

10. Soardi CM, Clozza E, Turco G, et al. Microradiography and microcomputed tomography comparative analysis in human bone cores harvested after maxillary sinus augmentation: A pilot study. *Clin Oral Implants Res* 2014;25:1161–1168.
11. Winter AA, Pollack AS, Odrich RB. Sinus/alveolar crest tenting (SACT): A new technique for implant placement in atrophic maxillary ridges without bone grafts or membranes. *Int J Periodontics Restorative Dent* 2003;23:557–565.
12. Soardi CM, Wang HL. New crestal approach for lifting sinus in the extremely atrophic upper maxillae. *Clin Adv Periodontics* 2012;2:179–185.
13. Pikos MA. Maxillary sinus membrane repair: Update on technique for large and complete perforations. *Implant Dent* 2008;17:24–31.
14. Wang HL, Misch C, Neiva RF. “Sandwich” bone augmentation technique: Rationale and report of pilot cases. *Int J Periodontics Restorative Dent* 2004;24:232–245.
15. Soardi CM, Suárez-López del Amo F, Galindo-Moreno P, Catena A, Zaffe D, Wang HL. Reliability of cone beam computed tomography in determining mineralized tissue in augmented sinuses. *Int J Oral Maxillofac Implants* 2016;31:352–358.
16. Peng W, Kim IK, Cho HY, et al. Assessment of the autogenous bone graft for sinus elevation. *J Korean Assoc Oral Maxillofac Surg* 2013;39:274–282.
17. Summers RB. The osteotome technique: Part 4—Future site development. *Compend Contin Educ Dent* 1995;16:1090–1098.
18. Pjetursson BE, Tan WC, Zwahlen M, Lang NP. A systematic review of the success of sinus floor elevation and survival of implants inserted in combination with sinus floor elevation. *J Clin Periodontol* 2008;35(8 suppl):s216–s240.
19. Block MS. The crestal window approach for sinus floor grafting with delayed implant placement: A preliminary report. *J Oral Maxillofac Surg* 2018;76:2319–2330.
20. Tavelli L, Borgonovo AE, Ravidà A, et al. Analysis of forces applied during transalveolar sinus lift: A preliminary clinical study. *Implant Dent* 2018;27:630–637.
21. Wen SC, Chan HL, Wang HL. Classification and management of antral septa for maxillary sinus augmentation. *Int J Periodontics Restorative Dent* 2013;33:509–517.
22. Testori T, Wallace SS, Del Fabbro M, et al. Repair of large sinus membrane perforations using stabilized collagen barrier membranes: Surgical techniques with histologic and radiographic evidence of success. *Int J Periodontics Restorative Dent* 2008;28:9–17.