

UC Irvine

UC Irvine Previously Published Works

Title

Cryogen spray cooling in combination with nonablative laser treatment of facial rhytides.

Permalink

<https://escholarship.org/uc/item/8204j68w>

Journal

Archives of dermatology, 135(6)

ISSN

0003-987X

Authors

Kelly, KM
Nelson, JS
Lask, GP
et al.

Publication Date

1999-06-01

DOI

10.1001/archderm.135.6.691

Copyright Information

This work is made available under the terms of a Creative Commons Attribution License, available at <https://creativecommons.org/licenses/by/4.0/>

Peer reviewed

Cryogen Spray Cooling in Combination With Nonablative Laser Treatment of Facial Rhytides

Kristen M. Kelly, MD; J. Stuart Nelson, MD, PhD; Gary P. Lask, MD; Roy G. Geronemus, MD; Leonard J. Bernstein, MD

Background: Cryogen spray cooling can be used to provide epidermal protection while still achieving spatially selective photocoagulation in the upper dermis. The objective of this study is to determine the efficacy and safety of cryogen spray cooling in combination with a nonablative Nd:YAG ($\lambda = 1320$ nm) laser treatment of facial rhytides in human volunteers.

Observations: Thirty-five adults with bilateral periorbital rhytides were treated with cryogen spray cooling in combination with 3 nonablative laser treatments performed sequentially at intervals of 2 weeks. Small but statistically significant improvements were noted in the mild, moderate, and severe rhytid groups 12 weeks after the final laser treatment. A final assessment performed 24 weeks after the last treatment showed statistically sig-

nificant improvement only in the severe rhytid group. The procedure was found to be safe; 4 sites (5.6%) developed transient hyperpigmentation. Two sites (2.8%) subsequently developed barely perceptible pinpoint pitted scars.

Conclusions: Cryogen spray cooling is a safe and effective method for protecting the epidermis during nonablative laser treatment of facial rhytides thereby avoiding much of the morbidity associated with other resurfacing procedures. Minor improvements in rhytides can be achieved with the current technology. Optimization of treatment parameters may further improve these results.

Arch Dermatol. 1999;135:691-694

SPATIALLY SELECTIVE photocoagulation is the term used to describe the concept of providing epidermal protection while still achieving thermal injury in the papillary and upper reticular dermis. In 1994, Nelson et al¹ described a novel and efficient method for achieving spatially selective photocoagulation with "dynamic" or cryogen spray cooling. When a millisecond cryogen spurt is applied to the skin surface, the cooling remains localized to the epidermis while leaving the temperature of targeted dermal structures unchanged and, thus, susceptible to laser thermal injury. Clinical studies have demonstrated the efficacy of cryogen spray cooling during pulsed laser treatment of port-wine stain birthmarks.^{2,3}

A variety of methods have been used to treat facial rhytides associated with photoaging, which include dermabrasion, chemical peels, and carbon dioxide⁴⁻⁶ or erbium:YAG⁷ laser resurfacing. However, all of these methods completely disrupt or remove the epidermis. The resulting open wounds require daily care to optimize healing and put the patients at risk for a variety of potential complications that include pain, infection, persistent erythema, scarring, or dyspigmentation.

The concept of nonablative laser treatment of rhytides in combination with cryogen spray cooling was first described in 1997.⁸ In that study, cryogen spray cooling in combination with nonablative Nd:YAG ($\lambda = 1320$ nm) laser irradiation using light dosages in the range of 20 to 36 J/cm² successfully protected the epidermis while at the same time producing spatially selective thermal injury in the papillary and upper reticular dermis in animals (pigs) and human subjects. When cryogen spray cooling was *not* used in combination Nd:YAG ($\lambda = 1320$ nm) laser irradiation using light dosages in the range of 20 to 36 J/cm², dermal injury was achieved but epidermal blistering and subsequent necrosis resulted.

The purpose of our current study was to determine the efficacy and safety of cryogen spray cooling in combination with nonablative Nd:YAG ($\lambda = 1320$ nm) laser treatment of facial rhytides in human volunteers. This procedure addresses the aforementioned problems of rhytid treatment by providing a method for inducing dermal remodeling by denaturing the collagen below the skin surface, while avoiding epidermal injury. The results of the studies described herein are expected to lead to the development of a new technology that will provide a much more effective and, most importantly, safer ap-

From the Beckman Laser Institute and Medical Clinic, University of California, Irvine (Drs Kelly and Nelson), the Department of Dermatology, University of California, Los Angeles (Dr Lask), and Laser & Skin Surgery Center of New York, New York City (Drs Geronemus and Bernstein).

PATIENTS AND METHODS

Patients between the ages of 40 and 70 years with bilateral periorbital rhytides and skin types I or II were eligible for enrollment. Patients were excluded if they had active localized or systemic infections, were pregnant, immunocompromised, or had a photosensitivity or coagulation disorder. Additional exclusions included the concurrent use of aspirin or antioxidants or an inability to follow protocol instructions. Patients were permitted neither use of glycolic acids or tretinoin nor of chemical peels or other laser treatments during the study period. The institutional review board at each participating laser center approved the study protocol, and informed written consent was obtained from all patients. Pretreatment evaluations included photography standardized for film and head position.

Prior to each treatment, topical anesthetic Emla cream (a eutectic mixture of local anesthetics—2.5% lidocaine hydrochloride and 2.5% prilocaine hydrochloride; Astra USA, Westborough, Mass) was applied under occlusion to the bilateral periorbital areas for 1.5 to 2 hours. Care was taken to avoid contact of Emla cream with the eye. Immediately prior to treatment, the cream was removed and patients then washed the areas with a mild soap, followed by a gentle cleansing with alcohol.

The New Star model 130 Nd:YAG laser (New Star Lasers, Auburn, Calif) combines cryogen spray cooling with 1320-nm wavelength irradiation. In contrast to ablative carbon dioxide and erbium:YAG laser resurfacing, where incoming photon energy is absorbed in the most superficial few micrometers of human skin, the absorption coefficient for water is much lower at a wavelength of 1320 nm and, therefore, the light penetrates deeper into the

targeted papillary and upper reticular dermis. The cryogen spray cooling is provided by 1,1,1,2-tetrafluoroethane, an environmentally compatible, nontoxic, nonflammable refrigerant that provides epidermal protection and a local anesthetic effect.

Ten milliseconds following a 20- to 40-millisecond cryogen spurt, the laser pulse was delivered. The laser energy was delivered to the skin through an optical fiber and lens that focused the beam onto a 5-mm-diameter spot on the target. The laser energy density used was 28 to 36 J/cm² depending on the patient's blistering response to pretreatment trial pulses of 28, 30, 33, or 36 J/cm². The energy density was increased or decreased during subsequent treatments depending on the occurrence of adverse effects. Bilateral periorbital areas of approximately 2 cm² were treated with 1 or 2 passes of the laser beam at each visit. The initial therapy was followed by 2 treatments, 2 and 4 weeks later; follow-up visits were scheduled 2, 4, 12, and 24 weeks following the third and final treatment. Photography standardized for film and head position were obtained and patients monitored for rhytid reduction and adverse effects at each follow-up visit.

Interim and final assessments were performed 12 and 24 weeks after the last laser treatment. Rhytides were categorized into 1 of 3 groups determined by the mean pretreatment score using the following scale: mild (a score of 1-3), moderate (a score of 4-5), or severe (a score of 6-9) by 3 dermatologists knowledgeable and experienced in laser treatment, but not previously involved in the study. Each dermatologist was given pretreatment and posttreatment photographs of each site to evaluate by paired comparison. Differences between the pretreatment and posttreatment mean scores were then determined and a paired *t* test was performed for each group.

Table 1. Interim Photographic Evaluation (12 Weeks)

Rhytid Severity	N*	Mean (± SD) Pretreatment Score	Mean (± SD) Posttreatment Score	Mean (± SD) Difference	P
Mild	22	2.62 ± 0.35	2.22 ± 0.35	0.40 ± 0.31	<.05
Moderate	37	4.22 ± 0.80	3.55 ± 0.97	0.68 ± 0.50	<.05
Severe	11	6.64 ± 0.57	5.70 ± 1.18	0.94 ± 0.97	<.05

*Denotes the number of treatment sites.

Table 2. Final Photographic Evaluation (24 Weeks)

Rhytid Severity	N*	Mean (± SD) Pretreatment Score	Mean (± SD) Posttreatment Score	Mean (± SD) Difference	P†
Mild	22	2.64 ± 0.67	2.86 ± 0.69	0.23 ± 0.79	NS
Moderate	37	3.95 ± 0.79	3.80 ± 0.87	0.15 ± 0.80	NS
Severe	11	6.30 ± 0.71	5.58 ± 0.87	0.73 ± 0.68	<.05

*Denotes the number of treatment sites.

†NS indicates not significant.

proach to the clinical management of patients with rhytides who are receiving laser therapy.

RESULTS

A total of 37 adults, 3 men and 34 women with bilateral periorbital rhytides, were enrolled at 3 outpatient laser centers. Two patients were lost to follow-up. Therefore, 35 patients with a total of 70 treatment sites were included in the final analysis.

Twenty-two periorbital sites were categorized as mild rhytides, 37 as moderate, and 11 as severe. During an interim assessment performed approximately 12 weeks (**Table 1**) after the final laser treatment, small but statistically significant improvements were noted in the mild,

moderate, and severe rhytides groups. A final assessment performed 24 weeks (**Table 2**) after the last treatment showed statistically significant improvement only in the severe rhytides group (**Figure 1**, **Figure 2**, and **Figure 3**).

Using topical anesthetic Emla cream, the treatment was well tolerated by all patients who described the procedure as only mildly uncomfortable. The cryogen spray cooling also provided an anesthetic effect. Patients did not require postoperative analgesics. Some patients developed erythema or mild edema posttreatment that resolved spontaneously in 1 to 3 days without medical intervention.

Four (5.6%) of the 70 sites developed small, superficial, nonpainful blisters on the treated areas that were therefore treated with emolliation and healed within a

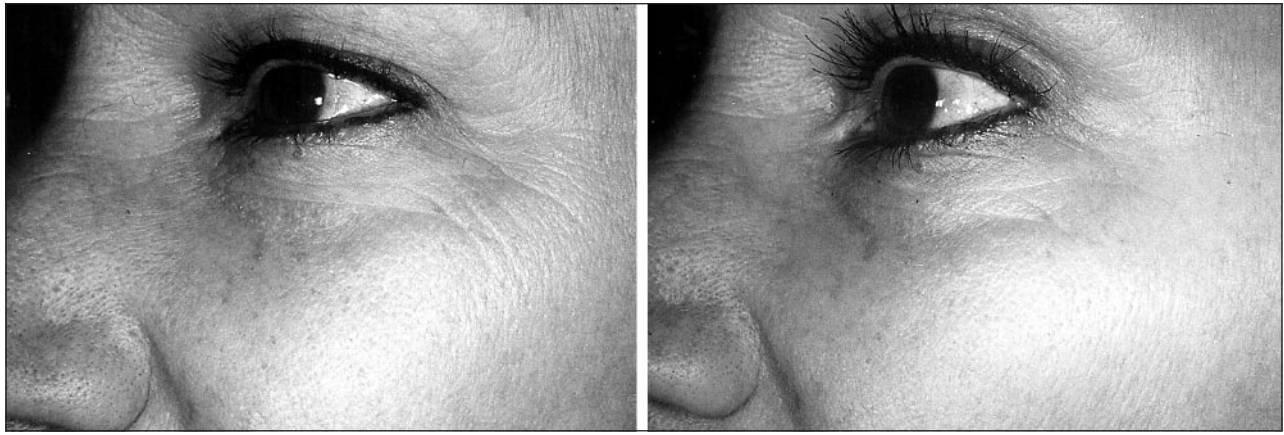

Figure 1. A 53-year-old patient with moderate wrinkling prior to nonablative treatment of rhytides (left) and 24 weeks posttreatment.

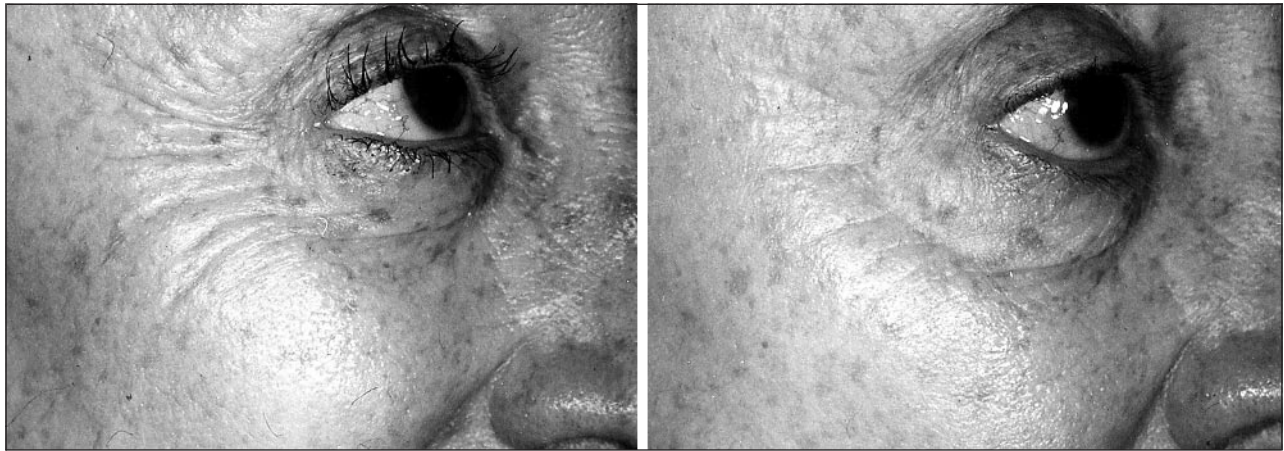


Figure 2. A 64-year-old patient with severe wrinkling prior to nonablative treatment of rhytides (left) and 24 weeks posttreatment (right).

few days. Subsequently, all blistered sites developed transient hyperpigmentation that resolved with the use of 4% hydroquinone cream and avoidance of sun exposure. Two (2.8%) of the 70 sites developed pinpoint pitted scars that, although barely perceptible by inspection, did not improve. These sites did not blister with subsequent retreatments although the energy delivered was decreased by at least 2 J/cm². No other adverse effects were noted.

COMMENT

Most features used to describe "aged" skin are the result of a lifetime of UV exposure rather than the intrinsic aging process. The pathogenesis of this photoaging has not been clearly elucidated, but a partial explanation was recently proposed. Fisher et al⁹ found that UV irradiation induces metalloproteinases in the skin that include collagenase, gelatinase, and stromelysin which subsequently degrade dermal collagen. If such a hypothesis is accurate, it would seem logical that photocoagulation with subsequent dermal collagen remodeling would improve this aspect of photoaging.

With cryogen spray cooling, the laser produces spatially selective collagen denaturation in the papillary and upper reticular dermis without epidermal injury. If effective, the risk of complications such as pain, infection, persistent erythema, scarring, and dyspigmenta-

tion frequently seen after carbon dioxide or erbium: YAG laser skin resurfacing would be considerably reduced. Cryogen spray cooling in combination with nonablative laser treatment minimizes or eliminates the above complications while inciting a wound-healing response that removes denatured collagen and increases fibroblast activity resulting in the formation of new dermal collagen and the reduced appearance of rhytides. The first study describing cryogen spray cooling in combination with nonablative Nd:YAG (1320-nm) laser irradiation indicated that light dosages of 20 to 40 J/cm² are required to induce this dermal remodeling.⁸ Multiple treatments at lower light dosages, below the threshold for epidermal damage, are not likely to create the same dermal effect. However, this was not specifically tested in humans and remains a possibility to be explored in future research.

Inasmuch as the final analysis showed statistically significant improvement only in the severe rhytid group, the improvement noted in the mild and moderate rhytid groups at 12 weeks but not at 24 weeks may have been secondary to edema. It should be noted that our method of rhytid assessment, photography review, is subject to some reviewer error and possible bias.

It is not surprising that rhytid reduction was best observed in patients in the severe rhytid group who had the greatest potential for benefit. Cryogen spray cooling in combination with nonablative laser treatment where

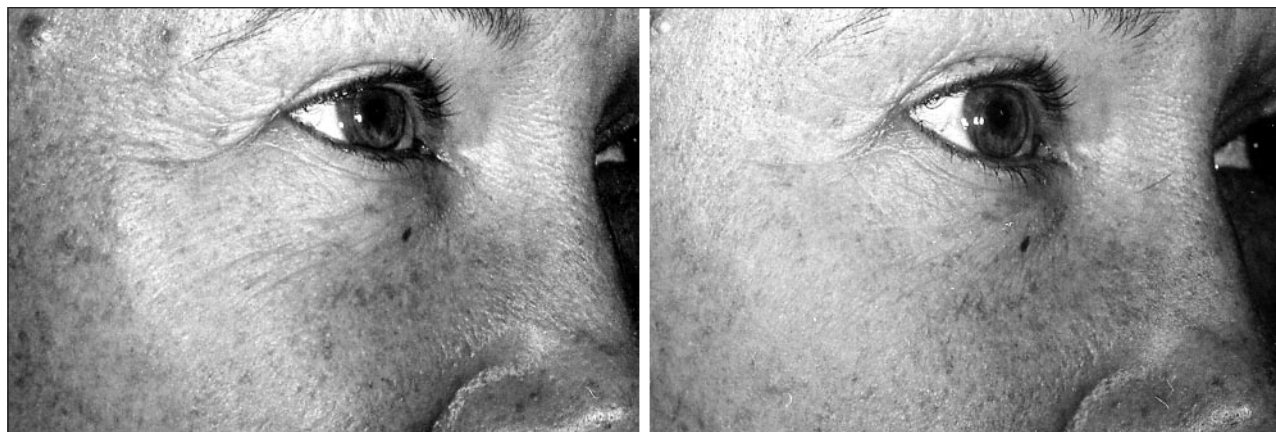

Figure 3. A 47-year-old patient with moderate wrinkling prior to nonablative treatment of rhytides (left) and 24 weeks posttreatment (right).

the epidermis is specifically protected would not be expected to affect surface texture and pigmentary changes that are also a considerable aspect of photoaging. Improved results might be obtained by combining nonablative laser treatment either with a pretreatment regimen that includes tretinoin, glycolic acids, and bleaching agents or superficial chemical peels that would promote epidermal improvement without significant morbidity.

The goal of epidermal protection was achieved on almost all treated areas and the 4 sites that developed blisters with subsequent dyspigmentation were easily treated with bleaching agents containing hydroquinone. The origin of the pinpoint pitted scars that developed in 2 of these 4 sites remains unclear; perhaps the cryogen spray failed to release prior to the laser pulse. A safety feature has now been incorporated into the device so that if the cryogen spray fails to release, the skin will not be exposed to laser irradiation. There have been no further reports of pitted scars since this modification was adopted.

Another recently added feature may also help to improve results. We have determined that blistering is more likely to occur when the skin surface temperature exceeds 50°C immediately after laser exposure. Skin temperature measurements during laser exposure documented substantial interpatient and even site-to-site intrapatient variability; the optimal skin surface temperature immediately after pulsed laser exposure appears to range from 42°C to 47°C. A thermal sensor has been built into the handpiece to measure the skin surface temperature prior to treatment, and then immediately after pulsed laser exposure. By measuring the temperature increase in response to the first few laser pulses, the clinician will be in a better position to choose the optimum light dosage: one that will sufficiently increase the skin temperature to achieve therapeutic results while at the same time not exceeding the epidermal threshold for blistering of 50°C.

Although considerable progress has been made in our study, our experience indicates that several fundamental questions regarding the thermodynamics of cryogen spray cooling in combination with nonablative laser irradiation on the skin surface need to be addressed. We have identified several variables such as cryogen selection, size and velocity of the cryogen droplets, delivery distance between the nozzle and skin surface, and orientation of the cryogen spray relative to the skin surface,

which, if optimized, could improve the results of cryogen spray cooling in combination with nonablative laser treatment of facial rhytides. Moreover, the development of a device with a larger spot size, leading to more uniform dermal heating, is also being actively pursued.

Accepted for publication February 25, 1999.

This project was supported by research grant AR43419 from the Institute of Arthritis and Musculoskeletal and Skin Diseases, National Institutes of Health, Bethesda, Md (Dr Nelson). Institutional support from the Department of Energy and the Beckman Laser Institute and Medical Clinic endowment at the University of California, Irvine, and corporate support provided by New Star Lasers, Auburn, Calif, are gratefully acknowledged.

Presented in part at the 1998 meeting of the American Society for Laser Medicine and Surgery, San Diego, Calif, April 6, 1998.

We would also like to thank Tom Milner, PhD, Bahman Anvari, PhD, Rick Menefee, and John Baumgardner for their valuable scientific and technical contributions.

Reprints: J. Stuart Nelson, MD, PhD, Beckman Laser Institute, University of California, Irvine, 1002 Health Sciences Rd, East Irvine, CA 92612 (e-mail: snelson@bli.uci.edu).

REFERENCES

1. Nelson JS, Milner TE, Anvari B, et al. Dynamic cooling of the epidermis during laser port-wine stain therapy [abstract]. *Lasers Surg Med.* 1994;65:48.
2. Nelson JS, Milner TE, Anvari B, et al. Dynamic epidermal cooling during pulsed laser treatment of port wine stain: a new methodology with preliminary clinical evaluation. *Arch Dermatol.* 1995;131:695-700.
3. Nelson JS, Milner TE, Anvari B, et al. Dynamic epidermal cooling in conjunction with laser induced photothermolysis of port wine stain blood vessels. *Lasers Surg Med.* 1996;19:224-229.
4. Waldorf HA, Kauvar AN, Geronemus RG. Skin resurfacing of fine to deep rhytides using a char-free carbon dioxide laser in 47 patients. *Dermatol. Surg.* 1995;21: 940-946.
5. Fitzpatrick RE, Goldman MP, Satur NM, et al. Pulsed carbon dioxide laser resurfacing of photoaged facial skin. *Arch Dermatol.* 1996;132:395-402.
6. Hruza GJ. Skin resurfacing with lasers. *Fitzpatrick's J Clin Dermatol.* 1995;3:38-41.
7. Laufmann R, Hibst R. Pulsed erbium: YAG laser ablation in cutaneous surgery. *Lasers Surg Med.* 1996;19:324-330.
8. Nelson JS, Milner TE, Dave D, et al. Clinical study of non-ablative laser treatment of facial rhytides. *Lasers Surg Med.* 1997;95:32-33.
9. Fisher GJ, Wang Z, Datta SC, et al. Pathophysiology of premature skin aging induced by ultraviolet light. *N Engl J Med.* 1997;337:1419-1428.