

Review

Current concepts in the management of tendon disorders

J. D. Rees^{1,2}, A. M. Wilson¹ and R. L. Wolman¹

Primary disorders of tendons are common and constitute a high proportion of referrals to rheumatologists. Certain tendons are particularly vulnerable to degenerative pathology; these include the Achilles, patella, elements of the rotator cuff, forearm extensors, biceps brachii and tibialis posterior tendons. Disorders of these tendons are often chronic and can be difficult to manage successfully in the long term.

Significant advances have been made in understanding the pathophysiology of these conditions. Histopathological evidence, together with advances in imaging techniques, has made us more appreciative of the degenerative (rather than inflammatory) nature of these conditions. Additionally the presence of neovascularization is now well-recognized in long-standing tendinopathy.

We review the mechanical, vascular and developing neural theories that attempt to explain the aetiology of degenerative tendinopathy. We also explore theories of why specific tendons (such as the Achilles and supraspinatus tendons) are particularly prone to degenerative pathology.

Traditionally, treatments have placed a heavy emphasis on anti-inflammatory strategies, which are often inappropriate. Recently, however, significant advances in the practical management of tendon disorders have been made. In particular the advent of 'eccentric loading' training programmes has revolutionized the treatment of Achilles tendinopathy in some patients. This concept is currently being extended to include other commonly injured tendons. Other current treatments are reviewed, as are potential future treatments.

Primary disorders of tendons (tendinopathies) are common. Although there are no accurate figures specifically relating to tendon disorders, soft tissues problems in general comprise up to 43% of new rheumatology patient referrals [1].

Studies from primary care show that 16% of the general population suffer with shoulder pain [2]. This rises to 21% in elderly hospital and community populations [3, 4]. Rotator cuff disease was the most common cause of shoulder pain found in the latter two studies.

The prevalence of Achilles tendinopathy in runners has been estimated at 11% [5]. However, they are by no means only linked to sport; in one series of 58 patients nearly one-third did not participate in vigorous activity [6]. Achilles tendon disorders can be difficult to manage successfully in the longer term, with up to 29% requiring surgery [7], and historically there has been a lack of agreement on management due to insufficient outcome data [8].

Tendinopathy of the forearm extensor tendons affects 1–2% of the population, most commonly occurring in the fourth and fifth decades of life. The majority of these injuries (80%) is essentially chronic, repetitive type conditions that are prone to recur [9]. Commonly involved tendons are detailed in Table 1.

Pathology

Primarily degenerative condition in established cases

Historically the term tendinitis has been used to describe chronic pain relating to a symptomatic tendon. Its use is deeply ingrained in the literature and implies that inflammation is central to the pathological process. However, opinion has moved away from this theory.

Histological studies of surgical specimens of chronic tendinopathy consistently show either absent or minimal inflammation. The predominant lesion is one of degenerative change. This is seen in, for example, the Achilles [10, 11], rotator cuff [12], patella [13] and extensor carpi radialis brevis (tennis elbow) [14]. Importantly tendinopathy is not necessarily symptomatic [15].

The macroscopic appearance is of a disorganized tissue, which is soft and yellow or brown in colour (mucoid degeneration). There is loss of the tightly bundled collagen appearance [14, 16]. Microscopically there is degenerative change to the collagen with accompanying fibrosis [17–19]. Typical histopathological changes are shown in Fig. 1.

Additionally neovascularization is consistently identified both in histology [17, 20] and with the use of powered Doppler

¹Institute of Orthopaedics and Musculo-Skeletal Science, Royal National Orthopaedic Hospital, Stanmore, Middlesex HA7 4LP and ²Defence Medical Rehabilitation Centre, Headley Court, Surrey KT18 6JN, UK.

Submitted 13 October 2005; revised version accepted 13 January 2006.

Correspondence to: J. D. Rees. E-mail: j.rees@doctors.org.uk

ultrasound (US) *in vivo* [21, 22]. This neovascularization is reminiscent of that seen in both rheumatoid arthritis and osteoarthritis [23–25].

More recent evidence from Alfredson *et al.* [26] lends additional weight to the degenerative argument. They performed microdialysis of chronically involved (intact) Achilles tendons and were unable to demonstrate the presence of the inflammatory mediator prostaglandin E2. Alternatively, tendon degeneration may be secondary to failure of regulation of specific matrix metalloproteinase (MMP) activities in response to repeated injury [27].

However, most of the histopathological evidence is derived from samples at the point where surgical intervention is necessary, i.e. in chronic cases. It is therefore still possible that inflammation is involved at the initiation of the degenerative process.

TABLE 1. Common primary disorders of tendons classified by anatomical area and tendons most commonly affected.

Area	Tendons most commonly involved
Shoulder	Rotator cuff (particularly supraspinatus) and Biceps brachii tendons
Forearm	Forearm extensor and flexor tendons
Knee	Patella and quadriceps tendons
Lower leg	Achilles tendon
Foot and ankle	Tibialis posterior tendon

There is a combination of anti-gravity and non-anti-gravity tendons. Some tendons are high load (such as the Achilles and patella) whilst some are subject to smaller loads (such as the forearm extensor and supraspinatus).

Is acute inflammation involved at the start of the injury?

There is a lack of good quality histological data from symptomatic tendon disorders of short duration. Two studies, one of the Achilles tendon and one of the patella tendon, included patients with symptoms of only 4 months' duration [28, 29]. Both studies showed a lack of an inflammatory infiltrate but the number of patients with symptoms of such short duration was very small.

Certainly, *in vitro* studies have demonstrated that mechanical loading of human tendon fibroblasts increases production of both prostaglandin E2 (PGE2) [30, 31] and leucotriene B4 (LTB4) [32] and that these mediators may contribute to degenerative tendon change [33]. However, the onset of symptoms does not necessarily coincide with onset of pathology. With advances in imaging these degenerative changes are being recognized in asymptomatic active populations [34, 35]. It is therefore possible that in the early symptomatic cases the pathological process may have been present for much longer. A schematic representation of the disease process is shown in Fig. 2.

What do animal models tell us about early pathology?

One way around the lack of human histopathology in early tendon disease is to look at evidence from experimentally induced tendon damage.

The evidence from two different rat models [36, 37] suggests a degenerative and not an inflammatory process. In rabbit models pathology appears to be related to experimental protocol. In very acute protocols (6 h after a single exercise session) an

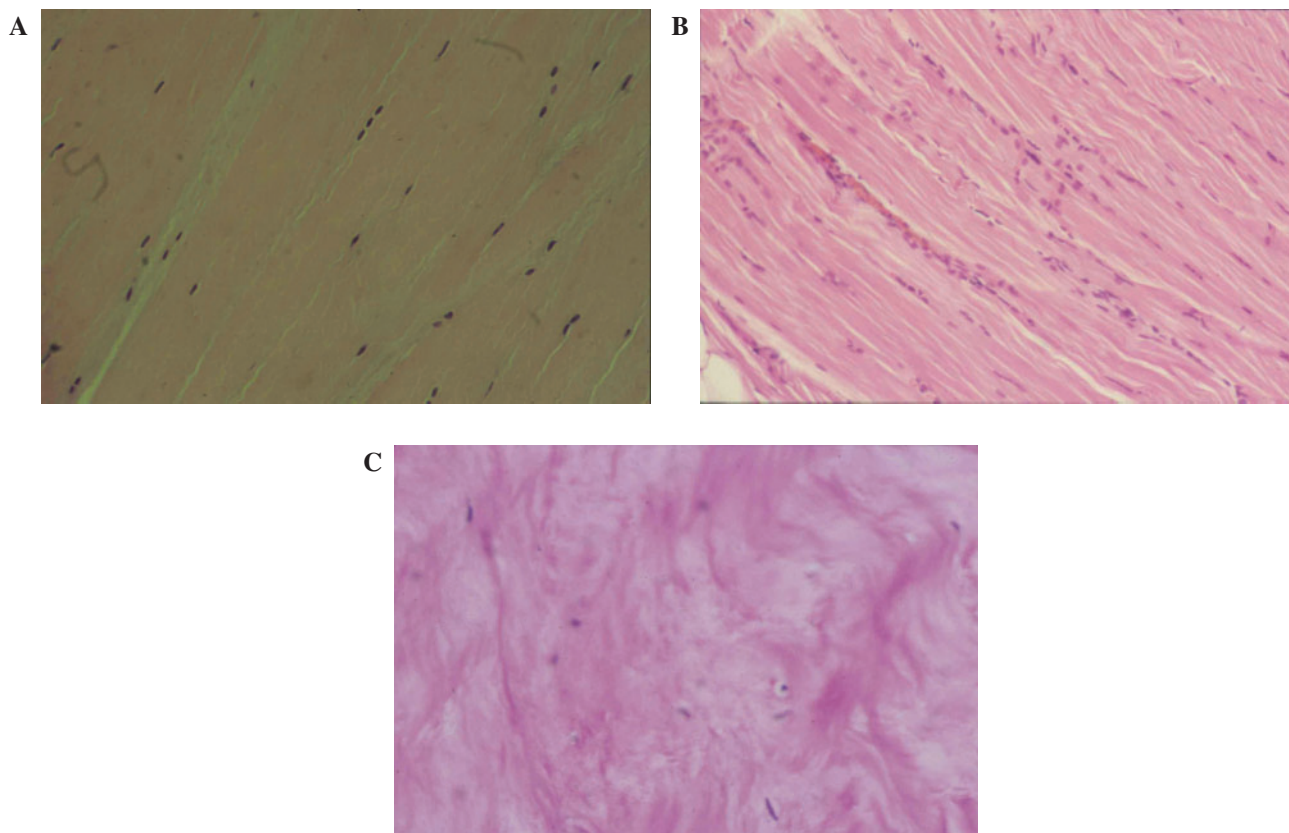


FIG. 1. Histopathological changes seen in tendinopathy demonstrating a lack of an inflammatory response. (A) Normal tendon with scattered elongated cells. (B) Slightly pathological tendinous tissue with islands of high cellularity and initial disorganization. (C) Highly degenerated tendon with some chondroid cells; distinct lack of inflammatory infiltrate. (Images reproduced from Benazzo F, Mosconi M, Maffulli N. Hindfoot tendinopathies in athletes. In: Maffulli N, Renström, Leadbetter WB, ed. Tendon injuries basic science and clinical medicine, Springer, London, 2005, with kind permission of Springer Science and Business Media.) This figure may be viewed in colour as supplementary data at *Rheumatology Online*.

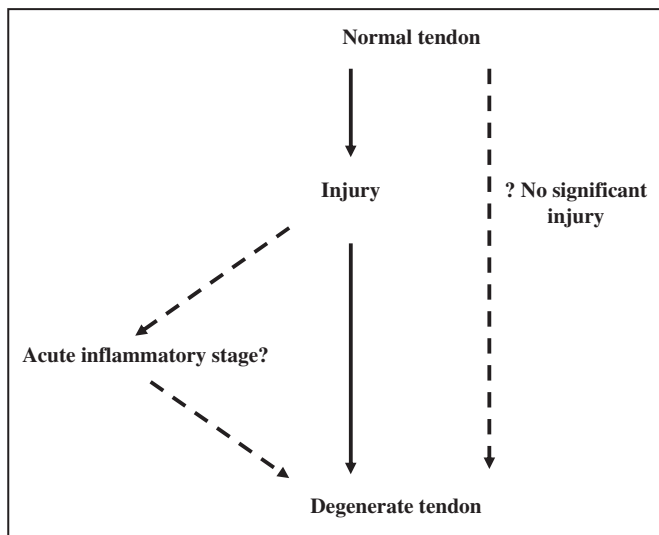


FIG. 2. Schematic representation of the process from initial injury to degenerative tendinopathy, highlighting the potential lack of either a significant inflammatory stage or discernible injury.

inflammatory cell infiltrate is demonstrated within the Achilles tendon [38]. However, a more chronic loading programme (over 11 weeks) failed to show any detectable injury response [39].

The most detailed animal work on tendinopathy induced by overuse has probably been performed in horses, and on the equine superficial digital flexor tendon in particular. Marr and co-workers describe an inflammatory reaction, but only within the first 2 weeks [40].

In an attempt to produce an animal model of tendinopathy, both collagenase and prostaglandin E1 have been injected into tendons [41–44]. Both substances produce a tendinopathy that is similar to the histopathological appearance in humans. Such models have, however, been criticized as they do not directly simulate the overuse process [45].

In summary the limited early human histology suggests no significant inflammatory role at 4 months. Animal models suggest that an inflammatory reaction is present in acute situations but that a degenerative process soon supersedes this.

Terminology

There is confusion within the literature. Numerous terms are used to describe the pathology of tendons, the most common of which are tendinitis (implying inflammation), tendinosis (a degenerative tendon condition without accompanying inflammation) and tendinopathy (no implication for pathology). These terms are often used interchangeably and without precision [46].

Puddu *et al.* [47] proposed the term tendinosis as a histological description of a degenerative pathology with a lack of inflammatory change, and this has widespread support [48]. In the clinical setting, however, it may be more appropriate to refer to a symptomatic primary tendon disorder as a tendinopathy as this makes no assumption as to the underlying pathological process. Tendinitis, however, is not an appropriate term for such a condition.

Aetiology of tendinopathy

Historically there have been two main theories on the causes of tendon degeneration and subsequent rupture, one a mechanical theory the other a vascular theory. More recently a neural theory has begun to develop.

The mechanical theory

In the mechanical theory it is argued that repeated loading within the normal physiological stress range of a tendon causes fatigue and eventually leads to tendon failure.

At rest a tendon has a crimped or wavelike structure. As the tendon is loaded it passes through two stretch regions. The first (known as a toe stretch region) is due to the stretching out of this crimped structure. Only a small amount of force is required to straighten out the crimp [49]. If stretching is continued past the toe region then the tendon enters a linear relationship between load and strain (Fig. 3). Here the load is directly taken up by the collagen fibrils and the stress–strain values are thus determined directly by the physiological properties of the collagen fibrils. Tendons divide into those that experience low strains and those that experience higher strains. The latter are usually loaded during locomotion and as part of their role function as significant elastic energy stores. Historically strain (stretch) values of up to 4% have been regarded as physiological in nature [49, 50] although more recent work has suggested that strain values of 6% and even up to 8% may be physiological [51–54].

Within the physiological range, particularly towards the higher range, microscopic degeneration within the tendon may start to occur, especially with repeated and/or prolonged stressing. This can eventually lead to a symptomatic tendon with altered mechanical properties as a result of repeated microtrauma [49, 55–57].

This theory explains how chronic repetitive damage to tendons could accumulate over time and perhaps why tendinopathy would be degenerative rather than inflammatory in nature. The increased incidence of tendinopathy with age and in the active population is consistent with this theory.

However, this theory does not fully explain why certain areas of particular tendons are particularly prone to degenerative change, neither does it explain the pain sometimes associated with chronic tendinopathy. Also it is somewhat counterintuitive that exercise well within a physiological range should actually harm that tendon. Perhaps, however, accumulated microdamage in a tendon is analogous to the same process that results in a stress fracture. A fracture, though, has the potential for a very good recovery as increased osteoblastic activity followed by osteoclastic remodelling can give an excellent result. A damaged tendon, however, is subject to fibroplasia, which will result in scar tissue formation and a weakened tendon.

The vascular theory

Tendons are metabolically active tissues requiring a vascular supply. Compromise of this supply may cause degeneration. It is argued that certain tendons are susceptible to vascular compromise [58]; these include the supraspinatus [59], the Achilles [60] and the tibialis posterior [61].

Taking the Achilles tendon as an example, there is evidence to support a hypovascular region in the mid tendon area, roughly between 2 and 6 cm proximal to the calcaneal insertion [62]. This is the area most susceptible to both degenerative change and neovascularization. Additionally vascular compromise may be worse during exercise [63].

However, this theory remains controversial. Åstrom and Westlin suggested that there was uniform blood flow in the Achilles with the exception of its distal insertion [64]. Also why would a young athletic population be susceptible to vascular compromise? Certain vigorous exercise regimens such as eccentric loading (explained below) actually lead to a normalization of structure [65]. Furthermore there is the possibility that exercise-induced localized hyperthermia may be detrimental to tendon cell survival rather than vascular compromise [66, 67].

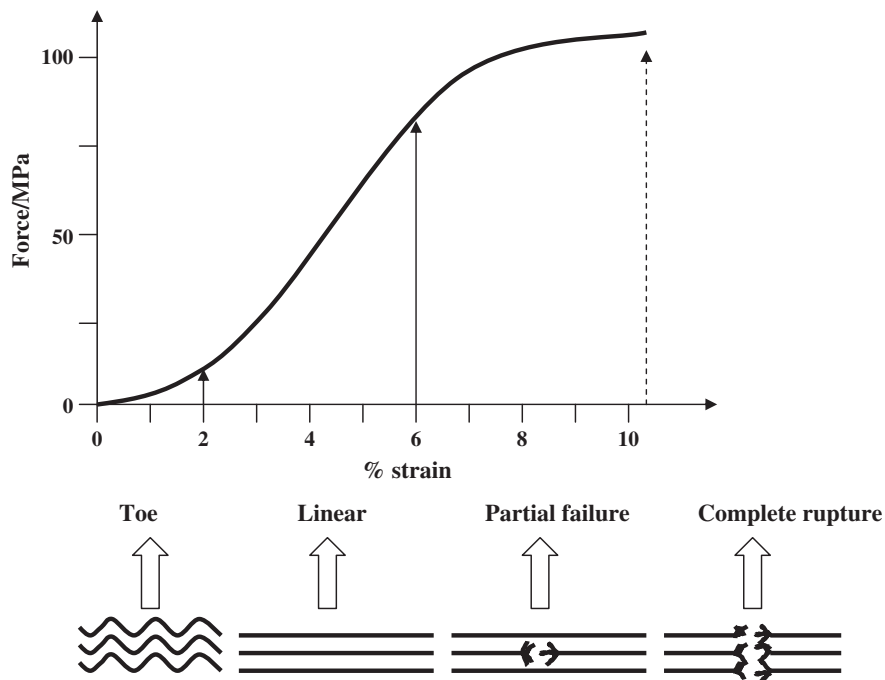


FIG. 3. Stress–strain relationship for progressive loading of a tendon showing three distinct regions (toe, linear and partial failure) prior to complete rupture. Approximate stress forces (MPa) and strain values (% strain) are shown.

The neural theory

More recently a possible neural aetiology for tendinopathy has been explored. This has been based on a number of separate observations:

- (i) The fact that tendons are innervated [68–70].
- (ii) The close association within tendons of nerve cell endings and mast cells. This raises the possibility of neurally mediated mast cell degranulation and release of mediators such as substance P (a nociceptive neurotransmitter) and calcitonin gene related peptide [69]. Chronic tendon overuse could, therefore, lead to excessive neural stimulation and result in mast cell degranulation.
- (iii) That increased levels of substance P have been found in rotator cuff tendinopathy [71].
- (iv) The fact that substance P has been implicated as a pro-inflammatory mediator [72].
- (v) The finding of glutamate, a neurotransmitter, within the ultradialysate in Achilles tendinopathy [73].
- (vi) An association between radiculopathy and tendon disorders. Maffulli *et al.* [74] found an association between Achilles tendinopathy requiring surgery and sciatica in a study using peer-nominated controls.

As yet the full significance of these observations is yet to be determined. More evidence is required to develop a neural theory for degenerative tendon disorders.

Further thinking on aetiology

In practice the aetiology of tendinopathy is likely to be the result of a combination of the above three theories (Table 2), although further possibilities are being explored. These include the possibility that tendinopathy results from a ‘failure of healing’ [75] or even, for lesions of the enthesis, that ‘underuse’ rather than ‘overuse’ is responsible [76].

Any successful theory would also have to explain the cause of pain in tendinopathy. It is uncertain at present where the pain

in tendinopathy arises from, but certainly tendinopathy is only sometimes painful. A biomechanical hypothesis for the pain has been postulated [77] but this theory is yet to be validated.

Intrinsic and extrinsic factors. When considering the aetiology of tendinopathy both intrinsic and extrinsic factors must be taken into consideration, as they may be crucial for both the initiation and propagation of an injury.

Common intrinsic factors that can influence tendon pathology include age, gender, biomechanics and the presence or absence of systemic diseases either inherited (such as Marfan’s or Ehlers–Danlos syndromes) or acquired (such as rheumatoid arthritis or diabetes mellitus). Control over intrinsic factors is often very limited, although some intrinsic factors may be modified (for example by improving glycaemic control in diabetes or by the use of orthotics to alter lower limb biomechanics).

Common extrinsic factors include physical load on a tendon (load and frequency), the environment (e.g. equipment, the working environment, footwear) and occupation. Additionally it is important to recognize a training error (a rapid, not gradual, increase in workload that does not allow any adaptation of the tendon over time) as a possible trigger for a tendon injury.

Genetic factors. It has been reported in some studies that there is an increased incidence of blood group O in patients with tendon injuries, particularly Achilles tendon injuries [78, 79]. These results suggest a genetic linkage between the ABO blood group and the molecular structure of tendons.

Indeed recent studies have revealed the alpha 1 type V collagen (*COL5A1*) gene, which encodes for a structural protein found in tendons, and the guanine–thymine dinucleotide repeat polymorphism within the tenascin-C gene, are both associated with chronic Achilles tendinopathy [80, 81].

Calcific tendinopathy. Calcific tendinopathy (often referred to as calcific tendinitis), a common finding on X-ray and US examination, may be symptomatic although it is commonly an incidental finding. A common site to be affected is the

TABLE 2. Theories on the aetiology of tendinopathy

Mechanical theory	Related to mechanical overload of tendon Damage to collagen or other matrix components can accumulate with repeated stretching, even within physiological limit
Strengths	Explains degenerative nature of tendon histology Consistent with observation, cumulative damage can lead to 'spontaneous' tendon rupture Makes sense physiologically Animal models offer some support
Weaknesses	Does not explain why exercise can improve diseased tendon Does not explain why certain tendons are more susceptible than others Does not explain spontaneous rupture in patients with lack of exercise history
Vascular theory	States that tendons heal poorly because they, or at least certain parts of a tendon, have a poor blood supply. They are thus prone to vascular insufficiency
Strengths	Some support for watershed areas in particular tendons May explain why tendons have vulnerable sections (e.g. mid portion of Achilles)
Weaknesses	Does not explain why exercise (eccentric loading) can heal tendon No convincing evidence of vascular compromise in healthy individuals Role of neovascularization unclear
Neural theory	Tendons are innervated. Alteration to neural homeostasis may lead to tendon pathology
Strengths	Close proximity of tendon innervation to mast cells and potential interaction/degranulation and release of inflammatory mediators Substance P implicated in inflammatory arthritis in other conditions Increased incidence of certain injuries in 'neuropathic' groups, e.g. Achilles tendon rupture with sciatica Altered neural tone may affect feedback to muscle tendon unit and thus affect tensioning and function of muscle/tendon unit
Weaknesses	Essentially a collection of observations rather than a true theory Offers no insight into why only some tendinopathy is painful No direct evidence in support of this theory

supraspinatus tendon, although reliable figures on incidence and prevalence are difficult to obtain.

Various theories have been proposed to explain the pathogenesis of calcific tendinopathy. Calcification secondary to tendon degeneration [82] or chondrogenic metaplasia of the tendon have both been proposed [83, 84]. Uhthoff [83] has additionally suggested a cell-mediated process, which is essentially self-limiting.

It has more recently been suggested that the greatest amount of calcified tissue occurs at the insertion of the tendon and is related to the degree of force transmitted through the tendon [85]. There is more recent evidence from both animal [86] and human studies [87] that endochondral ossification of the tendon is important in the aetiology of this condition. However, the aetiology of this condition remains obscure and more research in this area is required.

Why are specific tendons prone to pathology?

Do these theories help to explain why certain tendons are particularly susceptible to degenerative change?

The rotator cuff and supraspinatus tendon

Degeneration of the rotator cuff increases with age, as does the size of rotator cuff tears [88, 89]. However, the supraspinatus tendon is particularly vulnerable to degenerative change, particularly in the elderly [90]. Several theories have been proposed to account for this although the subject is still controversial, particularly in terms of which factors are primary and which are secondary [91].

Codman [92] suggested the presence of a 'critical zone' of relative avascularity close to the point of insertion of the supraspinatus tendon. This may be affected by the position of the shoulder [93] and increase with age [94]. However, this theory has been criticized. It has been suggested that infraspinatus as well as supraspinatus have a watershed area of vascularity close to their humeral insertions suggesting that factors other than vascularity are important [95]. It has also been argued that

a poor blood supply may be a result of, and not the cause of, an injury [96].

Neer [97] proposed impingement of the rotator cuff, and supraspinatus in particular, as being central to its pathology. Impingement occurs, for example, in forward flexion when the anterior margin of the acromion 'impinges' upon the supraspinatus tendon. This theory provides the rationale for the surgical procedure of decompression of the subacromial space in order to relieve the impingement.

Acromial morphology has also been linked to supraspinatus pathology. Three types of acromial shape have been described [98], types I (flat), II (curved) and III (hooked) with type III associated with a much higher incidence of cuff tear. However, the usefulness of this study has been questioned both because of poor inter-observer reliability on identification of acromion type [99] and acromion shape being possibly an age-related finding [100].

The vascular and impingement theories are not, however, mutually exclusive. It is possible, therefore, that the high incidence of supraspinatus pathology is the result of impingement in and around a critical zone of vascular supply [101].

The Achilles tendon

Although the Achilles tendon is the strongest in the body it is commonly injured. In normal walking, forces of 2.5 times the body weight act on the tendon [102] and considerably larger forces act during running (estimates vary between 6 and 12 times body weight) [103, 104].

The interaction between the foot and shoe may also have an impact on the forces acting on the muscles around the foot. Komi and co-workers [105] have shown that increased pronation can result in increased electromyography (EMG) amplitude in the extensor muscles and decreased EMG amplitude in the flexor muscles. A varus forefoot has also been associated with Achilles tendinopathy [106]. However, there is a lack of evidence to confirm benefit from the use of orthoses or heel wedges in Achilles tendinopathy.

There is a growing body of evidence to suggest that functional overload is an important risk factor. In an US study of a physically

active asymptomatic military population (126 subjects) there was a significant correlation between both hypoechoic area and increased cross-sectional diameter (both indicators of degenerative tendon disease) and years in sport [35]. In a study of elite football players, asymptomatic degenerative changes were a common finding in both the Achilles and patella tendons [34]. These studies are suggestive of a 'load years' or accumulated microdamage concept as a risk factor for degenerative disease.

Other established risk factors for Achilles tendon rupture include quinolone antibiotics [107], particularly in the over 60 yr age group and in those with concurrent oral corticosteroid use [108]. Additionally there is the association between local injection of corticosteroid and tendon rupture (detailed below). The controversy regarding a possible hypovascular area and the significance of this has already been highlighted [62–64].

The tibialis posterior tendon

A further tendon commonly affected by degenerative pathology is the tibialis posterior tendon, the primary dynamic stabilizer of the medial longitudinal arch. Dysfunction of this tendon is a common cause of an adult-acquired flat foot deformity [109–111]. Middle-aged women are commonly affected and numerous risk factors have been identified including increasing age, pes planus, hypertension, diabetes mellitus, peritendinous injections and inflammatory arthropathies [112].

Controversy remains regarding the aetiology of tibialis posterior tendinopathy. It is argued [61] that there are areas of the tendon that are relatively poorly vascularized thus conferring vulnerability, particularly close to the medial malleolus.

Forces acting through this tendon are high and may potentially be influenced by adverse biomechanics; an excessively pronated foot may suggest a mechanical aetiology in some patients [112].

The patella tendon

Patella tendinopathy is common [113] and occurs particularly in explosive jumping sports, hence its alternative, although less precise description, of jumper's knee [114]. It is believed by many to be a degenerative condition, the result of excessive load bearing and tensile strain [115].

Although an alternative impingement theory (of the inferior pole of the patella against the patellar tendon during flexion) has been suggested [116] this has been criticized [117]. More recently an adaptive model for lesions of the patella tendon has been proposed which offers some support for the impingement theory, although this adaptive theory is based on compressive forces being present in the proximal patella tendon, which are as yet unconfirmed [118].

Forces acting through the patella tendon are considerable; it has been calculated that a force of 17 times bodyweight will act on a patella tendon during competitive weightlifting [119]. It is therefore possible that unhelpful biomechanics (such as a large quadriceps or 'Q' angle, external tibial torsion, femoral anteversion or excessive pronation of the feet) may increase forces acting on the patella or result in an uneven load distribution across the tendon but more work is required in this area.

Existing treatments

There are numerous different types of treatment used in the management of tendon disorders and evidence regarding these treatments is summarized below. Unfortunately, few have a strong evidence base. In particular (with the exception of the recent work on eccentric loading) physical therapies, strength deficits, inflexibility and improper equipment had not been studied in a controlled and prospective manner [120].

Non-steroidal anti-inflammatory drugs

The use of non-steroidal anti-inflammatory drugs (NSAIDs) in the treatment of tendinopathy remains controversial both in the acute stage (where there is debate on whether blocking the acute inflammatory response is helpful or not) and in the chronic stage (where there is little or no inflammatory infiltrate) [121]. NSAIDs do, however, have an analgesic effect possibly independent of the anti-inflammatory action.

A review of the literature [100] found 32 studies on the use of NSAIDs in the treatment of tendinopathy. However, only nine of 32 studies were prospective and placebo controlled. Some pain relief was found in five of the nine controlled studies, but healing of the tendon was not studied.

Animal studies on the use of NSAIDs in tendon injuries have produced conflicting results, with some studies suggesting increased tendon tensile strength [122–124] whilst a primate study suggested a reduction in breaking point [125].

Corticosteroid injections

Corticosteroid injections are a commonly administered treatment for tendon disorders. All the usual side-effects of corticosteroids are possible (such as skin atrophy, skin hypopigmentation, post-injection flare of symptoms, infection and possible effects from systemic absorption particularly after multiple injections) [126]. There is also the possible effect on the mechanical integrity of the tendons themselves.

A Cochrane review was published on the role of corticosteroid injections for shoulder pain, which included outcome information for patients with rotator cuff disease specifically [127]. In this group of patients two small studies suggested a small benefit for subacromial steroid injection compared with placebo at 4 weeks. However, the reviewers commented that it was difficult to draw any firm conclusions on the results of five further trials due to varying methodological trial quality and varying results.

A systematic review of corticosteroid injection for tennis elbow found a total of 12 trials suitable for review. Analysis indicated that corticosteroid injection was effective in the short term (2–6 weeks) but that in the long term there was no difference from the control group [128]. Subsequent controlled studies have confirmed a beneficial initial response but failed to show any long-term benefit [129, 130].

There are several case reports of tendon rupture following corticosteroid injection, particularly involving the Achilles tendon [131]. Ford and DeBender [132] have reported a series of tendon ruptures (including the biceps brachii, Achilles and supraspinatus) following the use of corticosteroid injections.

Some animal studies have suggested that local corticosteroid injection may lead to a reduction in tendon strength [133], but again this finding is not universal [134]. Given possible concerns relating to tendon integrity post-injection, particularly at the Achilles tendon, some argue that the use of intratendinous injections is contraindicated whilst evidence surrounding peritendinous injections is lacking [135]. Given the paucity of good-quality studies it is impossible to provide high-quality advice [136, 137], but there is no good evidence to support the use of local corticosteroid injections in chronic tendon lesions [136].

Physical treatments

Cryotherapy. The use of cryotherapy in the acute injury of a tendon, particularly in sport, is widespread. However, there has been little research performed in this area. Cryotherapy is believed to reduce blood flow and tendon metabolic rate and hence swelling and inflammation in an acute injury [118, 119].

There is the potential benefit of analgesia, which may help explain the popularity of this treatment.

Therapeutic ultrasound. Therapeutic ultrasound is a common physical treatment for tendon disorders. Ultrasound waves are transmitted from a transducer to a patient via a coupling medium (such as a gel). Ultrasound has a thermal effect on tissues, causing local heating, although this may be attenuated by the use of a pulsed (intermittent) process. Despite the popularity of therapeutic ultrasound there is little clinical evidence demonstrating its efficacy [140–142].

Laser. A further physical treatment is the use of low-intensity lasers in the treatment of tendon lesions. Trials to date have shown contradictory results and it is therefore not possible to advocate the use of lasers until more data are forthcoming [143].

Manual therapy techniques

There are several manual therapies popular in the treatment of tendon disorders, the two most common being friction massage and soft tissue mobilization.

Deep transverse friction massage (DTFM), a treatment made popular by Cyriax, has been the subject of a Cochrane review. There were only two randomized controlled trials of sufficient quality to be included; one on the treatment of extensor carpi radialis tendinopathy (lateral epicondylopathy) and the other on the iliotibial band friction syndrome. In neither trial was DTFM able to show a consistent benefit over the control group for pain, strength or functional status, although the conclusions were limited by small sample sizes [144].

A second popular technique is of soft tissue mobilization. Mobilization via massage of the area around an injured tendon will stimulate blood supply in the vicinity of the injury and this is thought to promote healing of the affected tendon. However, studies in this area are lacking.

Biomechanical alterations

A common treatment for Achilles tendinopathy is the insertion of a heel pad. There is one small randomized trial of heel pads in the treatment of Achilles tendon disorders. No difference between the heel pad or non-heel pad group was observed at both 10 days and 2 months [145].

In lateral epicondylopathy the Cochrane review included five trials of orthotics but found there was insufficient evidence to draw any conclusions [146].

In tibialis posterior tendon dysfunction an orthotic, which supports the medial longitudinal arch of the foot, is thought to be helpful [112]. It is claimed that a conservative approach including the use of orthotics will produce good results in up to two-thirds of cases with mild disease [147] but controlled trials are lacking in this area.

Emerging treatments

Eccentric training. Recently there has been renewed interest in the use of eccentric training for the treatment of degenerative tendon disorders in general, and of the Achilles tendon in particular. Eccentric loading exercises involve active lengthening of the muscle tendon unit.

Although not new [148, 149] eccentric training or 'loading' regimens have been popularized following successful randomized controlled trials for the treatment of Achilles tendinopathy [150, 151].

In the Alfredson protocol [150] the patient groups were required to perform exercises on a daily basis for 12 weeks (Fig. 4). The control group were required to perform concentric exercises (active shortening of the muscle tendon unit). High levels of patient satisfaction were seen in the eccentric loading groups (82%). Similar outcomes have been demonstrated by other research groups [152].

In subsequent long-term follow-up (mean 3.8 yr) Alfredson and co-workers have confirmed both the initial good results and a statistically significant reduction of tendon thickening (from 8.8 mm average to 7.6 mm average; Fig. 5). Doppler evidence showed that neovascularization also resolved in the responders (Fig. 6) [153].

The success of this treatment this has led to efforts to see whether the results can be extended to other tendon disorders. Two small studies on the use of eccentric exercises in patella tendinopathy have shown some promising results, although the numbers in each group are small and the follow-up duration short [154, 155]. This second study suggested an advantage in using a decline board (raising the heel relative to the toes to increase the eccentric loading), a result that has subsequently been confirmed in a follow-up study [156].

A further pilot study using eccentric loading in the management of long-standing supraspinatus tendinopathy in patients waiting for surgery has recently been published [157]. Although containing very small patient numbers (nine only) after a 12-week exercise programme five (56%) had improved to the extent that they no longer wanted surgery. Patients with arthritis of

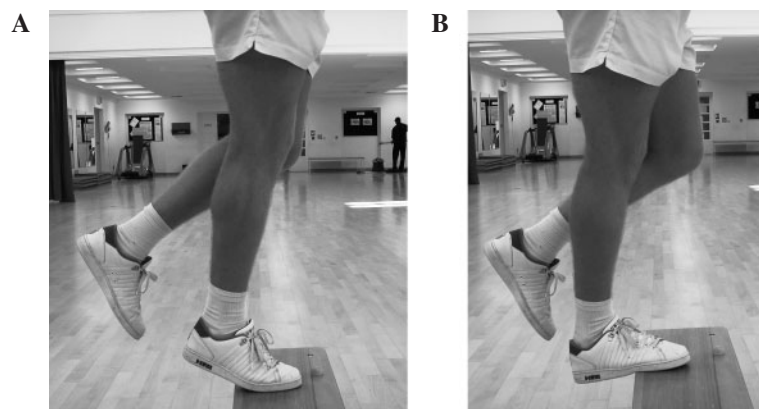


FIG. 4. Eccentric loading of the right gastrocnemius muscle/Achilles tendon showing the starting position (A) and finishing position (B). Three sets of 15 repetitions are performed twice per day, 7 days per week for 12 weeks. The exercises are repeated with the knee flexed to load the soleus muscle. The contralateral leg performs recovery to the starting position.

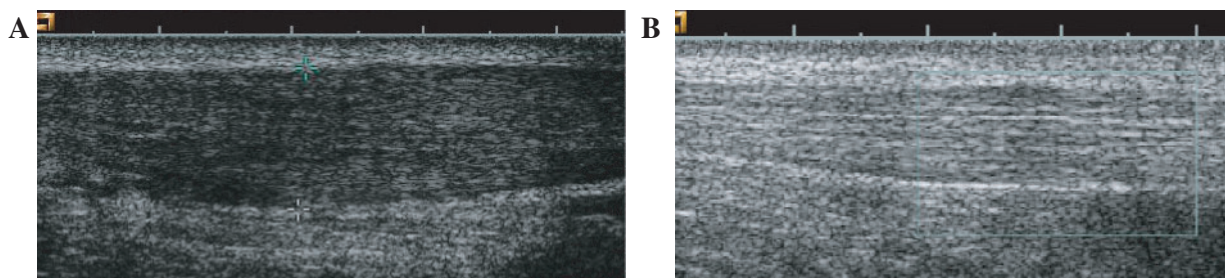


FIG. 5. Ultrasound appearance of Achilles tendon before and after a long-term eccentric loading programme. (A) Typical appearance of a hypoechoic Achilles tendon prior to commencing an eccentric loading programme. (B) The appearance after a long-term eccentric loading programme. Loss of hypoechoic appearance and reduced tendon thickening are demonstrated. (Reproduced from Öhberg L, Lorentzon R, Alfredson H. Eccentric training in patients with chronic Achilles tendinosis: normalised tendon structure and decreased thickness at follow up. *Br J Sports Med* 2004;38:8–11 with permission from the BMJ Publishing Group.)

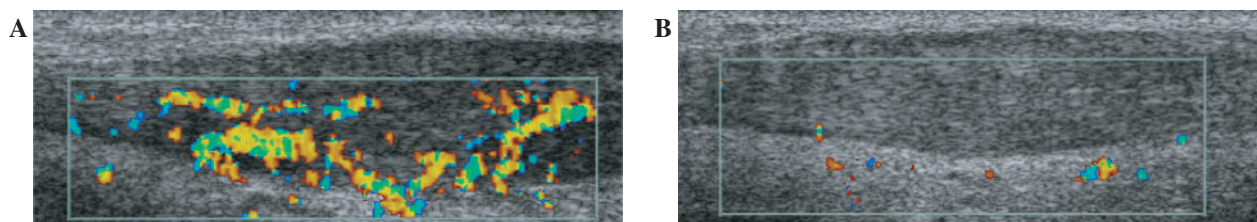


FIG. 6. Beneficial effect of eccentric training on neovascularization of the Achilles tendon. (A) Achilles tendon prior to eccentric loading programme. Significant neovascularization on power Doppler study. (B) Achilles tendon after eccentric loading programme. Absent neovascularization on power Doppler study. Image reproduced from Öhberg L, Alfredson H. Effects of neovascularisation behind the good results with eccentric training in chronic mid-portion Achilles tendinosis. *Knee Surg Sports Traumatol Arthrosc* 2004;12:465–70, with kind permission of Springer Science and Business Media.) This figure may be viewed in colour as supplementary data at *Rheumatology* Online.

the acromioclavicular joint or significant calcification were, however, excluded.

Despite these promising results questions remain. Why the programme is successful is uncertain. These programmes require highly motivated people who are also willing to perform multiple repetitions, twice daily, 7 days a week for 12 weeks, and this will not suit all patients. There is the additional concern still that these exercises could worsen the condition, as pain levels increase initially. Also the evidence is confined to tendon body lesions and does not apply to lesions of the muscle tendon junction or of the tendon insertion.

Other drugs, injections and treatments

Numerous other drugs or substances have been used in the treatment of tendon disorders, including heparin, dextrose, sclerosants, calcium gluconate, autologous blood injections and aprotinin. Various claims about the healing nature of the above substances have been made but few stand up to scrutiny.

Extracorporeal shock wave therapy. Extracorporeal shock wave therapy (ESWT) is a technique used in the treatment of tendon disorders, particularly calcific tendinopathy. The treatment is an extension of lithotripsy used in the treatment of renal calculi.

Some studies have suggested a benefit from this treatment for calcifying tendinopathy of the shoulder [158–161]. There is also some evidence of benefit in chronic heel pain [162]. However, there is little evidence of benefit in other conditions, such as lateral elbow [163] and shoulder pain not due to calcific tendinopathy [164, 165].

Heparin. Theoretically the injection of heparin, particularly in the acute situation, could lead to reduced adhesions and fibrin exudates. One animal study suggested that heparin injections could lead to improved orientation of collagen fibres and a reduction in cellularity and neovascularization in the tendon [166]. However, a more recent animal study found heparin had a degenerative effect [167].

Dextrose. There is only one trial on the use of dextrose injections as a treatment for tendinous lesions, although this was not controlled [168]. Proponents of these injections make the remarkable claim that ‘growth factors’ are released following injection, which results in local tissue proliferation or ‘prolotherapy’ [169]. In the absence of controlled data no further comment can be made on the efficacy of this treatment.

Aprotinin. Of all the ‘alternative’ substances available for injection aprotinin has probably become the most popular. Aprotinin is a broad-spectrum protease inhibitor. It is licensed for use in open heart surgery for prophylactic reduction of blood loss [170, 171].

There are two trials in the literature, both of approximately 100 patients and both using randomized controls. The first study was performed in patients with Achilles tendon disease (principally insertional tendinopathy or paratendinopathy) [172]; the second on patients with patella tendon disease (predominately insertional tendinopathy or lesions of the main body of the tendon) [173]. Injections were directed to the site of the pathology. Both studies suggested significant benefit from aprotinin injection, although there is a need for further work from other groups to confirm these findings. Proponents of aprotinin suggest that by inhibiting enzymes that break down or degrade tendons this can promote the healing response.

Autologous red cell injection. The injection of autologous red cells in and around a symptomatic tendon is sometimes performed, particularly in the field of sports medicine. There is one report in the literature of a small, non-controlled study of injection of autologous blood in the treatment of long-standing lateral elbow pain. No conclusion can be drawn from this study, as there was no control group [174] and thus this technique cannot be recommended.

Sclerosant injections. Alfredson *et al.* [175] have suggested that the pain in Achilles tendinopathy may be related to the neovascularization. Two very small uncontrolled pilot studies have been published by this group in which a sclerosant agent (polidocanol) was injected around the neovascularization both in mid-portion [176] and insertional Achilles tendinopathy [177]. The injections were effective at reducing levels of pain, presumably as the sclerosant injection was toxic both to the neovascularization and localized sensory nerves.

It is probably best to regard this technique as experimental for two reasons: the procedure is practically demanding and the results of controlled trials are awaited. There is also the theoretical risk that in removing the pain associated with tendinopathy there is removal of a protection mechanism against further tendon damage.

Topical glyceryl trinitrate. One group recently studied the effect of topical glyceryl trinitrate in the treatment of various tendinopathies including Achilles, forearm extensor and supraspinatus in double blind, randomized trials. These studies showed improvement in the treatment arms compared with controls at 6 months [178–180].

The reasons for the result are uncertain, although the authors speculate that local vasodilatation may lead to an increased local blood supply [178]. These results are yet to be repeated by other groups.

Polysulphated glycosaminoglycans. There are a number of studies, in both the human and the veterinary literature, suggesting that injection of glycosaminoglycan polysulphate (GAGPS) may lead to an improvement in disease of the human Achilles and equine superficial digital flexor tendon, respectively [181–183]. In the human study, local injection of GAGPS was compared with oral indomethacin and at 1-yr follow-up two-thirds of the GAGPS group had a good response compared with only one-third of the indomethacin-treated group [181]. However, this study was confined to peritendinous lesions rather than lesions of the body of the Achilles and more data are needed in this area.

Summary of current treatments

There are many drawbacks of existing treatments. One principal drawback is that the characteristic response to injury is for fibroplasia to occur, which inevitably leads to scar tissue in the tendon. Although remodelling of the scar tissue occurs over time the subsequent tissue is not normal and, in particular, has less compliance and functionality than the original tendon matrix.

The future

As a result of the deficiencies of current treatment there is great interest in investigating the potential for stem cell therapy in tendon injuries.

There are two main types of stem (progenitor) cells; embryonic (pluripotent but research restrained by ethical considerations) and post-natal. Post-natal stem cells are further subdivided into haematopoietic stem cells (differentiation restricted to haematological cell lineage) and mesenchymal stem cells. Mesenchymal

stem cells are able to differentiate into numerous cells including tenocytes, chondrocytes and fibroblasts. They therefore present a potentially exciting alternative in the treatment of tendon lesions.

Small animal models have been developed using mesenchymal stem cells to repair tendon defects. Young *et al.* [184] used mesenchymal stem cells to promote healing in a collagen matrix subsequently implanted in a rabbit Achilles tendon. Whilst there was healing of the defect, subsequent histology confirmed that the new cells exhibited morphology more similar to fibroblasts than tenocytes.

Subsequently, however, using autologous bone marrow-derived stromal cells, Smith and co-workers [185, 186] have developed a stem cell-based treatment for the management of acute tendon injuries in horses where injuries to the digital flexor tendons have many similarities to injuries of the human Achilles tendon. In this technique the stem cells harvested from bone marrow are expanded *in vitro* and then implanted under ultrasonographic guidance into the core lesion of the damaged tendon. After implantation the horses enter a controlled exercise programme. Ultrasonographic examination has revealed rapid infilling of the core defect of the animals treated to date (more than 60; Fig. 7). There is some early evidence that results using this technique may be superior to conventional treatments, although to confirm these findings a larger clinical trial would be required. Nevertheless these early results are exciting and highlight the potential use of stem cell treatment in the future.

There has also been recent speculation about the possible contribution from both reactive oxygen [187, 188] and reactive nitrogen [189] species in the development of tendinopathy. This raises the possibility that manipulation of reactive oxygen and nitrogen species may enhance tendon healing clinically.

Research into transcription factors, such as scleraxis and sox9, that regulate the determination and differentiation of tendon cells may help us understand the molecular signalling that helps govern tendon development [190]. Gene therapy offers an alternative method for the delivery of proteins to target tissue that has the potential for increased delivery over a longer time interval, although more research is needed to determine the safety and efficacy of these techniques [191]. Additionally, since excessive apoptosis has been described in degenerate tendon tissue this has raised the hope that strategies designed to reduce excessive apoptosis may prove effective in treating tendinopathy [192].

Furthermore, novel techniques are being developed for studying both tendon function and for determining tendon material properties *in vivo*. These techniques offer the potential for directly assessing tendon properties rather than inferring them indirectly, and will potentially make it feasible to perform objective clinical trials on the properties of tendons [193, 194].

Summary

Primary tendon disorders are common and can be difficult to manage successfully. The degenerative nature of these conditions is now well recognized and certain tendons appear particularly prone to this degenerative pathology. Traditional treatments have placed a heavy emphasis on anti-inflammatory strategies, although the evidence base for this approach is unconvincing. If inflammation is present then its presence appears transient.

There are three theories regarding the aetiology of tendinopathy and each has its own strengths and weaknesses. Indeed these three theories are not mutually exclusive and can help explain why certain tendons in particular are so prone to degenerative disease. Our understanding of the pathological processes is improving, and significant advances in imaging, particularly with MRI and ultrasound, aid this. However, many questions regarding the pathological process remain, such as why some tendinopathy is only sometimes painful and what causes the pain.

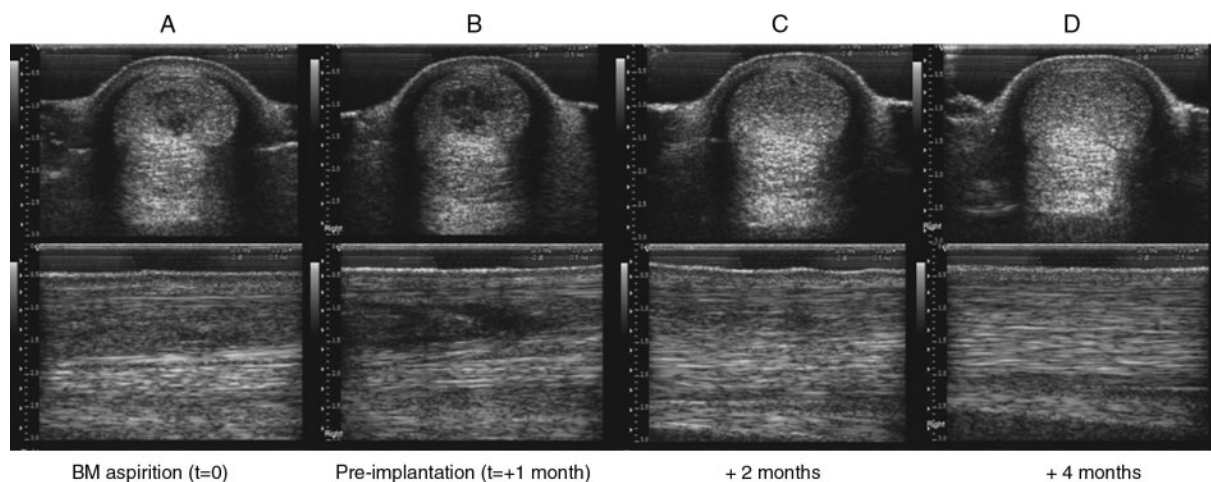


FIG 7 Sequential transverse (top row) and longitudinal (bottom row) ultrasonographs taken from a horse treated by the stem cell technique. (A) At bone marrow aspiration. (B) One month after aspiration, just prior to implantation. (C) One month post-implantation. (D) Three months post-implantation. Note the rapid infilling of the lesion within 1 month of implantation, whereas there was little change in the lesion in the preceding month. (Image reproduced from Smith RKW, Webbon PM. Harnessing the stem cell for the treatment of tendon injuries: heralding a new dawn? *Br J Sports Med* 2005;39:582–4, with permission from the BMJ Publishing Group.)

Whilst there are numerous other treatments currently in use for the treatment of tendinopathy many, unfortunately, have a poor or non-existent evidence base. More high-quality research is needed on these treatments in order to strengthen the evidence base and determine which treatments should be retained and which should be dropped.

The recent successful randomized controlled trials on eccentric loading, particularly for chronic mid-portion tendinopathy of the Achilles tendon, has transformed the management of this condition, although the benefit appears confined to mid-substance lesions. Eccentric loading regimens are, however, not suitable for our more frail patients, and require a high level of patient motivation.

A greater appreciation of the degenerative nature of these conditions will hopefully lead to more appropriate new treatments and more rational treatment strategies.

<i>Rheumatology</i>	Key messages
	<ul style="list-style-type: none"> • Primary disorders of tendon are degenerative in nature. Tendinitis is not an appropriate term. • There is a lack of evidence to support many commonly used treatments including the use of NSAIDs and corticosteroids. • Eccentric loading training programmes are providing excellent results in chronic tendinopathy of certain tendons, particularly the Achilles tendon.

The authors have declared no conflicts of interest.

Reference

1. Bamji AN, Dieppe PA, Haslock DI, Shipley ME. What do rheumatologists do? A pilot audit study. *Br J Rheumatol* 1990;29:295–8.
2. Urwin M, Symmons D, Alison T *et al*. Estimating the burden of musculoskeletal disorders in the community: the comparative

- prevalence of symptoms at different anatomical sites, and the relationship to social deprivation. *Ann Rheum Dis* 1998;57:649–55.
3. Chard MD, Hazleman R, Hazleman BL, King RH, Reiss BB. Shoulder disorders in the elderly: a community survey. *Arthritis Rheum* 1991;34:766–9.
4. Chard MD, Hazleman BL. Shoulder disorders in the elderly (a hospital study). *Ann Rheum Dis* 1987;46:684–7.
5. James SL, Bates BT, Osternig LR. Injuries to runners. *Am J Sports Med* 1978;6:40–50.
6. Rolf C, Movin T. Etiology, histopathology and outcome of surgery in achillodynia. *Foot Ankle Int* 1997;18:565–9.
7. Paavola M, Kannus P, Paakkala T, Pasanen M, Järvinen M. Long-term prognosis of patients with Achilles tendinopathy. *Am J Sports Med* 2000;28:634–42.
8. McLauchlan GJ, Handoll HHG. Interventions for treating acute and chronic Achilles tendinitis. *Cochrane Database Syst Rev* 2001;2: CD000232.
9. Gabel GT. Acute and chronic tendinopathies at the elbow. *Curr Opin Rheumatol* 1999;11:138–43.
10. Åström M, Rausing A. Chronic Achilles tendinopathy. A survey of surgical and histopathologic findings. *Clin Orthop Rel Res* 1995;316:151–64.
11. Movin T, Gad A, Reinholt FP, Rolf C. Tendon pathology in long-standing achillodynia. Biopsy findings in 40 patients. *Acta Orthop Scand* 1997;68:170–5.
12. Hashimoto T, Nobuhara K, Hamada T. Pathologic evidence of degeneration as a primary cause of rotator cuff tear. *Clin Orthop Relat Res* 2003;415:111–20.
13. Khan KM, Maffulli N, Coleman BD, Cook JL, Taunton JE. Patella tendinopathy: some aspects of basic science and clinical management. *Br J Sports Med* 1998;32:346–55.
14. Potter HG, Hannafin JA, Morwessel RM, DiCarlo EF, O'Brien SJ, Altchek DW. Lateral epicondylitis: correlation of MR imaging, surgical, and histopathologic findings. *Radiology* 1995;196:43–6.
15. Maffulli N, Wong J, Almekinders LC. Types and epidemiology of tendinopathy. *Clin Sports Med* 2003;22:675–92.
16. Raatikainen T, Karpakka J, Puranen J, Orava S. Operative treatment of partial rupture of the patellar ligament. A study of 138 cases. *Int J Sports Med* 1994;15:46–9.
17. Khan KM, Cook JL, Bonar F, Harcourt P, Åström M. Histopathology of common tendinopathies. Update and implications for clinical management. *Sports Med* 1999;27:393–408.

18. Roels J, Martens M, Mulier JC, Burssens A. Patella tendinitis (jumper's knee). *Am J Sports Med* 1978;6:362–8.
19. Nichols CE. Patella tendon injuries. *Clin Sports Med* 1992;11:807–13.
20. Maffulli N, Barrass V, Ewen SW. Light microscopic histology of Achilles tendon ruptures. A comparison with unruptured tendons. *Am J Sports Med* 2000;28:857–63.
21. Öhberg L, Lorentzon R, Alfredson H. Neovascularisation in Achilles tendons with painful tendinosis but not in normal tendons: an ultrasound investigation. *Knee Surg Sports Traumatol Arthrosc* 2001;9:233–8.
22. Gisslén K, Alfredson H. Neovascularisation and pain in jumper's knee: a prospective clinical and sonographic study in elite junior volleyball players. *Br J Sports Med* 2005;39:423–8.
23. Taylor PC, Steuer A, Gruber J *et al.* Comparison of ultrasonographic assessment of synovitis and joint vascularity with radiographic evaluation in a randomized, placebo-controlled study of infliximab therapy in early rheumatoid arthritis. *Arthritis Rheum* 2004;50:1107–16.
24. Haywood L, McWilliams DF, Pearson CI *et al.* Inflammation and angiogenesis in osteoarthritis. *Arthritis Rheum* 2003;48:2173–7.
25. Bonnet CS, Walsh DA. Osteoarthritis, angiogenesis and inflammation. *Rheumatology* 2005;44:7–16.
26. Alfredson A, Thorsen K, Lorentzon R. *In situ* microdialysis in tendon tissue: high levels of glutamate, but not prostaglandin E2 in chronic Achilles tendon pain. *Knee Surg Sports Traumatol Arthrosc* 1999;7:378–81.
27. Riley G. The pathogenesis of tendinopathy. A molecular perspective. *Rheumatology* 2004;43:131–42.
28. Movin T, Guntner P, Gad A, Rolf C. Ultrasonography-guided percutaneous core biopsy in Achilles tendon disorder. *Scand J Med Sci Sports* 1997;7:244–8.
29. Khan KM, Bonar F, Desmond PM *et al.* Patella tendinosis (jumper's knee): findings at histopathologic examination, US and MR imaging. *Radiology* 1996;200:821–7.
30. Wang JH, Jia F, Yang G *et al.* Cyclic mechanical stretching of human tendon fibroblasts increases the production of prostaglandin E2 and levels of cyclooxygenase expression: a novel *in vitro* model study. *Connect Tissue Res* 2003;44:128–33.
31. Almekinders LC, Banes AJ, Ballenger CA. 1993. Effects of repetitive motion on human fibroblasts. *Med Sci Sports Exerc* 1993;25:603–7.
32. Li Z, Yang G, Khan M, Stone D, Woo SL, Wang JH. Inflammatory response of human tendon fibroblasts to cyclic mechanical stretching. *Am J Sports Med* 2004;32:435–40.
33. Khan KM, Maffulli N. Tendinopathy: an Achilles' heel for athletes and clinicians. *Clin J Sport Med* 1998;8:151–4.
34. Fredberg U, Bolvig L. Significance of ultrasonically detected asymptomatic tendinosis in the patellar and achilles tendons of elite soccer players. *Am J Sports Med* 2002;30:488–91.
35. Nichol A McP, Burnett S, McCurdie I, Etherington J. Chronic Achilles tendinosis in a currently asymptomatic population. Unpublished study, Defence Medical Rehabilitation Centre, Headley Court, Epsom, Surrey, UK.
36. Sosolowsky LJ, Thomopoulos S, Tun S, *et al.* Neer Award 1999. Overuse activity injuries the supraspinatus tendon in an animal model: a histologic and biomechanical study. *J Shoulder Elbow Surg* 2000;9:79–84.
37. Zamora AJ, Marini JF. Tendon and myo-tendinous junction in an overloaded skeletal muscle of the rat. *Anat Embryol* 1988;179:89–96.
38. Backman C, Boquist L, Friden J, Lorentzon R, Toolanen G. Chronic Achilles paratenonitis with tendinosis: an experimental model in the rabbit. *J Orthop Res* 1990;8:541–7.
39. Archambault JM, Hart DA, Herzog W. Response of rabbit Achilles tendon to chronic repetitive loading. *Connect Tissue Res* 2001;42:13–23.
40. Marr CM, McMillan I, Boyd JS, Wright NG, Murray M. Ultrasonographic and histopathological findings in equine superficial digital flexor tendon injury. *Equine Vet J* 1993;25:23–9.
41. Williams IF, McCullagh KG, Goodship AE, Silver IA. Studies on the pathogenesis of equine tendinosis following collagenase injury. *Res Vet Sci* 1984;36:326–38.
42. Soslowsky LJ, Carpenter JE, DeBano CM, Banerji I, Moalli MR. Development and use of an animal model for investigations on rotator cuff disease. *J Shoulder Elbow Surg* 1996;5:383–92.
43. Stone D, Green C, Rao U *et al.* Cytokine-induced tendinitis: a preliminary study in rabbits. *J Orthop Res* 1999;17:168–77.
44. Sullo A, Maffulli N, Capasso G, Testa V. The effects of prolonged peritendinous administration of PGE1 to the rat Achilles tendon: a possible animal model of chronic Achilles tendinopathy. *J Orthop Sci* 2001;6:349–57.
45. Archambault JM, Banes AJ. Research methodology and animal modelling in tendinopathy. In: Maffulli N, Renström P, Leadbetter WB, ed. *Tendon injuries, basic science and clinical medicine*. London: Springer, 2005:281–2.
46. Maffulli N, Khan KM, Puddu G. Overuse tendon conditions: time to change a confusing terminology. *Arthroscopy* 1998;14:840–3.
47. Puddu G, Ippolito E, Postacchini F. A classification of Achilles tendon disease. *Am J Sports Med* 1976;4:145–50.
48. Khan KM, Cook JL, Kannus P, Maffulli N, Bonar SF. Time to abandon the 'tendinitis' myth. *Br Med J* 2002;324:626–7.
49. Curwin SL. The aetiology and treatment of tendinitis. In: Harries M, Williams C, Stanish WD, Micheli LJ, ed. *Oxford textbook of sports medicine*, 2nd edn. Oxford: Oxford University Press, 1998:610–32.
50. Kirkendall DT, Garrett WE. Function and biomechanics of tendons. *Scand J Med Sci Sports* 1997;7:62–6.
51. Magnusson SP, Hansen P, Aagaard P *et al.* Differential strain patterns of the human gastrocnemius aponeurosis and free tendon, *in vivo*. *Acta Physiol Scand* 2003;177:185–95.
52. Muramatsu T, Muraoka T, Takeshita D, Kawakami Y, Hirano Y, Fukunaga T. Mechanical properties of tendon and aponeurosis of human gastrocnemius muscle *in vivo*. *J Appl Physiol* 2001;90:1671–8.
53. McGough RL, Debski RE, Taskiran E, Fu FH, Woo SL. Mechanical properties of the long head of the biceps tendon. *Knee Surg Sports Traumatol Arthrosc* 1996;3:226–9.
54. Sheehan FT, Drace JE. Human patellar tendon strain. A non-invasive, *in vivo* study. *Clin Orthop Relat Res* 2000;370:201–7.
55. Mosler E, Folkhard W, Knorz E, Nemetschek-Gansler H, Nemetschek T, Koch MH. Stress-induced molecular re-arrangement in tendon collagen. *J Mol Biol* 1985;182:589–96.
56. Wren TA, Lindsey DP, Beaupre GS, Carter DR. Effects of creep and cyclic loading on the mechanical properties and failure of human Achilles tendons. *Ann Biomed Eng* 2003;31:710–17.
57. Barnes GRG, Pinder DN. *In vivo* tendon tension and bone strain measurement and correlation. *J Biomech* 1974;7:35–42.
58. Fenwick SA, Hazleman BL, Riley GP. The vasculature and its role in the damaged and healing tendon. *Arthritis Res* 2002;4:252–60.
59. Ling SC, Chen CF, Wan RX. A study on the vascular supply of the supraspinatus tendon. *Surg Radiol Anat* 1990;12:161–5.
60. Ahmed IM, Lagopoulos M, McConnell P, Soames RW, Sefton GK. Blood supply of the Achilles tendon. *J Orthop Res* 1998;16:591–6.
61. Frey C, Shereff M, Greenidge N. Vascularity of the posterior tibial tendon. *J Bone Joint Surg Am* 1990;72:884–8.
62. Carr AJ, Norris SH. The blood supply of the calcaneal tendon. *J Bone Joint Surg Br* 1989;71:100–1.
63. Langberg H, Bulow J, Kjaer M. Blood in the peritendinous space of the human Achilles tendon during exercise. *Acta Physiol Scand* 1998;163:149–53.
64. Åstrom M, Westlin N. Blood flow in the human Achilles tendon assessed by laser Doppler flowmetry. *J Orthop Res* 1994;12:246–52.
65. Öhberg L, Alfredson H. Effects on neovascularisation behind the good results with eccentric training in chronic mid-portion Achilles tendinosis? *Knee Surg Sports Traumatol Arthrosc* 2004;12:465–70.
66. Birch HL, Wilson AM, Goodship AE. The effects of exercise-induced localised hyperthermia on tendon cell survival. *J Exp Biol* 1997;11:1703–8.

67. Wilson AM, Goodship AE. Exercise-induced hyperthermia as a possible mechanism for tendon degeneration. *J Biomech* 1994; 23:306–12.
68. Józsa L, Balint BJ, Kannus P, Jarvinen M, Lehto M. Mechanoreceptors in human myotendinous junction. *Muscle Nerve* 1993;16:453–57.
69. Hart DA, Frank CB, Bray RC. Inflammatory processes in repetitive motion and overuse syndromes; potential role of neurogenic mechanisms in tendons and ligaments. In: Gordon SL, Blair SJ, Fine LJ, ed. *Repetitive motion disorders of the upper extremity*. Rosemont, IL: American Academy of Orthopaedic Surgeons, 1995:247–62.
70. Andres KH, von Düring M, Schmidt RF. Sensory innervation of the Achilles tendon by group III and IV afferent fibers. *Anat Embryol* 1985;172:145–56.
71. Gotoh M, Hamada K, Yamakawa H, Inoue A, Fukuda H. Increased substance P in subacromial bursa and shoulder pain in rotator cuff diseases. *J Orthop Res* 1998;16:618–21.
72. Garrett NE, Mapp PI, Cruwys SC, Kidd BL, Blake DR. Role of substance P in inflammatory arthritis. *Ann Rheum Dis* 1992; 51:1014–8.
73. Alfredson H, Thorsen K, Lorentzon R. *In situ* microdialysis in tendon tissue: high levels of glutamate, but not prostaglandin E2 in chronic Achilles tendon pain. *Knee Surg Sports Traumatol Arthrosc* 1999;7:378–81.
74. Maffulli N, Irwin AS, Kenward MG, Smith F, Porter RW. Achilles tendon rupture and sciatica: a possible correlation. *Br J Sports Med* 1998;32:174–7.
75. Cook JL, Khan KM, Purdam C. Achilles tendinopathy. *Man Ther* 2002;7:121–30.
76. Maganaris CN, Narici MV, Almekinders LC, Maffulli N. Biomechanical and pathophysiology of overuse tendon injuries: ideas on insertional tendinopathy. *Sports Med* 2004;34:1005–17.
77. Khan KM, Cook JL, Maffulli, Kannus P. Where is the pain coming from in tendinopathy? It may be biochemical, not only structural, in origin. *Br J Sports Med* 2000;34:81–3.
78. Józsa L, Bailint JB, Kannus P, Reffy A, Barzo M. Distribution of blood groups in patients with tendon rupture: an analysis of 832 cases. *J Bone Joint Surg Br* 1989;71:272–4.
79. Kujala UM, Järvinen M, Natri A *et al.* ABO blood groups and musculoskeletal injuries. *Injury* 1992;23:131–3.
80. Collins M, Mokone GG, Gajjar M *et al.* The alpha 1 type V collagen (COL5A1) gene is associated with chronic Achilles tendinopathy. *Med Sci Sports Exerc* 2003;35(Suppl 1):S184.
81. Mokone GG, Gajjar M, September AV *et al.* The guanine-thymine dinucleotide repeat polymorphism within the tenascin-c gene is associated with Achilles tendon injuries. *Am J Sports Med* 2005;33:1016–21.
82. Urist MR, Moss MJ, Adams JM, Jr. Calcification of tendon. A triphasic local mechanism. *Arch Pathol* 1964;77:594–608.
83. Uthoff HK. Calcifying tendinitis, an active cell-mediated calcification. *Virchows Arch A Pathol Anat Histol* 1975;366:51–8.
84. Uthoff HK, Sarkar K, Maynard JA. Calcifying tendinitis: a new concept of its pathogenesis. *Clin Orthop Rel Res* 1976;118:164–8.
85. Evans EJ, Benjamin M, Pemberton DJ. Variation in the amount of calcified tissue at the attachments of the quadriceps tendon and the patella ligament in man. *J Anat* 1991;174:145–51.
86. Benjamin M, Rufai A, Ralphs JR. The mechanism of formation of bony spurs (enthesophytes) in the Achilles tendon. *Arthritis Rheum* 2000;43:576–83.
87. Fenwick S, Harrall R, Hackney R *et al.* Endochondral ossification in Achilles and patella tendinopathy. *Rheumatology* 2002;41:474–6.
88. Hijioka A, Suzuki K, Nakamura T, Hojo T. Degenerative change and rotator cuff tears: an anatomical study in 160 shoulders of 80 cadavers. *Arch Orthop Trauma Surg* 1993;112:61–4.
89. Sher JS, Uribe JW, Posada A, Murphy BJ, Zlatkin MB. Abnormal findings on magnetic resonance images of asymptomatic shoulders. *J Bone Joint Surg Am* 1995;77:10–5.
90. Rees J, Wamuo I, Jan W, Gibson T. Ultrasound evaluation of shoulder pain and restriction in the elderly. *British Society for Rheumatology Annual Meeting*, April 2004;43(Suppl 2):ii73.
91. Mehta S, Gimbel JA, Soslowsky LJ. Etiologic and pathogenic factors for rotator cuff tendinopathy. *Clin Sports Med* 2003; 22:791–812.
92. Codman EA. *The shoulder: rupture of the supraspinatus tendon and other lesions in or about the subacromial bursa*. Boston, MA: Thomas Todd, 1934.
93. Rathbun JB, Macnab I. The microvascular pattern of the rotator cuff. *J Bone Joint Surg Br* 1970;52:540–53.
94. Ling SC, Chen CF, Wan RX. A study on the vascular supply of the supraspinatus tendon. *Surg Radiol Anat* 1990;12:161–5.
95. Brooks CH, Revell WJ, Heatley FW. A quantitative histological study of the vascularity of the rotator cuff tendon. *J Bone Joint Surg Br* 1992;74:151–3.
96. Carr A, Harvie P. Rotator cuff tendinopathy. In: Maffulli N, Renström P, Leadbetter WB, ed. *Tendon injuries*. London: Springer, 2005:101–18.
97. Neer CS. Impingement lesions. *Clin Orthop Rel Res* 1983;173:70–7.
98. Nicholson GP, Goodman DA, Flatow EL, Bigliani LU. The acromion; morphologic condition and age-related changes. A study of 420 scapulas. *J Shoulder Elbow Surg* 1996;5:1–11.
99. Zuckerman JD, Kummer FJ, Cuomo F, Greller M. Interobserver reliability of acromial morphology classification; an anatomic study. *J Shoulder Elbow Surg* 1997;6:286–7.
100. Wang JC, Shapiro MS. Changes in acromial morphology with age. *J Shoulder Elbow Surg* 1997;6:55–9.
101. Luo ZP, Hsu HC, Grabowski JJ, Morrey BF, An KN. Mechanical environment associated with rotator cuff tears. *J Shoulder Elbow Surg* 1998;7:616–20.
102. Perry J. Anatomy and biomechanics of the hindfoot. *Clin Orthop Relat Res* 1983;177:9–15.
103. Scott SH, Winter DA. Internal forces of chronic running injury sites. *Med Sci Sports Exerc* 1990;22:357–69.
104. Komi PV, Fukashiro S, Jarvinen M. Biomechanical loading of Achilles tendon during normal locomotion. *Clin Sports Med* 1992;11:521–31.
105. Komi PV, Hyvarinen T, Gollhofer A, Kvist M. Biomechanical considerations of impact forces and foot stability in running. *Sportverletzung Sportschaden* 1993;7:179–82.
106. Kvist M. Achilles tendon injuries in athletes. *Sports Med* 1994; 18:173–201.
107. McGarvey WC, Singh D, Trevino SG. Partial Achilles tendon ruptures associated with fluoroquinolone antibiotics: a case report and literature review. *Foot Ankle Int* 1996;17:496–8.
108. van der Linden PD, Sturkenboom MC, Herings RM, Leufkens HM, Rowlands S, Stricker BH. Increased risk of Achilles tendon rupture with quinolone antibacterial use, especially in elderly patients taking oral corticosteroids. *Arch Intern Med* 2003;163:1801–7.
109. Funk DA, Cass JR, Johnson KA. Acquired flat foot secondary to posterior tibial tendon pathology. *J Bone Joint Surg Am* 1986;68:95–102.
110. Jahss MH. Spontaneous rupture of the tibialis posterior tendon; clinical findings, tenographic studies, and a new technique of repair. *Foot Ankle* 1982;3:158–66.
111. Mann RA, Thompson FM. Rupture of the posterior tibial tendon causing flat foot. *J Bone Joint Surg Am* 1985;67:556–61.
112. Kohls-Gatzoulis J, Angel JC, Singh D, Haddad F, Livingstone J, Berry G. Tibialis posterior dysfunction: a common and treatable cause of adult acquired flatfoot. *Br Med J* 2004;329:1328–33.
113. Ferretti A. Epidemiology of jumper's knee. *Sports Med* 1986; 3:289–95.
114. Ferretti A, Puddu G, Mariani PP, Neri M. The natural history of jumper's knee. Patella or quadriceps tendonitis. *Int Orthop* 1985;8:239–42.
115. Khan KM, Cook JL, Maffulli N. Patella tendinopathy and patellar tendon rupture. In: Maffulli N, Renström P, Leadbetter WB, ed.

- Tendon injuries: basic science and clinical medicine. London: Springer, 2005:166–77.
116. Johnson DP, Wakeley CJ, Watt I. Magnetic resonance imaging of patellar tendonitis. *J Bone Joint Surg Br* 1996;78:452–7.
 117. Schmid MR, Hodler J, Cathrein P, Duester S, Jacob HA, Romero J. Is impingement the cause of jumper's knee? Dynamic and static magnetic resonance imaging of patellar tendonitis in an open-configuration system. *Am J Sports Med* 2002;30:388–95.
 118. Hamilton B, Purdam C. Patella tendinosis as an adaptive process: a new hypothesis. *Br J Sports Med* 2004;38:758–61.
 119. Zernicke RF, Garhammer J, Jobe FW. Human patella-tendon rupture. *J Bone Joint Surg Am* 1977;59:179–83.
 120. Almekinders LC, Temple JD. Etiology, diagnosis, and treatment of tendonitis: an analysis of the literature. *Med Sci Sports Exerc* 1998;30:1183–90.
 121. Weiler JM. Medical modifiers of sports injury. The use of nonsteroidal anti-inflammatory drugs (NSAIDs) in sports soft tissue injury. *Clin Sports Med* 1992;11:625–44.
 122. Vogel HG. Mechanical and chemical properties of various connective tissue organs in rats as influenced by non-steroidal antirheumatic drugs. *Connect Tissue Res* 1977;5:91–5.
 123. Carlstedt CA, Madsen K, Wredmark T. The influence of indomethacin on biomechanical and biochemical properties of the plantaris longus tendon in the rabbit. *Arch Orthop Trauma Surg* 1987;106:157–60.
 124. Forslund C, Bylander B, Aspenberg P. Indomethacin and celecoxib improve tendon healing in rats. *Acta Orthop Scand* 2003;74:465–9.
 125. Kulick MI, Smith S, Hadler K. Oral ibuprofen: evaluation of its effect on peritendinous adhesions and the breaking strength of a tenorrhaphy. *J Hand Surg Am* 1986;11:110–20.
 126. Canoso JJ. Aspiration and injection of joints and periarticular tissues. In: Hochberg MC, Silman AJ, Smolen J, Weinblatt ME, Weisman MH, ed. *Rheumatology*, 3rd edn. Edinburgh: Mosby, 2003:235.
 127. Buchbinder R, Green S, Youd JM. Corticosteroid injections for shoulder pain. *Cochrane Database Syst Rev* 2003;1:CD004016.
 128. Assendelft WJ, Hay EM, Adshear R, Boulter LM. Corticosteroid injections for lateral epicondylitis: a systemic review. *Br J Gen Pract* 1996;46:209–16.
 129. Hay EM, Paterson SM, Lewis M, Hosie G, Croft P. Pragmatic randomised controlled trial of local corticosteroid injection and naproxen for treatment of lateral epicondylitis in primary care. *Br Med J* 1999;319:964–8.
 130. Stahl S, Kaufman T. The efficacy of an injection of steroids in medial epicondylitis. *J Bone Joint Surg Am* 1997;79:1648–52.
 131. Kleinman M, Gross AE. Achilles tendon rupture following steroid injection: report of three cases. *J Bone Joint Surg Am* 1983;65:1345–7.
 132. Ford LT, DeBender J. Tendon rupture after local steroid injection. *South Med J* 1979;72:827–30.
 133. Kapetanios G. The effect of the local corticosteroids on the healing and biomechanical properties of the partially injured tendon. *Clin Orthop Relat Res* 1982;163:170–9.
 134. Matthews LS, Sonstegard DA, Phelps DB. A biomechanical study of rabbit tendon; effects of steroid injection. *J Sports Med* 1974;2:349–57.
 135. Fredberg U. Local corticosteroid injection in sport; review of the literature and guidelines for treatment. *Scan J Med Sci Sports* 1997;7:131–9.
 136. Speed CA. Fortnightly review; corticosteroid injections in tendon lesions. *Br Med J* 2001;323:382–6.
 137. Shrier I, Matheson GO, Kohl HW. Achilles tendonitis: are corticosteroid injections useful or harmful? *Clin J Sports Med* 1996;6:245–50.
 138. Rivenburgh DW. Physical modalities in the treatment of tendon injuries. *Clin Sports Med* 1992;11:645–9.
 139. Speed C. Therapeutic modalities. In: Hazleman B, Riley G, Speed C, ed. *Soft tissue rheumatology*. Oxford: Oxford University Press, 2004:259–65.
 140. Speed CA. Therapeutic ultrasound in soft tissue lesions. *Rheumatology* 2001;40:1331–6.
 141. Van der Windt DA, van der Heijden GJ, van der Berg SG, ter Riet G, de Winter AF, Boulter LM. Ultrasound therapy for musculoskeletal disorders: a systematic review. *Pain* 1999;81:257–71.
 142. Robertson VJ, Baker KG. A review of therapeutic ultrasound; effectiveness studies. *Phys Ther* 201;81:1339–50.
 143. Basford JR. Low intensity laser therapy: still not an established clinical tool. *Lasers Surg Med* 1995;16:331–42.
 144. Brosseau L, Casimiro L, Milne S *et al.* Deep transverse friction massage for treating tendonitis. *Cochrane Database Syst Rev* 2002;4:CD003528.
 145. Lowdon A, Bader DL, Mowat AG. The effect of heel pads on the treatment of Achilles tendonitis; a double blind trial. *Am J Sports Med* 1984;12:431–5.
 146. Struijs PA, Smidt N, Arola H, Dijk CN, Buchbinder R, Assendelft WJ. Orthotic devices for the treatment of tennis elbow. *Cochrane Database Syst Rev* 2002;1:CD001821.
 147. Chao W, Wapner KL, Lee TH, Adams J, Hecht PJ. Nonoperative management of posterior tibial tendon dysfunction. *Foot Ankle Int* 1997;18:457–8.
 148. Nirschl RP. The etiology and treatment of tennis elbow. *J Sports Med* 1974;2:308–23.
 149. Stanish WD, Rubinovich RM, Curwin S. Eccentric exercise in chronic tendonitis. *Clin Orthop Relat Res* 1986;208:65–8.
 150. Alfredson H, Pietilä T, Jonsson P, Lorentzon R. Heavy-load eccentric calf muscle training for the treatment of chronic Achilles tendonitis. *Am J Sports Med* 1998;26:360–6.
 151. Mafi N, Lorentzon R, Alfredson H. Superior short-term results with eccentric calf muscle training compared to concentric training in a randomized prospective multicenter study on patients with chronic Achilles tendonitis. *Knee Surg Sports Traumatol Arthrosc* 2001;9:42–7.
 152. Silbernagel KG, Thomeé R, Thomeé P, Karlsson J. Eccentric overload training for patients with chronic Achilles tendon pain – a randomised controlled study with reliability testing of the evaluation methods. *Scand J Med Sci Sports* 2001;11:197–206.
 153. Öhberg L, Lorentzon R, Alfredson H. Eccentric training in patients with chronic Achilles tendonitis: normalised tendon structure and decreased thickness at follow up. *Br J Sports Med* 2004;38:8–11.
 154. Cannell LJ, Taunton JE, Clement DB, Smith C, Khan KM. A randomised clinical trial of the efficacy of drop squats or leg extension/leg curl exercises to treat clinically diagnosed jumper's knee in athletes; pilot study. *Br J Sports Med* 2001;35:60–4.
 155. Purdam CR, Johnsson P, Alfredson H, Lorentzon R, Cook JL, Khan KM. A pilot study of the eccentric decline squat in the management of painful chronic patella tendonopathy. *Br J Sports Med* 2004;34:395–7.
 156. Young MA, Cook JL, Purdham CR, Kiss ZS, Alfredson H. Eccentric decline squat protocol offers superior results at 12 months compared with traditional eccentric protocol for patella tendonopathy in volleyball players. *Br J Sports Med* 2005;39:102–5.
 157. Jonsson P, Wahlström P, Öhberg L, Alfredson H. Eccentric training in chronic painful impingement syndrome of the shoulder; results of a pilot study. *Knee Surg Sports Traumatol Arthrosc* 2006;14:76–81.
 158. Gerdemeyer L, Wagenpfeil S, Haake M *et al.* Extracorporeal shock wave therapy for the treatment of chronic calcifying tendonitis of the rotator cuff. *J Am Med Assoc* 2003;290:2573–80.
 159. Loew M, Daecke W, Kusnierczak D, Rahmanzadeh M, Ewerbeck V. Shock-wave therapy is effective for chronic calcifying tendonitis of the shoulder. *J Bone Joint Surg Br* 1999;81:863–7.
 160. Wang CJ, Yang KD, Wang FS *et al.* Shock wave therapy for calcific tendonitis of the shoulder. *Am J Sports Med* 2003;31:425–30.
 161. Sabeti-Aschraf M, Dorotka R, Goll A, Trieb K. Extracorporeal shock wave therapy in the treatment of calcific tendonitis of the rotator cuff. *Am J Sports Med* 2005;33:1365–8.

162. Ogden JA, Alvarez R, Levitt R, Cross GL, Marlow M. Shock wave therapy for chronic proximal plantar fasciitis. *Clin Orthop Relat Res* 2002;398:267–8.
163. Buchbinder R, Assendelft WJJ, Barnsley L *et al.* Shock wave therapy for lateral elbow pain. *Cochrane Database Syst Rev* 2002;1: CD003524.
164. Speed CA, Richards C, Nichols D *et al.* Extracorporeal shock-wave therapy for tendonitis of the rotator cuff. A double-blind, randomised controlled trial. *J Bone Joint Surg Br* 2002;84:509–12.
165. Schmitt J, Haake M, Tosch A, Hildebrand R, Deike B, Griss P. Low-energy extracorporeal shock-wave treatment (ESWT) for tendinitis of the supraspinatus a prospective randomised study. *J Bone Joint Surg Br* 2002;84:619–20.
166. Williams IF, Nicholls JS, Goodship AE, Silver IA. Experimental treatment of tendon injury with heparin. *Br J Plast Surg* 1986; 39:367–72.
167. Tatari H, Kosay C, Baran O, Ozcan O, Ozer E, Ulukus C. Effect of heparin on tendon degeneration: an experimental study on rats. *Knee Surg Sports Traumatol Arthrosc* 2001;9:247–53.
168. Topol GA, Reeves KD, Hassanein KM. Efficacy of dextrose prolotherapy in elite male kicking sport athletes with chronic groin pain. *Arch Phys Med Rehab* 2005;86:697–702.
169. Reeves KD. Sweet relief. *Biomechanics* 2004;9:25–33.
170. British National Formulary 2005:2.11.
171. Aprotinin (Trasylol) product information sheet. West Haven, CT: Bayer Health Care, 2003.
172. Capasso G, Maffulli N, Testa V, Sgambato A. Preliminary results with peritendinous protease inhibitor injections in the management of Achilles tendinitis. *J Sports Traumatol Rel Res* 1993;15:37–43.
173. Capasso G, Testa V, Maffulli N *et al.* Aprotinin, corticosteroids and normosaline in the management of patellar tendinopathy in athletes; a prospective randomized study. *Sports Exerc Inj* 1997;3:111–5.
174. Edwards SG, Calandruccio JH. Autologous blood injections for refractory lateral epicondylitis. *J Hand Surg* 2003;28:272–8.
175. Alfredson H, Ohberg L, Forsgren S. Is vasculo-neural ingrowth the cause of pain in chronic Achilles tendinosis? An investigation using ultrasonography and colour Doppler, immunohistochemistry, and diagnostic injections. *Knee Surg Sports Traumatol Arthrosc* 2003;5:334–8.
176. Ohberg L, Alfredson H. Ultrasound guided sclerosis of neovessels in painful chronic Achilles tendinosis: pilot study of a new treatment. *Br J Sports Med* 2002;36:173–5.
177. Ohberg L, Alfredson H. Sclerosing therapy in chronic Achilles tendon insertional pain-results of a pilot study. *Knee Surg Sports Traumatol Arthrosc* 2003;11:339–43.
178. Paoloni JA, Appleyard RC, Nelson J, Murrell AC. Topical glyceryl trinitrate treatment of chronic noninsertional Achilles tendinopathy. A randomised, double-blind, placebo-controlled trial. *J Bone Joint Surg Am* 2004;86:916–22.
179. Paoloni JA, Appleyard RC, Nelson J, Murrell GA. Topical glyceryl trinitrate application in the treatment of chronic supraspinatus tendinopathy: a randomized, double-blinded, placebo-controlled clinical trial. *Am J Sports Med* 2005;33:806–13.
180. Paoloni JA, Appleyard RC, Nelson J, Murrell GA. Topical nitric oxide application in the treatment of chronic extensor tendinosis at the elbow: a randomized, double-blinded, placebo-controlled clinical trial. *Am J Sports Med* 2003;31:915–20.
181. Sundqvist H, Forsskahl B, Kvist M. A promising novel therapy for Achilles peritendinitis: double-blind comparison of glycosaminoglycan polysulfate and high-dose Indomethacin. *Int J Sports Med* 1987;8:298–303.
182. Marr CM, Love S, Boyd JS, McKellar Q. Factors affecting the clinical outcome of injuries to the superficial digital flexor tendon in National Hunt and point-to-point racehorses. *Vet Rec* 1993;132:539.
183. Dow SM, Wilson AM, Goodship AE. Treatment of acute superficial digital flexor tendon injury in horses with polysulphated glycosaminoglycan. *Vet Rec* 1996;139:413–6.
184. Young RG, Butler DL, Weber W, Caplan AI, Gordon SL, Fink DJ. Use of mesenchymal stem cells in a collagen matrix for Achilles tendon repair. *Orthop Res* 1998;16:406–13.
185. Smith RK, Korda M, Blunn GW, Goodship AE. Isolation and implantation of autologous equine mesenchymal stem cells from bone marrow into the superficial digital flexor tendon as a potential novel treatment. *Equine Vet J* 2003;35:99–102.
186. Smith RKW, Webbon PM. Harnessing the stem cell for the treatment of tendon injuries; heralding a new dawn? *Br J Sports Med* 2005;39:582–4.
187. Bestwick CS, Maffulli N. Reactive oxygen species and tendinopathy: do they matter? *Br J Sports Med* 2004;38:672–4.
188. Yuan J, Murrell GA, Trickett A, Landtmeters M, Knoops B, Wang MX. Overexpression of antioxidant enzyme peroxiredoxin 5 protects human tendon cells against apoptosis and loss of cellular function during oxidative stress. *Biochim Biophys Acta* 2004;1693:37–45.
189. Lin J, Wang MX, Wei A, Zhu W, Murrell GA. The cell specific temporal expression of nitric oxide synthase isoforms during Achilles tendon healing. *Inflamm Res* 2001;50:515–22.
190. Rodeo SA. What's new in orthopaedic research. *J Bone Joint Surg Am* 2003;85:2054–62.
191. Hannallah D, Peterson B, Lieberman JR, Fu FH, Huard J. Gene therapy in orthopaedic surgery. *J Bone Joint Surg Am* 2002;84:1046–61.
192. Yuan J, Wang MX, Murrell GA. Cell death and tendinopathy. *Clin Sports Med* 2003;22:693–701.
193. Litchwark GA, Wilson AM. *In vivo* mechanical properties of the human Achilles tendon during one legged hopping. *J Expir Biol* 2005;208:4713–23.
194. Maganaris CN, Narici MV, Reeves ND. *In vivo* human tendon mechanical properties: effect of resistance training in old age. *J Musculoskelet Neuronal Interact* 2004;4:204–8.