

# UC San Diego

## Independent Study Projects

### Title

Current management of succinate dehydrogenase deficient gastrointestinal stromal tumors

### Permalink

<https://escholarship.org/uc/item/1n04t463>

### Authors

Neppala, Pushpa  
Banerjee, Sudeep  
Fanta, Paul T.  
et al.

### Publication Date

2019

**Title:**

Current Management of Succinate Dehydrogenase Deficient Gastrointestinal Stromal Tumors

**Authors:**

Pushpa Neppala<sup>1</sup>, Sudeep Banerjee<sup>2,3</sup>, Paul T. Fanta<sup>4,5</sup>, Mayra Yerba<sup>2</sup>, Kevin A. Porras<sup>1</sup>, Adam M. Burgoyne<sup>5</sup>, Jason K. Sicklick<sup>2,4</sup>

**Affiliations:**

<sup>1</sup> UC San Diego School of Medicine, University of California, San Diego, La Jolla, California

<sup>2</sup> Division of Surgical Oncology, Department of Surgery, UC San Diego Moores Cancer Center, University of California, San Diego, La Jolla, California

<sup>3</sup> Department of Surgery, David Geffen School of Medicine at UCLA, Los Angeles, California

<sup>4</sup> Center for Personalized Cancer Therapy, UC San Diego Moores Cancer Center, University of California, San Diego, La Jolla, California

<sup>5</sup> Division of Hematology-Oncology, Department of Medicine, UC San Diego Moores Cancer Center, University of California, San Diego, La Jolla, California

**Corresponding Authors:**

Jason K. Sicklick, MD, Division of Surgical Oncology, Department of Surgery, UC San Diego Moores Cancer Center, University of California, San Diego, 3855 Health Sciences Drive, MC 0987, La Jolla, CA 92093-0987; Tel: 858-822-6173; Fax: 858-228-5153; Email: [jsicklick@ucsd.edu](mailto:jsicklick@ucsd.edu)

Adam M. Burgoyne, MD, PhD, Division of Hematology-Oncology, Department of Medicine, UC San Diego Moores Cancer Center, University of California, San Diego, 3855 Health Sciences Drive, MC 0987, La Jolla, CA 92093-0987; Tel: 858-246-0674; Fax: (858) 246-0284

Email: [aburgoyne@ucsd.edu](mailto:aburgoyne@ucsd.edu)

**Financial Support:**

This work was supported by the Society for Surgery of the Alimentary Tract (SSAT) Mentored Research Award (S.B), UC San Diego GIST Research Fund (J.K.S.), NIH K08CA168999 (J.K.S.) and NIH R21CA192072 (J.K.S.).

**Conflict of Interest:**

Jason Sicklick receives research funds from Foundation Medicine Inc., Amgen Pharmaceuticals and Novartis Pharmaceuticals, as well as consultant fees from Loxo, and Grand Rounds. Adam Burgoyne receives consultant fees from Exelixis and Eisai. All other authors have no relationships to disclose.

**Contributors:**

Pushpa Neppala: Study design, data analysis, article drafting, and critical review of the manuscript.

Sudeep Banerjee: Data analysis, article drafting, and critical review of the manuscript.

Paul T. Fanta: Critical review of the manuscript.

Mayra Yerba: Data analysis, article drafting, and critical review of the manuscript.

Kevin A. Porras: Article drafting.

Adam M. Burgoyne: Data analysis, article drafting, and critical review of the manuscript.

Jason K. Sicklick: Study design, data analysis, article drafting, and critical review of the manuscript.

All authors have approved the final article.

**Keywords:** Gastrointestinal stromal tumors, GIST, succinate dehydrogenase, tyrosine kinase inhibitors, SDH

**ABSTRACT**

Gastrointestinal stromal tumors (GIST) are increasingly recognized as having diverse biology. With the development of tyrosine kinase inhibitors molecularly matched to oncogenic *KIT* and *PDGFRA* mutations, GIST have become a quintessential model for precision oncology. However, about 5-10% of GIST lack these driver mutations and are deficient in succinate dehydrogenase (SDH), an enzyme that converts succinate to fumarate. SDH deficiency leads to accumulation of succinate, an oncometabolite that promotes tumorigenesis. SDH-deficient GIST are clinically unique in that they generally affect younger patients and are associated with GIST-paraganglioma hereditary syndrome, also known as Carney-Stratakis Syndrome. SDH-deficient GIST are generally resistant to tyrosine-kinase inhibitors, the standard treatment for advanced or metastatic GIST. Thus, surgical resection is the mainstay of treatment for localized disease, but recurrence is common. Clinical trials are currently underway investigating systemic agents for treatment of advanced SDH-deficient GIST. However, further studies are warranted to improve our understanding of SDH-deficient GIST disease biology, natural history, surgical approaches, and novel therapeutics.

## INTRODUCTION

Gastrointestinal stromal tumor (GIST) is the most common sarcoma, affecting 6.8 per million people annually in the United States [1]. GIST arise from interstitial cells of Cajal, which are pacemaker cells in the gut that control the slow wave of smooth muscle contraction [2]. GIST can arise anywhere in the gastrointestinal tract but occur most often in the stomach and small bowel [3-5]. They also can have histopathologic heterogeneity ranging from spindleoid to epithelioid to mixed histologies [6-8]. Moreover, GIST are driven by a variety of oncogenic driver or loss of function mutations making them molecularly diverse [3, 4].

Before the advent of targeted cancer therapies, the prognosis for GIST was poor given their resistance to conventional chemotherapy and radiation [9]. In 1998, gain of function mutations in *KIT* were identified. These mutations activate the receptor tyrosine kinase c-KIT via ligand-independent receptor dimerization, which promotes downstream signaling. This leads to unchecked tumor cell growth and survival [10]. We now know that 70-80% of GIST have mutations in *KIT* or another receptor tyrosine kinase, *PDGFRA* [11, 12]. Tyrosine kinase inhibitors such as imatinib target mutations in *KIT* and *PDGFRA* and are the mainstay of treatment. Subsequently, GIST has become an important proof-of-principle model for precision therapy in cancer patients [9, 13].

Further studies of the molecular biology of GIST have identified additional GIST subsets caused by mutations of *K/H/N-RAS*, *BRAF*, and *NF1*, as well as gene fusions of *FGFR1* and *ETV6-NTRK3* [12, 14-17]. Additionally, another 5-10% of GIST have mutations in succinate dehydrogenase (SDH) subunits [18, 19]. Mutations in SDH subunits have been linked to a number of cancers. More importantly, they were first linked to GIST in the setting of hereditary GIST-paraganglioma syndrome, also known as Carney-Stratakis syndrome [20].

## CLINICAL AND PATHOLOGIC FEATURES OF SDH-DEFICIENT GIST

The median age of diagnosis of GIST is 64 years old, but SDH-deficient GIST usually first appear in children, adolescents, and young adults [1]. However, patients in their 40s to late 50s also can present with an initial diagnosis of SDH-deficient GIST (Sicklick, unpublished data). Over 80% of pediatric GIST have inactivating mutations in SDH subunits [20-22]. Females are reported to be disproportionately affected [18]. However, in our practice of young adults with GIST, we have observed a higher proportion of male patients with SDH mutations (Fanta, Burgoyne, and Sicklick, unpublished data).

SDH-deficient GIST generally arise in the stomach. The clinical presentation is often non-specific, which leads to a delay in diagnosis. Many patients with GISTs are diagnosed after presenting with severe epigastric pain or gastrointestinal bleeding due to ulceration [19, 23]. This is consistent with the indolent biology of these tumors. In fact, many patients present with gastric recurrences and lymph node metastases later in life, a phenomenon that is less common in SDH-competent GIST. Recurrence often leads to repeat partial gastrectomy [19, 24]. Histology often shows epithelial hypercellularity and lymphovascular invasion, as well as multifocality, which is also rarer in *KIT/PDGFRA*-mutated GIST. Thus, the natural history and biology of these tumors seem distinct from their oncogene-driven counterparts.

## SDH LOSS IN TUMORIGENESIS

The SDH complex is a component of complex II in the Krebs cycle, a process that connects glycolysis in the cytoplasm to oxidative phosphorylation in the mitochondria (**Figure 1**). This complex resides in the inner mitochondrial membrane and has four subunits, encoded by the *SDHA*, *SDHB*, *SDHC*, and *SDHD* genes. In mammalian mitochondria, *SDHA* forms the catalytic core, while *SDHB* forms an iron sulphur protein, and *SDHC/SDHD* are integral membrane proteins (**Figure 2**) [25, 26].

The SDH complex is involved in the conversion of succinate to fumarate during cellular respiration. Tumors with inactivating mutations in *SDHx* genes lack a functional SDH complex, losing the ability to convert succinate to fumarate. Thus, they are considered to be SDH-deficient. In 1977, SDH deficiency was first described in a mutant Chinese hamster fibroblast cell line [27]. Lack of SDH in this system resulted in a defect of oxidative phosphorylation, as well increased cellular reliance on glycolysis for energy metabolism. Twenty-three years later, *SDHx* mutations were first linked to cancer in 2000 when germline mutations in *SDHD* were reported in hereditary paraganglioma [28]. Since that time, *SDHx* mutations have been implicated in a number of tumor

types including carcinomas (i.e., renal cell, thyroid) and other neuroendocrine tumors (i.e., neuroblastoma, paraganglioma, pheochromocytoma) [29-32], as well as GIST.

Knockdown of *SDHB* in mouse ovarian cancer cells leads to increased proliferation and epithelial-to-mesenchymal transition. This occurs through transcriptional upregulation of genes involved in hypermethylation and downregulation of genes involved in oxidative phosphorylation. Loss of *SDHB* also causes increased utilization of glucose in the pentose phosphate pathway (PPP) and glutamine in the Krebs cycle [33].

Mutations in *SDHx* result in an accumulation of succinate. Similarly, deficiency of fumarate hydratase (FH) results in an accumulation of fumarate. Both succinate and fumarate have been implicated as oncometabolites, a term used to describe how these metabolites dysregulate oxygen-dependent signaling in the tumor microenvironment [34-36]. Under normoxic conditions, hypoxia-inducible factor 1 $\alpha$  (HIF1 $\alpha$ ) is hydroxylated by prolyl hydroxylase domain (PHD) proteins, via an oxygen-dependent reaction that converts  $\alpha$ -ketoglutarate ( $\alpha$ -KG) to succinate, which in turn targets HIF1 $\alpha$  for proteasome-mediated degradation. In hypoxic conditions such as those within a tumor environment, HIF1 $\alpha$  accumulates and translocates into the nucleus where it complexes with HIF1 $\beta$  to promote the transcription of genes involved in angiogenesis, proliferation, and glycolysis [37]. However, deficiency of either *SDH* or *FH* leads to the accumulation of succinate or fumarate, respectively, inhibiting PHDs and leading to the stabilization and accumulation of HIF1 $\alpha$  in normoxic conditions [37][38]. Such HIF1 $\alpha$  activation under normoxic conditions is termed pseudohypoxia. In this setting, HIF1 $\alpha$  activation supports increased angiogenesis and glycolysis, processes that enhance tumor growth. Furthermore, the exogenous administration of  $\alpha$ -KG allows PHDs to overcome inhibition by succinate in *SDH*-deficient tumor cells through a concentration-dependent manner [39]. This suggests  $\alpha$ -KG may be a potential therapeutic target in *SDH*-deficient GIST.

## GENETIC MUTATIONS IN SDH-DEFICIENCY

### ***Mutations in SDHA***

*SDHA* is the most common mutation leading to *SDH*-deficient GIST, occurring in up to 30% of cases [40]. Loss of function mutations of *SDHA* were first identified in an isolated case of abdominal paraganglioma [41]. In 2011, sequencing of sporadic non-*KIT/PDGFR*A-mutated GIST revealed germline mutations in *SDHA* [42]. Miettinen and colleagues further classified these *SDHA* germline mutations using immunohistochemistry. Tumors with *SDHA* mutations were found to be devoid of mutations in the other *SDH* subunits. However, these tumors were *SDHB*-deficient on immunohistochemistry, making this a reliable tool for identifying *SDHA*-mutant GISTs. Patients with *SDHA*-mutant tumors tend to have an older median age (34 years old) versus *SDH*-deficient GIST from other subunit mutations (21 years old) [40].

With the increased use of molecular testing and next generation sequencing (NGS), many *SDHA* variants of unknown significance (VUS) have been identified. In 2017, Bannon and colleagues reported the creation of a yeast model to determine the functional significance of 22 of these variants on mitochondrial function. Their screen identified pathogenic VUS sequences that resulted in decreased expression of *SDH* and defective oxidative phosphorylation. They determined that 16 (73%) of the alterations are actually pathogenic resulting in loss of *SDH* function. The remaining six (27%) have no effect on *SDH* function [43]. Thus, we continue to learn about the functional significance and previous underappreciation of these alterations.

### ***Mutations in SDHB, C, and D subunits***

Defects of other *SDHx* genes in non-*KIT/PDGFR*A mutated GIST were first reported in 2011 by Janeway and colleagues. This group demonstrated germline mutations in *SDHB* and *SDHC* lead to deficient *SDHB* expression, while most *KIT*-mutated GIST have conserved expression of *SDHB* protein [18]. Germline mutations in *SDHB*, *SDHC*, and *SDHD* occur in only 20-30% of *SDH*-deficient GIST [24]. Currently, *SDHB* immunohistochemistry is used to identify all *SDH*-deficient GIST.

### ***Epigenetic mutations in SDHC***

Almost 50% of *SDH*-deficient GIST lack mutations in the genomic sequencing of *SDHx* subunits. However, DNA methylation analyses of *SDH*-deficient GIST have revealed hypermethylation of the *SDHC* promoter sequence. The frequency of *SDHC* hypermethylation in non-*KIT/PDGFR*A-mutated GIST appears to be similar to that of

coding mutations in *SDHx* subunit sequences. There are no reported simultaneous cases of *SDHC* genomic mutation and hypermethylation [44].

Epigenetic mutations in *SDHx* are also seen in the Carney Triad, a GIST syndrome in young females notable for development of gastric GIST, pulmonary chondroma, and paraganglioma [45]. The features of concurrent GIST and paragangliomas, as well as loss of SDHB in immunohistochemistry are shared with Carney-Stratakis Syndrome. However, no germline mutations in *SDHx* have been identified in Carney Triad patients, suggesting that it is not a heritable condition. Tumors in these patients exhibit hypermethylation of the *SDHC* promoter sequence, leading to loss of SDHC protein expression and functional SDH deficiency [46, 47]. The identification of this hypermethylation phenomenon raises the hypothesis that demethylating agents may have therapeutic potential in SDH-deficient GIST.

### **SURGICAL MANGEMENT OF SDH DEFICIENT GISTS**

Surgical resection continues to be a mainstay of treatment for all GIST [48]. Generally, surgical resection of primary tumors is considered when the tumor is bleeding, causing obstruction, larger than 2 cm, or is increasing in size [49]. Resection of primary tumor with negative margins is achieved in 85% of patients, but recurrence or progression within 5 years is common. This suggests that surgical resection alone is not adequate for curative treatment of GIST [50]. Currently, guidelines do not exist for surgical management of GIST based on genetic mutations.

Only recently has the population of pediatric GIST patients been identified as a group of patients with genetically-distinct tumors that likely require unique treatment approaches. The majority of pediatric patients have non-*KIT/PDGFR*A-mutated GIST [51]. Most treatments for pediatric GIST take place in the context of clinical trials and tertiary care centers [52]. Surgical resection is aimed at an organ-sparing resection of primary tumor. Given the increased incidence of lymph node metastases in non-*KIT/PDGFR*A-mutated GISTs, sampling of draining lymph node basins is recommended [22]. Close follow up after surgery is also necessary due to high recurrence rates [52].

A retrospective study of young adult and adolescents with GIST in the SEER database showed that this population was more likely to receive surgical treatment. Young adults and adolescents had improved overall survival, as well as GIST-specific survival following surgical resection. In the same study, it was found that GIST located in the stomach had poorer outcomes than those found in small intestine [53]. It is noteworthy that SDH-deficient GIST are primarily found in the stomach. However, this study did not include stratification by genetic mutations limiting its application to the treatment for SDH-deficient GIST.

In 2017, the results of a retrospective analysis from the NIH Pediatric and Wild-type GIST clinic were reported [54]. This study was the first to evaluate surgical management of exclusively non-*KIT/PDGFR*A mutated GISTs. Analysis of 76 patients who underwent surgery found median event-free survival (EFS) to be 2.5 years with 71% of patients experiencing tumor recurrence or disease progression. The EFS was negatively affected by an elevated mitotic index and by the presence of metastases. Interestingly, negative resection margins and neoadjuvant or adjuvant treatment did not appear to affect EFS. SDH-deficient and SDH-competent tumors were only stratified for the outcome of EFS in a limited number of patients, with other variables such as metastases not being evaluated. Taken together, the results suggest that surgical resection of non-*KIT/PDGFR*A-mutated tumors may not be of benefit to some patients. However, given the inherent limitations of retrospective analysis, it is difficult to make any definitive recommendations for the surgical management of SDH-deficient GIST from the available data. But, with all surgical decision making, the morbidities should be weighed against the benefits of resection on an individualized basis.

### **MEDICAL MANAGEMENT OF SDH DEFICIENT GIST**

#### ***Use of tyrosine kinase inhibitors***

The tyrosine kinase inhibitor (TKI) imatinib is used as adjuvant therapy after surgical resection in high risk patients treated with curative intent and as first-line systemic therapy for metastatic patients [48, 55]. Although imatinib is very effective in treating *KIT/PDGFR*A-mutant GISTs, SDH-deficient GIST are largely resistant to TKIs due to the absence of gain-of-function tyrosine kinase mutations [18, 56]. Sunitinib is a TKI approved for the treatment of imatinib-resistant GIST [57]. Sunitinib inhibits the ATP-binding domains of KIT and PDGFR, a

property shared with imatinib. Unlike imatinib, sunitinib also inhibits VEGFR, which leads to blockade of angiogenesis. Sunitinib has been shown to increase progression-free and overall survival in advanced non-*KIT/PDGFR*A-mutated GIST after imatinib failure, possibly due to these added anti-angiogenic properties [58]. Unfortunately, primary and secondary resistance to sunitinib develops in almost all GIST patients with a median of 24 months after initiation of first-line treatment and 6-9 months after second-line treatment. The TKI regorafenib is approved for treatment of GIST after failure of imatinib and sunitinib. In a phase II study of third-line regorafenib, 2 out of 6 patients with SDH-deficient GIST had a partial response [59]. In a 2014 phase II study of another TKI targeting VEGFR, pazopanib, the authors describe a patient with SDH-deficient GIST who experienced a 20% reduction of tumor size after failing sixth-line therapy [60]. However, most current studies continue to demonstrate the limited efficacy of TKIs in SDH deficient GIST (**Table 1**).

### ***Chemotherapeutic agents and experimental approaches***

Traditional cytotoxic chemotherapy has had limited success in GIST patients. One example is temozolomide, an alkylating agent with demonstrated anti-tumor activity in soft tissue sarcomas [61]. Temozolomide appears to be ineffective in treating unselected GIST patients. Two different studies have evaluated the efficacy of temozolomide in GIST patients, both showing an objective response rate of 0% [62, 63]. However, a 2014 study of 15 patients with paraganglioma and pheochromocytoma demonstrated that 50% of *SDHB*-mutated patients had a partial response to temozolomide by RECIST 1.1 criteria [64, 65]. On the other hand, 0% of the *SDHB* wild-type patients had partial responses with 40% having stable disease and 60% having progressive disease [64]. This suggests that *SDHB* mutations may be a biomarker for temozolomide sensitivity in paraganglioma and pheochromocytoma. The response of temozolomide has yet to be formally tested in SDH-deficient GIST patients. However, given SDH-deficient GIST and hereditary paragangliomas/pheochromocytomas share genomic mutations and inheritance patterns, we speculate that SDH-deficient GIST may have a response to temozolomide treatment. Our group at UC San Diego has recently opened Phase II clinical trial to investigate this hypothesis (ClinicalTrials.gov identifier NCT03556384).

As discussed above, hypermethylated promoter sequences in the *SDHC* gene leads to SDH deficiency. Furthermore, SDH deficiency in paragangliomas has been linked to the hypermethylation of target genes involved in chromaffin cell differentiation [66]. Thus, the use of DNA hypomethylating agents is under investigation for SDH-deficient cancers. A phase II clinical trial of the DNA methyltransferase inhibitor, guadecitabine, is currently recruiting participants with non-*KIT/PDGFR*A-mutated GIST and SDH-deficient paragangliomas and pheochromocytomas (ClinicalTrials.gov identifier NCT03165721).

Although the body of literature on the management of SDH-deficient GIST is limited, the increasing fund of knowledge regarding the metabolic role of SDH may lead to novel treatment approaches. A HIF2 $\alpha$  small molecule inhibitor, PT2385, has recently been identified and has been shown to act as a transcription factor-specific antagonist, inhibiting the expression of HIF2 $\alpha$  specific genes. In mice with renal cell carcinoma, treatment with PT2385 significantly reduced tumor burden [67]. In a recent phase I study of heavily pretreated clear cell renal carcinoma patients, PT2385 showed a favorable side-effect profile and some efficacy, with an observed 14% objective response rate [68]. Given SDH deficiency is implicated in HIF1 $\alpha$  stabilization in tumor cells, anti-hypoxics may play a role in SDH-deficient GIST treatment.

### ***Current guidelines for genetic testing and surveillance***

According to the 2019 NCCN guidelines for soft tissue sarcomas, *KIT* and *PDGFR*A genetic testing should be considered for all patients with GIST that are to be treated with systemic agents. Subsequently, for non-*KIT/PDGFR*A mutated GISTs, *SDHB* immunohistochemistry is recommended. Germline testing is recommended for all SDH-deficient GISTs.

Currently, there are no clear surveillance guidelines for follow-up for SDH deficient GIST, but follow-up should parallel that of the general GIST population. For all GIST patients with completely resected disease, follow-up with physical exams and cross sectional imaging (i.e., CT or MRI) of the abdomen/pelvis is recommended every 3-6 months for the first 5 years and then annually.

Given their predisposition to various cancers, there is a question of whether asymptomatic *SDHx* mutation carriers require surveillance. Recently, the results were reported of an annual surveillance program of 65



asymptomatic *SDHB* mutation carriers at a tertiary care center in the United Kingdom. All patients underwent annual MRIs of the abdomen with every other year MRIs of the neck, pelvis and thorax. Within 6 years, 25% had developed *SDHB*-related cancers with 16.6% having an asymptomatic tumor at the time of their first surveillance scan [69]. Of note, *SDHB* mutations are associated higher rates of pheochromocytoma and paragangliomas (PPGLs) [70, 71]. Patients with *SDHD* mutations were found to have a younger age of penetrance and were more likely to develop multifocal disease [72, 73]. In addition, *SDHB* and *SDHD* mutant PPGLs often cosecrete norepinephrine and dopamine or secrete only dopamine [74, 75]. Dopamine-only producing PPGLs are rare, and are often difficult to diagnose as they would not be detected by plasma or urine metanephrine and normetanephrine testing. Plasma-free methoxytyramine has proven to be a sensitive test to diagnose *SDHB/SDHD* mutant PPGLs. [76, 77].

Currently there is no available data regarding surveillance in *SDHA* and *SDHC* mutation carriers. However, given the difference in malignancy phenotypes between *SDHB* and *SDHD* mutation carriers as well their disposition to unique cancers, we believe that *SDH* mutation carriers require specific surveillance recommendations, and these recommendations should take into account which SDH subunit is mutated [78].

## **CONCLUSION**

SDH-deficient GIST are largely resistant to tyrosine kinase inhibitor therapy and lack effective treatment options. However, the understanding of the role of succinate dehydrogenase in tumorigenesis continues to expand. This knowledge can be applied to develop novel treatment approaches to SDH-deficient GIST with an emphasis on the use of precision medicine to treat this unique set of cancers.

## REFERENCES

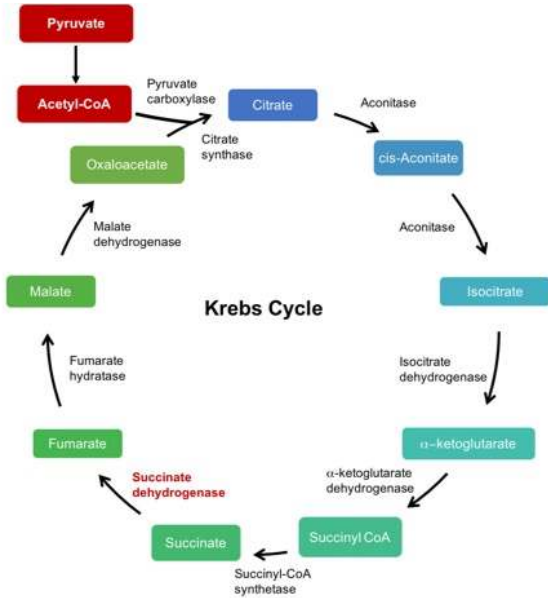
1. Ma, G. L., Murphy, J. D., Martinez, M. E., & Sicklick, J. K. (2015). Epidemiology of gastrointestinal stromal tumors in the era of histology codes: results of a population-based study. *Cancer Epidemiol Biomarkers Prev*, 24(1), 298-302, doi:10.1158/1055-9965.EPI-14-1002.
2. Kindblom, L.-G., Remotti, H. E., Aldenborn, F., & Meis-Kindblom, J. M. (1998). Gastrointestinal Pacemaker Cell Tumor (GIPACT) Gastrointestinal Stromal Tumors show phenotypic characteristics of the Interstitial Cells of Cajal. *American Journal of Pathology*, 152(5).
3. Miettinen, M., Monihan, J. M., Sarlomo-Rikala, M., Kovatich, A. J., Carr, N. J., Emory, T. S., et al. (1999). Gastrointestinal Stromal Tumors/Smooth Muscle Tumors (GISTs) Primary in the Omentum and Mesentery: Clinicopathologic and Immunohistochemical Study of 26 Cases. *The American Journal of Surgical Pathology*, 23(9), 1109.
4. Miettinen, M., Sarlomo-Rikala, M., Sobin, L. H., & Lasota, J. (2000). Esophageal Stromal Tumors: A Clinicopathologic, Immunohistochemical, and Molecular Genetic Study of 17 Cases and Comparison With Esophageal Leiomyomas and Leiomyosarcomas. *The American Journal of Surgical Pathology*, 24(2), 211-222.
5. Miettinen, M., Sobin, L. H., & Lasota, J. (2005). Gastrointestinal stromal tumors of the stomach: a clinicopathologic, immunohistochemical, and molecular genetic study of 1765 cases with long-term follow-up. *The American Journal of Surgical Pathology*, 29(1), 52-68, doi: 10.1097/01.pas.0000146010.92933.de.
6. Erlandson, R. A., Klimstra, D. S., & Woodruff, J. M. (2009). Subclassification of Gastrointestinal Stromal Tumors Based on Evaluation by Electron Microscopy and Immunohistochemistry. *Ultrastructural Pathology*, 20(4), 373-393, doi:10.3109/01913129609016340.
7. Miettinen, M. (1988). Gastrointestinal stromal tumors. An immunohistochemical study of cellular differentiation. *American Journal of Clinical Pathology*, 89(5), 601-610.
8. Miettinen, M., & Lasota, J. (2001). Gastrointestinal stromal tumors - definition, clinical, histological, immunohistochemical, and molecular genetic features and differential diagnosis. *Virchows Archiv*, 438(1), 1-12, doi:10.1007/s004280000338.
9. Dematteo, R. P., Heinrick, M. C., El-Rifai, W.-e., & Demetri, G. (2002). Clinical Management of Gastrointestinal Stromal Tumors: Before and After STI-571. *Human Pathology*, 33(5), 478-483, doi:10.1053/hupa.2002.124123.
10. Hirota, S., Isozaki, K., Moriyama, Y., Hashimoto, K., Nishida, T., Ishiguro, S., et al. (1998). Gain-of-Function Mutations of c-kit in Human Gastrointestinal Stromal Tumors. *Science*, 279(5350), 577-580, doi:10.1126/science.279.5350.577.
11. Heinrich, M. C., Corless, C. L., Duensing, A., McGreevey, L., Chen, C.-J., Joseph, N., et al. (2003). PDGFRA Activating Mutations in Gastrointestinal Stromal Tumors. *Science*, 299(5607), 708-710, doi:10.1126/science.1079666.
12. Shi, E., Chmielecki, J., Tang, C. M., Wang, K., Heinrich, M. C., Kang, G., et al. (2016). FGFR1 and NTRK3 actionable alterations in "Wild-Type" gastrointestinal stromal tumors. *Journal of Translational Medicine*, 14(1), 339, doi:10.1186/s12967-016-1075-6.
13. Corless, C. L., Barnett, C. M., & Heinrich, M. C. (2011). Gastrointestinal stromal tumours: origin and molecular oncology. *Nature Reviews Cancer*, 11(12), 865-878, doi:10.1038/nrc3143.
14. Agaram, N. P., Wong, G. C., Guo, T., Maki, R. G., Singer, S., Dematteo, R. P., et al. (2008). Novel V600E BRAF mutations in imatinib-naive and imatinib-resistant gastrointestinal stromal tumors. *Genes Chromosomes Cancer*, 47(10), 853-859, doi:10.1002/gcc.20589.
15. Brenca, M., Rossi, S., Polano, M., Gasparotto, D., Zanatta, L., Racanelli, D., et al. (2016). Transcriptome sequencing identifies ETV6-NTRK3 as a gene fusion involved in GIST. *Journal of Pathology*, 238(4), 543-549, doi:10.1002/path.4677.
16. Miranda, C., Nucifora, M., Molinari, F., Conca, E., Anania, M. C., Bordoni, A., et al. (2012). KRAS and BRAF mutations predict primary resistance to imatinib in gastrointestinal stromal tumors. *Clinical Cancer Research*, 18(6), 1769-1776, doi:10.1158/1078-0432.CCR-11-2230.
17. Alkhuziem, M., Burgoyne, A. M., Fanta, P. T., Tang, C.-M., & Sicklick, J. K. (2017). The Call of "The Wild"-Type GIST: It's Time for Domestication. *Journal of the National Comprehensive Cancer Network*, 15(5), 551-554, doi:10.6004/jnccn.2017.0057.
18. Janeway, K. A., Kim, S. Y., Lodish, M., Nose, V., Rustin, P., Gaal, J., et al. (2011). Defects in succinate dehydrogenase in gastrointestinal stromal tumors lacking KIT and PDGFRA mutations. *Proceedings of the National Academy of Sciences of the United States of America*, 108(1), 314-318, doi:10.1073/pnas.1009199108.
19. Miettinen, M., Wang, Z. F., Sarlomo-Rikala, M., Osuch, C., Rutkowski, P., & Lasota, J. (2011). Succinate dehydrogenase-deficient GISTs: a clinicopathologic, immunohistochemical, and molecular genetic study of 66 gastric GISTs with predilection to young age. *The American Journal of Surgical Pathology*, 35(11), 1712-1721, doi:10.1097/PAS.0b013e3182260752.
20. Pasini, B., McWhinney, S. R., Bei, T., Matyakhina, L., Stergiopoulos, S., Muchow, M., et al. (2008). Clinical and molecular genetics of patients with the Carney-Stratakis syndrome and germline mutations of the genes coding for the succinate dehydrogenase subunits SDHB, SDHC, and SDHD. *European Journal of Human Genetics*, 16(1), 79-88, doi:10.1038/sj.ejhg.5201904.
21. Boikos, S. A., Pappo, A. S., Killian, J., & et al. (2016). Molecular subtypes of KIT/PDGFRA wild-type gastrointestinal stromal tumors: A report from the National Institutes of Health gastrointestinal stromal tumor clinic. *JAMA Oncology*, 2(7), 922-928, doi:10.1001/jamaoncol.2016.0256.

22. Mullassery, D., & Weldon, C. B. (2016). Pediatric/"Wildtype" gastrointestinal stromal tumors. *Seminars in Pediatric Surgery*, 25(5), 305-310, doi:10.1053/j.sempedsurg.2016.09.004.
23. Wang, Y. M., Gu, M. L., & Ji, F. (2015). Succinate dehydrogenase-deficient gastrointestinal stromal tumors. *World Journal of Gastroenterology*, 21(8), 2303-2314, doi:10.3748/wjg.v21.i8.2303.
24. Miettinen, M., & Lasota, J. (2014). Succinate dehydrogenase deficient gastrointestinal stromal tumors (GISTs) - a review. *The International Journal of Biochemistry & Cell Biology*, 53, 514-519, doi:10.1016/j.biocel.2014.05.033.
25. Rutter, J., Winge, D. R., & Schiffman, J. D. (2010). Succinate dehydrogenase - Assembly, regulation and role in human disease. *Mitochondrion*, 10(4), 393-401, doi:10.1016/j.mito.2010.03.001.
26. Gottlieb, E., & Tomlinson, I. P. M. (2005). Mitochondrial tumour suppressors: a genetic and biochemical update. [Review Article]. *Nature Reviews Cancer*, 5, 857, doi:10.1038/nrc1737.
27. Soderberg, K. L., Ditta, G. S., & Scheffler, I. E. (1977). Mammalian cells with defective mitochondrial functions: a Chinese hamster mutant cell line lacking succinate dehydrogenase activity. *Cell*, 10(4), 697-702, doi:10.1016/0092-8674(77)90103-9.
28. Baysal, B. E., Ferrell, R. E., Willett-Brozick, J. E., Lawrence, E. C., Myssiorek, D., Bosch, A., et al. (2000). Mutations in SDHD, a Mitochondrial Complex II Gene, in Hereditary Paraganglioma. *Science*, 287(5454), 848-851, doi:10.1126/science.287.5454.848.
29. Astuti, D., Latif, F., Dallol, A., Dahia, P. L., Douglas, F., George, E., et al. (2001). Gene mutations in the succinate dehydrogenase subunit SDHB cause susceptibility to familial pheochromocytoma and to familial paraganglioma. *American Journal of Human Genetics*, 69(1), 49-54, doi:10.1086/321282.
30. Bardella, C., Pollard, P. J., & Tomlinson, I. (2011). SDH mutations in cancer. *Biochimica et Biophysica Acta*, 1807(11), 1432-1443, doi:10.1016/j.bbabi.2011.07.003.
31. Burnichon, N., Vescovo, L., Amar, L., Libe, R., de Reynies, A., Venisse, A., et al. (2011). Integrative genomic analysis reveals somatic mutations in pheochromocytoma and paraganglioma. *Human Molecular Genetics*, 20(20), 3974-3985, doi:10.1093/hmg/ddr324.
32. Ricketts, C., Woodward, E. R., Killick, P., Morris, M. R., Astuti, D., Latif, F., et al. (2008). Germline SDHB mutations and familial renal cell carcinoma. *Journal of the National Cancer Institute*, 100(17), 1260-1262, doi:10.1093/jnci/djn254.
33. Aspuria, P.-J. P., Lunt, S. Y., Våremo, L., Vergnes, L., Gozo, M., Beach, J. A., et al. (2014). Succinate dehydrogenase inhibition leads to epithelial-mesenchymal transition and reprogrammed carbon metabolism. *Cancer & Metabolism*, 2(1), 21, doi:10.1186/2049-3002-2-21.
34. Iommarini, L., Porcelli, A. M., Gasparre, G., & Kurelac, I. (2017). Non-Canonical Mechanisms Regulating Hypoxia-Inducible Factor 1 Alpha in Cancer. *Frontiers in Oncology*, 7, 286, doi:10.3389/fonc.2017.00286.
35. Fuhler, G. M., Eppinga, H., & Peppelenbosch, M. P. (2017). Fumarates and Cancer. *Trends in Molecular Medicine*, 23(1), 3-5, doi:10.1016/j.molmed.2016.12.001.
36. Frezza, C., Pollard, P. J., & Gottlieb, E. (2011). Inborn and acquired metabolic defects in cancer. *Journal of Molecular Medicine*, 89(3), 213-220, doi:10.1007/s00109-011-0728-4.
37. Ruas, J. L., & Poellinger, L. (2005). Hypoxia-dependent activation of HIF into a transcriptional regulator. *Seminars in Cell and Developmental Biology*, 16(4-5), 514-522, doi:10.1016/j.semcdb.2005.04.001.
38. Selak, M. A., Armour, S. M., MacKenzie, E. D., Boulahbel, H., Watson, D. G., Mansfield, K. D., et al. (2005). Succinate links TCA cycle dysfunction to oncogenesis by inhibiting HIF-alpha prolyl hydroxylase. *Cancer Cell*, 7, doi:10.1016/j.ccr.2004.11.022.
39. MacKenzie, E. D., Selak, M. A., Tennant, D. A., Payne, L. J., Crosby, S., Frederiksen, C. M., et al. (2007). Cell-permeating alpha-ketoglutarate derivatives alleviate pseudohypoxia in succinate dehydrogenase-deficient cells. *Molecular and Cellular Biology*, 27(9), 3282-3289, doi:10.1128/MCB.01927-06.
40. Miettinen, M., Killian, J. K., Wang, Z. F., Lasota, J., Lau, C., Jones, L., et al. (2013). Immunohistochemical loss of succinate dehydrogenase subunit A (SDHA) in gastrointestinal stromal tumors (GISTs) signals SDHA germline mutation. *The American Journal of Surgical Pathology*, 37(2), 234-240, doi:10.1097/PAS.0b013e3182671178.
41. Burnichon, N., Briere, J. J., Libe, R., Vescovo, L., Riviere, J., Tissier, F., et al. (2010). SDHA is a tumor suppressor gene causing paraganglioma. *Human Molecular Genetics*, 19(15), 3011-3020, doi:10.1093/hmg/ddq206.
42. Pantaleo, M. A., Astolfi, A., Indio, V., Moore, R., Thiessen, N., Heinrich, M. C., et al. (2011). SDHA loss-of-function mutations in KIT-PDGFRA wild-type gastrointestinal stromal tumors identified by massively parallel sequencing. *Journal of the National Cancer Institute*, 103(12), 983-987, doi:10.1093/jnci/djr130.
43. Bannon, A. E., Kent, J. D., Forquer, I., Town, A., Klug, L. R., McCann, K. E., et al. (2017). Biochemical, Molecular, and Clinical Characterization of Succinate Dehydrogenase Subunit A Variants of Unknown Significance. *Clinical Cancer Research*, doi:10.1158/1078-0432.ccr-17-1397.
44. Killian, J. K., Miettinen, M., Walker, R. L., Wang, Y., Zhu, Y. J., Waterfall, J. J., et al. (2014). Recurrent epimutation of SDHC in gastrointestinal stromal tumors. *Science Translational Medicine*, 6(268), 1-9, doi:10.1126/scitranslmed.3009961.
45. Carney, J. A., Sheps, S. G., Go, V. L. W., & Gordon, H. (1977). The Triad of Gastric Leiomyosarcoma, Functioning Extra-Adrenal Paraganglioma and Pulmonary Chondroma. *New England Journal of Medicine*, 296(26), 1517-1518, doi:10.1056/nejm197706302962609.
46. Matyakhina, L., Bei, T. A., McWhinney, S. R., Pasini, B., Cameron, S., Gunawan, B., et al. (2007). Genetics of carney triad: recurrent losses at chromosome 1 but lack of germline mutations in genes associated with paragangliomas and

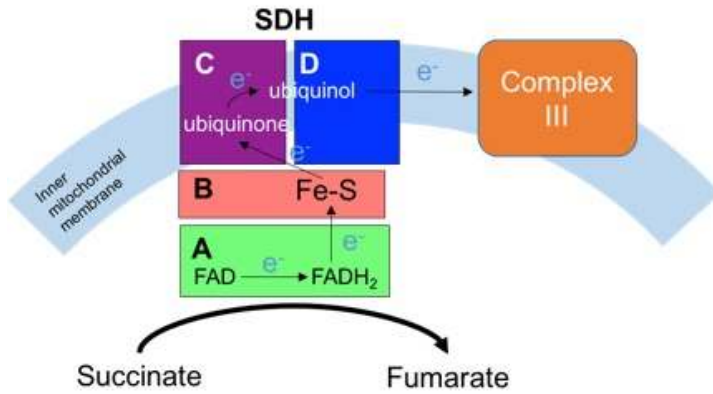
- gastrointestinal stromal tumors. *The Journal of Clinical Endocrinology & Metabolism*, 92(8), 2938-2943, doi:10.1210/jc.2007-0797.
47. Stratakis, C. A., & Carney, J. A. (2009). The triad of paragangliomas, gastric stromal tumours and pulmonary chondromas (Carney triad), and the dyad of paragangliomas and gastric stromal sarcomas (Carney-Stratakis syndrome): molecular genetics and clinical implications. *Journal of Internal Medicine*, 266(1), 43-52, doi:10.1111/j.1365-2796.2009.02110.x.
  48. Sicklick, J. K., & Lopez, N. E. (2013). Optimizing surgical and imatinib therapy for the treatment of gastrointestinal stromal tumors. *Journal of Gastrointestinal Surgery*, 17(11), 1997-2006, doi:10.1007/s11605-013-2243-0.
  49. Mei, L., Du, W., Idowu, M., von Mehren, M., & Boikos, S. A. (2018). Advances and Challenges on Management of Gastrointestinal Stromal Tumors. *Frontiers in Oncology*, 8, 135, doi:10.3389/fonc.2018.00135.
  50. DeMatteo, R. P., Lewis, J. J., Leung, D., Mudan, S. S., Woodruff, J. M., & Brennan, M. F. (2000). Two Hundred Gastrointestinal Stromal Tumors: Recurrence Patterns and Prognostic Factors for Survival. *Annals of Surgery*, 231(1), 51.
  51. Janeway, K. A., Liegl, B., Harlow, A., Le, C., Perez-Atayde, A., Kozakewich, H., et al. (2007). Pediatric KIT wild-type and platelet-derived growth factor receptor alpha-wild-type gastrointestinal stromal tumors share KIT activation but not mechanisms of genetic progression with adult gastrointestinal stromal tumors. *Cancer Research*, 67(19), 9084-9088, doi:10.1158/0008-5472.CAN-07-1938.
  52. Willobee, B. A., Quiroz, H. J., Sussman, M. S., Thorson, C. M., Sola, J. E., & Perez, E. A. (2018). Current treatment strategies in pediatric gastrointestinal stromal cell tumor. *Translational Gastroenterology and Hepatology*, 3, 53-53, doi:10.21037/tgh.2018.07.09.
  53. Fero, K. E., Coe, T. M., Fanta, P. T., Tang, C. M., Murphy, J. D., & Sicklick, J. K. (2017). Surgical Management of Adolescents and Young Adults With Gastrointestinal Stromal Tumors: A US Population-Based Analysis. *JAMA Surgery*, 152(5), 443-451, doi:10.1001/jamasurg.2016.5047.
  54. Weldon, C. B., Madenci, A. L., Boikos, S. A., Janeway, K. A., George, S., von Mehren, M., et al. (2017). Surgical Management of Wild-Type Gastrointestinal Stromal Tumors: A Report From the National Institutes of Health Pediatric and Wildtype GIST Clinic. *Journal of Clinical Oncology*, 35(5), 523-528, doi:10.1200/jco.2016.68.6733.
  55. Norton, J. A., Kim, T., Kim, J., McCarter, M. D., Kelly, K. J., Wong, J., et al. (2018). SSAT State-of-the-Art Conference: Current Surgical Management of Gastric Tumors. *Journal of Gastrointestinal Surgery*, 22(1), 32-42, doi:10.1007/s11605-017-3533-8.
  56. Heinrich, M. C., Rankin, C., Blanke, C. D., Demetri, G. D., Borden, E. C., Ryan, C. W., et al. (2017). Correlation of Long-term Results of Imatinib in Advanced Gastrointestinal Stromal Tumors With Next-Generation Sequencing Results: Analysis of Phase 3 SWOG Intergroup Trial S0033. *JAMA Oncology*, 3(7), 944-952, doi:10.1001/jamaoncol.2016.6728.
  57. Demetri, G. D., van Oosterom, A. T., Garrett, C. R., Blackstein, M. E., Shah, M. H., Verweij, J., et al. (2006). Efficacy and safety of sunitinib in patients with advanced gastrointestinal stromal tumour after failure of imatinib: a randomised controlled trial. *The Lancet*, 368(9544), 1329-1338, doi:10.1016/S0140-6736(06)69446-4.
  58. Heinrich, M. C., Maki, R. G., Corless, C. L., Antonescu, C. R., Harlow, A., Griffith, D., et al. (2008). Primary and secondary kinase genotypes correlate with the biological and clinical activity of sunitinib in imatinib-resistant gastrointestinal stromal tumor. *Journal of Clinical Oncology*, 26(33), 5352-5359, doi:10.1200/JCO.2007.15.7461.
  59. Ben-Ami, E., Barysaukas, C. M., Von Mehren, M., Heinrich, M. C., Corless, C. L., Butrynski, J. E., et al. (2016). Long-term follow-up results of the multicenter phase II trial of regorafenib in patients with metastatic and/or unresectable GI stromal tumor after failure of standard tyrosine kinase inhibitor therapy. *Annals of Oncology*, 27(9), 1794-1799, doi:10.1093/annonc/mdw228.
  60. Ganjoo, K. N., Villalobos, V. M., Kamaya, A., Fisher, G. A., Butrynski, J. E., Morgan, J. A., et al. (2014). A multicenter phase II study of pazopanib in patients with advanced gastrointestinal stromal tumors (GIST) following failure of at least imatinib and sunitinib. *Annals of Oncology*, 25(1), 236-240, doi:10.1093/annonc/mdt484.
  61. Tsang, L. L. H., Quarterman, C. P., Gescher, A., & Slack, J. A. (1991). Comparison of the cytotoxicity in vitro of temozolomide and dacarbazine, prodrugs of 3-methyl-(triazene-1-yl)imidazole-4-carboxamide. [journal article]. *Cancer Chemotherapy and Pharmacology*, 27(5), 342-346, doi:10.1007/bf00688855.
  62. Trent, J. C., Beach, J., Burgess, M. A., Papadopolous, N., Chen, L. L., Benjamin, R. S., et al. (2003). A two-arm phase II study of temozolomide in patients with advanced gastrointestinal stromal tumors and other soft tissue sarcomas. *Cancer*, 98(12), 2693-2699, doi:10.1002/cncr.11875.
  63. Garcia Del Muro, X., Lopez-Pousa, A., Martin, J., Buesa, J. M., Martinez-Trufero, J., Casado, A., et al. (2005). A phase II trial of temozolomide as a 6-week, continuous, oral schedule in patients with advanced soft tissue sarcoma. *Cancer*, 104(8), 1706-1712, doi:10.1002/cncr.21384.
  64. Hadoux, J., Favier, J., Scoazec, J. Y., Leboulleux, S., Al Ghuzlan, A., Caramella, C., et al. (2014). SDHB mutations are associated with response to temozolomide in patients with metastatic pheochromocytoma or paraganglioma. *International Journal of Cancer*, 135(11), 2711-2720, doi:10.1002/ijc.28913.
  65. Eisenhauer, E. A., Therasse, P., Bogaerts, J., Schwartz, L. H., Sargent, D., Ford, R., et al. (2009). New response evaluation criteria in solid tumours: Revised RECIST guideline (version 1.1). *European Journal of Cancer*, 45(2), 228-247, doi:10.1016/j.ejca.2008.10.026.
  66. Letouze, E., Martinelli, C., Lorient, C., Burnichon, N., Abermil, N., Ottolenghi, C., et al. (2013). SDH mutations establish a hypermethylator phenotype in paraganglioma. *Cancer Cell*, 23, doi:10.1016/j.ccr.2013.04.018.

67. Wallace, E. M., Rizzi, J. P., Han, G., Wehn, P. M., Cao, Z., Du, X., et al. (2016). A Small-Molecule Antagonist of HIF2alpha Is Efficacious in Preclinical Models of Renal Cell Carcinoma. *Cancer Research*, 76(18), 5491-5500, doi:10.1158/0008-5472.CAN-16-0473.
68. Courtney, K. D., Infante, J. R., Lam, E. T., Figlin, R. A., Rini, B. I., Brugarolas, J., et al. (2017). Phase I Dose-Escalation Trial of PT2385, a First-in-Class Hypoxia-Inducible Factor-2 $\alpha$  Antagonist in Patients With Previously Treated Advanced Clear Cell Renal Cell Carcinoma. *Journal of Clinical Oncology*, 36(9), 867-874, doi:10.1200/JCO.2017.74.2627.
69. Tufton, N., Shapiro, L., Srirangalingam, U., Richards, P., Sahdev, A., Kumar, A. V., et al. (2017). Outcomes of annual surveillance imaging in an adult and paediatric cohort of succinate dehydrogenase B mutation carriers. *Clin Endocrinol (Oxf)*, 86(2), 286-296, doi:10.1111/cen.13246.
70. Gimenez-Roqueplo, A.-P., Favier, J., Rustin, P., Rieubland, C., Crespin, M., Nau, V., et al. (2003). Mutations in the SDHB Gene Are Associated with Extra-adrenal and/or Malignant Pheochromocytomas. *Cancer Research*, 63(17), 5615-5621.
71. Amar, L., Baudin, E., Burnichon, N., Peyrard, S., Silvera, S., Bertherat, J., et al. (2007). Succinate dehydrogenase B gene mutations predict survival in patients with malignant pheochromocytomas or paragangliomas. *Journal of Clinical Endocrinology and Metabolism*, 92(10), 3822-3828, doi:10.1210/jc.2007-0709.
72. Neumann, H. H., Pawlu, C., Pęczkowska, M., & et al. (2004). Distinct clinical features of paraganglioma syndromes associated with SDHB and SDHD gene mutations. *Journal of the American Medical Association*, 292(8), 943-951, doi:10.1001/jama.292.8.943.
73. Benn, D. E., Gimenez-Roqueplo, A. P., Reilly, J. R., Bertherat, J., Burgess, J., Byth, K., et al. (2006). Clinical presentation and penetrance of pheochromocytoma/paraganglioma syndromes. *Journal of Clinical Endocrinology and Metabolism*, 91(3), 827-836, doi:10.1210/jc.2005-1862.
74. Timmers, H. J. L. M., Kozupa, A., Eisenhofer, G., Raygada, M., Adams, K. T., Solis, D., et al. (2007). Clinical Presentations, Biochemical Phenotypes, and Genotype-Phenotype Correlations in Patients with Succinate Dehydrogenase Subunit B-Associated Pheochromocytomas and Paragangliomas. *The Journal of Clinical Endocrinology & Metabolism*, 92(3), 779-786, doi:10.1210/jc.2006-2315.
75. Eisenhofer, G., Pacak, K., Huynh, T.-T., Qin, N., Bratslavsky, G., Linehan, W. M., et al. (2010). Catecholamine metabolomic and secretory phenotypes in pheochromocytoma. *Endocrine-Related Cancer*, 18(1), 97-111, doi:10.1677/ERC-10-0211.
76. Eisenhofer, G., Goldstein, D. S., Sullivan, P., Csako, G., Brouwers, F. M., Lai, E. W., et al. (2005). Biochemical and Clinical Manifestations of Dopamine-Producing Paragangliomas: Utility of Plasma Methoxytyramine. *The Journal of Clinical Endocrinology & Metabolism*, 90(4), 2068-2075, doi:10.1210/jc.2004-2025.
77. Eisenhofer, G., Lenders, J. W. M., Timmers, H., Mannelli, M., Grebe, S. K., Hofbauer, L. C., et al. (2011). Measurements of Plasma Methoxytyramine, Normetanephrine, and Metanephrine as Discriminators of Different Hereditary Forms of Pheochromocytoma. *Clinical Chemistry*, 57(3), 411, doi:10.1373/clinchem.2010.153320.
78. Tufton, N., Sahdev, A., & Akker, S. A. (2017). Radiological Surveillance Screening in Asymptomatic Succinate Dehydrogenase Mutation Carriers. *Journal of the Endocrine Society*, 1(7), 897-907, doi:10.1210/js.2017-00230.

## FIGURES



**Figure 1. Schematic of the Krebs cycle.** The succinate dehydrogenase (SDH) complex converts succinate to fumarate.



**Figure 2. Complex II in the electron transport chain.** Electrons enter complex II. FAD is then reduced to FADH<sub>2</sub>, during the oxidation of succinate to fumarate in SDHA. Electrons are transferred from FADH<sub>2</sub> to iron sulphur proteins in SDHB, and then to ubiquinone bound to SDHC and SDHD. Ubiquinone is reduced to ubiquinol, which transfers electrons to complex III.

**TABLE****Table 1.** Clinical studies of FDA-approved TKI efficacy in *SDH* deficient or non-*KIT/PDGFRA* mutated GIST.

Author	Journal	Year	Study	Genetic profile	Imatinib	Regorafenib	Sunitinib	Vandetanib	Type of response
Boikos	<i>JAMA Oncology</i>	2016	Retrospective cohort study	SDH- deficient	1/49 (2.0%)		7/38 (18.4%)		Imatinib: 1 partial Sunitinib: 1 complete, 3 partial, 3 mixed.
Ben Ami	<i>Annals of Oncology</i>	2016	Phase II study	SDH-deficient		2/6 (33.3%)			Partial response
Janeway	<i>Ped Blood Cancer</i>	2009	Treatment use protocol	Non- <i>KIT/PDGFRA</i> mutant			1/7 (14.3%)		Partial response
Heinrich	<i>JAMA Oncology</i>	2017	SWOG Intergroup Trial S0033	SDH-deficient	1/12 (8.3%)				Partial response
Glod	<i>JCO</i>	2016	Phase II study	Non- <i>KIT/PDGFRA</i> mutant				0/9 (0%)	