

Review Article

Current status and future perspectives in laparoendoscopic single-site and natural orifice transluminal endoscopic urological surgery

Riccardo Autorino,^{1,2} Robert J Stein,¹ Estevão Lima,³ Rocco Damiano,⁴ Rakesh Khanna,¹ Georges-Pascal Haber,¹ Michael A White¹ and Jihad H Kaouk¹

¹Center for Laparoscopy and Robotic Surgery, Glickman Urological and Kidney Institute, Cleveland Clinic, Cleveland, Ohio, USA;

²Urology Clinic, Second University of Naples, Napoli, ⁴Department of Urology, Magna Graecia University, Catanzaro, Italy; and ³Life and Health Sciences Research Institute, School of Health Sciences, University of Minho, Braga, Portugal

Abstract: Objective of this study is to provide an evidence-based analysis of the current status and future perspectives of scarless urological surgery. A PubMed search has been performed for all relevant urological literature regarding natural orifice transluminal endoscopic surgery (NOTES) and laparoendoscopic single-site surgery (LESS). In addition, experience with LESS and NOTES at our own institution has been considered. All clinical and investigative reports for LESS and NOTES procedures in the urological literature have been considered. A wide variety of clinical procedures in urology have been successfully completed by using LESS techniques. Thus far, experience with NOTES has largely been investigational, although early clinical reports are emerging. Further development of instrumentation and platforms is necessary for both techniques to become more widely adopted throughout the urological community.

Key words: laparoendoscopic single-site surgery (LESS), natural orifice transluminal endoscopic surgery (NOTES), scarless surgery, urology.

Introduction

For many urological applications, laparoscopic surgery has been shown to decrease postoperative morbidity, shorten hospitalization and convalescence, and improve cosmesis while matching the outcomes of equivalent open procedures. However, complications related to port placement have been well recognized in laparoscopy.¹

With the aim of preventing port-site complications, further decreasing discomfort associated with laparoscopic surgery, and improving cosmesis, natural orifice transluminal endoscopic surgery (NOTES) and laparoendoscopic single-site surgery (LESS) have recently been developed.² The term 'NOTES' was first formally introduced by the Natural Orifice Surgery Consortium for Assessment and Research (NOSCAR), a joint initiative supported by the American Society for Gastrointestinal Endoscopy (ASGE) and the Society of American Gastrointestinal and Endoscopic Surgeons (SAGES).³ The central tenets of NOTES involve the intentional puncture of one of the viscera (e.g. stomach, rectum, vagina, urinary bladder) to access the abdominal cavity and perform intra-abdominal surgical

procedures. The hypothesized advantages of NOTES include further reduction in the invasiveness of the surgical procedure with associated reduced patient pain and morbidity.⁴

NOTES, in its purest form, does not use any transabdominal ports, such that the lack of a visible scar, decreased pain, and the elimination of abdominal wound morbidity represent major potential benefits of using this approach. Difficulties performing 'pure' NOTES procedures have been well documented and include challenges secondary to the parallel insertion of instruments with a lack of triangulation, maintaining spatial orientation, inefficient traction, and indirect force transmission.

The use of a transabdominal port has not been considered as being incompatible with NOTES, but is instead regarded as being part of the development of this technique. Thus, procedures performed via one, or a combination of natural orifices, but with an additional transabdominal port have been defined as 'hybrid' NOTES.⁵

The first NOTES series was reported in 2004 by Kalloo *et al.* and consisted of cases of transgastric liver biopsies.⁶ Following that publication, other investigators demonstrated the feasibility of several procedures, all based on experimental porcine models. At the 2006 SAGES conference the first transgastric NOTES appendectomy performed in humans was reported.⁷ Three years later, Marescaux *et al.* described the first cholecystectomy performed by transvaginal NOTES in humans, what has been presented as the 'Anubis Project'.⁸

Correspondence: Riccardo Autorino MD FEBU, Center for Laparoscopy and Robotic Surgery, Glickman Urological and Kidney Institute, 9500 Euclid Avenue, Cleveland, OH 44195, USA. Email: ricautor@tin.it; autorir@ccf.org

Received 7 January 2010; accepted 20 January 2010.

Online publication 3 March 2010

Experimentally, urologists have been at the forefront of NOTES. The event prompting experimental evaluation of urological NOTES was the description of vaginal extraction of an intact surgical specimen following laparoscopic radical nephrectomy.⁹ The first experimental application of NOTES was reported by Gettman *et al.* describing a successful transvaginal nephrectomy in the pig.¹⁰ Indeed, this work predated the acronym NOTES as well as the first recognized NOTES report by Kalloo *et al.* in the gastroenterology literature.⁶ Likewise, the bladder was successfully used for the first time by Lima *et al.* as a NOTES portal in experimental porcine models.¹¹

Several urological groups initially used a variety of terms to describe the technique now defined as LESS.⁵ LESS appears to provide several of the benefits of NOTES, with enhanced cosmesis and decreased abdominal wall trauma, without the added risks and difficulty encountered by traversing a natural orifice.¹² However, LESS still requires cutaneous incisions, an approach avoided by NOTES. From a cosmetic standpoint LESS may be ideally performed via the umbilicus, an embryonic remnant of development. It might include a single laparoscopic access port, an access platform with several channels for instrumentation, a single skin incision through which several separate ports can be placed, a single incision through which several ports are placed through separate fascial incisions, or even several small incisions grouped around a common site.

The aim of the present review is to provide an evidence-based analysis of the current status and future perspectives of *scarless* urological surgery.

NOTES access: Issues and controversies

In the debate regarding the best portal for performing NOTES several factors need to be considered: ease of access, ease of closure, potential for infectious complications, security of closure, severity of complications related to closure failure, maximum diameter for instrument insertion and specimen removal, and the relationship to the target anatomy.¹³

NOTES has thus far been successfully completed experimentally by the transgastric, transvaginal, transcolonic, and transvesical routes. Overall, the logistics of transvisceral surgery are universal:¹² (i) the natural orifice is accessed with the aid of a flexible multichannel scope; (ii) incision is made through the visceral wall using a needle-knife; (iii) a wire is passed into the peritoneal cavity using a modified Seldinger technique; (iv) a dilating balloon is variably used to obtain a suitable access tract; (v) a catheter, guide tube, or overtube is placed over the guide-wire and insufflation is achieved with CO₂; (vi) scope is advanced into the peritoneal cavity; and (vii) viscerotomy is closed.

As already mentioned, Kalloo *et al.* demonstrated the feasibility and potential surgical usefulness of *trans*-gastric access to the peritoneal cavity in a porcine model.⁶ However, following the initial enthusiasm, the possibility to carry out abdominal procedures through an isolated transgastric route faced several limitations, including access to the peritoneal cavity, the need for endoscope retroflexion for upper abdominal procedures, and endoscopic closure of the gastrotomy. In attempting to overcome these limitations, several solutions have been proposed such as the construction of more rigid transgastric platforms¹⁴ and the combination of the transgastric access with a *trans*-abdominal port (hybrid approach) or with a lower abdominal access (pure NOTES combined approach).¹⁵ Gastrotomy closure has become one of the key areas in NOTES research and development. Although stapling devices have become the mainstay for gastrointestinal anastomosis, the technological hurdle to be able to apply this to an endoscope is substantial. Therefore, an individually placed suture or clip is the most likely method of gastrotomy closure for the foreseeable future.¹⁶ Improvements are needed in endoscopic technologies, gastric access techniques and closure methods, and the development of instrumentation that can be used effectively through endoscopic channels.

For lower abdominal access several options exist, all of them offering the possibility of introducing rigid instruments into the abdomen (Table 1).

One of the most important factors when performing NOTES is the secure closure of the access portal. Secure closure of the vagina is readily attainable using standard surgical techniques. In the gynecological literature, thousands of patients have been subjected to an opening from the vagina into the peritoneal cavity for a variety of procedures with a low complication rate. Of course, it should be considered that a notable difference when performing NOTES would be the need to introduce instrumentation through the

Table 1 Comparing access routes for natural orifice trans-luminal endoscopic surgery

	Bladder	Vagina	Colon
Available in both sexes	++	–	++
Possible use of rigid instruments	++	++	+
Sterility	+	–	—
Limited ‘otomy’ size	++	+	+
Ease of closure	+	++	+
Specimen retrieval	–	++	+

Adapted from Lima E, Rolanda C, Correia-Pinto J. *NOTES performed using multiple ports of entry: Current experience and potential implications for urologic applications.* J Endourol 2009; 23(5):759–64.²²

vagina into an area of the abdominal cavity remote from the initial incision site. This may increase the risk for infectious complications.

Of all the access sites, the vagina is best suited for specimen extraction. Performing transvaginal surgery allows for in-line direct visualization of most retroperitoneal structures without the need for retroflexion and the resultant difficulties with spatial orientation. Finally, rigid instruments are able to be inserted via this approach, because there is a direct line to the upper tract urological target organs.

Despite the fact that the transvaginal access portal holds many potential advantages over all of the other access points, several questions do remain. One obvious limitation of the transvaginal portal is that it can be used in only 50% of the population because of gender, and then among women, previous pelvic or vaginal surgery may preclude this approach. It will also be important to study the effects on sexual function and quality of life. Currently, there is a relative paucity of information on these issues in vaginal surgery, and the reports in the literature are inconsistent.¹⁷

Within the realm of NOTES, there are specific theoretical advantages of the transcolonic approach. For upper abdominal exploration and interventions, the transcolonic approach allows for en-face visualization as well as increased stability of the endoscope, because retroflexion is unnecessary in the transgastric approach. Furthermore, the rectum is much more compliant with a larger capacity to allow for insertion of larger diameter instruments and removal of larger specimens than that allowed by the upper gastrointestinal tract. The general consensus is that the transcolonic approach to NOTES is technically feasible and has been demonstrated in multiple animal studies.¹⁸ The concern for increased risk of infection during NOTES is the most worrisome potential disadvantage in its widespread application. Because NOTES requires a transvisceral incision to access the intra-abdominal space, there is strong concern for translocation of intraluminal bacterial pathogens into the previously sterile peritoneal space. A large hurdle that needs to be overcome for the transfer of the experimental model of transcolonic NOTES to the human trial is the ability to attain reliable and complete closure of the colonic access site. Current techniques of closure have included endoscopic clips, endoscopic suturing devices, and laparoscopic stapling devices. Nevertheless, most of these closure techniques have been studied in gastrotomy sites, which may be more forgiving than a colostomy. Further studies are needed to investigate the most reliable method of achieving leak-proof colotomy closure. Visualization of the retroperitoneal space and urogenital system through a transcolonic approach is comparable to the transvaginal route, with the additional benefit of not being limited by the gender of the patient. Unlike the transvesical route, which is limited by the luminal diameter, the transcolonic route is compliant and able to accept larger instruments and to allow specimen retrieval.

Lima *et al.* were the first to assess the feasibility and safety of creating a transvesical port.¹¹ The transvesical port is placed at the most anterior positioning in the sagittal plane and for this reason is associated with reduced risk of visceral damage. Introducing the surgical instruments via the bladder dome allows one to work anterior to the bowel loops, instead of among them. Additionally, the transvesical port is the unique lower abdominal access that is inherently sterile, and available in both genders in contrast to the transvaginal access.¹⁹

In 2007, Gettman and coworkers performed cadaveric studies before applying transvesical NOTES in the clinical setting.²⁰ Transvesical peritoneoscopy and appendectomy were performed in one cadaver, while transvesical peritoneoscopy and division of the falciform ligament were performed in the other.

The combination transgastric–transvesical access aims to overcome many limitations previously described for the isolated transgastric approach related to exposure, organ retraction, grasping and limited triangulation. The efficiency of the concept of combining transgastric access (using flexible instruments) and transvesical access (using rigid instruments) was demonstrated by Lima *et al.* who performed pure NOTES nephrectomy in a non-survival study in a porcine model.²¹

The fact that the upper abdominal organs are visualized in a direct line of sight using transvesical access decreases the complexity of spatial orientation that may be encountered with access via other natural orifices. Another concern with NOTES procedures has been the ability to achieve and maintain pneumoperitoneum. In the porcine, cadaveric, and clinical settings, pneumoperitoneum was achieved with insufflation through the working channel of ureteroscopes. Difficulty was not encountered with maintaining a seal around the scope in the transvesical approach; thus, obtaining and maintaining pneumoperitoneum through a transvesical portal appears feasible.

At this point in time an isolated port raises limitations in performing NOTES complex procedures in the urology field. It is predictable that for moderately complex procedures, multiple ports may be needed. In this regard the transvaginal-transabdominal (hybrid) approach is the most appealing, whereas for pure NOTES, transgastric coupled with transvesical access may be a preferred method.²²

NOTES in urology

Urologists have been on the forefront of minimally invasive surgery for 25 years. Stones that were formerly managed with open lithotomy are now approached with SWL, ureteroscopy, and percutaneous techniques. Large, obstructing prostate glands once managed with open prostatectomy are now routinely managed endoscopically. Thus, urologists are uniquely equipped with the skill sets necessary to perform

pure NOTES because they have experience in both endoscopy and surgery. To address the urological application of NOTES a working group has been established under the auspices of the Endourological Society.²

Experimental NOTES urological procedures

Nephrectomy (Table 2)

In 2002, Gettman and coworkers described the first transvaginal nephrectomy in a porcine model.¹⁰ However, in five of six renal units, a single 5-mm transabdominal trocar for the laparoscope was required to facilitate visualization. The authors concluded that hybrid NOTES nephrectomy was feasible in the porcine model even if the procedure was compromised by ill-adapted instrumentation and was not yet ready for human application. There were neither subsequent reports of this procedure from other institutions nor any clinical cases over the ensuing 5 years.

More recently, several groups have begun to revisit the concept of NOTES applications in urology. Clayman *et al.* reported transvaginal nephrectomy performed using a purpose-built operating platform (TransPort multi-lumen operating platform, USGI Medical, San Clemente, CA).²³ The porcine kidney was mobilized exclusively through the vaginal port, and the renal hilum was controlled with an endovascular stapler placed through a 12-mm umbilical port. This represented the initial report of a successful transvaginal porcine nephrectomy using purpose-built NOTES instrumentation.

In 2007, Lima and colleagues described a novel combined transgastric and transvesical approach for six porcine nephrectomies.²¹ The authors used a two-orifice approach in an attempt to minimize instrument collision and restore, in part, instrument triangulation. They placed a 5-mm transvesical port into the peritoneal cavity and passed the gastroscope orally into the peritoneal cavity through a gastrostomy in six female pigs. The mobilization of the kidney was accomplished with the cautery and the grasper passing through the gastroscope. The renal pedicle was ligated using metal clips and an ultrasonic dissector introduced through the transvesical port. The authors concluded that nephrectomy by NOTES using the combined transgastric and transvesical approach is technically feasible, although the use of 5-mm clips and ultrasonic shears for hilar ligation is widely regarded as not applicable to human nephrectomy.

Haber *et al.* assessed the technical feasibility and reproducibility of pure NOTES transvaginal nephrectomy in a porcine model using NOTES-specific instrumentation and with no transabdominal port.²⁵ Five female farm pigs underwent a right NOTES nephrectomy using a single-channel gastroscope in the first three pigs and a dual-channel gastroscope in the remaining two. The peritoneal cavity was accessed through the posterior fornix of the vagina. An XL

articulated 60-cm endo-GIA stapler (US Surgical, Norwalk, CO, USA), inserted transvaginally via a separate vaginal incision, was used for tissue retraction and renal hilar transection. After complete mobilization, the kidney was extracted intact transvaginally. All procedures were successful with no complications, no addition of a transabdominal laparoscopic port, and no incidence of conversion. Mean total operative time was 113 min with minimal blood loss.

Isariyawongse *et al.* reported bilateral NOTES nephrectomy using standard instruments through a modified transvaginal trocar.²⁴ The authors were able to dissect and divide the renal pedicle and the ureter with a transvaginal laparoscopic stapler with visualization using a transgastric endoscope in a female pig.

An animal model necessarily has variations from human anatomy. As the next step in developing pure NOTES nephrectomy for ultimate clinical application, Aron *et al.* investigated the human cadaver model using a rigid transvaginal platform.²⁶ They used a multichannel R-Port placed into the umbilicus, a Quadport into the vagina, straight and articulating laparoscopic instruments, and a rigid 10-mm, 30° laparoscope. Three nephrectomies were successfully performed; one left-sided procedure was aborted due to adhesions from prior surgery. In the first two cadavers, transient umbilical assistance was necessary toward the end of the procedure to release posterosuperior attachments between the upper-pole kidney and the diaphragm. In the final case, the entire dissection was completed with a transvaginal flexible gastroscope, without any transabdominal assistance whatsoever. This cadaveric study provided some thoughtful insights into the procedure: the cephalad aspect of the hilum and the upper-pole attachments are problematic areas for transvaginal dissection; extra long (bariatric) laparoscopic instruments can be useful; and flexible instruments can be considered if operative angles are suboptimal with rigid instruments.

Nephron-sparing surgery (Table 3)

Boylu *et al.* aimed to evaluate the feasibility of NOTES transgastric partial nephrectomy without hilar clamping in a porcine model.²⁷ A therapeutic gastroscope was introduced through the esophagus, and a 2-cm gastrotomy was performed using a diathermy electrocautery needle at the junction of the fundus and the proximal body. After incision of Gerota's fascia, the left kidney's upper pole was excised using the thulium laser without hilar dissection or clamping. An endoscopic wire loop was used to entrap and extract the specimen into the stomach. The gastroscope was subsequently withdrawn with the intact specimen. After hemostasis via reinsertion of the endoscope was ensured, metal clips were applied endoscopically to close the gastrotomy. Total operative time was 240 min. The final specimen was 3 cm in

Table 2 Experimental application of natural orifice transluminal endoscopic surgery (NOTES) in urology: Nephrectomy

Year	Author	Model	Access	Trans-abdominal port	Technical details	Drawbacks	Conclusions
2002	Gettman ¹⁰	Porcine, chronic	Transvaginal	Yes (in 5 of 6 cases)	Plastic fascial Amplatz dilators used as laparoscopic ports. Stiff end of a glide-wire inserted through a flexible cystoscope to facilitate dissection. 5-mm laparoscope and standard laparoscopic instruments used. Endo-GIA stapler to divide renal vessels and ureter.	Current technology makes the surgical technique cumbersome and difficult to complete.	Complete transvaginal nephrectomy is feasible in the porcine model using a single abdominal trocar for visualization.
2007	Clayman ²³	Porcine, acute	Transvaginal	Yes	Single 12-mm trocar placed in the midline. TransPort Multi-Lumen Operating Platform passed transvaginally. Dissection performed using an endoscopic needle-knife and a grasper for retraction. Renal artery and vein taken separately with Endo-GIA and titanium clips, respectively.	Challenging in providing retraction via the Transport, in obtaining an adequate angle of approach for tissue dissection, in securing the renal hilum.	Transvaginal NOTES nephrectomy can be accomplished in a porcine model.
2007	Lima ²¹	Porcine, acute	Transgastric Transvesical	No	Rigid ureteroscope through the vesical port. Double-channel endoscope introduced through the gastric port. Ultrasonic scissors and clips applicator introduced into the peritoneal cavity through the transvesical over tube and guided to the renal hilum using the gastroscopic image.	Ureterscopes far from the ideal design to be used in NOTES. Inability to safely close the gastrotomy. No available method for specimen removal.	NOTES nephrectomy using combined approach is feasible.
2008	Isariyawongse ²⁴	Porcine, acute	Transgastric Transvaginal	No	Transgastric endoscopic visualization guided the introduction of a second transvaginal endoscope through a novel laparoscopic trocar/endoscopic overtube device. Dissection of kidney with standard laparoscopic instruments through transvaginal trocar device. Vessels and ureter dissected and divided with transvaginal laparoscopic stapler.	Concerns regarding access, tissue manipulation and closure.	Combined transgastric and transvaginal approach to pure NOTES nephrectomy is feasible in the porcine model by using standard instruments.
2009	Habe ²⁵	Porcine, acute	Transvaginal	No	Peritoneal cavity accessed through the posterior fornix of the vagina. XL articulated endo-GIA stapler, inserted via separate vaginal incision and used for tissue retraction and hilum transection. Kidney extracted transvaginally.	Need for: designed vaginal port; suitable instrumentation to use through the gastroscope; articulated endocatch bag to facilitate single-handed entrapment of specimen.	Pure NOTES transvaginal nephrectomy feasible in the porcine model.
2009	Aron ²⁶	Cadaver	Transvaginal	Yes (in 2 of 3 cases)	3-channel R-port placed in the umbilicus to monitor the transvaginal procedure. 4-channel QuadPort placed through the posterior fornix into the peritoneal cavity. Regular laparoscopic instruments used transvaginally. Renal artery managed with clips, renal vein with stapler. Transvaginal extraction of specimen.	Angle of view at certain locations. Instrument clashing. Concerns about hemostasis, retraction and countertraction. Paucity of dedicated instruments.	Clinical NOTES nephrectomy remains a complex and challenging procedure.

Table 3 Experimental applications of natural orifice transluminal endoscopic surgery (NOTES): Other urological procedures

Year	Author	Procedure	Model	Access	Trans-abdominal port	Technical details	Drawbacks	Conclusions
2008	Crouzet ²⁸	Cryoablation	Porcine, acute	Transgastric Transvaginal	No	Dual-channel gastroscope; cryoablation probe introduced percutaneously.	Lack of suitable instrumentation to use gastroscope and of specific NOTES cryoprobe. Need for training to navigate flexible scope. Limited retraction with gastroscope.	Both approaches effective for NOTES renal cryoablation.
2009	Boylu ²⁷	Partial nephrectomy	Porcine, acute	Transgastric	No	Therapeutic gastroscope. Kidney excision with thulium laser without hilar dissection or clamping. Endoscopic wire loop to entrap and extract the specimen into the stomach. Metal clips to close gastrotomy.	Excessive smoke production. Lack of availability of an entrapment sac that can be introduced through the gastroscope.	NOTES transgastric partial nephrectomy with thulium laser feasible.
2009	Humphreys ²⁹	Radical prostatectomy	Cadaver	Transurethral	No	Use of 100W holmium laser, 550 mm end-firing laser fiber, 26F resectoscope, 7F laser stabilizing catheter, and continuous irrigation. Prostate delivered into the bladder. Rigid offset 27F nephroscope to perform the vesicourethral anastomosis using a laparoscopic suture device and knot pusher. Prostate tissue removed endoscopically with tissue morcellator.	Procedure done in absence of bleeding or physiological consequences. Technical limitations for vesicourethral anastomosis. Lack of intact specimen for pathology. Node dissection not possible.	NOTES-radical prostatectomy feasible in the cadaver model, but further testing is necessary before clinical application.
2009	Sawyer ³⁰	Partial cystectomy	Porcine, acute & chronic	Transurethral	No	Rigid cystoscope inserted into the bladder with CO ₂ insufflation. Endoscopic loop device. Grasping device. Bladder segment excised with electrocautery	Lack of triangulation, difficult orientation, and deficiencies of equipment.	Pure NOTES partial cystectomy technique possible in a porcine model using these approaches.
			Porcine, acute	Transgastric	No	gastrostomy made with a dual channel endoscope. Endoscopic loops. Endoscopic clips.		

size, and the estimated blood loss was 200 mL. A major drawback of the thulium laser was excessive smoke produced by vaporization of the tissue, which was minimized with the use of external irrigation.

Crouzet *et al.* presented their laboratory experience with NOTES renal cryoablation in pigs.²⁸ The procedure was performed with either a transgastric or transvaginal approach. Pneumoperitoneum was first obtained using a transabdominal Veress needle. In one case, the left kidney was approached with a dual-channel video gastroscope. The stomach wall was punctured using a needle-knife, a guide-wire was passed into the abdominal cavity and the access dilated by using a controlled radial expansion balloon. Under direct endoscopic vision, a cryoablation probe was introduced percutaneously into the anterior upper pole of the kidney. A transvaginal approach was used for the second case with the gastroscope introduced through the posterior fornix of the vagina. Overall, four procedures were performed successfully (mean operative time 83 min), with no intraoperative complications and no need for additional laparoscopic ports or open conversions. Stomach closure was tested and found to be watertight, and there were no abdominal or pelvic injuries found at autopsy.

Prostatectomy (Table 3)

Expanding the technique of holmium laser enucleation of the prostate (HoLEP), which is already used for the management of benign prostatic hyperplasia, Humphreys *et al.* reported their preliminary experience with the technical development of NOTES radical prostatectomy.²⁹ The procedure was performed on four male cadavers and a 100W holmium:YAG laser was used with a 550-mm end-firing laser fiber, a 26F resectoscope and a 7F laser stabilizing catheter. Resected prostate was delivered into the bladder. Neurovascular bundles were preserved bilaterally, as well as the dorsal venous complex, bladder neck, and external sphincter. A rigid offset 27F nephroscope was used to perform the vesicourethral anastomosis using a laparoscopic suture device and knot pusher in an interrupted fashion. The prostate tissue was removed endoscopically after morcellation.

Cystectomy (Table 3)

Although transvesical NOTES procedures have been described in several reports,²⁰ a NOTES approach for partial cystectomy has only recently been described by Sawyer *et al.* who described two completely pure NOTES techniques in a porcine model: a transurethral NOTES partial cystectomy and transgastric NOTES partial cystectomy.³⁰ Each technique provided a full-thickness bladder wall specimen. Endoscopic loop devices were used to remove the

desired part of the bladder and ideally to close the defect with subsequent reinforcement by endoscopic clips or by primary closure. The pure transurethral approach has the benefit of not entering the abdominal cavity. Potential disadvantages include inability to effectively access certain areas of the bladder (e.g. bladder floor) or to visualize extravescical structures as the endoscopic loop is closed with potential for injury to adjacent organs or blood vessels. Although the transgastric approach is more invasive than the pure transurethral approach, it does have several potential advantages as it allows access to areas that cannot be treated with the transurethral technique, lymph node sampling for staging purposes, excision of urachal tumors, and visualization of extravescical structures during endoscopic loop closure with reduced potential for injury. Further investigation is required to assess safety, efficacy, and adequate bladder healing. A suture closure device, such as described by Lima *et al.*³¹ may be helpful as the tagged sutures could be placed before excision either intravesically or extravescically.

Early human experience: From hybrid to pure urological NOTES (Table 4)

In 2007, Gettman and Blute successfully performed transvesical peritoneoscopy on a 56-year-old man before robotic prostatectomy. Under confirmatory standard laparoscopic guidance, an injection needle was used to perforate the bladder wall through which a flexible ureteroscope was passed. The peritoneal cavity was surveyed adequately and completely. The cystotomy was closed robotically before prostatectomy. No intraoperative or postoperative complications occurred.³⁸

Pure NOTES implies the use of empty organs as an access to the peritoneal cavity, completely avoiding skin incisions. Flexible NOTES instrumentation has been criticized as providing inadequate retraction with severe limitations in hemostatic devices. In order to overcome current technical limitations, investigators have combined NOTES with the conventional laparoscopic approach into the so-called hybrid NOTES technique.³⁹

Hybrid NOTES nephrectomy in humans was first described by Branco *et al.*³² They reported a case of transvaginal NOTES simple nephrectomy in a 23-year-old woman with right flank pain and recurrent urinary tract infection due to a nonfunctional right kidney. She underwent nephrectomy using the endoscope by vaginal access and two additional 5-mm trocars in the abdomen. Total procedure time was 170 min. Estimated blood loss was 350 cc. The patient had an uneventful postoperative course, being discharged 12 h after the procedure. The vagina has been proposed as a viable route for kidney retrieval following laparoscopic nephrectomies more than a decade ago.⁹ In 2002, Gill *et al.* reported the initial series employing this

Table 4 Human applications of natural orifice transluminal endoscopic surgery (NOTES) in urology: Reported cases

Author (ref.)	Publication year	Hybrid/Pure	Procedure (no. of cases)	NOTES access	Abdominal trocars	Special instruments	Mean operative time (min)	EBL (mL)	LOH (hours)	Complications (n)
Branco ³²	2008	Hybrid	Simple nephrectomy (1)	Transvaginal	2 × 5 mm	Flexible endoscope (Olympus); polypectomy snare (Olympus).	170	350	12	None
Castillo ³³	2009	Hybrid	Simple nephrectomy (2)	Transvaginal	1 × 10 mm 1 × 3 mm	Retrieval device (Applied)	80	200	36	None
Kaouk ³⁴	2009	Hybrid	Simple nephrectomy (1)	Transvaginal	1 × 5 mm	Triport (ASC), then switched to GelPort (Applied); Gastroscope; 5 mm 0° deflecting laparoscope (Olympus); articulating graspers and scissors (Novare); extra-long (65 cm) monopolar J-hook.	307	100	23	None
Alcaraz ³⁵	in press	Hybrid	Radical (10) and simple (4) nephrectomy	Transvaginal	1 × 10 mm 1 × 5 mm	Deflectable optic (Olympus); LigaSure device (Valleylab).	133	111	96	Colon injury (1)
Sotelo ³⁶	in press	Hybrid	Radical nephrectomy (1)	Transvaginal	Triport (Olympus)	Triport (ASC); 5-mm, 0° laparoscope with flexible tip; 30° endoeye laparoscope (Olympus); ultrasonic shears; monopolar J-hook.	210	1	150	Intra-abdominal collection (1)
Kaouk ³⁷	in press	Pure	Simple nephrectomy (1)	Transvaginal	None	GelPort (Applied), then switched to Triport (ASC); Gastroscope; 5-mm 0° deflecting laparoscope (Olympus); articulating graspers and scissors (Novare); extra-long (65 cm) monopolar J-hook.	420	50	19	None

EBL, estimated blood loss; LOH: length of hospital stay.

natural orifice for intact specimen extraction after standard four-port laparoscopic radical nephrectomy.⁴⁰ This access allows improved cosmetic results and likely minimizes morbidity when compared to extending an abdominal incision. The report by Branco *et al.* demonstrated the feasibility of hybrid NOTES nephrectomy with the vaginal access not only for specimen extraction but also as a working port.

More recently, Castillo *et al.* reported two cases of transvaginal hybrid NOTES simple nephrectomy with standard laparoscopic instruments.³³ There were no perioperative complications, and both patients were discharged 36 h after the surgery.

Alcaraz *et al.* presented their early experience with transvaginal NOTES-assisted laparoscopic nephrectomy in female patients with T1–T3a N0M0 renal cancer.³⁵ The authors used a vaginal access for a deflectable camera along with two additional abdominal trocars. One patient had a colon injury, which was not due to the transvaginal hybrid procedure as such, but was probably related to patient selection after previous open gynecological surgery. Difficulties in the procedure, specifically in retrieving the organ, were described in another patient (case 3) with a higher body mass index (BMI).

Sotelo and colleagues reported a multi-institutional experience with hybrid NOTES transvaginal nephrectomy in four patients.³⁶ Various operative steps were developed experimentally in the first three clinical cases, which were electively converted to standard laparoscopy because of rectal injury during vaginal entry, of failure to progress, and of gradual bleeding during upper-pole dissection after transvaginal hilar control, respectively. The one remaining patient underwent successful hybrid NOTES transvaginal nephrectomy without conversion to standard laparoscopy. A multichannel single port was placed transumbilically through which dissection and hilar division was performed. The patient required readmission and drainage of an intra-abdominal abscess. The authors concluded that although NOTES transvaginal nephrectomy is feasible in selected cases, significant refinement in operative technique and instrumentation is required.

Hybrid NOTES nephrectomy reported by Sotelo *et al.* differs from the Branco and Alcaraz series in that the transvaginal approach was used to perform the majority of intraoperative dissections, and the patient had no extra-umbilical skin incisions whatsoever. Still, complete or pure NOTES should involve no transabdominal port placement at all.

Further minimizing the use of accessory transabdominal ports, in 2009 Kaouk and colleagues at the Cleveland Clinic successfully performed the world's first transvaginal NOTES nephrectomy on a 57-year-old woman with a non-functioning right kidney.³⁴ The procedure was successfully completed, with all the operative steps performed transvaginally. Dense pelvic adhesions from a prior hysterectomy necessitated the use of only one 5-mm umbilical port during

vaginal port placement and for retraction of the ascending colon during division of the renal hilum. No intraoperative complications occurred. Operative time was 307 min, with 124 min dedicated to vaginal port placement and 183 min dedicated to adhesiolysis and nephrectomy. Duration of hospitalization was <1 day with return to normal activities within 1 week.

Later, the same group was able to successfully perform a pure NOTES transvaginal nephrectomy in a 58-year-old woman who presented with an atrophic right kidney.³⁷ A blunt-tipped trocar was introduced transvaginally into the peritoneal cavity and pneumoperitoneum was established. Using a standard flexible video gastroscope the abdominal cavity was explored transvaginally and minimal pelvic adhesions were encountered. The GelPort device (Applied Medical, Rancho Santa Margarita, CA, USA) was deployed across the vaginal incision. The depth of the patient's vagina prevented reliable positioning of the inner ring of the GelPort, accounting for a small but manageable air leak. Two 10-mm standard trocars and one 5-mm standard trocar were placed across the GelPort through which a 5-mm deflecting laparoscope (Olympus Surgical, Orangeburg, NJ, USA) and 45-cm articulating graspers and scissors (Novare Surgical, Cupertino, CA, USA) were placed. While developing the plane between the retroperitoneum and the mesentery of the colon, there was a displacement of the GelPort device, resulting in significant air leak. For this reason, the GelPort was exchanged for the multichannel TriPort (Olympus Surgical, Orangeburg, NJ, USA). Before reaching the hilum, given the patient's comparatively long vaginal length, dissection through the TriPort could not be continued and therefore the GelPort was reinserted again. After exposing the hilum, an endovascular stapler was fired across the renal vein and renal artery. The remaining posterior and upper pole attachments were taken down using an extra-long (65 cm) monopolar J-hook with care taken to spare the adrenal gland. The kidney was placed into a retrieval bag and brought out through the existing vaginal incision. There was no perioperative complication.

LESS: Technical challenges and currently available platforms and instrumentation

Despite being an evolution of standard laparoscopic surgery, LESS defies the most basic tenets of laparoscopy including triangulation of working instruments and external spacing to decrease intra- and extracorporeal clashing (Fig. 1).⁴¹

Several multichannel platforms have been developed and used for LESS in urological surgery (Fig. 2). Standard laparoscopic instrumentation may be used in this setting but often articulating or curved instruments can be beneficial for providing triangulation with reduced clashing of instruments⁴² (Table 5). In some cases this may require

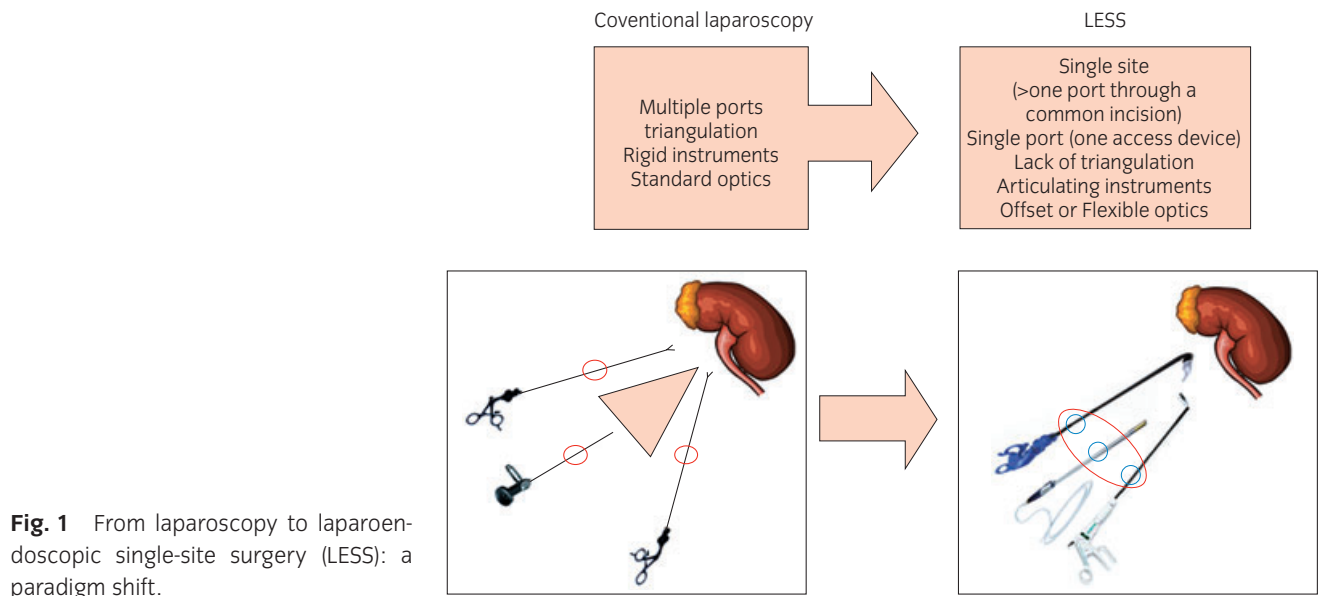


Fig. 1 From laparoscopy to laparoendoscopic single-site surgery (LESS): a paradigm shift.




Fig. 2 Purpose-built instruments for laparoendoscopic single-site surgery: (a) Triport, Olympus; (b) SILS port, Covidien; (c) Airseal, Surgique; (d) X-cone, Storz; (e) Gelpoint, Applied Medical; (f) Pre-bent instrument; (g) Autonomy Laparoangle, Cambridge Endo; (h) Real hand, Novare surgical.

Table 5 Laparoendoscopic single-site surgery (LESS) toolbox

	Company	Features	Comment
Access device			
<i>Triport</i>	Olympus	Flexible multichannel valve; up to 3 instruments (1 × 12 mm; 2 × 5 mm); covered with an elastomer; Hassan introduction.	Adapts to size of incision and abdominal wall thickness; fragile when using 12-mm instruments; lubrication required; constrictive outer ring; gas leaking; usable only once for insertion.
<i>Quadport</i>		Flexible multichannel valve; up to 4 instruments (1 × 15 mm, 1 × 10 mm, 2 × 5 mm); covered with an elastomer; Hassan introduction.	
<i>SILS port</i>	Covidien	Flexible platform; up to 3 individual ports and instruments; Hassan introduction.	Easy exchange of different sized ports; difficult suturing for robotic LESS; difficult to use with large abdominal wall.
<i>GelPOINT</i>	Applied Medical	Three components: GelSeal providing PseudoAbdomen platform; Alexis wound retractor; self-retaining trocars; Hassan introduction.	Larger outer working profile for enhanced triangulation; adapts to size of incision and abdominal wall thickness; fragile.
<i>Airseal</i>	Surgiquest	Oval valve-less cannula with invisible pressure barrier	Stable CO ₂ pressure; multiple instruments insertion; rigid; noisy.
<i>AnchorPort</i>		Low-profile ports of various lengths placed in close proximity	Anchoring system; optical entry; rigid; less freedom of movement.
<i>X-cone</i>	Storz	Device with 3 working channels (5 or 12 mm); Hassan introduction.	Simple design; re-usable; rigid; less expensive.
Scope			
<i>Endocamaleon</i>	Storz	10-mm scope with adjusting knob for selection of viewing direction	Can be used with different access platforms; rigid.
<i>Extra long</i>		5-mm 30° scope	Cost; off-setting of instrumentation; rigid; scope not off instrument axis.
<i>Eyemax,</i>	Wolf	5-10-mm, 0-30° digital scope	In-line design; excellent image quality; rigid; scope not off instrument axis.
<i>Ideal eyes</i>	Stryker	5-mm extra length rigid scope	Cost; off-setting of instrumentation; rigid.
<i>Ideal eyes HD</i>		10-mm articulating scope	High-quality off-axis image; unstable tip; skilled assistant required; cost.
<i>Endoeye LTF</i>	Olympus	Articulating HD 5/10-mm scope.	All-in-one; off-axis image; HD image quality; unstable tip; skilled assistant required; cost.
<i>Endoeye HD</i>		5-mm 30° digital scope	All-in-one; low profile; HD image quality; careful handling required; cost.
Instrument			
<i>Roticulator</i>	Covidien	5-mm instruments with monopolar cautery (dissector, grasper, scissors)	Cost; standard profile; fewer degrees of freedom; external clashing.
<i>Prebent</i>	various	Pre-shaped curved instruments	Re-usable; cost-effective; fewer degrees of freedom.
<i>Real Hand</i>	Novare	Hand-held 5-mm instruments (scissors, dissector, needle-holder, hook, grasper, etc)	Full range of motion mirroring hand instruments; low profile; not intuitive locking mechanism; cost.
<i>Autonomy laparo-angle</i>	Cambridge Endo	Hand-held 5-mm instruments (scissors, dissector, needle-holder, hook, grasper)	Full articulation and high degree of freedom mirroring hand's motions; bulky handles; cost.

HD, high-definition.

counterintuitive movements when the surgeon's instruments may cross each other. The use of digital in-line laparoscopes with only one cord in parallel is also beneficial for LESS as additional cords with perpendicular insertion into the scope interfere with other instruments and the surgeon's movements when space is at a premium.

One potential disadvantage of LESS is related to the costs of single-port devices, articulating instruments and flexible cameras. Cost comparisons between single and multiple port laparoscopy have not yet been reported. In the meantime, authors demonstrated the feasibility of urological LESS procedures without special devices, which can be an option when greater expense is prohibitive.⁴³

LESS: Experimental development

Any new technology or technique requires a thorough inquiry of its utility, safety and reproducibility. In the case of LESS, experimental studies have been published addressing its safety, cosmetic benefits and superior pain profile.

Raman and colleagues presented a pioneering study of LESS for nephrectomy that included seven successful experimental nephrectomies on pigs followed by three clinical procedures.⁴⁴

Before embarking on their first clinical procedure, Barret *et al.* reported their experience with LESS extraperitoneal radical prostatectomy in a cadaver model, using both standard and articulated laparoscopic instruments.⁴⁵

More recently, Boylu *et al.* determined the feasibility, instrumentation, and learning curve for LESS partial nephrectomy in a pig model. The investigators performed 10 transumbilical procedures using the R-Port multichannel port, a 5-mm flexible laparoscope, and custom-engineered articulating needle drivers, graspers, and scissors. Either the upper or lower pole of the kidney was scored and excised after placing a bulldog clamp on the renal pedicle. Bolsters were prepared with absorbable hemostat, placed at the site of excision, and secured with polyglactin sutures. Modified suturing techniques were developed to achieve reconstruction in a small working space. There was no need for an additional port for triangulation. The total ischemia time decreased from 50 min in the first case to 27 min in the last. The authors concluded that the procedure is feasible, however they also recognized that further refinement of instrumentation and techniques is needed.⁴⁶

LESS: Current clinical experience

Advances in instrument technology, together with increasing experience in NOTES and LESS approaches, have driven the transition from porcine models to the human.

The first two cases of single-port surgery in urology were reported by Rane *et al.* in abstract form, at the 2007 World Congress of Endourology.⁴⁷ Subsequently, the first multi-

trocar single-incision transumbilical nephrectomy was reported by Raman *et al.* Following an initial porcine feasibility demonstration, three human nephrectomies were performed: two for benign nonfunction and one for clear-cell carcinoma.⁴⁴

Since those pioneering reports, several other clinical series have been reported by a few groups worldwide with an estimated cumulative clinical experience of more than 300 cases. Thus, nowadays the entire spectrum of urological procedures both for upper and lower urinary tract diseases has been described and shown to be feasible, including advanced reconstructive procedures and major extirpative ones.

Upper urinary tract surgery (Table 6)

Patients undergoing any laparoscopic upper-tract procedure, whether for purposes of oncological resection, anatomic reconstruction, or directed organ donation, may potentially benefit from LESS because of decreased skin incisions and resultant improved cosmetic outcomes.

The first single-port transumbilical nephrectomy was reported by Desai *et al.* in 2007.⁵⁷ Specialized instrumentation included the R-port; a 5-mm, 30° endoscope and curved laparoscopic graspers. The procedure was successfully completed in 3.6 h without any extra-umbilical skin incisions. In the same report the authors described a single-port transumbilical pyeloplasty. A 2-mm needlescopic grasper was used to facilitate suturing. No functional outcomes were reported.

Rane *et al.* from the UK presented a series of five LESS simple nephrectomies.⁵³ Three of the procedures were carried out with the umbilicus as the port of entry. All cases were completed uneventfully. The operative duration was 45–150 min and blood loss was negligible. There were no conversions to conventional multi-port laparoscopy or open surgery. Minor complications occurred in two patients.

From Germany, Stolzenburg *et al.* recently reported their LESS radical nephrectomy technique in 10 patients (BMI ≤ 30).⁵⁴ All cases were successfully accomplished (two right-sided tumors and eight left-sided tumors; tumor diameter 4–8 cm). One bleeding complication occurred. Limitations regarding the intraoperative instrument ergonomics and the requirement for ambidexterity of the surgeon were noted.

Gill *et al.* first reported the successful completion of single-port transumbilical live-donor nephrectomy in four patients.⁵⁰ The authors used the R-Port and pneumoperitoneum was achieved using a 2-mm Veress needle port inserted via a skin needle puncture. This was used to insert a needlescopic grasper to aid tissue handling. The donor kidney was pre-entrapped and extracted transumbilically. All cases were completed successfully without complication with a 3–4-cm incision that was nearly concealed after extraction.

Table 6 Laparoendoscopic single-site surgery (LESS) series (≥ 3 cases) for upper urinary tract surgery: Worldwide overview

Author	Year of publication	Country	SP/Sl	Procedure (no. of cases)	Access device	Conversion to laparoscopy (n)	Articulating instruments	Mean operative time (min)	EBL (mL)	LOH (days)	Complications (n)
Goel & Kaouk ⁴⁸	2008	USA	SP	Cryotherapy (6)	Unix-port	0	Yes	170	83	2.3	None
Aron ⁴⁹	2008		SP	Partial nephrectomy (5)	R-port	1	Yes	270	150	3	Postoperative hemorrhage and pulmonary embolism (1)
Gill ⁵⁰	2008		SP	Donor nephrectomy (4)	R-port	0	Yes	200	50	n/a	None
Kaouk ⁵¹	2009		SP	Partial nephrectomy (5)	Unix port	1	Yes	160	420	3.2	Focally positive margin (1)
Rais-Bahrami ⁵²	2009		SI	Donor nephrectomy (4); Radical nephrectomy (2); Partial nephrectomy (3); Pyeloplasty (2).	Standard trocars	0	Yes	162	104	2.4	Delayed gross hematuria (1)
Rane ⁵³	2009	UK	SP	Simple nephrectomy (5)	Triport	0	Yes	103	60	2.3	Port bruising (1); pyrexia (1).
Stolzenburg ⁵⁴	2009	Germany	SP	Radical nephrectomy (10)	Triport	0	Yes	146.4	202	n/a	Bleeding requiring transfusion (1)
Ryu ⁵⁵	2009	South Korea	SP	Renal cyst decortication (5); adrenalectomy (2); nephroureterectomy (2); nephrectomy (3); ureterolithotomy (2).	Home-made device	0	Yes	156	403	6.5	Wound dehiscence (1); bleeding (1).
Ganpule ⁵⁶	In press	India	SP	Donor nephrectomy (13)	Quadport/Triport	11	Yes	176.9	158	3	None

EBL, estimated blood loss; LOH: length of hospital stay; n/a, not available; SI, single incision; SP, single port.

More recently, Ganpule *et al.* from India reported a series of 13 patients undergoing LESS donor nephrectomy.⁵⁶ The Quadport/Triport was inserted through an incision in the umbilicus. After securing the hilum, the graft was brought near the umbilical extraction site with a grasper inserted through an extra 3- or 5-mm port and easily retrieved with the help of two fingers. Mean warm ischemia time was 6.79 min. Urine output was prompt in all cases. In 11 of the 13 cases an extra 3- or 5-mm port was used.

Most investigators have remained even more careful and selective in applying LESS for oncological conditions. Ponsky *et al.* reported LESS radical nephrectomy for an 8-cm renal tumor with intact specimen extraction.⁵⁸ They placed three standard laparoscopic ports through a GelPort that was seated in a 7-cm paramedian incision. Standard laparoscopic instruments were used for dissection and total operative time was 96 min with minimal blood loss. The patient was discharged on postoperative day 2 without complications.

The first series of single-port cryotherapy was reported by Goel and Kaouk.⁴⁸ Patients with localized small renal mass (<3 cm) ineligible for partial or radical nephrectomy were included. Patients with multiple abdominal surgeries or solitary kidneys were excluded. The procedure was performed in two patients undergoing a transperitoneal approach for anterior tumors, and four patients had retroperitoneoscopic single-port cryotherapy with the multilumen port positioned at the tip of the 12th rib for posterior tumors. Mean tumor size was 2.6 cm. Although instrument clashing was frequent, cryotherapy was feasible without intraoperative complication, and mean hospital stay was 2.3 days. All cases were completed without complication or conversion.

Laparoscopic partial nephrectomy represents a technically demanding procedure under the best of circumstances. Only two series have been reported so far describing LESS partial nephrectomy. Aron *et al.* reported successful LESS partial nephrectomy in five patients (median tumor size 3 cm) using the TriPort.⁴⁹ In all cases a 2-mm grasper was used through a separate entry to assist in suture closure of the renal defect. A patient required the placement of an extra 5-mm port. The median warm ischemia time was 20 min (range, 11–29 min). One patient required blood transfusion and angioembolization. Subsequently, Kaouk and Goel reported their experience with seven LESS partial nephrectomies, including the use of robotic assistance in two cases.⁵¹ One patient required conversion to conventional laparoscopy with the placement of additional ports for control of bleeding after tumor resection. The lone complication was a focally positive margin on final pathology, which was initially read as negative on intraoperative frozen section.

Recently, Rais-Baharami *et al.* presented a total of 11 renal LESS procedures.⁵² All were performed through a single operative site using a 5-mm flexible-tip laparoscope and flexible working instruments. In another report, the

same group described in more detail their technique of donor nephrectomy through a Pfannenstiel incision.⁵⁹ Through a 5-cm Pfannenstiel incision, three 5-mm ports were placed in a triangular manner. After the kidney was placed in the entrapment sac, the anterior rectus fascia between the two midline ports was incised and the kidney was removed.

Increasing experience, and the proven safety and feasibility of single-incision surgery has allowed the expansion of indications to include complex reconstructive procedures such as bilateral pyeloplasty, ileal interposition, ureteral reimplantation and psoas hitch. Desai *et al.* reported these procedures as well as the extension of the single-port incision for extracorporeal bowel anastomosis and ileal reconfiguration without any complications.⁶⁰

One report described single-port laparoscopic urological surgery via the retroperitoneal approach using the Alexis wound retractor with flexible laparoscopic instrumentation.⁵⁵ Fourteen patients underwent LESS for various urological diseases. All cases were completed without conversion to standard laparoscopic or open surgery. There were no major intraoperative complications, but wound dehiscence and bleeding were noted in two patients.

Pelvic surgery (Table 7)

LESS radical prostatectomy was performed by Kaouk *et al.* in four patients, all with T1c prostate cancer, no previous pelvic surgery and BMI < 35.⁶¹ Flexible and pre-bent instruments were inserted through a Uni-X port placed in the umbilicus. An endoscopic camera with flexible tip provided visualization of the operative field and extracorporeal knot tying was performed for the anastomosis. Positive surgical margins were detected in two patients with extracapsular extension. After 18 weeks, all patients required one or no pad for continence daily. A rectourethral fistula was diagnosed in one case.

Desai *et al.* reported their early experience with the so-called single-port transvesical enucleation of the prostate (STEP) technique in three patients with large-volume benign prostatic hyperplasia. The single-port device (R-Port) was introduced percutaneously into the bladder through a 2.5-cm incision under cystoscopic guidance. After establishing pneumovesicum, the adenoma was enucleated in its entirety transvesically under laparoscopic visualization using standard and articulating laparoscopic instrumentation. The adenoma was extracted through the solitary skin and bladder incision after bivalving the prostate lobes within the bladder.⁶²

Sotelo *et al.* also detailed the technique of the LESS simple prostatectomy for benign prostatic hyperplasia using a single multilumen port inserted through a solitary 2.5-cm intra-umbilical incision. Standard ultrasonic shears and needle drivers, articulating scissors and specifically

Table 7 Laparoendoscopic single-site surgery (LESS) for pelvic surgery: Reported outcomes

Author	Year of publication	Procedure (n)	No. of cases	Access device	Additional ports	Articulating instruments	Mean operative time (min)	EBL (mL)	LOH (days)	Complications (n)
Kaouk ⁶¹	2008	Radical prostatectomy	4	Unix port	No	Yes	258	287	2.5	Positive margins (2); Rectourethral fistula (1).
Desai ⁶²	2008	Simple prostatectomy	3	R-port	No	Yes	198	500	1.6	Bowel injury (1)
Sotelo ⁶³	2009	Simple prostatectomy	1	Tri-port	No	Yes	120	200	2	None
Noguera ⁶⁴	2009	Augmentation enterocystoplasty	1	Quad-port	No	Yes	300	<100	6	None
White ⁶⁵	2009	Sacral colpopexy	10	Unix port	No	Yes	162	47.5	1.5	De novo stress incontinence (2); cystocele (1).

EBL, estimated blood loss; LOH: length of hospital stay.

designed bent grasping instruments facilitated dissection and suturing. No complications occurred.⁶³

A case of LESS subtotal cystectomy and augmentation enterocystoplasty performed through a single multichannel transumbilical port in a patient with neurogenic bladder was also reported from the same group.⁶⁴ Additional instruments included the 5-mm video laparoscope, SonoSurge, and flexible scissors. The ileal segment was exteriorized through the single port by detaching the valve, the ileal pouch was created and bowel continuity was restored extracorporeally. The vesico-ileal anastomosis was performed laparoscopically. The use of the larger diameter port facilitated extracorporeal bowel reconstruction.

More recently, White *et al.* performed a retrospective cohort study to determine the efficacy and safety of single-port laparoscopic abdominal sacral colpopexy for the treatment of female pelvic organ prolapse. Although the study's follow up was limited, the procedure appeared to be comparable to the laparoscopic and robotic approaches in terms of efficacy but with superior cosmesis.⁶⁵

Cumulative series

To date, two large series of urological LESS procedures have been reported. Desai *et al.* described their experience with 100 LESS procedures including simple, partial, radical and donor nephrectomies, nephroureterectomies, renal cyst decortications, adrenalectomy, pyeloplasty, transvesical simple prostatectomy and other procedures such as uretero-neocystostomy, ileal ureter, hysterectomy and mesh sling removal.⁶⁶

White *et al.* also reported experience with their first 100 LESS urological procedures.⁶⁷ A broad range of techniques proved to be feasible while complication rates including bleeding and conversion to open surgery were similar to those of conventional laparoscopy. At the time of writing the present review, over 140 LESS procedures have been performed at the Cleveland Clinic, which represents the largest single-center experience with LESS urological surgery reported herein so far (unpubl. data).

LESS vs conventional laparoscopy (Table 8)

The first case-control study comparing LESS with the conventional laparoscopic surgery was reported by Raman *et al.* in 2009.⁶⁸ They compared 11 LESS nephrectomies with 22 conventional laparoscopic nephrectomies. No differences in operative time, postoperative hospital stay, narcotic analgesic use, complication rate, or transfusion requirement were observed between the two techniques. However, estimated blood loss was significantly lower in the LESS group than in the conventional laparoscopy group. The authors concluded that the superiority of LESS nephrectomy over standard laparoscopy was limited to a mere subjective cosmetic advantage.

Table 8 Laparoendoscopic single-site surgery (LESS) vs laparoscopy (Lap): Major outcome parameters from published series

Author (ref.)	Procedure (n)	Study design	SP/SI	Access device	Additional trocar	Special instruments (type)	Scope	No. of cases (LESS vs Lap) (n)	Conversion (n)	Mean OT (min)	Mean EBL (mL)	Mean LOH (hours)	Complications (type), n
Raman ⁶⁸	Simple & Radical Nephrectomy	Case-control	SI	3 × 5-mm trocars	No	Yes (Articulating)	Rigid, 45°, 5 mm	11	0	122	20	49	0
								22	0	125	100	53	0
Tracy ⁶⁹	Pyeloplasty	Case-control	SI	3 × 5-mm trocars	Yes	Yes (Articulating)	Rigid, 45°, 5 mm	15	1*	202	35	77	5 (hematuria, urine leak, clot obstruction)
								28	0	257	85	74	6 (hematuria, nausea/vomiting, urine leak)
Jeong ⁷⁰	Adrenalectomy	Case-control	SP	Home-made device	No	Yes (Reticulator)	Flexible, 0°, 5 mm	9	1	169.2	177.8	77	1 (small bowel injury)
								17	1	144.5	204.7	84	1 (postoperative bleeding)
Canes ⁷¹	Donor Nephrectomy	Case-control	SP	R-port	No	Yes (Articulating)	Rigid, 30°, 5 mm	18	1*	269	108	72	2 (corneal abrasion, allograft thrombosis)
								17	0	239	141	84	0
Raybourn ⁷²	Simple Nephrectomy	Case-control	SP	R-port	Only in 2 cases	Yes (Articulating)	Flexible, 0°, 5 mm	11	0	151	51	32	2 (port site bruising, pyrexia)
								10	0	165	68	26	1 (prolonged ileus)

*Excluded from the analysis. EBL, estimated blood loss; LOH, length of hospital stay; OT, operative time; SI, single incision; SP, single port.

Starting from the consideration that in this first study half of the LESS patients had a nephrectomy for malignancy, necessitating extension of the initial umbilical incision for specimen extraction, the same group of investigators speculated that this may have blunted the potential benefit of LESS.

Therefore they addressed a reconstructive procedure, such as pyeloplasty, which requires less dissection than nephrectomy and is usually performed in a younger population. Fourteen patients undergoing LESS pyeloplasty were matched 2:1 with regard to age and side of surgery to a previous cohort of 28 patients who underwent conventional laparoscopic pyeloplasty. Intracorporeal suturing was aided through a 5-mm instrument placed in the eventual drain site. Median operative times and median estimated blood loss were significantly lower in patients undergoing LESS, albeit these findings need some consideration. The majority of control patients underwent cystoscopy with retrograde stent placement, which requires repositioning of the patient and additional equipment when compared with antegrade stent placement performed in all LESS cases. In addition, more patients in the laparoscopic cohort had previous endoscopic management of the disease, which may have made dissection more difficult, contributing to increased overall operative time. Moreover, the small statistical difference in estimated blood loss was probably not clinically significant, being a function of inaccuracies in measuring this parameter. No difference was noted between the two groups in regard to length of stay, morphine equivalents required and minor or major postoperative complications. There were three major complications in the LESS cohort (21%) compared with the 10% of patients in the laparoscopic cohort. Although this rate of complications with LESS pyeloplasty is higher than mature laparoscopic or robotic series reported, all major complications occurred in the initial cases, likely reflecting the early learning curve.⁶⁹

Raybourn *et al.* matched a total of 11 patients undergoing LESS laparoscopic simple nephrectomy with a group of 10 patients who previously underwent simple nephrectomies. All LESS simple nephrectomy procedures were completed uneventfully. There were no intraoperative complications in the LESS group. Postoperative complications included pyrexia and port site bruising in two patients. Operative time showed no significant difference between the two groups as well as narcotic analgesia requirements.⁷²

Jeong *et al.* recently described the first study comparing LESS vs laparoscopy in the treatment of benign adrenal adenoma.⁷⁰ Nine patients undergoing LESS adrenalectomy were compared with 17 patients undergoing conventional laparoscopic adrenalectomy. Controls were matched for age, sex, surgical indications, and tumor size. No significant differences in the mean operative time, blood loss, or postoperative hospital stay were observed between the groups. However, postoperative pain, as measured by the number of

days of intravenous patient controlled anesthesia use, was significantly lower in the LESS group (0.9 vs 1.9 days). Perioperative complications were similar between the two groups. The authors concluded that LESS adrenalectomy for benign adrenal adenoma is comparable to the conventional laparoscopic approach in terms of perioperative parameters but demonstrating more desirable cosmetic outcomes.

Finally, Canes *et al.* reported the first retrospective matched-pair comparison of LESS to standard laparoscopic live-donor nephrectomy.⁷¹ The LESS procedure was performed through an intra-umbilical multichannel port. A 5-mm rigid laparoscope with integrated camera head was used for visualization. Standard laparoscopic instruments as well as curved/articulating instruments were used as necessary. The kidney was extracted through a slightly extended umbilical incision. One right-sided donor was converted to standard laparoscopy and excluded from analysis. Mean warm ischemia time was significantly longer in the LESS group (3 vs 6.1 min), even if allograft function was comparable between groups at 3 months. Patients undergoing LESS donor nephrectomy had similar in-hospital analgesic requirements and mean visual analog scores at discharge. After discharge, their convalescence, as evaluated by using visual analog pain scores and questionnaires containing patient-reported time to recovery end-points was faster, including days on oral pain medication, days off work and days to full physical recovery.

Overall, the quality of evidence of all the above-mentioned studies remains low, most of them being retrospective, thus susceptible to biases inherent in retrospective studies and based on limited samples. Thus, further comparative analyses are still needed in order to identify the significant benefits of LESS. In this respect, well-designed prospective trials are awaited to compare LESS to conventional laparoscopy, including appropriate quality-of-life and outcome analyses, especially in terms of cosmetic benefit by using validated patient-reported-outcome instruments.

Robotics: The missing link towards scarless urological surgery?

The recognized benefits of the da Vinci robotic system (Intuitive Surgical, Sunnyvale, CA, USA) over conventional laparoscopy include superior ergonomics, optical magnification of the operative field within direct control of the console surgeon, enhanced surgeon dexterity within the field of view, and precision of surgical manipulation.⁷³

In 2008, Box *et al.* first reported a hybrid NOTES robotic-assisted nephrectomy in a porcine model with a combined transvaginal and transcolonic access.⁷⁴ Two 12-mm laparoscopic ports for robotic arms were placed into the abdomen via the vagina and the colon. The camera was introduced through an abdominal port and held by an assistant. After division of the renal pedicle using an endovascular stapler,

the kidney was placed in an entrapment sac and extracted via the vagina. Interestingly, access-site closure was not performed. The procedure was completed in 150 min. The authors pointed out that even if currently the robotic system offers many potential advantages for NOTES, such as a stable platform from which to work, improved comfort for the surgeon, increased precision, and the ability to suture, technical difficulties still need to be overcome, including robotic arm collisions, limited triangulation despite the EndoWrist instruments, and counterintuitive camera angles.

Haber *et al.* adopted a different approach toward robotic NOTES in the porcine model, placing the robotic camera lens and one arm through the umbilicus, with the other robotic arm inserted through the vagina.⁷⁵ Thus, the robot allowed simultaneous umbilical and vaginal access to perform various kidney procedures. The authors were able to show that robotic NOTES pyeloplasty, partial nephrectomy, and radical nephrectomy are feasible and safe in the porcine model, underscoring that incorporating robotics into NOTES will significantly enhance intracorporeal suturing.

Based on their early clinical experience with a novel percutaneous transvesical approach for simple prostatectomy, using a novel single-port device inserted percutaneously into the bladder, Desai *et al.* assessed the technical feasibility of performing transvesical robotic radical prostatectomy in a cadaver model with the aid of the da Vinci-S robotic system.⁷⁶ A four-lumen, single-port device (Quadport) was inserted into the bladder lumen through a 3-cm transverse skin incision. The da Vinci system was docked to the Quadport utilizing two 8-mm trocars for the robotic arms and a 12-mm trocar for the camera, and the final port was left for bedside assistance. There was no need for additional ports or conversion to standard laparoscopy. Clashing of the da Vinci arms represented the primary technical difficulty with the single-port procedure. Inability to perform lymph node dissection remains a significant obstacle for this approach.

Attempting novel modifications to port and robotic instrument configuration, Kaouk *et al.* reported in 2009 the first successful series of single-port robotic procedures in humans, including radical prostatectomy, dismembered pyeloplasty and radical nephrectomy.⁷⁷ A robotic 12-mm scope and 5-mm grasper were introduced through a multichannel single port (R-Port), while an additional 5-mm or 8-mm robotic port was introduced through the same umbilical incision (2 cm) alongside the multichannel port to facilitate entry of robotic instruments. The radical prostatectomy was completed in 5 h, with 45 min spent for the anastomosis. Blood loss was 250 mL, hospital stay was 36 h, pathology reported negative margins. The pyeloplasty was completed in 4.5 h, with minimal blood loss and hospital stay of 50 h. The radical nephrectomy was performed for a 5.7-cm interpoloid mass and completed in 2.5 h with 200 mL blood loss and 48 h hospital stay. The authors noted an

improved facility for intracorporeal dissecting and suturing due to robotic instrument articulation and stability.

Together with their experience in a cadaver model, Barret *et al.* also reported their experience with a hybrid LESS robotic-assisted radical prostatectomy in a single patient.⁴⁵ They placed two 8-mm robotic ports and a 12-mm port for the robotic camera into a 4-cm umbilical incision. An additional 5-mm port was placed at the right lower abdomen. The procedure was completed in 150 min, including 5 min for dorsal vein control and 30 min for the anastomosis. Neurovascular bundles were preserved, there was no intraoperative complication, margins were negative.

Our group also reported an initial experience with single-port robotic partial nephrectomy in two patients without conversions or complications.⁵¹ A multichannel port (Triport) was utilized. Pediatric 5-mm robotic instruments, including graspers, electrocautery hook, and harmonic scalpel, were used for tumor exposure and excision. A 30° robotic lens placed in the upward configuration minimized clashing between the scope and instruments.

In another study, we reported robotic LESS using a GelPort as the access platform.⁷⁸ Four clinical procedures were performed, including two pyeloplasties, one radical nephrectomy, and one partial nephrectomy. A 12-mm port for the camera was placed through the GelPort followed by two 8-mm robotic ports and an additional 12-mm port for assistance. For both pyeloplasty cases, mean operative time was 235 min and estimated blood loss minimal. For the patient undergoing radical nephrectomy for a 5.1-cm renal tumor, operative time was 200 min and blood loss 250 mL. The final patient underwent partial nephrectomy without renal hilar clamping for an 11-cm angiomyolipoma with an operative time of 180 min and blood loss of 600 mL. All procedures were successfully completed. The partial nephrectomy patient required one unit of packed red blood cell transfusion. The use of the GelPort as an access platform provided adequate spacing and flexibility of port placement and acceptable access to the surgical field for the assistant. Incision size required is still slightly larger than with laparoscopic instruments as the robot has not been specifically designed for single-site use. A newly available port known as GelPOINT (Applied Medical, Rancho Santa Margarita, California, USA) is similar to the GelPort, but smaller, without perforations in the gel cap, with an insufflation port on the side of the device, and a suture attached to the wound protection apparatus to allow for easier removal.

At the time of writing this paper, 25 robotic single-port procedures have been performed at the Cleveland Clinic including renal and pelvic surgeries and representing 16% of the entire group of patients undergoing LESS (unpubl. data).

As already mentioned, early clinical experiences with LESS have clearly pointed out limitations related to technical constraints including clashing of instruments and limited

operating space. In an attempt to overcome these limitations, Crouzet *et al.* recently presented their initial translational animal study in which a low-profile robot was used to assist one surgeon to complete LESS reconstructive and extirpative renal procedures.⁷⁹ After making a 2-cm umbilical incision, through which a single port was placed and pneumoperitoneum obtained, an operative 5-mm 30° rigid high-definition laparoscope was introduced and securely held using a novel low-profile robot under foot and/or voice control (Light Endoscope Holder Robot, LER, EndoControl, Grenoble, France). Using articulating instruments, each pig had bilateral reconstructive partial nephrectomy and bilateral pyeloplasty before a completion bilateral radical nephrectomy. There were no intraoperative complications and there was no need for additional ports to be placed. They concluded that the combination of a single-port, a robotic endoscope holder and articulated instruments operated by one surgeon is feasible and it allows more room for the surgeon.

Future perspectives in scarless urological surgery

The safe and successful development of NOTES has the potential to create a paradigm shift in surgery. Preliminary investigative research in this area of minimally invasive surgery has demonstrated that rigorous laboratory work is still clearly imperative. Fundamental technical issues related to NOTES that are yet to be addressed include secure closure of the entry portal, limiting infection from intraluminal contents, and spatial orientation of the flexible endoscopy equipment.

The most appropriate application of NOTES in urology will depend on future studies of the therapeutic aspects of this technology for specific urological diseases.

Training

One of the main challenges in the future application of NOTES in urology will be the training of residents and postgraduate urologists in this new technique. The learning curve for NOTES may be quite steep and challenging, particularly in the short term while technologies and techniques are evolving toward a known standard. It is likely that early in the development of NOTES, only academic centers and selected private practices with high patient volumes would be able to achieve a satisfactory level of skill with NOTES procedures. A unique characteristic of NOTES is that the required expertise potentially crosses several disciplines. The NOTES surgeon may be required to have in-depth knowledge of flexible endoscopy, laparoscopy, and different perspectives on abdominal anatomy. Urological surgeons to some extent have a diverse operative experience from their

training and clinical practice, placing them in a favorable position for developing and adopting this new technology.

Although the optimal method of acquiring skills in NOTES and LESS is yet to be clearly determined, experience with laparoscopic urological surgery may serve as a good template. Initially, surgeons will very likely work together to develop techniques and define indications, thereby training and teaching each other. NOTES curricula have already been proposed but are far from being established as even the most experienced NOTES surgeons in the world are probably still in an early learning curve.^{80,81}

Technology

Besides training, NOSCAR identified several potential barriers to safe clinical implementation of NOTES, including difficulties with access, spatial orientation, surgical performance, and management of complications.³ Potential adjuncts that may limit these challenges are technologies such as image-guided systems and soft-tissue navigation.⁸²

NOTES is a rapidly developing new technology that depends on collaborative support from engineers, translational clinical researchers, and surgeons. The construction of novel instruments specifically designed for NOTES should assist in overcoming many present limitations. Because the da Vinci system was not designed to operate effectively within the particular constraint of the NOTES environment, instrument collision and lack of flexibility are currently limiting factors. New robotic systems, including flexible robots, *in vivo* miniature robots, or a combination therein might bring NOTES to its full potential in the future.⁸³

Similarly, even if the addition of the da Vinci system to LESS has improved limitations experienced with standard LESS, a reduction in the range of motion of the instruments still exists.⁸⁴ Despite some adjustments to the present da Vinci robotic system to make a LESS approach possible, we still do not have a perfect system and are in the infancy of robotic single-site and especially NOTES surgery. The currently available robot remains bulky and not specifically designed for these techniques.

Besides robotics, ongoing technological advances in the development of novel platforms specific for LESS, such as the magnetic anchoring and guidance system (MAGS), are being developed and will likely assist in overcoming current limitations. MAGS consists of a moveable magnet- or needle-lockable platform that is positioned intra-abdominally and stabilized by an external magnetic element placed on the abdominal skin.⁸⁵ The platform is introduced via a single access port and allows unrestricted intra-abdominal movement and spacing of surgical instruments. Thus, MAGS has the potential to realize the benefits of LESS or NOTES surgery by restoring triangulation for the surgeon, reducing instrument collision, and overcoming

cumbersome hurdles associated with flexible endoscopic platforms. Recently, Cadeddu *et al.* presented the first clinical report of LESS procedures performed utilizing a novel MAGS camera in place of a conventional laparoscope or endoscope.⁸⁶ Technology such as this that looks beyond the commonly held principles of flexible instrumentation and endoscopy may likely accelerate the development of NOTES.

Conclusion

For some time the concept of increasingly minimally invasive surgery has been solely the subject of science fiction. The development of laparoscopy and focal ablative therapies eventually convinced many that ‘scarless’ surgery may now be conceptually possible. Nevertheless there has been very little progress toward this goal until the last 5 years, during which time the adoption of LESS principles and techniques has exploded and the earliest clinical experience with NOTES has taken place. A true revolution in technology and industry support is imminently upon us and an exciting era of discovery and change has begun. It cannot be overemphasized that critical appraisal of results and scrupulous determination of benefits will be very important as experience grows.

References

- Pemberton RJ, Tolley DA, van Velthoven RF. Prevention and management of complications in urological laparoscopic port site placement. *Eur. Urol.* 2006; **50**: 958–68.
- Gettman MT, Box G, Averch T *et al.* Consensus statement on natural orifice transluminal endoscopic surgery and single-incision laparoscopic surgery: heralding a new era in urology? *Eur. Urol.* 2008; **53**: 1117–20.
- Rattner D, Kalloo A, ASGE/SAGES working group. ASGE/SAGES working group on natural orifice transluminal endoscopic surgery. *Surg. Endosc.* 2006; **20**: 329.
- Pearl JP, Ponsky JL. Natural orifice transluminal endoscopic surgery: a critical review. *J. Gastrointest. Surg.* 2008; **12**: 1293–300.
- Box G, Averch T, Cadeddu J *et al.* Nomenclature of natural orifice transluminal endoscopic surgery (NOTES) and laparoendoscopic single-site surgery (LESS) procedures in urology. *J. Endourol.* 2008; **22**: 2575–81.
- Kaloo AN, Singh VK, Jagannath SB *et al.* Flexible transgastric peritoneoscopy: a novel approach to diagnostic and therapeutic interventions in the peritoneal cavity. *Gastrointest. Endosc.* 2004; **60**: 114–17.
- Rao GV, Reddy N. Transgastric appendectomy in humans. Oral presentation at: Society of American Gastrointestinal and Endoscopic Surgeons (SAGES) Conference; 26–29 April 2006; Dallas, TX, USA.
- Marescaux J, Dallemagne B, Perretta S *et al.* Surgery without scars: report of transluminal cholecystectomy in a human being. *Arch. Surg.* 2007; **142**: 823–6.
- Breda G, Silvestre P, Giunta A, Xaus D, Tamai A, Gherardi L. Laparoscopic nephrectomy with vaginal delivery of the intact kidney. *Eur. Urol.* 1993; **24**: 116–17.
- Gettman MT, Lotan Y, Napper CA, Cadeddu JA. Transvaginal laparoscopic nephrectomy: development and feasibility in the porcine model. *Urology* 2002; **59**: 446–50.
- Lima E, Rolanda C, Pego J *et al.* Transvesical endoscopic peritoneoscopy: a novel 5 mm port for intra-abdominal scarless surgery. *J. Urol.* 2006; **176**: 802–5.
- White WM, Haber GP, Doerr MJ, Gettman M. Natural orifice transluminal endoscopic surgery. *Urol. Clin. North Am.* 2009; **36**: 147–55.vii.
- Box GN, Bessler M, Clayman RV. Transvaginal access: current experience and potential implications for urologic applications. *J. Endourol.* 2009; **23**: 753–7.
- Bardaro SJ, Swanstrom L. Development of advanced endoscopes for natural orifice transluminal endoscopic surgery (NOTES). *Minimally Invasive Ther.* 2006; **15**: 378–83.
- Rolanda C, Lima E, Pêgo JM *et al.* Third-generation cholecystectomy by natural orifices: transgastric and transvesical combined approach. *Gastrointest. Endosc.* 2007; **65**: 111–17 (with video).
- Sclabas GM, Swain P, Swanstrom LL. Endoluminal methods for gastrotomy closure in natural orifice transenteric surgery (NOTES). *Surg. Innov.* 2006; **13**: 23–30.
- Tunuguntla HS, Gousse AE. Female sexual dysfunction following vaginal surgery: a review. *J. Urol.* 2006; **175**: 439.
- Shin EJ, Kalloo AN. Transcolonic NOTES: current experience and potential implications for urologic applications. *J. Endourol.* 2009; **23**: 743–6.
- Lima E, Henriques-Coelho T, Rolanda C *et al.* Transvesical thoracoscopy: a natural orifice transluminal endoscopic approach for thoracic surgery. *Surg. Endosc.* 2007; **21**: 854–8.
- Granberg CF, Frank I, Gettman MT. Transvesical NOTES: current experience and potential implications for urologic applications. *J. Endourol.* 2009; **23**: 747–52.
- Lima E, Rolanda C, Pego JM *et al.* Third-generation nephrectomy by natural orifice transluminal endoscopic surgery. *J. Urol.* 2007; **178**: 2648–54.
- Lima E, Rolanda C, Correia-Pinto J. NOTES performed using multiple ports of entry: current experience and potential implications for urologic applications. *J. Endourol.* 2009; **23**: 759–64.
- Clayman RV, Box GN, Abraham JB *et al.* Rapid communication: transvaginal single-port NOTES nephrectomy: initial laboratory experience. *J. Endourol.* 2007; **21**: 640–4.
- Isariyawongse JP, McGee MF, Rosen MJ, Cherullo EE, Ponsky LE. Pure natural orifice transluminal endoscopic surgery (NOTES) nephrectomy using standard laparoscopic instruments in the porcine model. *J. Endourol.* 2008; **22**: 1087–91.

- 25 Haber GP, Brethauer S, Crouzet S *et al.* Pure natural orifice transluminal endoscopic surgery for transvaginal nephrectomy in the porcine model. *BJU Int.* 2009; **104**: 1260–4.
- 26 Aron M, Berger A, Stein RJ *et al.* Transvaginal nephrectomy with a multichannel laparoscopic port: a cadaver study. *BJU Int.* 2009; **103**: 1537–41.
- 27 Boylu U, Oommen M, Joshi V, Thomas R, Lee BR. Natural orifice transluminal endoscopic surgery (NOTES) partial nephrectomy in a porcine model. *Surg. Endosc.* 2009; **24**: 485–9.
- 28 Crouzet S, Haber GP, Kamoi K *et al.* Natural orifice transluminal endoscopic surgery (NOTES) renal cryoablation in a porcine model. *BJU Int.* 2008; **102**: 1715–18.
- 29 Humphreys MR, Krambeck AE, Andrews PE, Castle EP, Lingeman JE. Natural orifice transluminal endoscopic surgical radical prostatectomy: proof of concept. *J. Endourol.* 2009; **23**: 669–75.
- 30 Sawyer MD, Cherullo EE, Elmunzer BJ, Schomisch S, Ponsky LE. Pure natural orifice transluminal endoscopic surgery partial cystectomy: intravesical transurethral and extravesical transgastric techniques in a porcine model. *Urology* 2009; **74**: 1049–53.
- 31 Lima E, Rolanda C, Osório L *et al.* Endoscopic Closure of Transmural Bladder Wall Perforations. *Eur. Urol.* 2008; **56**: 151–7.
- 32 Branco AW, Branco Filho AJ, Kondo W *et al.* Hybrid transvaginal nephrectomy. *Eur. Urol.* 2008; **53**: 1290–4.
- 33 Castillo OA, Vidal-Mora I, Campos R *et al.* Laparoscopic simple nephrectomy with transvaginal notes assistance and the use of standard laparoscopic instruments. *Actas Urol. Esp.* 2009; **33**: 767–70.
- 34 Kaouk JH, White WM, Goel RK *et al.* NOTES transvaginal nephrectomy: first human experience. *Urology* 2009; **74**: 5–8.
- 35 Alcaraz A, Peri L, Molina A *et al.* Feasibility of transvaginal NOTES-assisted laparoscopic nephrectomy. *Eur. Urol.* 2009; **57**: 233–7.
- 36 Sotelo R, de Andrade R, Fernandez G *et al.* NOTES hybrid transvaginal radical nephrectomy for tumor: stepwise progression toward a first successful clinical case. *Eur. Urol.* 2010; **57**: 138–144.
- 37 Kaouk JH, Haber GP, Goel RK *et al.* Pure Natural Orifice Transluminal Endoscopic Surgery (NOTES) transvaginal nephrectomy. *Eur. Urol.* 2009; doi:10.1016/j.eururo.2009.10.027.
- 38 Gettman MT, Blute ML. Transvesical peritoneoscopy: initial clinical evaluation of the bladder as a portal for natural orifice transluminal endoscopic surgery. *Mayo Clin. Proc.* 2007; **82**: 843–5.
- 39 Shih SP, Kantsevov SV, Kalloo AN *et al.* Hybrid minimally invasive surgery—a bridge between laparoscopic and transluminal surgery. *Surg. Endosc.* 2007; **21**: 1450–3.
- 40 Gill IS, Cherullo EE, Meraney AM *et al.* Vaginal extraction of the intact specimen following laparoscopic radical nephrectomy. *J. Urol.* 2002; **167**: 238–41.
- 41 Canes D, Desai MM, Aron M *et al.* Transumbilical single-port surgery: evolution and current status. *Eur. Urol.* 2008; **54**: 1020–30.
- 42 Kommu S, Rane A. Devices for laparoscopic single-site surgery in urology. *Expert. Rev. Med. Devices* 2009; **6**: 95–103.
- 43 Branco AW, Kondo W, Stunitz L, Filho AJB, de George AM. Transumbilical laparoscopic urological surgery: are special devices strictly necessary? *BJU Int.* 2009; **104**: 1136–42.
- 44 Raman JD, Bensalah K, Bagrodia A, Stern JM, Cadeddu JA. Laboratory and clinical development of single keyhole umbilical nephrectomy. *Urology* 2007; **70**: 1039–42.
- 45 Barret E, Sanchez-Salas R, Kasraeian A *et al.* A transition to laparoendoscopic single-site surgery (LESS) radical prostatectomy: human cadaver experimental and initial clinical experience. *J. Endourol.* 2009; **23**: 135–40.
- 46 Boylu U, Oommen M, Thomas R, Lee BR. Transumbilical single-port laparoscopic partial nephrectomy in a pig model. *BJU Int.* 2009; doi:10.1111/j.1464-410X.2009.08916.x.
- 47 Rane A, Kommu S, Eddy B, Bonadio F, Rao P, Rao P. Clinical evaluation of a novel laparoscopic port (R-port) and evolution of the single laparoscopic port procedure (SLiPP). *J. Endourol.* 2007; **21** (Suppl 1): A22–3.
- 48 Goel RK, Kaouk JH. Single port access renal cryoablation (SPARC): a new approach. *Eur. Urol.* 2008; **53**: 1204–9.
- 49 Aron M, Canes D, Desai MM *et al.* Transumbilical single-port laparoscopic partial nephrectomy. *BJU Int.* 2008; **103**: 516–21.
- 50 Gill IS, Canes D, Aron M *et al.* Single port transumbilical (E-NOTES) donor nephrectomy. *J. Urol.* 2008; **180**: 637–41.
- 51 Kaouk JH, Goel RK. Single-port laparoscopic and robotic partial nephrectomy. *Eur. Urol.* 2009; 1163–70.
- 52 Rais-Bahrami S, Montag S, Atalla MA, Andonian S, Kavoussi LR, Richstone L. Laparoendoscopic single-site surgery of the kidney with no accessory trocars: an initial experience. *J. Endourol.* 2009; **23**: 1319–24.
- 53 Rane A, Ahmed S, Kommu SS, Anderson CJ, Rimington PD. Single-port ‘scarless’ laparoscopic nephrectomies: the United Kingdom experience. *BJU Int.* **104**: 230–3.
- 54 Stolzenburg JU, Kallidonis P, Hellawell G *et al.* Technique of laparoscopic-endoscopic single-site surgery radical nephrectomy. *Eur. Urol.* 2009; **56**: 644–50.
- 55 Ryu DS, Park WJ, Oh TH. Retroperitoneal laparoendoscopic single-site surgery in urology: initial experience. *J. Endourol.* 2009; **23**: 1857–62.
- 56 Ganpule AP, Dhawan DR, Kurien A *et al.* Laparoendoscopic single-site donor nephrectomy: a single-center experience. *Urology* 2009; **74**: 1238–40.
- 57 Desai MM, Rao PP, Aron M *et al.* Scarless single port transumbilical nephrectomy and pyeloplasty: first clinical report. *BJU Int.* 2008; **101**: 83–8.
- 58 Ponsky LE, Cherullo EE, Sawyer M *et al.* Single access site laparoscopic radical nephrectomy: initial clinical experience. *J. Endourol.* 2008; **22**: 663–6.

- 59 Andonian S, Herati AS, Atalla MA, Rais-Bahrami S, Richstone L, Kavoussi LR. Laparoendoscopic Single-Site Pfannenstiel Donor Nephrectomy. *Urology* 2009; **75**: 9–12.
- 60 Desai MM, Stein R, Rao P *et al.* Embryonic natural orifice transumbilical endoscopic surgery (E-NOTES) for advanced reconstruction: initial experience. *Urology* 2009; **73**: 182–7.
- 61 Kaouk JH, Goel RK, Haber GP, Crouzet S, Desai MM, Gill IS. Single-port laparoscopic radical prostatectomy. *Urology* 2008; **72**: 1190–3.
- 62 Desai MM, Aron M, Canes D *et al.* Single-port transvesical simple prostatectomy: initial clinical report. *Urology* 2008; **72**: 960–5.
- 63 Sotelo RJ, Astigueta JC, Desai MM *et al.* Laparoendoscopic single-site surgery simple prostatectomy: initial report. *Urology* 2009; **74**: 626–30.
- 64 Noguera RJ, Astigueta JC, Carmona O *et al.* Laparoscopic augmentation enterocystoplasty through a single trocar. *Urology* 2009; **73**: 1371–4.
- 65 White WM, Goel RK, Swartz MA, Moore C, Rackley RR, Kaouk JH. Single-port laparoscopic abdominal sacral colpopexy: initial experience and comparative outcomes. *Urology* 2009; **74**: 1008–12.
- 66 Desai MM, Berger AK, Brandina R *et al.* Laparoendoscopic single-site surgery: initial hundred patients. *Urology* 2009; **74**: 805–12.
- 67 White WM, Haber GP, Goel RK, Crouzet S, Stein RJ, Kaouk JH. Single-port urological surgery: single-center experience with the first 100 cases. *Urology* 2009; **74**: 801–4.
- 68 Raman JD, Bagrodia A, Cadeddu JA. Single-incision, umbilical laparoscopic versus conventional laparoscopic nephrectomy: a comparison of perioperative outcomes and short-term measures of convalescence. *Eur. Urol.* 2009; **55**: 1198–204.
- 69 Tracy CR, Raman JD, Bagrodia A, Cadeddu JA. Perioperative outcomes in patients undergoing conventional laparoscopic versus laparoendoscopic single-site pyeloplasty. *Urology* 2009; **74**: 1029–34.
- 70 Jeong BC, Park YH, Han DH, Kim HH. Laparoendoscopic single-site and conventional laparoscopic adrenalectomy: a matched case-control study. *J. Endourol.* 2009; **23**: 1957–60.
- 71 Canes D, Berger A, Aron M *et al.* Laparo-Endoscopic Single Site (LESS) versus standard laparoscopic left donor nephrectomy: matched-pair comparison. *Eur. Urol.* 2009; doi: 10.1016/j.eururo.2009.07.023.
- 72 Raybourn JH III, Rane A, Sundaram CP. Laparoendoscopic single-site surgery for nephrectomy as a feasible alternative to traditional laparoscopy. *Urology* 2009; **75**: 100–3.
- 73 Rane A, Tan GY, Tewari AK. Laparoendoscopic single-site surgery in urology: is robotics the missing link? *BJU Int.* 2009; **104**: 1041–6.
- 74 Box GN, Lee HJ, Santos RJ *et al.* Rapid communication: robot-assisted NOTES nephrectomy: initial report. *J. Endourol.* 2008; **22**: 503–6.
- 75 Haber GP, Crouzet S, Kamoi K *et al.* Robotic NOTES (natural orifice transluminal endoscopic surgery) in reconstructive urology: initial laboratory experience. *Urology* 2008; **71**: 996–1000.
- 76 Desai MM, Aron M, Berger A *et al.* Transvesical robotic radical prostatectomy. *BJU Int.* 2008; **102**: 1666–9.
- 77 Kaouk JH, Goel RK, Haber GP, Crouzet S, Stein RJ. Robotic single-port transumbilical surgery in humans: initial report. *BJU Int.* 2008; **103**: 366–9.
- 78 Stein RJ, White WM, Goel RK *et al.* Robotic laparoendoscopic single-site surgery using GelPort as the access platform. *Eur. Urol.* 2009; doi: 10.1016/j.eururo.2009.03.054.
- 79 Crouzet S, Haber GP, White WM, Kamoi K, Goel RK, Kaouk JH. Single-port, single-operator-light endoscopic robot-assisted laparoscopic urology: pilot study in a pig model. *BJU Int.* 2009; doi:10.1111/j.1464-410X.2009.08955.x.
- 80 Gamboa AJ, Box GN, Preminger GM, McDougall EM. NOTES: education and training. *J. Endourol.* 2009; **23**: 813–19.
- 81 Müller EM, Cavazzola LT, Machado Grossi JV, Mariano MB, Morales C, Brun M. Training for laparoendoscopic single-site surgery (LESS). *Int. J. Surg.* 2009; doi:10.1016/j.ijssu.2009.11.003.
- 82 Rassweiler J, Baumhauer M, Weickert U *et al.* The role of imaging and navigation for natural orifice transluminal endoscopic surgery. *J. Endourol.* 2009; **23**: 793–802.
- 83 Canes D, Lehman AC, Farritor SM, Oleynikov D, Desai MM. The future of NOTES instrumentation: flexible robotics and in vivo minirobots. *J. Endourol.* 2009; **23**: 787–92.
- 84 White MA, Haber GP, Kaouk JH. Robotic single-site surgery. *Curr. Opin. Urol.* 2010; **20**: 86–91.
- 85 Zeltser IS, Bergs R, Fernandez R *et al.* Single trocar laparoscopic nephrectomy using magnetic anchoring and guidance system in the porcine model. *J. Urol.* 2007; **178**: 288–91.
- 86 Cadeddu J, Fernandez R, Desai M *et al.* Novel magnetically guided intra-abdominal camera to facilitate laparoendoscopic single-site surgery: initial human experience. *Surg. Endosc.* 2009; **23**: 1894–9.