

CLINICAL STUDY

Cushing's disease in childhood as the first manifestation of multiple endocrine neoplasia syndrome type 1

M Rix¹, N T Hertel³, F C Nielsen⁵, B B Jacobsen³, A S Hoejberg¹, K Brixen⁴, J Hangaard⁶ and J P Kroustrup²¹Department of Paediatrics, ²Department of Endocrinology, Aalborg University Hospital, 9000 Aalborg, Denmark, ³Department of Paediatrics,⁴Department of Endocrinology, Odense University Hospital, 5000 Odense, Denmark, ⁵Department of Clinical Chemistry, H:S Rigshospitalet,2100 Copenhagen, Denmark and ⁶Department of Endocrinology, Svendborg Hospital, 5700 Svendborg, Denmark

(Correspondence should be addressed to M Rix; Email: mariane.rix@dadlnet.dk)

Abstract

Objective: To describe three cases of Cushing's disease in children with multiple endocrine neoplasia type 1 (MEN1), as clinical manifestations of MEN1 are very rare in childhood.

Design and methods: A retrospective review of three cases of Cushing's disease diagnosed between 1997 and 1999. Genetic screening for *MEN1* gene mutation was performed in each patient.

Results: An ACTH-secreting microadenoma was diagnosed in three children, aged 11–13 years, presenting with growth retardation and weight gain over a period of 3–4 years. All patients had successful transsphenoidal adenomectomies. Primary hyperparathyroidism was subsequently diagnosed in two of the patients, and in the monozygotic twin of one of the patients. A new mutation in the *MEN1* gene (Tyr351His) was identified in two of the patients and the affected members of their families. In the third patient a *de novo* *MEN1* gene mutation (Leu444Pro) was found.

Conclusions: MEN1 has to be considered in all children with tumours of the pituitary gland, and in those presenting with primary hyperparathyroidism. The children and their families should be advised to seek genetic counselling. We suggest that careful growth records be kept for children at risk of developing inherited MEN1 and, in the event of a decelerating growth rate, further diagnostic evaluation be undertaken with regards to ACTH-secreting pituitary tumours.

European Journal of Endocrinology 151 709–715

Introduction

Multiple endocrine neoplasia type 1 (MEN1) is an autosomal dominant disorder characterised by primary hyperparathyroidism in association with endocrine enteropancreatic tumours and anterior pituitary adenomas, but manifestations as carcinoid tumours, adrenal adenoma and lipoma are also seen (1). The occurrence of two of the MEN1-related endocrine tumours is sufficient to make the clinical diagnosis. The gene responsible for MEN1 was identified in 1997 (2). It is located on chromosome 11q13 and encodes menin, which acts as a tumour-suppressor by altering JunD-mediated transcription (3–5). The penetrance of *MEN1* gene mutations is complete: all patients who carry the mutation develop the disease. The phenotype is highly variable and no correlation of a phenotypic expression with a particular mutation has been found to date (6, 7). Carriers of a *MEN1* gene mutation may benefit from periodic clinical screening (8).

Primary hyperparathyroidism is the most common presenting manifestation, with a prevalence approaching 100% (1, 9, 10), whereas pituitary tumours have

been described in more than 50% of series of MEN1 families (11–13). Mechanisms involving neoplastic transformations of specific pituitary cell types and stimulation of their cell growth have been suggested (4, 14). Primarily prolactinomas and, less frequently, non-functional tumours and growth hormone (GH)-producing tumours are found, whereas corticotrophin (ACTH)-producing tumours are very rare (9, 13, 15, 16).

Cushing's disease has not previously been reported in children with MEN1. We present the cases of three children aged 11–13 years who were admitted to hospital with clinical suspicion of Cushing's disease, in whom *MEN1* gene mutations were subsequently found.

Materials and methods

Dexamethasone suppression test

Two control days were followed by 48 h when oral dexamethasone 0.5 mg was given every 6 h, followed by 2 mg every 6 h for 48 h. During all 6 days, serum cortisol, plasma ACTH and urinary free cortisol were

measured. A 50% decrease in serum cortisol values during the test was interpreted as suggestive of pituitary-dependent Cushing's disease. Normal persons suppress serum cortisol to less than 50 nmol/l.

Bilateral inferior petrosal sinus sampling

Bilateral inferior petrosal sinus sampling (IPSS) and peripheral vein sampling for measurements of ACTH were performed before and after administration of corticotrophin releasing hormone (CRH) in a dose of 1 µg/kg i.v. A central-to-peripheral ACTH ratio and the ratio of ACTH concentrations in the two sinuses were used for diagnosis and lateralisation (17).

Mutation analysis

The *menin* gene was screened for mutations by PCR amplification of individual exons as described by Chandrasekharappa *et al.* (2), followed by direct sequencing in both orientations, with fluorescent dye terminators on an ABI 377 or 310 DNA sequencer (Applied Biosystems, Foster City, CA). All mutations were confirmed by analysis of two independently collected blood samples.

Routine analyses

Normal ranges for free urinary cortisol excretion, plasma ACTH, ionised serum calcium, and intact parathyroid hormone (PTH) are given for each patient, because different reference values were used at the two clinics involved.

Case reports

Informed consent to participation in the study was obtained from all the patients and their parents.

Patient 1

A 13-year-old boy, a twin, was admitted to our paediatric clinic because of clinical signs suggestive of Cushing's syndrome. In childhood his appearance and growth had been identical to those of his monozygotic twin brother, but from the age of 9 years his growth rate had decreased, with a loss of height from -0.7 to -2.1 S.D.; in addition, truncal obesity was observed in comparison with his brother (Figs 1, 2). The boy complained of headaches, muscle weakness and fatigability. A computed tomography (CT) scan of the cerebrum performed 10 months before his admission to the paediatric unit was interpreted as normal.

At admission to hospital, the boy presented with moon face, truncal obesity, thin limbs, acne and pubic hair Tanner stage IV (PH 4) in spite of an infantile testes volume (2 ml). His height was 141 cm, his weight 39.4 kg and his blood pressure 141/82 mmHg. Serum Na, K and blood glucose values were normal.

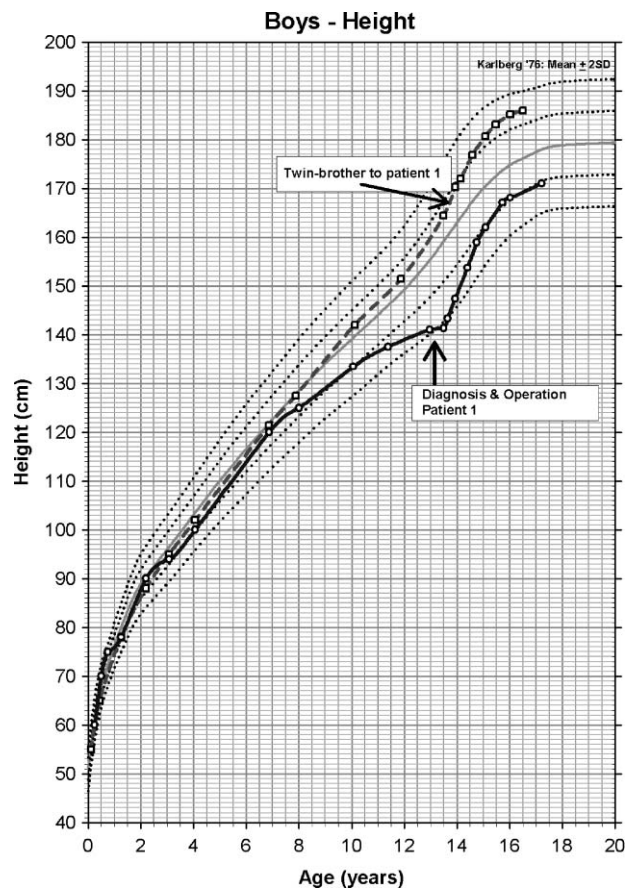


Figure 1 Growth chart illustrating the growth of the proband patient 1 (—) and his twin brother (---). The onset of treatment is indicated by an arrow.

Urinary excretion of free cortisol was increased (1160 nmol/24 h; normal range 37–341 nmol/24 h). No diurnal rhythms of serum cortisol (0800 h 781 nmol/l, 2200 h 698 nmol/l) and plasma ACTH (0800 h 58 ng/l, 2200 h 60 ng/l; normal range 10–60 ng/l) were observed. A dexamethasone suppression test demonstrated suppression of serum cortisol to 66 nmol/l and of urinary free cortisol excretion to 59 nmol respectively. A clonidine stimulation test showed decreased secretion of GH (peak value 7.9 mU/l, normal >15 mU/l) and a luteinizing hormone-releasing hormone (LHRH) test showed prepubertal luteinizing hormone and follicle-stimulating hormone responses. Thyroid hormone axis and serum prolactin concentrations were normal. Bone age was normal for chronological age.

Cerebral magnetic resonance imaging (MRI) revealed a pituitary microadenoma. MRI of the abdomen and chest radiograph was normal. Transsphenoidal surgery (TSS) was performed. Histological investigation confirmed the diagnosis of an ACTH-producing pituitary adenoma. Postoperative substitution with hydrocortisone was gradually decreased over the following 10 months; catch-up growth and normal

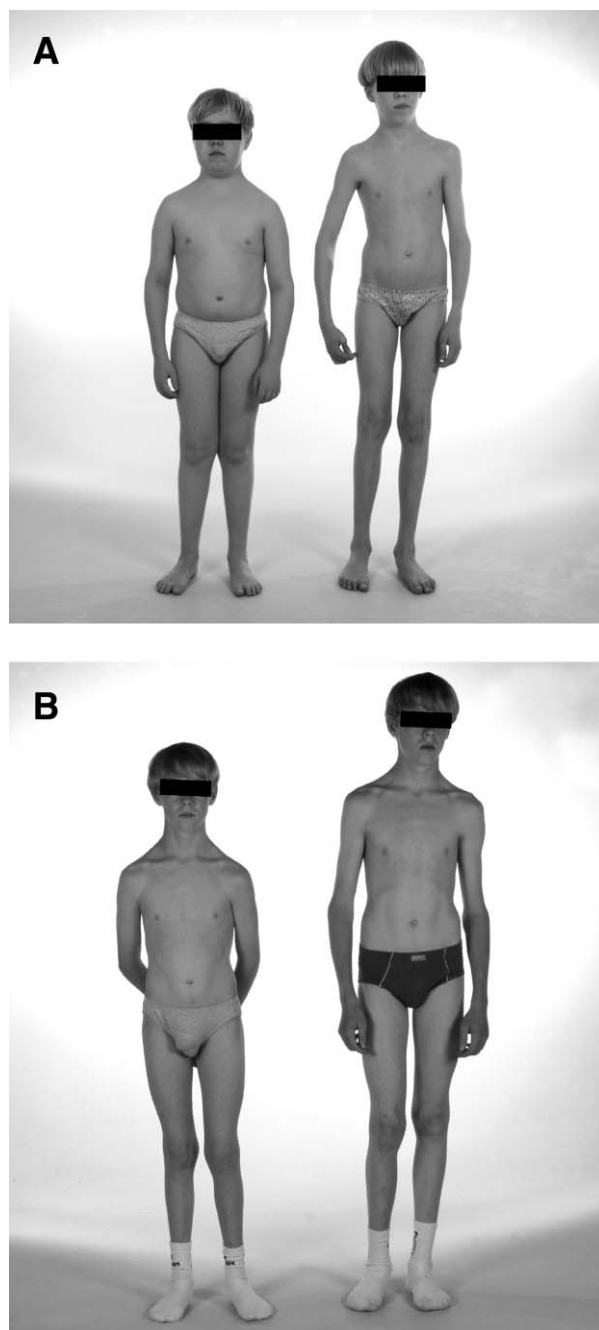


Figure 2 The proband patient 1 and his twin brother, before and 1 year after surgery.

pubertal development were observed, and pituitary function recovered.

Primary hyperparathyroidism was subsequently diagnosed on the basis of increased ionised serum calcium (1.40 nmol/l; normal range 1.18–1.38 nmol/l) and increased PTH (8.7 pmol/l; normal range 1.3–7.6 pmol/l). Investigation of the kidneys showed a large stone (0.7 × 1 cm) in the right kidney and two small stones in the left kidney. Final height at the age

of 18 years was 171 cm, shorter than the target height of 179 cm and considerably shorter than that of his twin brother (186 cm).

Family history The boy's father suffered from primary hyperparathyroidism and renal stones, and the paternal grandmother had undergone surgery for primary hyperparathyroidism. In addition, distant relatives had been reported to suffer from primary hyperparathyroidism, renal stones and gastropancreatic tumours, suggesting a large family with MEN1 syndrome.

Screening for hypercalcaemia was performed in the asymptomatic twin brother, and hyperparathyroidism was revealed, with increased ionised serum calcium (1.41 nmol/l) and serum PTH (7.7 pmol/l). An abdominal CT scan revealed a large renal stone (2 × 1 cm) located at the left pelvis. Subtotal parathyroidectomy leaving half a gland was performed. The histology confirmed parathyroid hyperplasia. Subsequently, extracorporeal shock wave lithotripsy treatment of the renal stone was performed because of development of secondary hydronephrosis. Cushing's disease or other MEN1-related symptoms were not demonstrated.

Screening for hypercalcaemia in an 8-year-old sister was normal, and at the age of 15 years she still had no MEN1-related symptoms.

DNA-testing Sequencing of the menin gene showed that the proband carried a heterozygous T → C transition in exon 8, leading to substitution of tyrosine to a histidine at position 351 in the menin protein (Tyr351His). The mutation was also detected in the monozygotic twin and the father. No mutation was present in the patient's sister. The missense mutation has not previously been functionally characterised but, from the large pedigree, it can be calculated that it segregates with the disease phenotype with a logarithm of odds score of 3, indicating that it is tightly linked to the disease (AC Jaeger and LJ Friis-Hansen, personal communication).

Patient 2

An 11½-year-old girl was admitted to our paediatric clinic because of clinical signs of Cushing's syndrome, including weight gain from −0.5 s.d. to +0.8 s.d. and decreasing growth rate, with loss in height from 0 s.d. to −1.6 s.d. over a period of 3–4 years (Fig. 3). She complained of headache and dyspnoea during exercise. At the time of her admission she presented with truncal adipositas, moon face and hirsutism, but no striae. Pubertal staging was B3 and PH3 a.m. (Tanner). Her height was 136 cm, her weight 40.4 kg, and her blood pressure 122/80 mmHg. Bone age was normal. Serum Na, K and fasting blood glucose concentrations were normal. Urinary free cortisol excretion was increased (491 nmol/24 h; normal

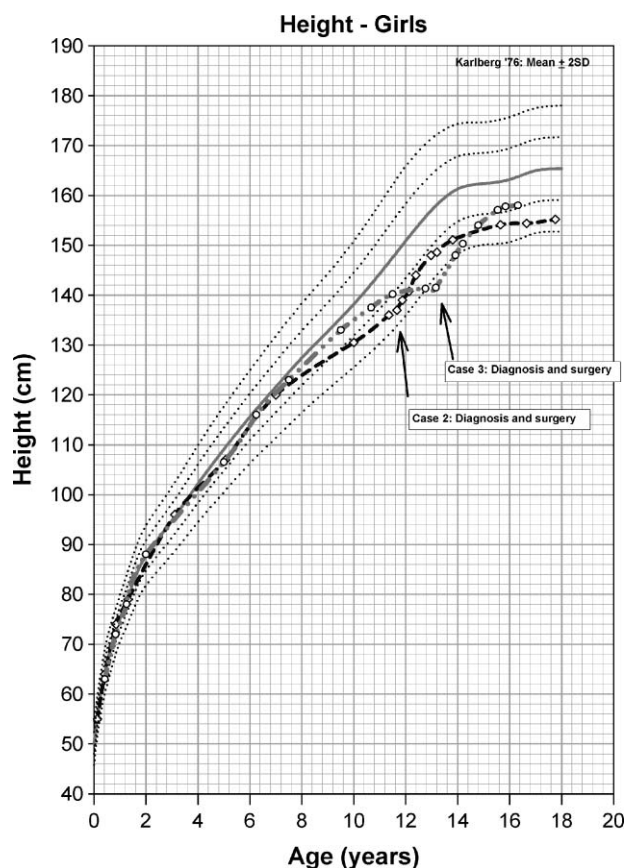


Figure 3 Growth chart illustrating the growth of the patients 2 (\diamond) and 3 (\circ). The onset of treatment is indicated by an arrow.

range 50–230 nmol/24 h). Serum ACTH was increased (29 pmol/l; normal range 2–14 pmol/l) and serum cortisol was 575 nmol/l. A dexamethasone suppression test showed suppression of serum ACTH and serum cortisol to 1 pmol/l and 13 nmol/l respectively. Stimulation of the GH axis by clonidine revealed a low excretion of GH (peak concentration 4.4 mU/l). The thyroid hormone axis was normal and serum prolactin concentrations were in the normal range. Ionised serum calcium was slightly increased (1.32 nmol/l; normal range 1.19–1.29 nmol/l), but serum PTH was normal (5.4 pmol/l).

MRI of the pituitary region demonstrated an asymmetric pituitary with enlargement of the left side, and IPSS revealed increased pituitary secretion of ACTH on the left side. The microadenoma was resected by TSS. Histological examination showed an ACTH-producing adenoma. Hydrocortisone replacement therapy was slowly decreased over a period of 22 months. No other pituitary deficiencies were demonstrated post-operatively. Cushingoid symptoms disappeared within 6 months. Pubertal development continued normally, with menarche at the age of 12½ years. Serum concentrations of PTH and calcium remained in the upper normal range throughout 6 years of observation.

A lipoma on the right shoulder was removed when the girl was aged 16 years and histology showed no malignancy. At the age of 18 years, her final height was 155.2 cm, for a target height of 154 cm. Weight was 42.7 kg.

Family history The sister and the mother of the index patient were examined and shown to have increased serum calcium concentrations and increased PTH concentrations. The mother's brother had undergone surgery for a malignant carcinoid tumour of the thymus and had increased serum concentrations of calcium and PTH.

Genetic testing of the *MEN1* gene showed that the girl harboured the same mutation as described in patient 1. The mother and the sister also carried the same mutation. Further genetic investigations in this large family are in progress and will be reported elsewhere.

Patient 3

A 12½-year-old girl was referred to our paediatric clinic because of progressive obesity and decelerating growth rate, with loss in height from -0.3 s.d. to -2.3 s.d. from 9 years of age (Fig. 3) and intermittent headache.

At the time of admission, the girl presented with short stature, truncal obesity, thin limbs, moonface with a flushing appearance, no breast development, but PH 3. Her height was 142 cm, her weight 46.7 kg and her blood pressure 135/76 mmHg. Bone age was retarded by 1.5 years. Serum Na, K and blood glucose concentrations were normal. Urinary free cortisol excretion was increased (800 nmol/24 h; normal range 37–341 nmol/l/24 h), and a loss of normal diurnal rhythm of serum cortisol (0800 h 502 nmol/l, 2200 h 539 nmol/l) was found. During a dexamethasone suppression test, urinary cortisol excretion, serum cortisol concentrations and plasma ACTH concentrations became suppressed to 29 nmol, 38 nmol/l and 7 ng/l respectively. Peak GH concentration as measured by a clonidine stimulation test was 14.7 mU/l. Serum prolactin concentration and the thyroid hormone axis were normal. An LHRH test showed a prepubertal response.

An ACTH-producing pituitary microadenoma was confirmed by MRI and IPSS. Abdominal MRI and CT scan of the chest were normal. Transsphenoidal surgery was performed successfully. Hydrocortisone replacement was slowly decreased over the following 6 months. Normal pituitary function was restored, with catch-up growth and pubertal development; menarche was noted at the age of 13½ years. Final height when the girl was 16½ years of age was 159.3 cm (target height 168 cm) and weight was 53.5 kg.

Subsequently, primary hyperparathyroidism was diagnosed, with increased ionised serum calcium

(1.42 nmol/l; normal range 1.18–1.38 nmol/l) and increased plasma PTH (8.3 pmol/l). No renal stones were demonstrated.

Family history Genetic screening for *MEN1* gene mutation was performed, revealing a heterozygous T → C transition at codon 44 in exon 9, resulting in a leucine to proline substitution at position 444 in the menin protein (Leu444Pro). Screening for hypercalcaemia was performed in the asymptomatic parents and the older sister, with normal results. None of these family members carried the missense mutation.

Results

Three children (two girls, one boy), 11–13 years of age, were admitted to our paediatric clinic for investigation of Cushing's syndrome. An ACTH-secreting pituitary microadenoma was diagnosed in all of them, and successful TSS was performed. Subsequently a primary hyperparathyroidism was diagnosed in the boy and his monozygotic twin brother, and in one of the two girls.

Genetic screening confirmed the diagnosis of *MEN1* in all three children with Cushing's disease. In two of the patients, the same mutation of the *MEN1* gene (Tyr351His) was found. This mutation had not previously been described. Subsequently, the mutation was identified in affected members of their families, leading to a diagnosis of *MEN1*.

In the third patient, another mutation of the *MEN1* gene (Leu444Pro) was found. The parents and sister of this girl did not carry the mutation. This sporadic mutation had previously been described in an Italian family.

Discussion

Clinical manifestations of *MEN1*-associated diseases are very rare in childhood. Our three cases demonstrate that ACTH-producing pituitary adenomas in *MEN1* can occur in patients of young age. The clinical presentation of Cushing's disease did not differ from ordinary cases of this disease. The sensitivity and the specificity of the high-dose dexamethasone suppression test is only about 80%, which explains the normal suppression of serum cortisol and urinary cortisol excretion in two of our three patients (18, 19). The suggestion of *MEN1*-associated Cushing's disease first arose with detection of primary hyperparathyroidism in patients 1 and 3, and subsequent family history in patients 1 and 2. Genetic testing of affected members of the families of patients 1 and 2 showed the same mutation of the *MEN1* gene, not previously described. Further exploration of the history of these two families revealed distant membership of a large kindred with clinical signs of *MEN1* in several generations going back to

the 19th century. In patient 3, a sporadic new mutation of the *MEN1* gene was found, which had been described earlier in an Italian kindred (20). It is known that *de novo* mutations are found in about 15% of patients with *MEN1* (9, 21).

To our knowledge, this is the first report describing clinical symptoms and genetic testing in monozygotic twins with *MEN1*. It is of interest that the twin brothers presented different phenotypes, with primary hyperparathyroidism and renal stones in both, but Cushing's disease only in the index patient. The variability in phenotype may reflect the results of random chance for a second mutation in susceptible cells with loss of heterozygosity, in accordance with Knudson's 'two-hit' hypothesis (4, 21). Prolactinomas are much more common in *MEN1* than are ACTH-producing pituitary adenomas, and it has been shown that prolactinomas in *MEN1* appear to be larger and more aggressive than sporadic cases in patients without *MEN1* (4, 9, 14, 15).

In heritable disorders, the benefits of a genetic diagnosis must be balanced against the psychological burden of the screening procedure. No curative treatment can be offered to carriers of *MEN1* gene mutations, but early detection and treatment at a pre-symptomatic stage may decrease morbidity and mortality (8). Thus the children's families should receive genetic counselling throughout, in order to be able to make informed decisions. Using mutation screening of the *MEN1* gene, a mutation is detected in 80–90% of affected patients. Hence, screening for mutations of the *MEN1* gene can confirm the clinical diagnosis in most of the patients, but in 10–20% no mutation can be found.

The earliest reported presentation of any serious endocrine tumour in *MEN1* was of an aggressive prolactin- and GH-secreting pituitary macroadenoma in a 5-year-old boy (22). A pancreatic insulinoma has been described in a 7-year-old boy (23), and primary hyperparathyroidism from the age of 8 years (24). Johnston *et al.* (25, 26) suggested a screening programme for children carrying *MEN1* gene mutations, to start at the age of 10–15 years. These children should be screened with annual blood tests measuring serum calcium, pancreatic polypeptide and gastrin, prolactin and insulin-like growth factor-1. Annual pancreatic ultrasound and pancreatic and pituitary MRI every 3–5 years should also be performed. A consensus statement from 2001 (24) recommended that screening begin at 5 years of age. We suggest that careful growth records should be added to the annual screening programme, and further measures should be performed in children who fail to thrive, with respect to the possible presence of an ACTH-secreting pituitary tumour. Children with negative results from genetic testing for a known familial *MEN1* gene mutation can be spared a prospective screening programme and uncertainty.

The incidence of Cushing's disease in children is rare compared with the rate of occurrence in adults (27, 28). Cushing's disease accounts for 75% of children admitted for Cushing's syndrome (29–31), with a mean age at diagnosis of about 11–14 years (range 6–18 years), as for our patients. Cure or remission rates after TSS have been reported as 50–98% (29, 32–34). Post-operative endocrine deficits are permanent in only a small proportion of patients (35). All our patients remained in remission 4–6 years after TSS, with restored pituitary function. TSS was also followed by catch-up growth in our patients, but a reduction in final height was clearly demonstrated in patient 1 (36).

In conclusion, in patients presenting with Cushing's disease or other pituitary adenomas in childhood in addition to hyperparathyroidism, a careful family history with regards to familial MEN1 should be performed, and the possibility of genetic confirmation of the diagnosis of MEN1 should be offered to the children and their families. Careful growth monitoring should be performed in children at risk of developing inherited MEN1, and in the case of growth failure, further investigation with regard to an ACTH-secreting pituitary tumour should be undertaken.

References

- Trump D, Farren B, Wooding C, Pang JT, Besser GM, Buchanan K, Edwards CR, Heath DA, Jackson CE, Jansen S, Lips K, Monson JP, O'Halloran D, Sampson J, Shalet SM, Wheeler MH, Zink A & Thakker RV. Clinical studies of multiple endocrine neoplasia type 1 (MEN1). *Quarterly Journal of Medicine* 1996 **89** 653–669.
- Chandrasekharappa SC, Guru SC, Manickam P, Olufemi SE, Collins FS, Emmert-Buck MR, Debelenko LV, Zhuang Z, Lubensky IA, Liotta LA, Crabtree JS, Wang Y, Roe BA, Weisemann J, Boguski MS, Agarwal SK, Kester MB, Kim YS, Heppner C, Dong Q, Spiegel AM, Burns AL & Marx SJ. Positional cloning of the gene for multiple endocrine neoplasia-type 1. *Science* 1997 **276** 404–407.
- Kim H, Lee JE, Cho EJ, Liu JO & Youn HD. Menin, a tumor suppressor, represses JunD-mediated transcriptional activity by association with an mSin3A-histone deacetylase complex. *Cancer Research* 2003 **63** 6135–6139.
- Marx SJ & Nieman LK. Aggressive pituitary tumours in MEN1: do they refute the two-hit model of tumorigenesis? *Journal of Clinical Endocrinology and Metabolism* 2002 **87** 453–456.
- Chandrasekharappa SC & Teh BT. Functional studies of the MEN1 gene. *Journal of Internal Medicine* 2003 **253** 606–615.
- Bassett JH, Forbes SA, Pannett AA, Lloyd SE, Christie PT, Wooding C, Harding B, Besser GM, Edwards CR, Monson JP, Sampson J, Wass JA, Wheeler MH & Thakker RV. Characterization of mutation in patient with multiple endocrine neoplasia type 1. *American Journal of Human Genetics* 1998 **62** 232–244.
- Waterlot C, Porchet N, Bauders C, Decoux M, Wemeau JL, Proye C, Degand PM, Aubert JP, Cortet C & Dewailly D. Type 1 multiple endocrine neoplasia (MEN1): contribution of genetic analysis to the screening and follow-up of a large French kindred. *Clinical Endocrinology (Oxford)* 1999 **51** 101–107.
- Geerdink EAM, Van der Luijt RB & Lips CJM. Do patients with multiple endocrine neoplasia syndrome type 1 benefit from periodical screening? *European Journal of Endocrinology* 2003 **149** 577–582.
- Verges B, Boureille F, Goudet P, Murat A, Beckers A, Sassolas G, Cougard P, Chambe B, Montvernay C & Calender A. Pituitary disease in MEN type 1 (MEN1): data from the France–Belgium MEN1 multicenter study. *Journal of Clinical Endocrinology and Metabolism* 2002 **87** 457–465.
- Veldhuis JD, Norton JA, Wells SA, Vinik AI & Perry RR. Therapeutic controversy. Surgical versus medical management of multiple endocrine neoplasia (MEN) type 1. *Journal of Clinical Endocrinology and Metabolism* 1997 **82** 357–364.
- Burgess JR, Nord B, David R, Greenway TM, Parameswaran V, Larsson C, Shepherd JJ & Teh BT. Phenotype and phenocopy: the relationship between genotype and clinical phenotype in a single large family with multiple endocrine neoplasia type 1 (MEN1). *Clinical Endocrinology* 2000 **53** 205–211.
- Skogseid B, Eriksson B, Lundquist G, Lörelus E, Rastad J, Åkerström G & Oberg K. Multiple endocrine neoplasia type 1: a 10-year prospective screening study in four kindreds. *Journal of Clinical Endocrinology and Metabolism* 1991 **73** 281–287.
- Vasen HFA, Lamers CBHW & Lips CJM. Screening for the multiple endocrine neoplasia syndrome type 1. A study of 11 kindreds in the Netherlands. *Archives of Internal Medicine* 1989 **149** 2717–2722.
- Beckers A, Betea D, Valdes Socin H & Stevenaert A. The treatment of sporadic versus MEN1-related pituitary adenomas. *Journal of Internal Medicine* 2003 **253** 599–605.
- Burgess JR, Shepherd JJ, Parameswaran V, Hoffman L & Greenaway TM. Spectrum of pituitary disease in multiple endocrine neoplasia type 1 (MEN 1): clinical, biochemical, and radiological features of pituitary disease in a large MEN1 kindred. *Journal of Clinical Endocrinology and Metabolism* 1996 **81** 2642–2646.
- Gaitan D, Loosen PT & Orth DN. Two patients with Cushing's disease in a kindred with multiple endocrine neoplasia type 1. *Journal of Clinical Endocrinology and Metabolism* 1993 **76** 1580–1581.
- Oldfield EH, Doppman JL, Nieman LK, Chrousos GP, Miller DL, Katz DA, Cutler GB Jr & Loriaux DL. Petrosal sinus sampling with and without corticotropin-releasing hormone for differential diagnosis of Cushing's syndrome. *New England Journal of Medicine* 1991 **325** 897–905.
- Aron CA, Raff H & Findling JW. Effectiveness versus efficacy: the limited value in clinical practice of high dose dexamethasone suppression testing in differential diagnosis of adrenocorticotropic-dependent Cushing's syndrome. *Journal of Clinical Endocrinology and Metabolism* 1996 **82** 1780–1785.
- Isidori AM, Kaltsas GA, Mohammed S, Morris DG, Jenkins P, Chew SL, Monson JP, Besser GM & Grossman AB. Discriminatory value of the low-dose dexamethasone suppression test in establishing the diagnosis and differential diagnosis of Cushing's syndrome. *Journal of Clinical Endocrinology and Metabolism* 2003 **88** 5299–5306.
- Cetani F, Pardi E, Cianferotti L, Vignali E, Picone A, Micolli P, Pinchera A & Marcocci C. A new mutation of MEN1 gene in an Italian kindred with multiple endocrine neoplasia type 1. *European Journal of Endocrinology* 1999 **140** 429–433.
- Marx S, Spiegel AM, Skarulis MC, Doppman JL, Collins FS & Liotta LA. Multiple endocrine neoplasia type 1: clinical and genetic topics. *Annals of Internal Medicine* 1998 **129** 484–494.
- Stratakis CA, Schussheim DH, Freedman SM, Keil MF, Pack SD, Agarwal SK, Skarulis MC, Weil RJ, Lubensky IA, Zhuang Z, Oldfield EH & Marx SJ. Pituitary macroadenoma in a 5-year-old: an early expression of multiple endocrine neoplasia type 1. *Journal of Clinical Endocrinology and Metabolism* 2000 **85** 4776–4780.
- Kontogeorgos G, Kapranos N, Tzavara I, Thalaassinis N & Rologis D. Monosomy of chromosome 11 in pituitary adenoma in a patient with familial multiple endocrine neoplasia type 1. *Clinical Endocrinology* 2001 **54** 117–120.
- Brandi ML, Gagel RF, Angeli A, Bilezikian JP, Beck-Peccoz P, Bordi C, Conte-Devolx B, Falchetti A, Gheri RG, Libroia A, Lips CJ, Lombardi G, Mannelli M, Pacini F, Ponder BA, Raue F, Skogseid B, Tamburrano G, Thakker RV, Thompson NW, Tomassetti P, Tonelli F, Wells SA Jr & Marx SJ. Consensus: guidelines for

- diagnosis and therapy of MEN type 1 and type 2. *Journal of Clinical Endocrinology and Metabolism* 2001 **86** 5658–5671.
- 25 Johnston LB, Chew SL, Trainer PJ, Reznick R, Grossman AB, Besser GM *et al.* Screening children at risk of developing inherited endocrine neoplasia syndromes. *Clinical Endocrinology* 2000 **52** 127–136.
- 26 Johnston LB, Chew D, Lowe D, Reznick R, Monsom JP & Savage MO. Investigating familial endocrine neoplasia syndromes in children. *Hormone Research* 2001 **55** 31–35.
- 27 Moshang T. Cushing's disease, 70 years later and the beat goes on. *Journal of Clinical Endocrinology and Metabolism* 2003 **88** 31–33.
- 28 Lindholm J, Juul S, Jorgensen JO, Astrup J, Bjerre P, Feldt-Rasmussen U, Hagen C, Jorgensen J, Kosteljanetz M, Kristensen L, Laurberg P, Schmidt K & Weeke J. Incidence and late prognosis of Cushing's syndrome: a population-based study. *Journal of Clinical Endocrinology and Metabolism* 2001 **86** 117–123.
- 29 Magiakou MA, Mastorakos G, Oldfield EH, Gomez MT, Doppman JL, Cutler GB Jr, Nieman LK & Chrousos GP. Cushing's syndrome in children and adolescents. *New England Journal of Medicine* 1994 **331** 629–636.
- 30 Storr HL, Plowman PN, Carroll PV, Francois I, Krassas GE, Afshar F, Besser GM, Grossman AB & Savage MO. Clinical and endocrine responses to pituitary radiotherapy in pediatric Cushing's disease: an effective secondline treatment. *Journal of Clinical Endocrinology and Metabolism* 2003 **88** 34–37.
- 31 Weber A, Trainer PJ, Grossman AB, Afshar F, Medbak S, Perry LA, Plowman PN, Rees LH, Besser GM & Savage MO. Investigation, management and therapeutic outcome in 12 cases of childhood and adolescent Cushing's syndrome. *Clinical Endocrinology (Oxford)* 1995 **43** 19–28.
- 32 Savage MO, Lienhardt A, Lebrethon MC, Johnston LB, Huebner A, Grossman AB, Afshar F, Plowman PN & Besser GM. Cushing's disease in childhood: presentation, investigation, treatment and long-term outcome. *Hormone Research* 2001 **51** (Suppl 1) 24–30.
- 33 Devoe DJ, Miller WL, Conte FA, Kaplan SL, Grumbach MM, Rosenthal SM, Wilson CB & Gitelman SE. Long-term outcome in children and adolescents after transsphenoidal surgery for Cushing's disease. *Journal of Clinical Endocrinology and Metabolism* 1997 **82** 3196–3902.
- 34 Leinung MS, Kane LA, Scheithauer BW, Carpenter PC, Laws ER Jr & Zimmermann D. Long-term follow-up of transsphenoidal surgery for the treatment of Cushing's disease in childhood. *Journal of Clinical Endocrinology and Metabolism* 1995 **80** 2475–2479.
- 35 Massoud AF, Powel M, Williams RA, Hindmarsh PC & Brook CGD. Transsphenoidal surgery for pituitary tumours. *Archives of Disease in Childhood* 1997 **76** 398–404.
- 36 Lebrethon M-C, Grossman AB, Afshar F, Plowman N, Besser M & Savage MO. Linear growth and final height after treatment for Cushing's disease in childhood. *Journal of Clinical Endocrinology and Metabolism* 2000 **85** 3262–3265.

Received 29 March 2004

Accepted 6 September 2004