

CUTANEOUS BOTRYOMYCOSIS. REPORT OF THE TWO FIRST URUGUAYAN CASES

Ismael A. CONTI-DIAZ (1), Edgardo A. ALMEIDA (2), Mariela RONDAN (3), Gabriela ALGORTA (4) & Marta OTERO (5)

SUMMARY

The first two Uruguayan cases of botryomycosis were diagnosed in white adult male patients with cutaneous lesions. *Staphylococcus aureus* was the etiologic agent in both cases. In one of them, however, *Pseudomonas aeruginosa* was also identified during relapse.

General comments on diagnosis and pathogenesis of the disease are made.

KEYWORDS: Botryomycosis; *Staphylococcus aureus*; Granules.

INTRODUCTION

Botryomycosis is a rare suppurative chronic and granulomatous disease characterized by presence of granules in tissues due to the infection by non filamentous bacteria.

Originally described by BOLLINGER in equines in 1870¹, RIVOLTA¹² named it botryomycosis (from Greek: *Botrys*, grape bunch and *mycosis* for attributing it a fungal origin). In 1919, MAGROU⁹ established the bacterial origin of the disease.

This paper refers the first two Uruguayan cases stressing the importance of a correct diagnostic methodology for the recognition of the disease.

CLINICAL OBSERVATIONS

Case 1. Patient F.S., male, white, 20 year old, from Montevideo city, with presumptive diagnosis of sporotrichotic residual abscess. At examination: nodular

ovoid dermohypodermic lesion on the left supraepitrochlear region of 1.5 cm long by 1 cm wide, a bit painful and fluctuating, without local heat or epidemic changes. No general symptoms. One year before, traumatic lesion on left fore-finger treated with antibiotics during 2 weeks and with local iodines and hot water bag for other 3 weeks.

After puncture scarce pus with small yellowish masses was obtained. The microscopic examination showed groups of round shaped granules with amorphous center and lobulated periphery, surrounded some of them by clubs. Their diameters ranged between 350 and 420 microns (Fig. 1). Smears of the granules stained by Gram's method, revealed abundant Gram positive cocci. Cultures on blood agar developed abundant *Staphylococcus aureus* colonies. The pus was embedded in paraffin. Hematoxylin & Eosin (H & E) stain showed granules with irregular borders, amphophylic granular center and eosinophylic periphery. Around them, dense infiltrate containing pyocytes, fibrin and leukocytes. Gram's stain showed numerous coccoid Gram + organisms inside the granules.

(1) Professor and Chairman Department of Parasitology, Institut of Hygiene, School of Medicine, Montevideo, URUGUAY.

(2) Pathology Residents' Chief, Hospital Maciel, Public Health Service, Montevideo, URUGUAY.

(3) Assistant Professor of Pathology, School of Medicine, Montevideo, URUGUAY.

(4) Assistant Professor, Department of Bacteriology and Virology, School of Medicine, Montevideo, URUGUAY.

(5) Pathology Resident, Hospital Maciel, Public Health Service, Montevideo, URUGUAY.

Correspondence to: Prof. Dr. Ismael A. Conti-Diaz, Ayacucho 3314, Montevideo, URUGUAY.

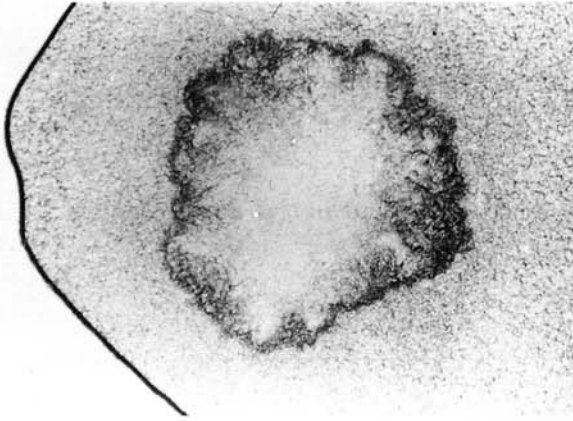


Fig. 1 – Case 1. – Botryomycotic granule with circinated margins. Fresh examination between slide and coverslip, x 100.

An apparent cure was obtained after surgical drainage. However, ten months later, a relapse occurred; *S. aureus* and *Pseudomonas aeruginosa* were isolated. De-

finite and fast cure was obtained after antibioticotherapy.

Case 2. Patient O.G., male, white, 64 years old, from Montevideo city with 6 dermo-hypodermic nodules on upper and lower limbs as well as dorsum of 1 to 6 cm in diameter, at different evolutive stages. Some of them showed discharge of scarce pus through one or more sinuses (Fig. 2). The nodules appeared 45 days before. Fresh examination of the nodules was not done, but a biopsy was performed. Whereas in the cultures developed *S. aureus*, the histological section stained by H & E showed a subacute inflammatory process with dense histiocytic masses, necrotic areas and exudate rich in pyocytes and leukocytes. In this exudate granules with similar characteristics to those described in the first case were observed (Fig. 3). Gram's stain for histological sections showed abundant Gram positive organisms inside the granules (Fig. 4).

DISCUSSION

The present paper refers the first two Uruguayan cases of botryomycosis. According to PHILIPPOT et al.¹⁰ only 95 cases of the disease had been communicated until 1992.

In our both patients granules containing abundant Gram + cocci inside them, were found. Cultures gave development to *S. aureus* but in the relapse of the first case, *P. aeruginosa* was also isolated.

Differential clinical diagnosis of botryomycosis is mainly with stated mycetomas. The importance of a careful fresh examination of pus setting a diagnosis of botryomycosis was pointed out by AYNAUD in 1928³ and by MACKINNON et al.⁷.

Smears of granules stained by Gram's method and Kinyoun's if necessary are recommended. Paraffin sections of granules or cutaneous biopsies stained by H & E and Gram's method usually confirm diagnosis.

Production of granules by *S. aureus* and other bacteria in botryomycosis is poorly understood. While MAGROU⁹ suggested an special host-parasite balance, other authors accept an interaction between light pathogenic bacterial strains and an increased host's resistance¹⁴. However, the diagnosis of botryomycosis in several AIDS patients^{6,10}, makes doubtful the concept of a concomitant increase in host's resistance. Furthermore, TOTH & KAZAL¹³ refer a defect in the intracellular destruction of bacteria by the macrophagic-mononuclear system in a botryomycosis AIDS patient. It is nowadays accepted that in most botryomycosis patients it is diffi-

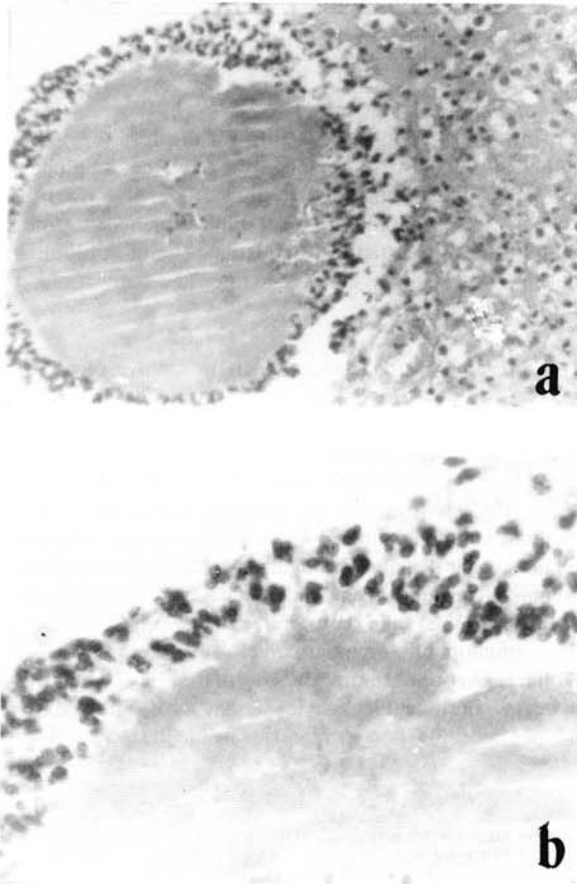


Fig. 2 – Case 2. – a) Rounded granule surrounded by a dense polymorphonuclear crown. H. & E. x 100. b) A fragmentary view of granule "a" at higher magnification. x 250.

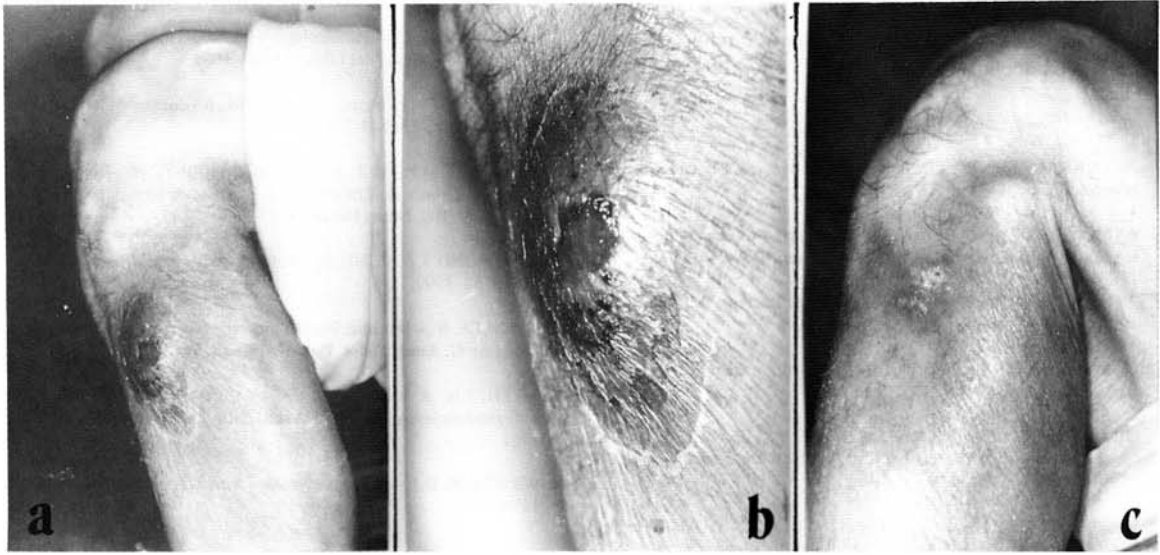


Fig. 3 – Case 2. – a) Nodular lesion on upper third of external aspect of left leg. b) Same lesion than “a” but at higher magnification. c) Scarred lesion after treatment.

cult or impossible to demonstrate predisponent factors or defects in the immune response¹¹ what certainly happened in our two patients.

In 1969, MACKINNON et al.⁷ obtained actinomycetoid granules in guinea-pigs inoculated intratesticularly with low dosis of *P. aeruginosa*. They brought attention on the peculiar characteristics of an eosinophilic sheath with clubs around it. The deposit of eosinophilic substance on the periphery of botryomycotic, actinomycotic or fungal granules⁸ with a

crown shape or like radiated structures according to the case, represents the well known phenomenon of Splendore-Hoeppli¹. A similar thing happens on isolated fungal cells (asteroid bodies in sporotrichosis f. ex.), parasites, and also on inorganic materials¹⁴. It would correspond to the deposit of host's antibodies against antigens of very different origin. Both IgG and C3 were found in such a substance in botryomycosis granules¹⁰.

Finally, regarding therapy, though the spontaneous regression has been described², treatment should associate in most cases surgical drainage with antibioticotherapy according to antibiogram⁵.

RESUMO

Botriomicose cutânea: relato dos dois primeiros casos no Uruguai

Apresentamos os dois primeiros doentes de Botriomicose tegumentar no Uruguai.

Ambos doentes eram adultos do sexo masculino.

Um tinha lesão isolada abscedida. No outro as lesões eram múltiplas e algumas fistulizadas.

Em ambos doentes o agente etiológico isolado foi *Staphylococcus aureus*. No primeiro doente, além disso, foi isolado *Pseudomonas aeruginosa* na recidiva.

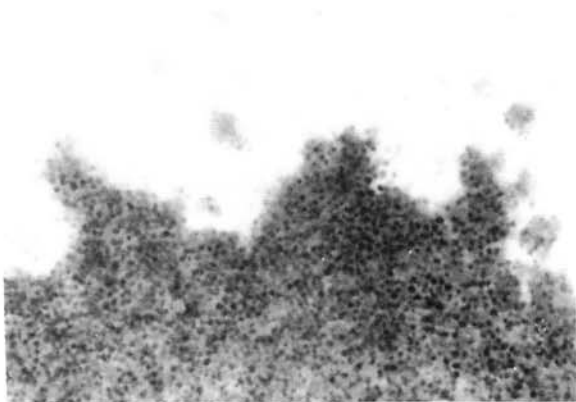


Fig. 4 – Case 2. – Another sector of granule with irregular edges and abundant Gram + cocci inside. Gram's stain for histological sections. x 1000.

Comentários gerais são feitos sobre o diagnóstico e patogenia da doença.

REFERENCES

1. ARENAS, R. – Micología médica ilustrada. México, Nueva Editorial Interamericana, 1993.
2. AYMOUNIN, J.F. & BONVALET, D. – Prurigo-like spontaneously regressive botryomycosis. *Ann. Derm. Vénér.*, **199**: 267-270, 1992.
3. AYNAUD, M. – Botryomycosis. *Ann. Inst. Pasteur*, **42**: 256-259, 1928.
4. BOLLINGER, O. – Mycosis der Lunge beim pferde. *Virchows Arch. path. Anat.*, **49**: 583-586, 1870.
5. GILLOCK, C.B.; SAHNI, K.S.; MUMAW, V.R. & MEIER, F.A. – Cerebral botryomycosis: case study. *J. infect. Dis.*, **162**: 765-767, 1990.
6. KATAPADI, K.; PUJOL, F.; VULETIN, J.C.; KATAPADI, M. & PACHTER, B.R. – Pulmonary botryomycosis in a patient with AIDS. *Chest*, **109**: 276-278, 1996.
7. MACKINNON, J.E.; CONTI-DIAZ, I.A.; GEZUELE, E. et al. – Experimental botryomycosis produced by *Pseudomonas aeruginosa*. *J. med. Microbiol.*, **2**: 369-372, 1969.
8. MACKINNON, J.E. – Parasitología y micología médicas. I. Micología. Montevideo, Oficina del Libro – AEM, 1966.
9. MAGROU, J. – Les formes actinomycotiques du staphylocoque. *Ann. Inst. Pasteur*, **33**: 344-374, 1919.
10. PHILIPPOT, M.P.; HILL, A.; GHO, B. & PERROT, H. – Botryomycosis cutanée au cours de l'infection par le virus de l'immunodeficiency humaine (VIH). *Nouv. Derm.*, **12**: 700-703, 1993.
11. RICHMOND, I. & MENE, A. – Botryomycosis renal. *Histopathology*, **20**: 67-69, 1992.
12. RIVOLTA, S. – Del micellio e delle varietà e specie di discoineceti patogeni. *G. Anat. Fisiol. Pat. d'Animali*, **16**: 181-198, 1884.
13. TOTH, I.R. & KAZAL, H.L. – Botryomycosis in acquired immunodeficiency syndrome. *Arch. Path. Lab. Med.*, **111**: 246-249, 1987.
14. WINSLOW, D.J. – Botryomycosis. *Amer. J. Path.*, **35**: 153-167, 1959.

Recebido para publicação em 13/11/1995

Aceito para publicação em 29/10/1996