

# Cutaneous Infection by *Fusarium* Species in Healthy and Immunocompromised Hosts: Implications for Diagnosis and Management

Marcio Nucci<sup>1</sup> and Elias Anaissie<sup>2</sup>

<sup>1</sup>University Hospital, Universidade Federal do Rio de Janeiro, Brazil; and <sup>2</sup>University of Arkansas for Medical Sciences, Little Rock

Infections by *Fusarium* species frequently involve the skin, either as the primary or the metastatic site. To better understand the pathophysiology of these infections, 43 new patients with fusariosis were evaluated, and the literature was reviewed. A total of 259 patients (232 immunocompromised and 27 immunocompetent) were identified. Skin involvement was present in 70% of patients, particularly in immunocompromised patients (72% vs. 52%;  $P = .03$ ). In immunocompetent patients, cutaneous infections were characterized by preceding skin breakdown, localized involvement, slow pace of progression, and good response to therapy. In contrast, skin involvement in immunocompromised patients was only occasionally preceded by skin breakdown and typically was presented as rapidly progressive disseminated lesions at various stages of evolution. Metastatic skin lesions were associated with fungemia, neutropenia, and death. Skin was the single source of diagnosis for the majority of immunocompromised and immunocompetent patients. Recommendations for the prevention of fatal fusariosis originating from skin are presented.

Fungal infections represent an important complication for immunosuppressed patients and are associated with high morbidity and mortality [1, 2]. The limited diagnostic tools available usually delay the diagnosis and treatment of these infections. Therapy is complicated further by the variable susceptibilities of pathogens to antifungal agents [3]. Thus, any clue to the early diagnosis of infection with a specific pathogen may lead to changes in antifungal therapy and may be critical for an improved outcome. *Fusarium* species have long been recognized as a cause of localized infections in immunocompetent individuals [4] and disseminated infections among those who are severely immunocompromised [5]. *Fusarium* species now represent the sec-

ond most frequent mold-causing invasive fungal infections in this latter population [5, 6].

One of the most frequent aspects of infection by *Fusarium* species is the development of skin lesions, which are frequently the only source of diagnostic material. Therefore, it is important to characterize the clinicopathological features of skin infection involvement in fusariosis and to establish their role in the diagnosis and management of this infection. We describe the characteristics of fusarial skin infections in immunocompetent and immunocompromised hosts and make practical recommendations for management.

## PATIENTS AND METHODS

A computerized search of MEDLINE from January 1966 to October 2001 was performed; we used the keywords "*Fusarium*" and "fusariosis." In addition, 45 previously unpublished cases of fusariosis from Brazil were included in our analysis [7]. We selected studies that provided a detailed description of the clinical presentation, treatment, and outcome. Reports with limited

Received 1 March 2002; revised 25 April 2002; electronically published 18 September 2002.

Reprints or correspondence: Dr. Elias J. Anaissie, Myeloma Institute for Research and Therapy, University of Arkansas for Medical Sciences, 4301 W. Markham, Slot 776, Little Rock, AR 72205 (anaissieeliasj@exchange.uams.edu).

**Clinical Infectious Diseases** 2002;35:909–20

© 2002 by the Infectious Diseases Society of America. All rights reserved.  
1058-4838/2002/3508-0001\$15.00

information, those published in languages other than English, and duplicate publications were excluded, as were cases of onychomycosis without an associated soft-tissue infection.

The following data were reviewed: underlying disease and its therapy, presence of neutropenia (<500 neutrophils/mm<sup>3</sup>) and other immunosuppression, results of blood cultures, skin lesions (presence, distribution, type [localized or disseminated], culture results, and histopathology), and clinical outcome. Localized infection was defined as the presence of a single skin lesion or >1 lesion clustered in a single cutaneous segment; disseminated infection was defined as the presence of >1 skin lesion in noncontiguous sites. Categorical variables were analyzed by  $\chi^2$  or Fisher's exact test. Registration and analysis of data were performed by EpiInfo 6.04 software (Centers for Disease Control and Prevention).  $P \leq .05$  was considered to be statistically significant.

## RESULTS

There were 157 reports describing fusarial infections between 1970 and 2001. Cases described in 31 reports were excluded because of publication in languages other than English ( $n = 15$ ), lack of detailed clinical description ( $n = 12$ ), and duplicate publication ( $n = 4$ ). Thus, we examined 126 publications reporting 216 patients with fusariosis [5, 8–131]. Forty-three previously unpublished cases of fusarial infections from a multicenter Brazilian study [7] also were included, for a total of 259 patients. The 259 evaluated patients included 232 who were immunocompromised (90%) and 27 who were immunocompetent (table 1). Skin involvement by fusariosis was present in 181 patients (70%) and was more common among immunocompromised patients (72% vs. 52%;  $P = .03$ ).

**Type of skin lesions in immunocompetent hosts.** Thirteen of the 14 immunocompetent patients with fusarial skin involvement presented with localized lesions (figure 1). The majority of these patients ( $n = 10$ ) had a history of recent skin breakdown at the site of the fusarial infection, either as a result of trauma (7 patients) or of preexisting onychomycosis (3 patients). Fusarial infection presented as cellulitis among these latter 3 patients. The 7 patients who developed infection after trauma presented with necrotic lesions of the skin and soft tissues after a motor vehicle accident (2 patients) [35]; cellulitis with necrosis after severe burns (2 patients) [10, 18]; chronic, painful toe ulcer that developed 1 year after surgery on the same toe [19] (1 patient); subcutaneous abscess after direct trauma, 1 year earlier, with a small bamboo chip (1 patient) [84]; and a plaque with several vesicles and pustules and a central superficial ulcer on a finger 3 weeks after minor trauma (1 patient) [32]. In 3 patients, a history of skin breakdown or trauma was not reported. Two of the latter patients presented

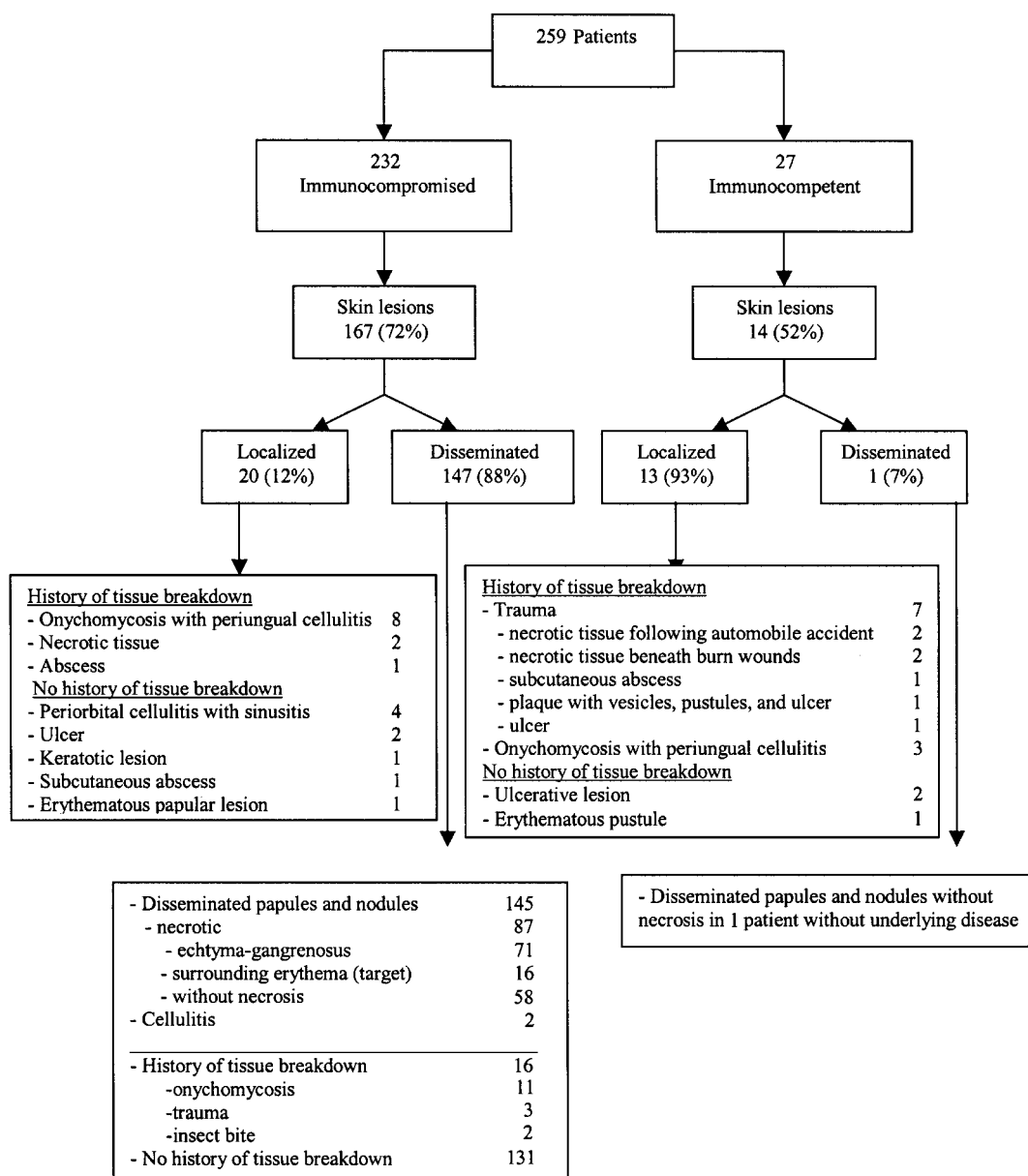
**Table 1. Underlying conditions in 259 cases of fusariosis in immunocompromised and immunocompetent patients.**

Condition	No. (%) of patients
Immunocompromised	232
Cancer	205 (88)
Aplastic anemia	15 (6)
Solid-organ transplantation	7 (3)
Renal	4
Heart and lung	1
Heart and liver	1
Lung	1
Other	5 (2)
AIDS	2
Diabetes	1
Chronic neutropenia	1
Chronic granulomatous disease	1
Immunocompetent	27
None	15 (56)
Motor vehicle accident	4 (15)
Renal failure, chronic ambulatory peritoneal dialysis	3 (11)
Burns	2 (7)
Alcohol abuse	1 (4)
Heatstroke	1 (4)
Injection drug abuse	1 (4)

with ulcerated lesions resembling chromoblastomycosis. One patient had 1 large ulcerated lesion extending from the left shoulder to the upper forearm, as well as another circular indurated ulcer on the right forearm, which had evolved over years [28]. The second patient had 2 large, deep ulcers covering the entire skin surface of the dorsum of both feet, which had been present for 1 year [56]. A third patient without a history of skin breakdown had a 5 × 5-mm erythematous pustule on the dorsum of the hand [12]. The single case of disseminated metastatic skin lesion occurred in a child with fever, pulmonary infiltrates, multiple erythematous papules and nodules, and several blood cultures yielding *Fusarium* species. The results of an extensive workup for an underlying immunosuppressive illness were negative [7].

**Type of skin lesions in immunocompromised hosts.** Of 167 patients, localized cutaneous lesions occurred in only 20 (12%), of whom 11 had a recent history of skin breakdown. The most frequent lesion among the latter 11 patients was cellulitis at the site of preexisting onychomycosis (8 patients). The skin lesions in the remaining 3 patients were necrotic lesions on the feet after local trauma (2 neutropenic patients with acute lymphoid leukemia) [7] and an abscess on the left calf (a bone marrow transplant recipient with acute lymphoid leukemia) [42].

Among the 9 patients without a history of skin breakdown,

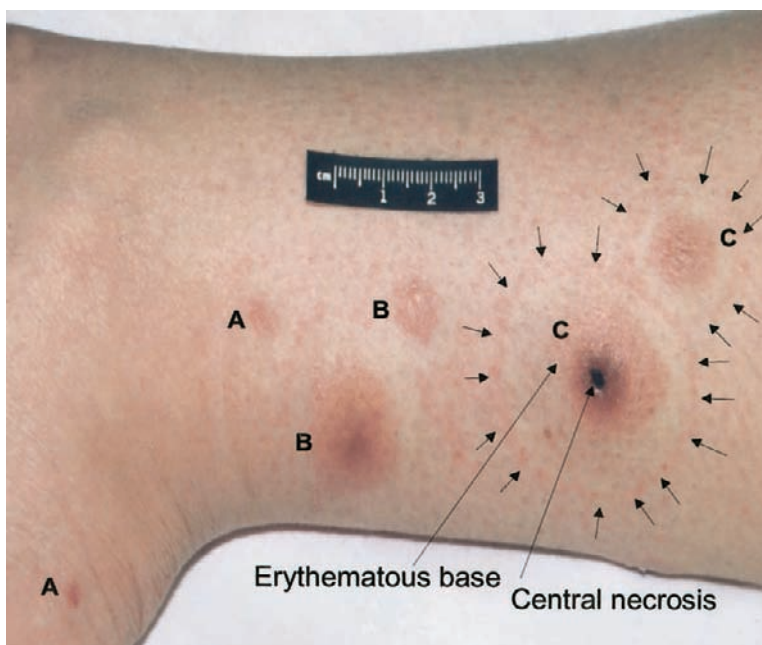


**Figure 1.** Type and extent of skin lesions caused by *Fusarium* species, according to immune competence of host. Among the 65 immunocompromised patients without skin lesions, infections included fungemia (37 patients), pneumonia (10 patients), sinusitis (9 patients), brain abscess (2 patients), arthritis (1 patient), liver involvement (1 patient), and endophthalmitis (1 patient). No data were available for the remaining 4 patients. Infections among 13 immunocompetent patients without skin involvement included peritonitis following peritoneal dialysis (3 patients), sinusitis (2 patients), pneumonia (2 patients), arthritis following motor vehicle accident (2 patients), endophthalmitis (2 patients [1 injection drug user]), and fungemia following heat stroke and allergic bronchopulmonary fusariosis (1 patient each).

the skin lesions included periorbital cellulitis (4 patients with sinusitis) and ulcerative lesions (2 patients): a leg ulcer in a patient with diabetes [16], and a left heel ulcer in a kidney transplant recipient [91]. One patient with chronic granulomatous disease developed a keratotic lesion on the cheek that evolved over 6 months [8]. One renal transplant recipient presented with a subcutaneous abscess on the dorsum of the foot [121], and 1 patient with acute lymphoid leukemia developed

a single 2 × 2-cm erythematous, tender, raised lesion on the forearm [48]. Ten of 12 patients with cellulitis were neutropenic, and 4 of the 5 patients with ulcers or abscesses had adequate neutrophil counts ( $P = .02$ ).

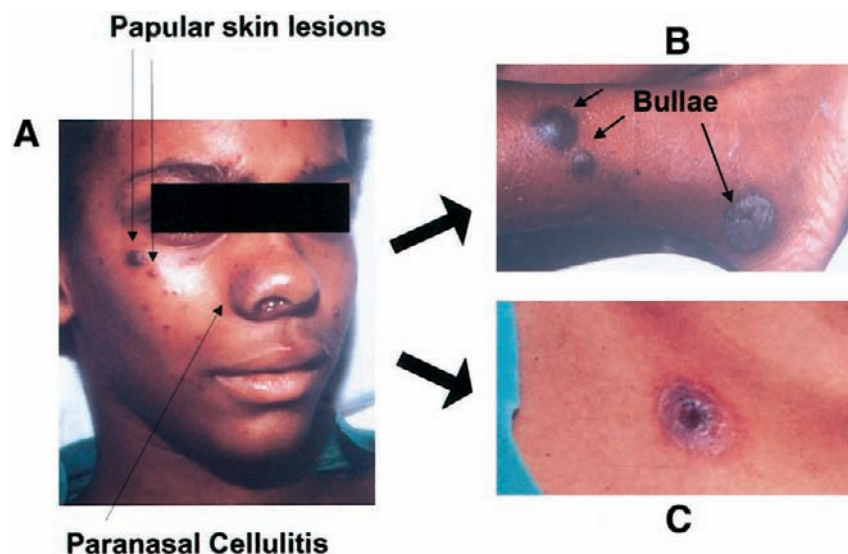
The most frequent skin lesions among patients with disseminated disease were multiple painful erythematous papular or nodular lesions with (87 patients) or without (58 patients) central necrosis. Most necrotic lesions had an ecthyma gan-



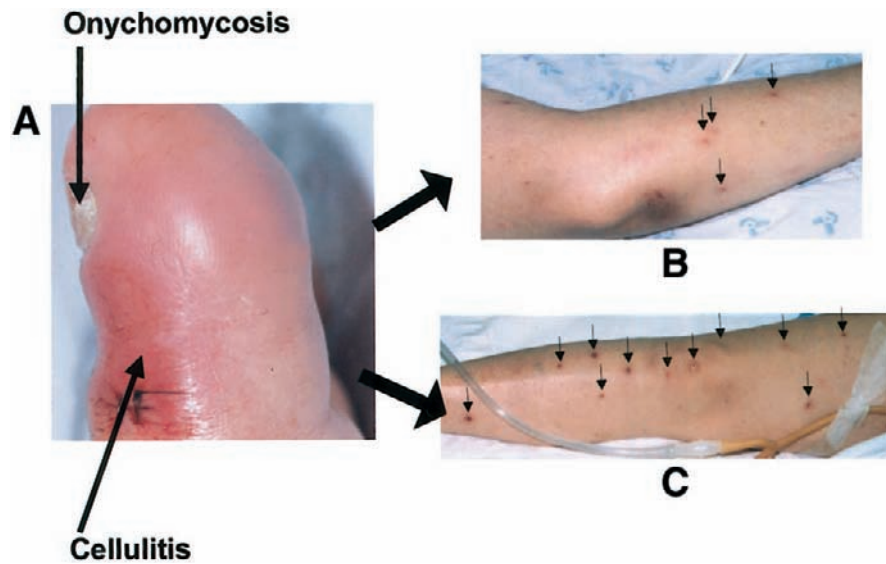
**Figure 2.** Lower extremity involvement, with several *Fusarium* skin lesions of different types and ages. *A*, Small macular lesions. *B*, Papular lesions of different sizes. *C*, Two target lesions: central necrosis surrounded by an erythematous base, an area of normal skin, and an outer rim of thin erythema (arrows). Patient was a 32-year-old woman with relapsed leukemia who had undergone allogeneic bone marrow transplantation and developed disseminated and fatal fusarial infection.

grenosum-like appearance (71 patients), whereas target lesions (a thin rim of erythema of 1–3 cm in diameter surrounding the above-mentioned papular or nodular lesions) were reported in the remaining 16 patients (figure 2). One patient developed

bullae in addition to nodular lesions (figure 3). These lesions involved practically any skin site, with predominance in the extremities. The lesions evolved rapidly, usually over a few days (range, 1–5 days). Lesions at different stages of evolution were



**Figure 3.** *A*, Paranasal cellulitis in a 15-year-old girl with aplastic anemia who presented with *Fusarium* sinusitis with subsequent development of cutaneous nodules on the face (*A*), extremities (*B*), and chest (*C*) caused by *Fusarium* species. Note the appearance of bullae in some fusarial lesions (*B*). The chest lesion became necrotic (*C*); the patient developed endophthalmitis with blindness and died a few days later. Panels *B* and *C* are reprinted with permission from [65].



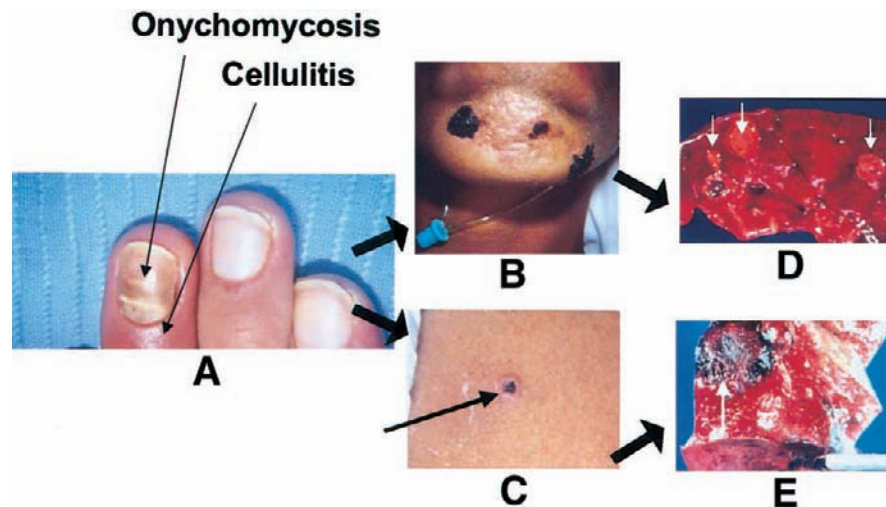
**Figure 4.** *Fusarium* toe cellulitis developing at the site of onychomycosis (A) after cytotoxic chemotherapy in a 45-year-old woman with lymphoma who underwent allogeneic bone marrow transplantation. Disseminated *Fusarium* skin lesions developed subsequently in upper (B) and lower (C) extremities. Several blood cultures were positive for *Fusarium* species. Panel A is reprinted with permission from [5].

described in 51 patients (usually a combination of papules, nodules, and necrotic lesions; figure 1), and myalgias (suggesting muscle involvement) were reported in 23 patients.

Among 16 patients with metastatic skin lesions, a recent history of cellulitis at the site of onychomycosis (11 patients; figures 4 and 5), local trauma (3 patients), or an insect bite (2 patients) were reported, suggesting that skin was the primary site of infection that led to disseminated fusariosis in these 16 patients. Only 2 patients with metastatic skin lesions did not

have papular or nodular lesions. In these 2 patients, a fusarial cellulitis developed in one toe after trauma and was followed by cellulitis at another toe in the other foot [45, 46]. The pattern of skin lesions did not appear to be associated with any particular *Fusarium* species.

Compared with nonneutropenic immunocompromised patients, patients with neutropenia had a higher rate of skin lesions (78% vs. 45%;  $P = .0001$ ), and these lesions were disseminated more frequently (94% vs. 41%;  $P < .0001$ ). Patients



**Figure 5.** *Fusarium* finger cellulitis developing at the site of onychomycosis (A) after autologous bone marrow transplantation in a 43-year-old man with Hodgkin's disease. Disseminated *Fusarium* skin lesions developed subsequently on the face (B) and trunk (C). Fatal multiorgan involvement followed, with liver (D) and lung (E) involvement. Panel A is reprinted with permission from [5].

**Table 2. Differentiating features of cutaneous infection with *Fusarium* species between immunocompetent and immunocompromised hosts.**

Feature	Immunocompetent host	Immunocompromised host
Risk factor		
Tissue breakdown (trauma, onychomycosis, insect bite)	Very common (>70%); may precede infection by up to 1 year	Uncommon (<10%)
Neutrophil count	Adequate	Usually immediately before infection; neutropenia
Type of skin lesion	Necrosis, cellulitis, ulcer, abscess, rarely chromoblastomycosis-like	Multiple, painful erythematous papules or nodules with necrosis; some with evolution into target lesions; different stages of evolution; less commonly, cellulitis (usually site of tissue breakdown)
Histopathology		
Inflammation	Marked	Scant
Necrosis	Variable	Marked
Vascular invasion	No	Abundant
Neutrophils	Abundant	No
Hyphae	Few	Abundant
Extent	Localized	Disseminated
Pace of clinical progression	Slow, over months	Rapid, over days
Blood cultures	Negative	Positive (50%)
Skin cultures, histopathology	Positive	Positive
Treatment	Local debridement; systemic antifungal therapy; perhaps local antifungal therapy	Perhaps systemic antifungal therapy with newer agents; perhaps granulocyte transfusion
Mortality	Very low	Very high, unless immunosuppression can be resolved promptly

with disseminated lesions also were more likely to have blood cultures positive for *Fusarium* species than those whose lesions were localized (57% vs. 7%;  $P < .0001$ ).

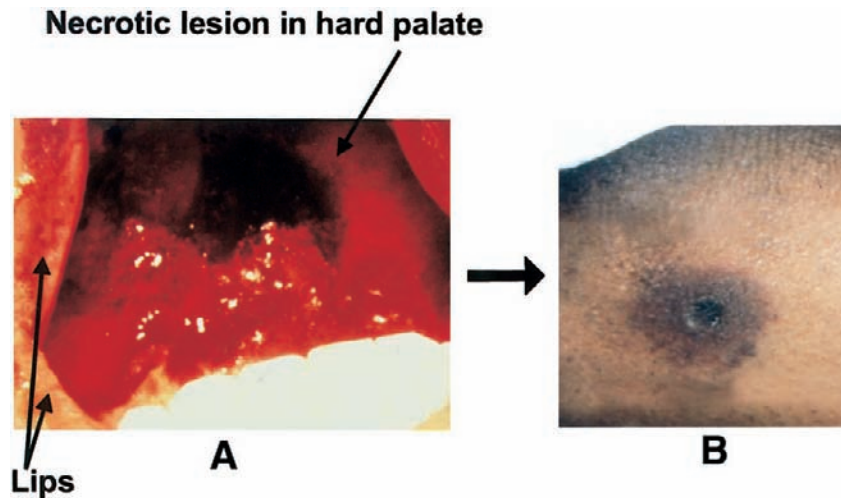
**Contribution of cutaneous infection to the diagnosis of fusariosis.** Skin lesions were the single source of diagnosis of fusarial infection in the majority of patients (100 [55%] of 181), including in the 148 patients whose skin lesions were disseminated. Of these 148 patients, 78 had blood cultures negative for *Fusarium* species, and the skin was the only source of diagnostic material in all except 2 patients (sinus was the source in 2 patients). Detailed information on the timing of positive blood cultures and the occurrence of skin lesions was provided for 18 of the remaining 71 patients whose blood cultures yielded *Fusarium* species

In these latter patients, skin lesions preceded fungemia in 11 patients by a median of 5 days (range, 1–10 days), occurred on the same day (4 patients), and did not appear until after the diagnosis of fungemia was made (3 patients, at 3, 5, and 13 days after diagnosis). Seventy-six of the 82 patients for whom information on histopathologic examination was available had hyaline acute-branching septate hyphae invading the skin. Hy-

phal invasion extended into the blood vessels, with thrombosis and skin necrosis in those patients with metastatic lesions.

**Patient outcome in relation to cutaneous involvement.**

The overall death rate of patients with fusarial infections was 66% (170 of 259 patients), with a 100% mortality among persistently neutropenic patients, compared with only 30% among those who ultimately recovered from immunosuppression ( $P < .0001$ ). A higher mortality also was observed among patients with skin lesions (70% vs. 56%;  $P = .04$ ), particularly among those whose lesions were disseminated (76% vs. 39%;  $P < .0001$ ). However, a stratified analysis of patients with metastatic lesions by neutrophil count revealed that the higher mortality rate remained significant only among those who had an adequate neutrophil count throughout the course of their illness. In this group of patients with persistently adequate neutrophil counts, the mortality rate was 67% for those with metastatic lesions and 21% for those with localized lesions ( $P = .03$ ). The mortality among neutropenic patients was high, regardless of whether the lesions were localized or metastatic (64% vs. 77%;  $P = .33$ ), respectively, which reflects the contribution of severe immunosuppression to the fatal outcome.



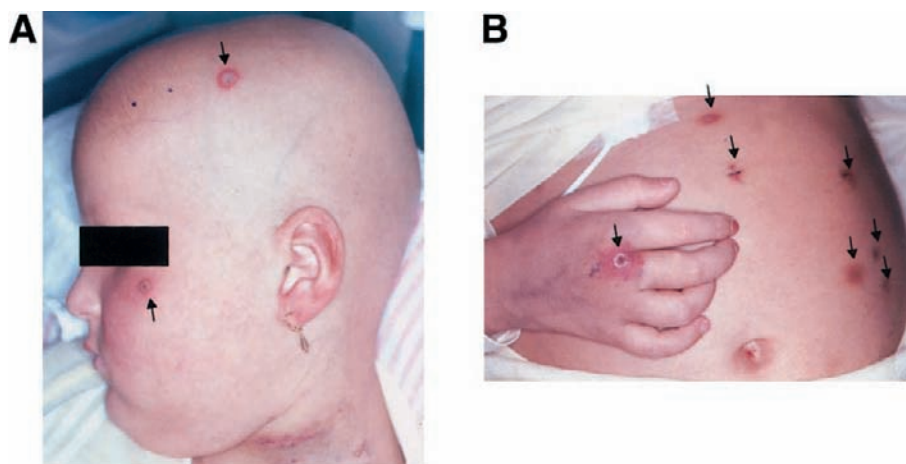
**Figure 6.** Black necrotic hard palate ulcer (A) caused by *Fusarium* species in a 29-year-old patient with leukemia and fusarial sinusitis and pneumonia. The infection later became disseminated and involved multiple organs, including the skin (B).

## DISCUSSION

This is the first attempt to characterize the cutaneous involvement in infections with *Fusarium* species in immunocompetent and immunosuppressed hosts and to compare the findings in these 2 patient populations. Our analysis yielded several findings. First, skin lesions represent a frequent manifestation (>50%) of infection by *Fusarium* species, especially among immunocompromised patients, in contrast to the rare cutaneous involvement (<10%) in infection with other opportunistic fungi, such as *Candida* species or *Aspergillus* species. Second, skin is the primary site of disseminated and life-threatening infections among a subset of highly immunocompromised pa-

tients. Third, skin is also the most common source of diagnostic material (and frequently the only one). Fourth, distinct patterns of skin involvement by *Fusarium* species exist, depending on the immune status of the host (table 2). Fifth, the mortality rate among neutropenic patients is high, regardless of whether fusarial skin lesions are localized or disseminated. This is in contrast to the immunocompromised patients with adequate neutrophil count and in whom localized skin lesions are associated with a lower mortality rate. We also describe the first patient with skin bullae as a manifestation of disseminated fusariosis.

Among immunocompetent individuals, skin lesions typically are localized and develop after skin breakdown at the site of



**Figure 7.** Multiple cutaneous fusarial skin lesions on the face and scalp (A) and abdomen (B) of an 8-year-old girl who experienced relapse of leukemia. The infection started as paranasal sinusitis, which was followed by pneumonia and skin lesions. Patient died 30 days later with persistent fusariosis and leukemia. Courtesy of Dr. Flavio Queiroz-Telles, University Hospital, Universidade Federal do Paraná, Curitiba, Brazil.

infection. It is of note that skin breakdown may precede infection by up to 1 year. Cutaneous infections in these immunocompetent hosts present most commonly as necrotic lesions that complicate extensive wounds (burns and trauma), cellulitis secondary to underlying onychomycosis, or chronic ulcers and abscesses. Skin infection may rarely resemble chromoblastomycosis, an infection caused by dematiaceous fungi.

By contrast, the majority of immunocompromised patients have disseminated skin lesions that evolve over a much shorter period of time, particularly among neutropenic patients. Lesions in these patients typically consist of multiple painful erythematous papules or nodules with necrosis, occur among neutropenic patients, and are associated frequently with cultures positive for *Fusarium* species (blood and skin) and death. These disseminated lesions may result from a skin breakdown in some patients with preexisting onychomycosis. When such patients undergo severely immunosuppressive therapy, toe or finger cellulitis develops at the site of the onychomycosis and is followed by disseminated infection (figures 4 and 5). It is likely that the preexisting skin damage allows for entry of these pathogenic fungi into the underlying soft tissues, which leads to the development of cellulitis and subsequent dissemination in a manner reminiscent of bacterial infections. The nasal sinuses are yet another primary site of fusarial infections that may lead to dissemination after severe immunosuppression (figures 6 and 7).

Our study is limited by its retrospective nature and, thus, may underestimate the true incidence of some of our findings, such as the history of previous trauma and the presence of lesions at different stages of evolution. However, the consistency of findings across various reports from different institutions and over a long period of time suggests that our analysis is an accurate reflection of the nature of the cutaneous involvement in infection by *Fusarium* species

Our findings have several implications for the clinical management of immunocompromised patients. Because skin may be the source for disseminated and frequently life-threatening fusarial infections, we recommend that patients likely to undergo severely immunosuppressive therapy undergo a thorough skin evaluation before commencing immunosuppressive therapy (table 3). All areas of tissue breakdown should be identified and suspicious skin lesions cultured, and a biopsy should be performed. The histopathological findings of infection with *Fusarium* species (branching hyaline hyphae) cannot be distinguished from those caused by infection with other opportunistic molds, such as *Aspergillus* species. Because of these remarkable similarities and the differences in susceptibility to antifungal agents between *Fusarium* species and various hyaline molds, identification by culture is critical.

Local debridement should be performed and topical antifungal agents (e.g., natamycin and amphotericin B) considered

**Table 3. Prevention of fusarial infections during severe immunosuppression.**

---

Educate patients about need to avoid the following:
Activities associated with increased risk of skin breakdown
Contact of areas with skin breakdown (onychomycosis, dermatomycosis, or other) with tap water
History and physical examination before commencing immunosuppression should ascertain the following:
History of skin lesions during previous immunosuppression
Presence of areas of skin breakdown (onychomycosis, dermatomycosis, or other) and skin lesions that imply presence of fungal infection
Preventive measures (before immunosuppression) for patients with skin breakdown include the following:
Perform local debridement with biopsy and culture of areas with skin breakdown
Apply topical antifungal agents active against <i>Fusarium</i> species and other pathogenic molds (terbinafine, natamycin, or other) at site of skin breakdown before and throughout immunosuppression
Consider delaying severely immunosuppressive therapies (when possible) until areas of skin breakdown have healed
Maintain lowest immunosuppression possible throughout therapy
Select donors very carefully in settings of organ or stem, cell transplantation (to avoid immunosuppressive effects of GVHD and organ rejection and their therapies)
Consider in vitro susceptibility testing of <i>Fusarium</i> species isolated from skin breakdown areas and incorporation of active agents in antifungal prophylactic regimen

---

**NOTE.** GVHD, graft-versus-host disease.

if *Fusarium* species are identified. In addition, severely immunocompromised patients with skin or other exposed tissue breakdown should avoid exposure to environmental sources of *Fusarium* species, such as tap water. Indeed, we have shown that hospital water may be contaminated with *Fusarium* species and may lead to patient infection [132].

Because infection with *Fusarium* species is more likely to involve the skin than infections by *Candida* species or *Aspergillus* species and because skin is the most likely source of diagnostic material, the presence of skin lesions in immunocompromised patients should raise the index of suspicion for this infection. Because of the relatively high yield of blood cultures among patients with fusarial skin lesions, immunocompromised patients with skin lesions should have blood samples collected and cultured. Identifying the specific pathogen is critical, because *Fusarium* species have variable susceptibilities to the antifungal agents that are currently used. Newer antifungal triazole agents that may have good activity against *Fusarium* species have become available. These include itraconazole, voriconazole, and posaconazole [133–139]. The development of these new antifungal drugs with activity against *Fusarium* species and the promising role of granulocyte transfusions in severely neutropenic



patients should prompt considerations for such approaches in patients with fusariosis and may improve the otherwise dismal prognosis of these patients.

## References

- de Pauw BE, Meunier F. The challenge of invasive fungal infection. *Chemotherapy* **1999**;45(Suppl 1):1–14.
- Walsh TJ, Hiemenz JW, Anaissie E. Recent progress and current problems in treatment of invasive fungal infections in neutropenic patients. *Infect Dis Clin North Am* **1996**;10:365–400.
- Rex JH, Pfaller MA, Walsh TJ, et al. Antifungal susceptibility testing: practical aspects and current challenges. *Clin Microbiol Rev* **2001**;14:643–58.
- Nelson PE, Dignani MC, Anaissie EJ. Taxonomy, biology, and clinical aspects of *Fusarium* species. *Clin Microbiol Rev* **1994**;7:479–504.
- Boutati EI, Anaissie EJ. *Fusarium*, a significant emerging pathogen in patients with hematologic malignancy: ten years' experience at a cancer center and implications for management. *Blood* **1997**;90:999–1008.
- Walsh TJ, Groll AH. Emerging fungal pathogens: evolving challenges to immunocompromised patients for the twenty-first century. *Transpl Infect Dis* **1999**;1:247–61.
- Nucci M, Queiroz-Telles F, Trabasso P, et al. Epidemiologic study of systemic *Fusarium* infection in Brazil [abstract 1421]. In: Programs and abstracts of the 40th Interscience Symposium on Antimicrobial Agents and Chemotherapy (Toronto). Washington, DC: American Society for Microbiology, **2000**:383.
- Benjamin RP, Callaway L, Conant NF. Facial granuloma associated with fusarium infection. *Arch Dermatol* **1970**;101:598–600.
- Cho CT, Vats TS, Lowman JT, Brandsberg JW, Tosh FE. *Fusarium solani* infection during treatment for acute leukemia. *J Pediatr* **1973**;83:1028–31.
- Abramowsky CR, Quinn D, Bradford WD, Conant NF. Systemic infection by fusarium in a burned child: the emergence of a saprophytic strain. *J Pediatr* **1974**;84:561–4.
- Gutmann L, Chou SM, Pore RS. Fusariosis, myasthenic syndrome, and aplastic anemia. *Neurology* **1975**;25:922–6.
- Collins MS, Rinaldi MG. Cutaneous infection in man caused by *Fusarium moniliforme*. *Sabouraudia* **1977**;15:151–60.
- Young NA, Kwon-Chung KJ, Kubota TT, Jennings AE, Fisher RL. Disseminated infection by *Fusarium moniliforme* during treatment for malignant lymphoma. *J Clin Microbiol* **1978**;7:589–94.
- Lieberman TW, Ferry AP, Bottone EJ. *Fusarium solani* endophthalmitis without primary corneal involvement. *Am J Ophthalmol* **1979**;88:764–7.
- Young CN, Meyers AM. Opportunistic fungal infection by *Fusarium oxysporum* in a renal transplant patient. *Sabouraudia* **1979**;17:219–23.
- van Dijk E, van den Berg WH, Landwehr AJ. *Fusarium solani* infection of a hypertensive leg ulcer in a diabetic. *Mykosen* **1980**;23:603–6.
- Mutton KJ, Lucas TJ, Harkness JL. Disseminated fusarium infection. *Med J Aust* **1980**;2:624–5.
- Wheeler MS, McGinnis MR, Schell WA, Walker DH. *Fusarium* infection in burned patients. *Am J Clin Pathol* **1981**;75:304–11.
- Page JC, Friedlander G, Dockery GL. Postoperative fusarium osteomyelitis. *J Foot Surg* **1982**;21:174–6.
- Kerr CM, Perfect JR, Craven PC, et al. Fungal peritonitis in patients on continuous ambulatory peritoneal dialysis. *Ann Intern Med* **1983**;99:334–6.
- Steinberg GK, Britt RH, Enzmann DR, Finlay JL, Arvin AM. *Fusarium* brain abscess: case report. *J Neurosurg* **1983**;58:598–601.
- Jakle C, Leek JC, Olson DA, Robbins DL. Septic arthritis due to *Fusarium solani*. *J Rheumatol* **1983**;10:151–3.
- Blazar BR, Hurd DD, Snover DC, Alexander JW, McClave PB. Invasive *Fusarium* infections in bone marrow transplant recipients. *Am J Med* **1984**;77:645–51.
- Kiehn TE, Nelson PE, Bernard EM, Edwards FF, Koziner B, Armstrong D. Catheter-associated fungemia caused by *Fusarium chlamydosporum* in a patient with lymphocytic lymphoma. *J Clin Microbiol* **1985**;21:501–4.
- Matsuda T, Matsumoto T. Disseminated hyalohyphomycosis in a leukemic patient. *Arch Dermatol* **1986**;122:1171–5.
- Valenstein P, Schell WA. Primary intranasal *Fusarium* infection: potential for confusion with rhinocerebral zygomycosis. *Arch Pathol Lab Med* **1986**;110:751–4.
- Anaissie E, Kantarjian H, Jones P, et al. *Fusarium*: a newly recognized fungal pathogen in immunosuppressed patients. *Cancer* **1986**;57:2141–5.
- Attapattu MC, Anandkrishnan C. Extensive subcutaneous hyphomycosis caused by *Fusarium oxysporum*. *J Med Vet Mycol* **1986**;24:105–11.
- June CH, Beatty PG, Shulman HM, Rinaldi MG. Disseminated *Fusarium moniliforme* infection after allogeneic marrow transplantation. *South Med J* **1986**;79:513–5.
- Okuda C, Ito M, Sato Y, Oka K, Hotchi M. Disseminated cutaneous *Fusarium* infection with vascular invasion in a leukemic patient. *J Med Vet Mycol* **1987**;25:177–86.
- Veglia KS, Marks VJ. *Fusarium* as a pathogen: a case report of *Fusarium* sepsis and review of the literature. *J Am Acad Dermatol* **1987**;16:260–3.
- Uchiyama N, Shindo Y, Mikoshiba H, Saito H. Cutaneous infection caused by *Fusarium solani* and *Fusarium oxysporum*. *J Dermatol* **1987**;14:471–5.
- Rippon JW, Larson RA, Rosenthal DM, Clayman J. Disseminated cutaneous and peritoneal hyalohyphomycosis caused by *Fusarium* species: three cases and review of the literature. *Mycopathologia* **1988**;101:105–11.
- Summerbell RC, Richardson SE, Kane J. *Fusarium proliferatum* as an agent of disseminated infection in an immunosuppressed patient. *J Clin Microbiol* **1988**;26:82–7.
- Nuovo MA, Simmonds JE, Chacho MS, McKittrick JC. *Fusarium solani* osteomyelitis with probable nosocomial spread. *Am J Clin Pathol* **1988**;90:738–41.
- Mowbray DN, Paller AS, Nelson PE, Kaplan RL. Disseminated *Fusarium solani* infection with cutaneous nodules in a bone marrow transplant patient. *Int J Dermatol* **1988**;27:698–701.
- Richardson SE, Bannatyne RM, Summerbell RC, Milliken J, Gold R, Weitzman SS. Disseminated fusarium infection in the immunocompromised host. *Rev Infect Dis* **1988**;10:1171–81.
- Merz WG, Karp JE, Hoagland M, Jett-Goheen M, Junkins JM, Hood AF. Diagnosis and successful treatment of fusariosis in the compromised host. *J Infect Dis* **1988**;158:1046–55.
- Venditti M, Micozzi A, Gentile G, et al. Invasive *Fusarium solani* infections in patients with acute leukemia. *Rev Infect Dis* **1988**;10:653–60.
- Anaissie E, Kantarjian H, Ro J, et al. The emerging role of *Fusarium* infections in patients with cancer. *Medicine (Baltimore)* **1988**;67:77–83.
- Sturm AW, Grave W, Kwee WS. Disseminated *Fusarium oxysporum* infection in patient with heatstroke. *Lancet* **1989**;1:968.
- Minor RL Jr, Pfaller MA, Gingrich RD, Burns LJ. Disseminated *Fusarium* infections in patients following bone marrow transplantation. *Bone Marrow Transplant* **1989**;4:653–8.
- el Ani AS. Disseminated infection caused by *Fusarium solani* in a patient with aplastic anemia. *N Y State J Med* **1990**;90:609–10.
- Viscoli C, Castagnola E, Moroni C, Garaventa A, Manno G, Savioli C. Infection with *Fusarium* species in two children with neuroblastoma. *Eur J Clin Microbiol Infect Dis* **1990**;9:773–6.

45. Helm TN, Longworth DL, Hall GS, Bolwell BJ, Fernandez B, Tomecki KJ. Case report and review of resolved fusariosis. *J Am Acad Dermatol* **1990**; 23:393–8.
46. Nadler JP. Disseminated fusarial infection. *Rev Infect Dis* **1990**; 12: 162.
47. Barrios NJ, Kirkpatrick DV, Murciano A, Stine K, Van Dyke RB, Humbert JR. Successful treatment of disseminated *Fusarium* infection in an immunocompromised child. *Am J Pediatr Hematol Oncol* **1990**; 12:319–24.
48. Lupinetti FM, Giller RH, Trigg ME. Operative treatment of *Fusarium* fungal infection of the lung. *Ann Thorac Surg* **1990**; 49:991–2.
49. Graddon JD, Lerman A, Lutwick LI. Septic arthritis due to *Fusarium moniliforme*. *Rev Infect Dis* **1990**; 12:716–7.
50. Schneller FR, Gulati SC, Cunningham IB, O'Reilly RJ, Schmitt HJ, Clarkson BD. *Fusarium* infections in patients with hematologic malignancies. *Leuk Res* **1990**; 14:961–6.
51. Gamis AS, Gudnason T, Giebink GS, Ramsay NK. Disseminated infection with *Fusarium* in recipients of bone marrow transplants. *Rev Infect Dis* **1991**; 13:1077–88.
52. Robertson MJ, Socinski MA, Soiffer RJ, et al. Successful treatment of disseminated *Fusarium* infection after autologous bone marrow transplantation for acute myeloid leukemia. *Bone Marrow Transplant* **1991**; 8:143–5.
53. Agamanolis DP, Kalwinsky DK, Krill CE Jr, Dasu S, Halasa B, Galloway PG. *Fusarium* meningoencephalitis in a child with acute leukemia. *Neuropediatrics* **1991**; 22:110–2.
54. Viviani MA, Cofrancesco E, Boschetti C, Tortorano AM, Cortellaro M. Eradication of *Fusarium* infection in a leukopenic patient treated with liposomal amphotericin B. *Mycoses* **1991**; 34:255–6.
55. Lupinetti FM, Behrendt DM, Giller RH, Trigg ME, de Alarcon P. Pulmonary resection for fungal infection in children undergoing bone marrow transplantation. *J Thorac Cardiovasc Surg* **1992**; 104:684–7.
56. Landau M, Srebrnik A, Wolf R, Bashi E, Brenner S. Systemic ketoconazole treatment for *Fusarium* leg ulcers. *Int J Dermatol* **1992**; 31: 511–2.
57. Neumeister B, Bartmann P, Gaedicke G, Marre R. A fatal infection due to *Fusarium oxysporum* in a child with Wilms' tumour: case report and review of the literature. *Mycoses* **1992**; 35:115–9.
58. Brint JM, Flynn PM, Pearson TA, Pui CH. Disseminated fusariosis involving bone in an adolescent with leukemia. *Pediatr Infect Dis J* **1992**; 11:965–8.
59. Girmenia C, Arcese W, Micozzi A, Martino P, Bianco P, Morace G. Onychomycosis as a possible origin of disseminated *Fusarium solani* infection in a patient with severe aplastic anemia. *Clin Infect Dis* **1992**; 14:1167.
60. Cofrancesco E, Boschetti C, Viviani MA, et al. Efficacy of liposomal amphotericin B (AmBisome) in the eradication of *Fusarium* infection in a leukaemic patient. *Haematologica* **1992**; 77:280–3.
61. Alvarez-Franco M, Reyes-Mugica M, Paller AS. Cutaneous *Fusarium* infection in an adolescent with acute leukemia. *Pediatr Dermatol* **1992**; 9:62–5.
62. Madhavan M, Ratnakar C, Veliath AJ, Kanungo R, Smile SR, Bhat S. Primary disseminated fusarial infection. *Postgrad Med J* **1992**; 68: 143–4.
63. Ammari LK, Puck JM, McGowan KL. Catheter-related *Fusarium solani* fungemia and pulmonary infection in a patient with leukemia in remission. *Clin Infect Dis* **1993**; 16:148–50.
64. Kurien M, Anandi V, Raman R, Brahmadathan KN. Maxillary sinus fusariosis in immunocompetent hosts. *J Laryngol Otol* **1992**; 106: 733–6.
65. Nucci M, Spector N, Lucena S, et al. Three cases of infection with *Fusarium* species in neutropenic patients. *Eur J Clin Microbiol Infect Dis* **1992**; 11:1160–2.
66. Castagnola E, Garaventa A, Conte M, Barretta A, Faggi E, Viscoli C. Survival after fungemia due to *Fusarium moniliforme* in a child with neuroblastoma. *Eur J Clin Microbiol Infect Dis* **1993**; 12:308–9.
67. Spielberger RT, Falleroni MJ, Coene AJ, Larson RA. Concomitant amphotericin B therapy, granulocyte transfusions, and GM-CSF administration for disseminated infection with *Fusarium* in a granulocytopenic patient. *Clin Infect Dis* **1993**; 16:528–30.
68. Smith AG, Bustamante CI, Wood C. Disseminated cutaneous and vascular invasion by *Fusarium moniliforme* in a fatal case of acute lymphocytic leukemia. *Mycopathologia* **1993**; 122:15–20.
69. Caux F, Aractingi S, Baurmann H, et al. *Fusarium solani* cutaneous infection in a neutropenic patient. *Dermatology* **1993**; 186:232–5.
70. Mardiak J, Danisovicova A, Trupl J, Sloboda J, Jesenska Z, Krcmery V Jr. Three cases of fatal infection due to *Fusarium solani* in patients with cancer. *Clin Infect Dis* **1993**; 17:930–2.
71. Melcher GP, McGough DA, Fothergill AW, Norris C, Rinaldi MG. Disseminated hyalohyphomycosis caused by a novel human pathogen, *Fusarium napiforme*. *J Clin Microbiol* **1993**; 31:1461–7.
72. Engelhard D, Eldor A, Polacheck I, et al. Disseminated visceral fusariosis treated with amphotericin B–phospholipid complex. *Leuk Lymphoma* **1993**; 9:385–92.
73. Martino P, Gastaldi R, Raccach R, Girmenia C. Clinical patterns of *Fusarium* infections in immunocompromised patients. *J Infect* **1994**; 28(Suppl 1):7–15.
74. Louie T, el Baba F, Shulman M, Jimenez-Lucho V. Endogenous endophthalmitis due to *Fusarium*: case report and review. *Clin Infect Dis* **1994**; 18:585–8.
75. Hennequin C, Benkerrou M, Gaillard JL, Blanche S, Fraitag S. Role of granulocyte colony-stimulating factor in the management of infection with *Fusarium oxysporum* in a neutropenic child. *Clin Infect Dis* **1994**; 18:490–1.
76. Rabodonirina M, Piens MA, Monier MF, Gueho E, Fiere D, Mojon M. *Fusarium* infections in immunocompromised patients: case reports and literature review. *Eur J Clin Microbiol Infect Dis* **1994**; 13:152–61.
77. Ellis ME, Clink H, Younge D, Hainau B. Successful combined surgical and medical treatment of fusarium infection after bone marrow transplantation. *Scand J Infect Dis* **1994**; 26:225–8.
78. Patel AS, Hemady RK, Rodrigues M, Rajagopalan S, Elman MJ. Endogenous *Fusarium* endophthalmitis in a patient with acute lymphocytic leukemia. *Am J Ophthalmol* **1994**; 117:363–8.
79. Bushelman SJ, Callen JB, Roth DN, Cohen LM. Disseminated *Fusarium solani* infection. *J Am Acad Dermatol* **1995**; 32:346–51.
80. Hansson C, Rosen K, Braide I. *Fusarium* infection with unusual skin lesions in a patient with acute lymphocytic leukemia. *Dermatology* **1995**; 191:333–5.
81. Freidank H. Hyalohyphomycoses due to *Fusarium* spp: two case reports and review of the literature. *Mycoses* **1995**; 38:69–74.
82. Raad I, Hachem R. Treatment of central venous catheter–related fungemia due to *Fusarium oxysporum*. *Clin Infect Dis* **1995**; 20:709–11.
83. Mohammedi I, Gachot B, Grossin M, Marche C, Wolff M, Vachon F. Overwhelming myocarditis due to *Fusarium oxysporum* following bone marrow transplantation. *Scand J Infect Dis* **1995**; 27:643–4.
84. Leu HS, Lee AY, Kuo TT. Recurrence of *Fusarium solani* abscess formation in an otherwise healthy patient. *Infection* **1995**; 23:303–5.
85. Lopes JO, de Mello ES, Klock C. Mixed intranasal infection caused by *Fusarium solani* and a zygomycete in a leukaemic patient. *Mycoses* **1995**; 38:281–4.
86. Velasco E, Martins CA, Nucci M. Successful treatment of catheter-related fusarial infection in immunocompromised children. *Eur J Clin Microbiol Infect Dis* **1995**; 14:697–9.
87. Wolff MA, Ramphal R. Use of amphotericin B lipid complex for treatment of disseminated cutaneous fusarium infection in a neutropenic patient. *Clin Infect Dis* **1995**; 20:1568–9.
88. Backman KS, Roberts M, Patterson R. Allergic bronchopulmonary mycosis caused by *Fusarium vasinfectum*. *Am J Respir Crit Care Med* **1995**; 152:1379–81.
89. Myoken Y, Sugata T, Kyo T, Fujihara M. Oral *Fusarium* infection in a granulocytopenic patient with acute myelogenous leukemia: a case report. *J Oral Pathol Med* **1995**; 24:237–40.

90. Eljaschewitsch J, Sandfort J, Tintelnot K, Horbach I, Ruf B. Port-a-cath-related *Fusarium oxysporum* infection in an HIV-infected patient: treatment with liposomal amphotericin B. *Mycoses* **1996**; *39*: 115–9.
91. Heinz T, Perfect J, Schell W, Ritter E, Ruff G, Serafin D. Soft-tissue fungal infections: surgical management of 12 immunocompromised patients. *Plast Reconstr Surg* **1996**; *97*:1391–9.
92. Patterson TS, Barton LL, Shehab ZM, Hutter JJ. Amphotericin B lipid complex treatment of a leukemic child with disseminated *Fusarium solani* infection. *Clin Pediatr (Phila)* **1996**; *35*:257–60.
93. Krulder JW, Brimicombe RW, Wijermans PW, Gams W. Systemic *Fusarium nygamai* infection in a patient with lymphoblastic non-Hodgkin's lymphoma. *Mycoses* **1996**; *39*:121–3.
94. Rombaux P, Eloy P, Bertrand B, Delos M, Doyen C. Lethal disseminated *Fusarium* infection with sinus involvement in the immunocompromised host: case report and review of the literature. *Rhinology* **1996**; *34*:237–41.
95. Clancy CJ, Nguyen MH. Disseminated fusariosis [photo quiz]. *Clin Infect Dis* **1996**; *23*:963–1.
96. Antony SJ. Disseminated *Fusarium* infection in an immunocompromised host. *Int J Dermatol* **1996**; *35*:815–6.
97. Glasgow BJ, Engstrom RE Jr, Holland GN, Kreiger AE, Wool MG. Bilateral endogenous *Fusarium* endophthalmitis associated with acquired immunodeficiency syndrome. *Arch Ophthalmol* **1996**; *114*: 873–7.
98. Gabriele P, Hutchins RK. *Fusarium* endophthalmitis in an intravenous drug abuser. *Am J Ophthalmol* **1996**; *122*:119–21.
99. Repiso T, Garcia-Patos V, Martin N, Creus M, Bastida P, Castells A. Disseminated fusariosis. *Pediatr Dermatol* **1996**; *13*:118–21.
100. Child FJ, Fuller LC, Higgins EM, du Vivier AW, Mufti GJ. Cutaneous presentation of *Fusarium solani* infection in a bone marrow transplant recipient. *J R Soc Med* **1996**; *89*:647–8.
101. Arrese JE, Pierard-Franchimont C, Pierard GE. Fatal hyalohyphomycosis following *Fusarium* onychomycosis in an immunocompromised patient. *Am J Dermatopathol* **1996**; *18*:196–8.
102. Flynn JT, Meislich D, Kaiser BA, Polinsky MS, Baluarte HJ. *Fusarium* peritonitis in a child on peritoneal dialysis: case report and review of the literature. *Perit Dial Int* **1996**; *16*:52–7.
103. Bleggi-Torres LF, de Medeiros BC, Neto JZ, et al. Disseminated *Fusarium* sp infection affecting the brain of a child after bone marrow transplantation. *Bone Marrow Transplant* **1996**; *18*:1013–5.
104. Kumar RR, Kumar BR, Shafiulla M, Lakshmaiah KC, Sridhar H. *Fusarium solani* infection in a patient with acute myelogenous leukemia: a case report. *Indian J Pathol Microbiol* **1997**; *40*:555–7.
105. Vasiloudes P, Morelli JG, Weston WL. Painful skin papules caused by concomitant *Acremonium* and *Fusarium* infection in a neutropenic child. *J Am Acad Dermatol* **1997**; *37*:1006–8.
106. Arney KL, Tiernan R, Judson MA. Primary pulmonary involvement of *Fusarium solani* in a lung transplant recipient. *Chest* **1997**; *112*: 1128–30.
107. Baran R, Tosti A, Piraccini BM. Uncommon clinical patterns of *Fusarium* nail infection: report of three cases. *Br J Dermatol* **1997**; *136*: 424–7.
108. Fang CT, Chang SC, Tang IL, et al. *Fusarium solani* fungemia in a bone marrow transplant recipient. *J Formos Med Assoc* **1997**; *96*:129–33.
109. Krcmery V Jr, Jesenska Z, Spanik S, et al. Fungaemia due to *Fusarium* spp in cancer patients. *J Hosp Infect* **1997**; *36*:223–8.
110. Yildiran ST, Komurcu S, Saracli MA, et al. *Fusarium* fungaemia in severely neutropenic patients. *Mycoses* **1998**; *41*:467–9.
111. Game MA, Owen WC, Mitchell DK. Cutaneous manifestations of disseminated fungal infection in an immunocompromised child. *J Pediatr* **1998**; *133*:466.
112. Sander A, Beyer U, Amberg R. Systemic *Fusarium oxysporum* infection in an immunocompetent patient with an adult respiratory distress syndrome (ARDS) and extracorporeal membrane oxygenation (ECMO). *Mycoses* **1998**; *41*:109–11.
113. Segal BH, Walsh TJ, Liu JM, Wilson JD, Kwon-Chung KJ. Invasive infection with *Fusarium chlamydosporum* in a patient with aplastic anemia. *J Clin Microbiol* **1998**; *36*:1772–6.
114. Guinvarc'h A, Guilbert L, Marmorat-Khuong A, et al. Disseminated *Fusarium solani* infection with endocarditis in a lung transplant recipient. *Mycoses* **1998**; *41*:59–61.
115. Antunes NL, Hariharan S, DeAngelis LM. Brain abscesses in children with cancer. *Med Pediatr Oncol* **1998**; *31*:19–21.
116. Paugam A, Baixench MT, Frank N, et al. Localized oral *Fusarium* infection in an AIDS patient with malignant lymphoma. *J Infect* **1999**; *39*:153–4.
117. Mangini C, de Camargo B. Fungal infection due to *Fusarium* (spp) in children with refractory hematologic malignancies. *Med Pediatr Oncol* **1999**; *32*:149–50.
118. Farina C, Vailati F, Manisco A, Goglio A. Fungaemia survey: a 10-year experience in Bergamo, Italy. *Mycoses* **1999**; *42*:543–8.
119. Ariffin H, Ariffin W, Mohamed M, Arasu A, Peng LH. Management of systemic *Fusarium* infection in children with leukemia. *Med Pediatr Oncol* **1999**; *33*:598–9.
120. Tacyildiz N, Yavuz G, Unal E, Gozdasoglu S, Ertem M, Aysev D. Fungal infection from *Fusarium* spp. in children with refractory hematologic malignancies. *Med Pediatr Oncol* **1999**; *33*:596–7.
121. Girardi M, Glusac EJ, Imaeda S. Subcutaneous *Fusarium* foot abscess in a renal transplant patient. *Cutis* **1999**; *63*:267–70.
122. Girmenia C, Iori AP, Boecklin F, et al. *Fusarium* infections in patients with severe aplastic anemia: review and implications for management. *Haematologica* **1999**; *84*:114–8.
123. Peltroche-Llacsahuanga H, Manegold E, Kroll G, Haase G. Case report: pathohistological findings in a clinical case of disseminated infection with *Fusarium oxysporum*. *Mycoses* **2000**; *43*:367–72.
124. Fergie JE, Huang DB, Purcell K, Milligan T. Successful treatment of *Fusarium solani* ecthyma gangrenosum in a child with acute lymphoblastic leukemia in relapse. *Pediatr Infect Dis J* **2000**; *19*:579–81.
125. Lo NL, Di Cataldo A, Ragusa R. Successful treatment of *Fusarium* (spp) infection in a child with acute lymphoblastic leukemia. *Med Pediatr Oncol* **2000**; *34*:356–7.
126. Guarro J, Nucci M, Akiti T, Gene J. Mixed infection caused by two species of *Fusarium* in a human immunodeficiency virus-positive patient. *J Clin Microbiol* **2000**; *38*:3460–2.
127. Musa MO, Al Eisa A, Halim M, et al. The spectrum of *Fusarium* infection in immunocompromised patients with haematological malignancies and in non-immunocompromised patients: a single institution experience over 10 years. *Br J Haematol* **2000**; *108*:544–8.
128. Okada H, Hamatani S, Kondo M, et al. Successful treatment of disseminated *Fusarium* infection in an infant with leukemia. *Int J Hematol* **2000**; *72*:494–8.
129. Sampathkumar P, Paya CV. *Fusarium* infection after solid-organ transplantation. *Clin Infect Dis* **2001**; *32*:1237–40.
130. Austen B, McCarthy H, Wilkins B, Smith A, Duncombe A. Fatal disseminated fusarium infection in acute lymphoblastic leukaemia in complete remission. *J Clin Pathol* **2001**; *54*:488–90.
131. Miyazaki M, Miyakoshi S, Kami M, et al. Systemic fusariosis after a preparative regimen including thiotepea, VP-16 and busulfan used for blood stem cell transplantation in Hodgkin's disease. *Leuk Lymphoma* **2001**; *40*:441–4.
132. Anaissie EJ, Kuchar RT, Rex JH, et al. Fusariosis associated with pathogenic fusarium species colonization of a hospital water system: a new paradigm for the epidemiology of opportunistic mold infections. *Clin Infect Dis* **2001**; *33*:1871–8.
133. Carrillo-Munoz AJ, Quindos G, Ruesga M, et al. Activity of itraconazole against clinical isolates of *Aspergillus* spp and *Fusarium* spp determined by the M38-P NCCLS method. *Rev Esp Quimioter* **2001**; *14*:281–5.
134. Romano C, Miracco C, Difonzo EM. Skin and nail infections due to *Fusarium oxysporum* in Tuscany, Italy. *Mycoses* **1998**; *41*:433–7.
135. Resnik BI, Burdick AE. Improvement of eumycetoma with itraconazole. *J Am Acad Dermatol* **1995**; *33*:917–9.

136. Reis A, Sundmacher R, Tintelnot K, Agostini H, Jensen HE, Althaus C. Successful treatment of ocular invasive mould infection (fusariosis) with the new antifungal agent voriconazole. *Br J Ophthalmol* **2000**; 84:932–3.
137. Clancy CJ, Nguyen MH. In vitro efficacy and fungicidal activity of voriconazole against *Aspergillus* and *Fusarium* species. *Eur J Clin Microbiol Infect Dis* **1998**; 17:573–5.
138. Arikan S, Lozano-Chiu M, Paetznick V, Nangia S, Rex JH. Microdilution susceptibility testing of amphotericin B, itraconazole, and voriconazole against clinical isolates of *Aspergillus* and *Fusarium* species. *J Clin Microbiol* **1999**; 37:3946–51.
139. Lozano-Chiu M, Arikan S, Paetznick VL, Anaissie EJ, Loebenberg D, Rex JH. Treatment of murine fusariosis with SCH 56592. *Antimicrob Agents Chemother* **1999**; 43:589–91.