

Progress in Epilepsy Research

Cysticercosis and Epilepsy: A Critical Review

*Arturo Carpio, †Alfonso Escobar, and ‡W. Allen Hauser

*Faculty of Medicine and Research Institute, University of Cuenca, Cuenca, Ecuador; †Department of Pathology, National Institute of Neurology and Neurosurgery of Mexico, and Department of Neurobiology Institute for Biomedical Research, University of Mexico, Mexico City, Mexico; and ‡G. H. Sergievsky Center, College of Physicians and Surgeons, Columbia University, New York, New York, U.S.A.

Summary: Neurocysticercosis (NC) remains a major public health problem in developing and some developed countries. Currently, the best procedures for diagnosing NC are neuroimaging studies. Immunoserologic assays, such as enzyme-linked immunoelectrotransfer blot assay (EITB) or enzyme-linked immunosorbent assay (ELISA), detect antibodies against *Taenia solium*, or cysticercus. Consequently, they are useful in identifying a population at risk of contact with the parasite but do not necessarily indicate a systemic active infection. Most seropositive individuals are asymptomatic. No data from prospective studies concern the proportion of these individuals that will develop seizures or other neurologic symptoms. There is a discrepancy between the results of serologic assays and neuroimaging studies: >50% of those individuals with NC diagnosed by computed tomography (CT) scan test EITB negative.

Pathophysiologic classification of NC into active, transitional, and inactive forms permits a good correlation between clinical manifestations and neuroimaging procedures and facilitates medical and surgical management and research. The most frequent clinical manifestations of NC are seizures. We assume that NC is the main cause of symptomatic epilepsy in

developing countries; however, no case-control or cohort studies demonstrate this association. Most patients with NC with seizures have a good prognosis; nevertheless, further studies analyzing factors related to recurrence of seizures and possibilities of discontinuation of antiepileptic medications (AEDs) are needed.

Regarding treatment of NC with antihelminthic drugs, no controlled clinical trials exist that establish specific indications, definitive doses, and duration of treatment. The most effective approach to taeniasis/cysticercosis infection is prevention. This should be a primary public health focus for developing countries.

We critically review the available information regarding the epidemiology and diagnosis of human cysticercosis, the pathophysiology and imaging correlation of the parasite in the central nervous system (CNS) of the host, the relation between seizures or epilepsy and NC, and the issues surrounding the treatment and prognosis of NC, including the use of antihelminthic therapy. **Key Words:** Epilepsy—Cysticercosis—Epidemiology—Antihelminthic treatment—Imaging studies.

At the end of the twentieth century, taeniasis and cysticercosis remain a world public health problem, not just in developing countries but increasingly in developed countries. This is due to increasing immigration from and more frequent travel to endemic regions (1-3). These parasitic diseases are related to poverty, illiteracy, and deficient sanitary infrastructures. For these reasons, cysticercosis has been designated a "biologic marker" of the social and economic development of a community (4,5). One or several parasites may go undetected in the brain of a host throughout his or her lifetime; alternately, the parasites can trigger florid symptoms. Neurocysticercosis (NC) appears to be commonly associated with clinical manifestations such as seizures, headaches, and

focal neurologic deficits, leading to long-term neurologic sequelae such as epilepsy, hydrocephalus, and dementia (6,7).

Whereas important advances in the diagnosis of NC have been achieved in the last 2 decades, many aspects pertaining to the natural history of the parasite infestation, its treatment, and its prognosis still await further knowledge. Although the infecting mechanism is well known, very few, if any, preventive measures have been taken worldwide to eradicate cysticercosis.

HOST-PARASITE BIOLOGY AND IMMUNE RESPONSE

Humans are the only known host of the adult cestode parasite *Taenia solium* in the intestine. Infection is acquired by ingesting undercooked pork infected with taenia larvae (cysticerci). The cysticerci evaginate in the

Accepted December 15, 1997.

Address correspondence and reprint requests to Dr. A. Carpio at P.O. Box 0101-719, Cuenca, Ecuador.

intestines, where they mature into adult worms. The worms consist of a scolex, which attaches itself to the intestinal wall, and numerous proglottides (segments). Proglottides and eggs are intermittently shed into the stools. The intermediate host, typically the pig, is infected by ingesting parasite eggs or proglottides containing eggs (porcine cysticercosis). The oncospheres escape from the eggs and penetrate the intestinal mucosa, migrating through the bloodstream and lodging in the tissues. Over a period of weeks to months, they evolve into larvae that enlarge and mature into cysticerci. The life cycle is completed when humans ingest pork contaminated with cysts (8).

Human cysticercosis is acquired from the "accidental" ingestion of ova excreted by human tapeworm carriers in their feces. In humans, the most common route of infection is ingestion of *T solium* eggs from contaminated food; very rarely is infection acquired from fecal-oral autoinfestation in patients harboring the adult parasite in their intestines (9). Although cysts can develop in any human tissue, they have a predilection for the central nervous system (CNS), skeletal muscle, subcutaneous tissue, and the eye. The parasites arrive at the CNS via blood vessels and tend to locate in the richly irrigated gray matter. From there, the parasites migrate to the choroidal plexuses and may end up in the ventricles or the subarachnoid space. When the cysticerci are located in the CNS, the resulting disease is called NC.

In humans and pigs, cysticerci may live within host tissues without causing inflammation or disease. This failure of living cysticerci to produce an immune response may be due to sequestration within immunologically privileged sites, antigenic shifts, molecular mimicry of host-like antigenic determinants, masking of cysticercal antigens by host immunoglobulins, and modulation of host immune responses (10). The immune response to cysticerci has been studied mainly because of the need for a diagnostic blood test. Although the literature consists of numerous serologic tests carried out with varying degrees of scientific rigor, it is clear that virtually all cases of symptomatic cysticercosis are associated with a detectable immune response (11,12). Infection with *T solium* often results in increased production of serum immunoglobulins (Igs) and formation of specific antibodies, mainly of the IgG class. Some patients have IgM, IgA, and IgE antibodies (13); however, these subclass responses are less common than IgG. It is possible that most infected hosts produce multiple antibodies of different specificity that appear at different intervals after infection, apparently in response to the qualitative and quantitative changes in excretory, secretory, and somatic antigens during the various phases of parasitic development (2).

The immunology of cysticercosis is an area of research with many intriguing questions. The response is

unpredictable, ranging from a complete tolerance to an intense immune response (10,14). Moreover, a single patient may show an intense inflammation around a cyst at any stage of the degeneration process, together with viable cysts without inflammation and several calcifications scattered in the brain. Autopsies of victims of warfare and road traffic accidents have revealed that a large proportion of NC infections are asymptomatic, discovered incidentally at necropsy (10). Frequently, multiple parenchymal calcifications have been incidentally detected in asymptomatic individuals during imaging studies. These calcifications evolve from a viable cyst through degenerative or transitional phases. The individuals harboring these parasites presumably have a "silent immune response" and a remarkable tolerance to the parasite.

EPIDEMIOLOGY

There are many reasons for the difficulty in studying the epidemiology of NC. The natural history of the clinical aspects of NC is not completely understood. Presumably a high percentage of the population harboring NC remains asymptomatic (15–17). Among the symptomatic patients, the clinical manifestations of NC are polymorphic, and their clinical course is unpredictable (17–21). The only truly reliable "gold standard" for diagnosing NC is pathologic confirmation through biopsy or autopsy. Unfortunately, these procedures have obvious limitations. In spite of the fact that there are no trustworthy data concerning the specificity and sensitivity of NC imaging diagnostic studies, computed tomography (CT) scans and magnetic resonance imaging (MRI) are the main tools of NC diagnosis (16,19,20,22–33) and must be considered as close to a gold standard as we now have. However, these procedures are impractical for application in field studies because they are expensive, even for developed countries. Longitudinal or prospective studies for analyzing factors associated with morbidity, treatment, or prognosis are also very expensive and time consuming.

There are few reliable data on the prevalence of intestinal taeniasis due to *T solium*. Recent studies that have included antigen-detection assays and collection of post-treatment stool samples have shown that stool examination is an insensitive method for identifying tapeworm carriers (34). Most publications on the frequency of NC (35) are based either on autopsy or biopsy materials or are culled from neurologic settings and general hospitals. Most reports fail to provide even minimal information regarding diagnostic criteria and definitions; consequently, these data are definitely biased and hardly representative of those of the general population. Serologic assays that use crude, nonspecific antigens have been used for individual diagnosis and epidemiologic surveys,

but they lack both sensitivity and specificity (36–38). In enzyme-linked immunosorbent assay (ELISA), for example, cross-reactions with other helminthic infection occur (37). Nieto (39), who designed a complement fixation test for diagnosing NC in the cerebrospinal fluid (CSF), warned against the use of tests in sera due to their unreliability.

An enzyme-linked immunoelectrotransfer blot assay (EITB) using specific glycoprotein antigens was developed for the immunodiagnosis of human cysticercosis (40,41) with high reported sensitivity (98%) and specificity (100%). A further study (42) confirmed the original results in patients with two or more cysts shown by CT or MRI (94% sensitivity), but sensitivity was markedly lower (28%) in patients with single enhancing cysts or calcifications. Some recent epidemiologic surveys for human cysticercosis using the EITB assay reported a seroprevalence of 8% in Peru (43) and 10.8% in Mexico (5); however, other surveys using the same procedure reported prevalence as high as 47.3% in India (41) and as low as 1.2% in Peru (44). These differences are probably due to the fact that the populations surveyed had different risks for infection (44). Most seropositive individuals in these populations were asymptomatic.

There are no data from prospective studies concerning the proportion of seropositive individuals that will develop seizures or other neurologic symptoms. The Peruvian and Mexican studies reported an association between seizures and cysticercosis. A substantially higher proportion of patients with epilepsy versus those without were EITB positive [Peru, 12 and 3%, respectively (36); Mexico, 29 and 8%, respectively (5)]. Some other studies also reported such an association (46–49). However, the proportion of individuals in these studies who do not have epilepsy and are EITB-positive is lower than the proportion of seropositivity in the general population. Furthermore, the proportion of seropositivity in patients with epilepsy is more or less similar to that reported in the general population, in spite of the fact that similar methods were used by the same authors. The questions raised by these facts remain intriguing. A study in Guatemala (50) found EITB seroprevalence to range from 10 to 17% in rural populations but did not establish a correlation between seropositivity and a history of seizures or epilepsy.

A report from Ecuador (13), conducted to determine the rate of EITB seropositivity among family members of patients with NC compared with those of the general population, showed the EITB test to be positive in 12% of family members and 4% of the general population ($p < 0.05$). This study confirms the high rate of seropositivity of cysticercosis among individuals in a developing country and that household contacts with patients with NC entail a risk of acquiring cysticercosis that is three times higher than that of the general population. How-

ever, only 18% of family members with a positive EITB test had parenchymal lesions on subsequent CT scan.

These epidemiologic studies demonstrate a potential impact of cysticercosis on public health, but it should be noted that the presence of antibodies in the host against *T solium* or cysticercus or both does not necessarily mean that an individual has an active cysticercus. Schantz et al (51) found that serum antibodies (either by ELISA or EITB tests) were related to NC, which was diagnosed by CT or MRI, in only 30% of cases. A study in Peru (52) used the EITB assay to determine the sensitivity and specificity of the CT scan for diagnosing NC. This is a questionable and perhaps doubtful procedure because, as noted, the EITB detects systemic antibodies against *T solium* or cysticercus or both but not necessarily cysticerci in the brain. Conversely, in this same study (52), >50% of individuals with NC diagnosed by CT tested EITB negative.

In a study of a selected rural population of 2,723 individuals in Ecuador (46), 31 patients were diagnosed with epilepsy. CT scans were performed on 26 patients and EITB on 28 patients. NC was detected with CT in 58% (16) of the cases; EITB was positive in only 21.4% of these. These results show an evident disagreement between CT and EITB. We believe that all these uncertainties are due, in part, to aspects related to the method of study, such as improper selection of patients with epilepsy, and lack of uniform, accurate definitions of NC and epilepsy (i.e., differentiation between provoked and unprovoked seizures). There is no reliable information regarding the proportion of systemic cysticercosis in individuals who also have CNS involvement. Further studies on the general population, randomly selected, are needed.

Attempts to eradicate taeniasis/cysticercosis by means of massive treatment with antihelminthic drugs have been performed in Ecuador (53) and Mexico (54,55). These programs may produce initial beneficial results but have been shown to be ineffectual when reevaluated some years after their application (56). The prevalence of pork cysticercosis has diminished in many industrialized countries, and in some, has finally disappeared thanks to the modernization of hog farming and improvements in sanitation. However, cysticercosis, as well as *T solium* infections, are often imported into the United States and western Europe by immigrants, refugees, and travelers from countries where the infection is endemic. These persons may develop their first onset of NC while staying in the country they visit or become a source of infection for local residents through fecal-oral routes of contamination (2,8). For example, 1.3% of the members of an Orthodox Jewish community in New York City were found to have positive EITB assays. Their seropositivity was associated with the presence of domestic employees who were from regions of endemicity (1).

PATHOPHYSIOLOGY AND IMAGING CORRELATION OF NEUROCYSTICERCOSIS

The natural history of the cysticerci in the CNS is not entirely understood. CT scans and MRIs have been useful in studying the evolution of the cysticercus within the brain parenchyma (22–33,57–71). The relation between imaging studies and the changes occurring in anatomy and pathology have been described by Escobar (9,72). In spite of the fact that no prospective studies show the differences between imaging procedures, MRI is probably more useful than CT in detecting intraventricular and subarachnoidal cysts, as well as the accompanying signs of cyst degeneration and pericystic inflammatory reaction, whereas the CT scan is preferred for the detection of parenchymal calcifications (16,22,24,29,31).

Once the oncospheres are in the CNS vascular net, the method of penetration into the vascular wall to reach adjacent nervous tissue is not known. What is well established is that the parasite does not remain inside the vessel, as some authors have asserted (9). Once the oncosphere has passed into the parenchyma, it grows and evolves through vesicular, colloidal, granular-nodular, and calcified phases (9,72). So far, no experimental evidence confirms this sequence; but CT scans or MRIs can identify these four phases. In the vesicular phase, the host tends to show immune tolerance. In most cases, there is no surrounding parenchymal reaction; the larva lives inside a translucent liquid-filled cystic structure surrounded by a thin membrane, where it can remain viable from a few months to several years (72,73). When the larva is viable, the CT scan—without enhancement by contrast media—depicts circumscribed, rounded, hypodense areas, varying in size and number (16,22–26,29–32) (Figs. 1–3). The average size of the cyst is 10 mm in diameter, but ranges from 4 to 20 mm. Larger

cysts are identified in the ventricles. In the MRI, the vesicular larva appears with a cerebrospinal fluid (CSF)-like intensity signal on all sequences (see Figs. 1 and 3) and no surrounding high signal on T₂-weighted images (27,28,33,60,67,71). Both MRI and CT may show a high intensity, 2–4 mm mural nodule depicting the scolex in the interior of some parenchymal vesicular cysts (see Figs. 1–3). This picture has been named “hole-with-eccentric dot imaging” (27) or “starry night effect” (74) and could be considered pathognomonic of cysticercosis; this phase corresponds to the active parenchymal form of the proposed classification of NC (29).

Two pathologic changes take place when the host immune system reacts against the parasite (29,72). First, in the colloidal phase, the parasite begins to show degenerative changes, the vesicular fluid takes on a gelatinous colloidal aspect, and the wall thickens (72). In this phase, the contrast-enhanced CT scan shows an annular enhancement surrounded by irregular perilesional edema (16,22–26,29–32) (Figs. 3 and 4). The fluid content gives slightly higher signal than CSF and is sometimes isodense with the parenchyma on T₁- or proton density-weighted images or both, and gives high signal on T₂-weighted images (27,28,33,66,67,70,71). The capsule shows higher signal than the adjacent brain with thick ring enhancement on T₁-weighted images, whereas on T₂-weighted images, there is a low ring signal surrounded by high-signal lesion, due mostly to edema (33, 66,67,70,71). The second pathologic change that takes place occurs in the nodular-granular phase. The vesicle tends to shrink, its content becoming semisolid as it is progressively replaced by granulomatous tissue (67). By using noncontrast CT scan, these findings could correspond to a diffuse hypodense area with irregular borders. After the administration of contrast media, a small, hyperdense, rounded, nodular image surrounded by

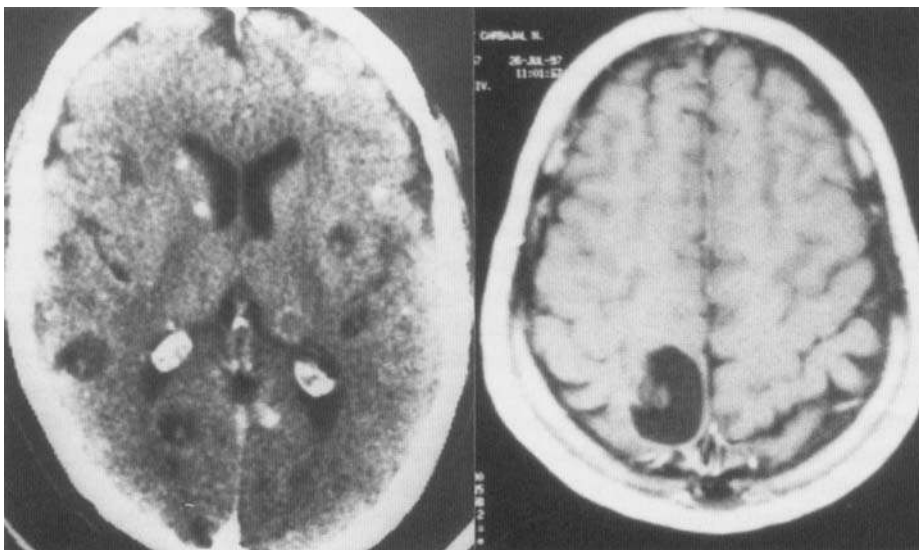
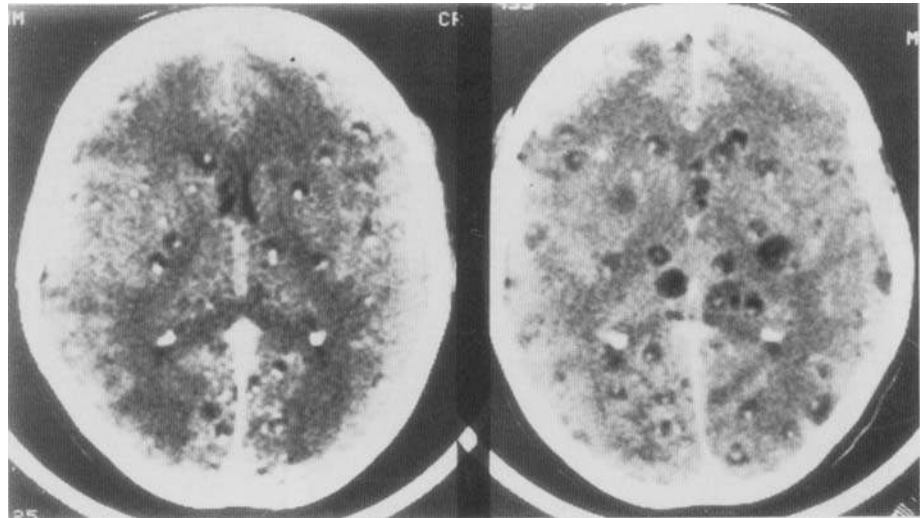


FIG. 1. Typical images of cysticerci. **Right:** Computed tomography (CT) scan showing many active cysts with scoleces and calcifications in both hemispheres; a ring-enhancing (transitional) cyst on left thalamus. **Left:** A T₁-weighted image showing viable active cyst with a clearly defined scolex with pedicle.

FIG. 2. Postcontrast computed tomography (CT) scans of a patient with seizures and intracranial hypertension syndrome, who received albendazole treatment. **Right:** Multiple active cysts with the scolex in their interior (vesicular phase). **Left:** Twelve months after treatment, more cysts appeared, some of which increased in size.



edema is observed (22,24,29,31; Fig. 5). In this stage, T₂-weighted images are the most striking, as they show the change in the signal from the cyst fluid (27,33). The nodular isointense or low signal seen in some lesions is probably the result of early mineralization of the cyst associated with hyaline degeneration (72). The low signal probably represents the marginal mineralized scolex inside the residual cyst, which will show as a bulls-eye

on CT (58). In these two consecutive phases, the parasite shows a progressive decay; thus it cannot be considered either "active" or "inactive," because of the surrounding inflammatory response. It is an intermediate form that some authors call the "acute" (75) or "focal encephalitic" phase (65). Carpio et al. (29) argued that these names are somewhat ambiguous and proposed a new category called "transitional" because the cysticer-

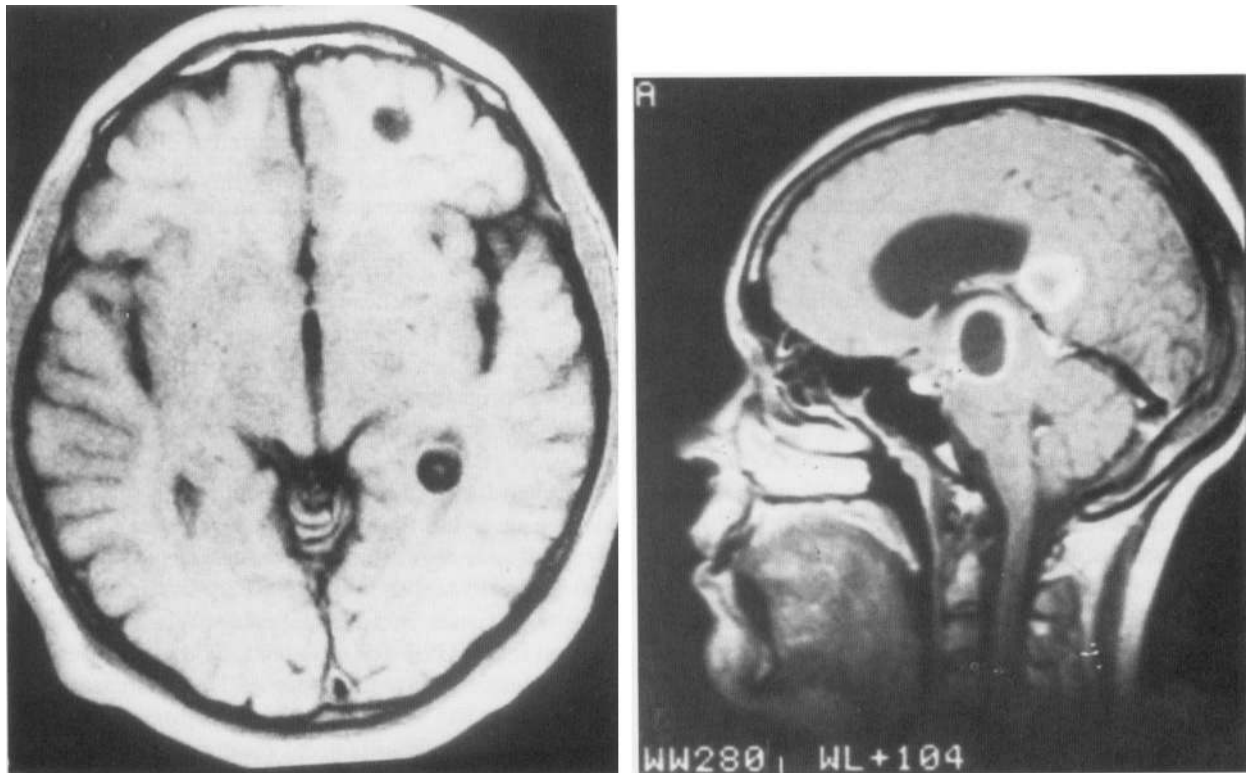


FIG. 3. Magnetic resonance images (MRI) of neurocysticercosis. **Right:** T₁-weighted MRI shows two active cysts with the scolex in their interior (vesicular phase). **Left:** Gadolinium-enhanced T₁-weighted MRI of two cysts in the transitional phase (Courtesy of Dr. Reynaldo Paez).

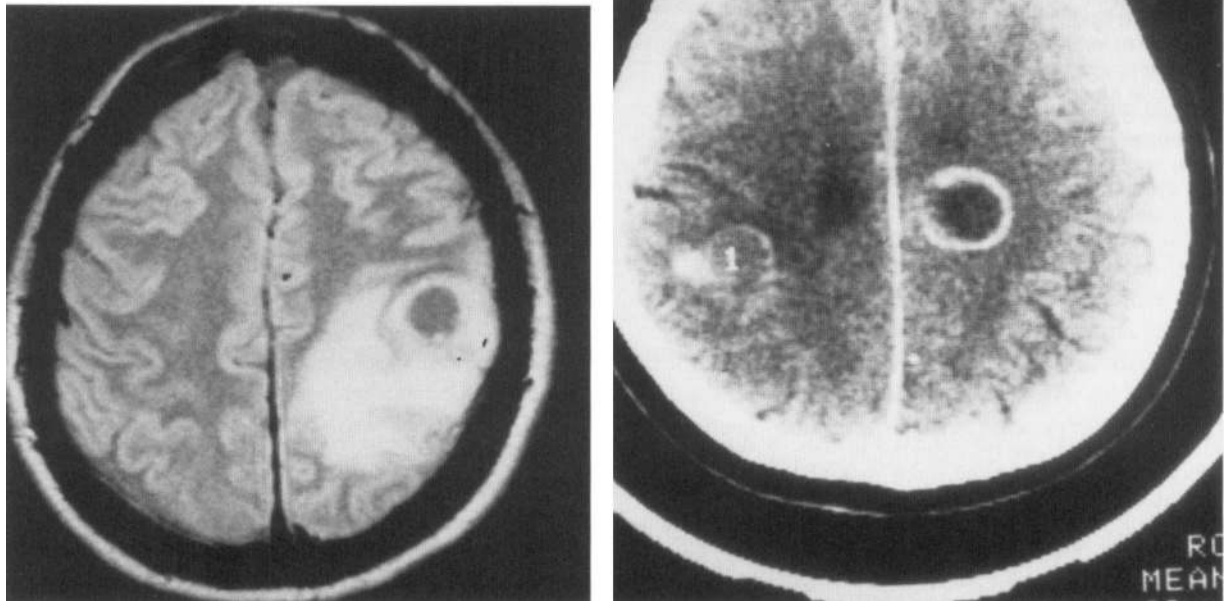


FIG. 4. Cysticerci in the transitional phase. **Right:** Postcontrast computed tomography (CT) scan shows a ring-enhancing cyst (colloidal phase) on left hemisphere and a nodular-enhancement image surrounded by edema (nodular-granular phase) on right hemisphere. **Left:** Proton density-weighted magnetic resonance image shows thick capsule with adjacent scolex and perilesional edema (colloidal phase).

cus has entered into a degenerative process. Although these pathologic changes are associated with symptoms (usually seizures or headaches), they may not cause any symptoms at all.

The cysts in the transitional phase may be single or multiple. In the latter case, if they coexist with other cysts in the vesicular phase and disseminated calcified nodules in the cerebral parenchyma, the most likely diagnosis is NC (see Fig. 1). However, when there is only one cyst in the transitional phase, it corresponds to the so-called "single enhancing lesion on CT" (SECTL) (see Fig. 5) or hyperintense lesion on MRI, which corresponds to a special syndrome discussed in more detail later.

Finally, when the parasite dies, a mineralization and resorption process occurs, ending in a calcified nodule that lodges permanently in the CNS (29,72). The non-contrasted CT shows a rounded, homogeneous hyperdense area, showing no enhancement of the contrast media (22,24,29,31,76; see Figs. 1 and 5). In the MRI, only the proton density-weighted image shows a low-intensity lesion (33,66,67,70,71). This phase corresponds to the inactive parenchymal form of the proposed classifications of NC (29,77). It is not uncommon to see multiple calcifications disseminated in the parenchyma simultaneous with viable cysts and transitional-stage lesions. This is a typical image of cysticercosis;

nevertheless, when this phase coexists with other active or transitional phases, it is difficult to distinguish between reinfection during the patient's life span and the varying pace of parasite evolution.

One form of NC that has different clinical and radiologic characteristics from those described is the so-called "cysticercotic encephalitis" that occurs mainly in children and young women (78-81). The noncontrast CT image shows diffuse and intense cerebral edema and small or collapsed ventricles; with contrast media, multiple, small, hyperdense, nodular, or annular images appear disseminated throughout the whole cerebral parenchyma (Fig. 6). The underlying pathology appears as an intense inflammatory reaction composed of lymphocytic, plasmocytic, and eosinophilic cell exudates (72).

When the parasites are located in the subarachnoid space or inside the ventricular system, their process of evolution is also different from the usual path. Surgical data have established that the parasites in this location usually remain in the vesicle stage (82-84). Being immersed in a CSF-rich environment, these cysticerci can evolve into the racemose form ("Traubenhydatiden") of NC (72). The racemose form constitutes a hydropic change that leads to large or even giant vesicles usually devoid of scolex; the parasite, unable to cope with the dropsy process, vanishes (9,72). These racemose cysts tend to show a rapid process of hyalinization of the cyst

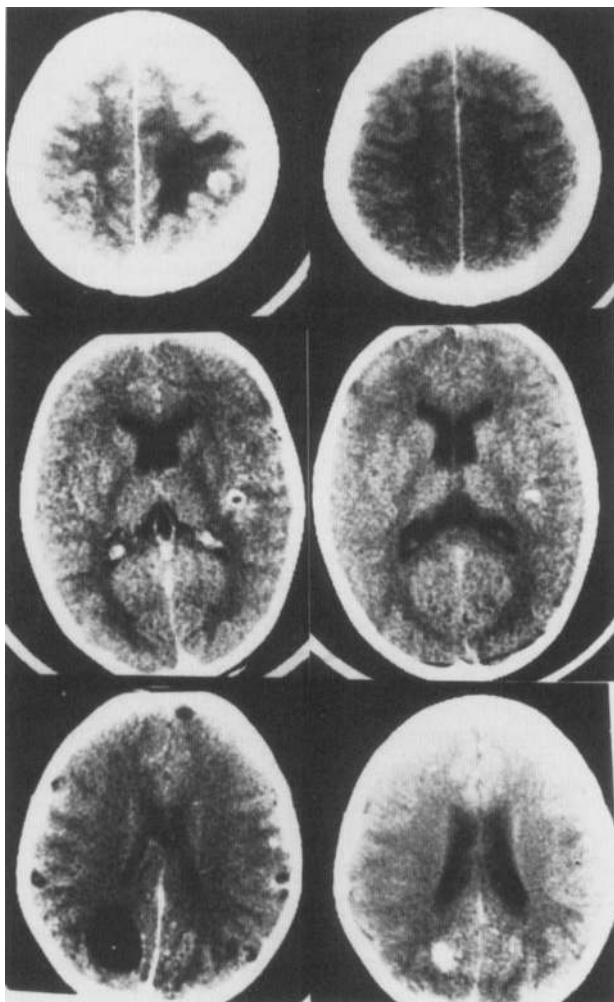


FIG. 5. Natural history of neurocysticercosis (NC). **Top right:** Parietal single nodular-enhancing lesion (transitional, nodular-granular phase). **Top left:** Six months later the lesion has disappeared. **Center right:** Single annular-enhancing lesion (transitional, colloidal phase). **Center left:** Ten months later the cyst was replaced by a calcification. **Bottom right:** Large occipital active cyst (vesicle phase) and many small cortical cysts. **Bottom left:** After 18 months, the occipital cyst has been replaced by a calcification, and the remaining cysts have disappeared.

wall. These types of cysts are most frequently located either in the basal cisterns or inside the sylvian valley and can reach 100 mm in diameter (28,73).

The noncontrasted CT depicts a hypodense image in the subarachnoid or ventricular space; the cysts deform the surrounding structures, and noncommunicating hydrocephalus occurs (16,17,24,26). Before MRI, intraventricular NC had been diagnosed with metrizamide CT ventriculography (27,60,82,84); however, this is an invasive method associated with possible misdiagnosis in fourth-ventricle cysts (83,84). The MRI (proton or T₂-weighted) more precisely shows the cyst as a hypointense CSF-like image in all phases; it permits a direct visualization of intraventricular cysticercosis by identifying the cyst wall, scolex, or both (27,66,71). The ven-

tricular ependymal lining reacts to the cysts, causing an inflammatory reaction or ependymitis, which can be visualized by CT or MRI as a high-intensity signal in the ependymal layer. Gadolinium-enhanced MRI is more sensitive than contrast-enhanced CT to detect ependymitis (66,70,71). There is no information regarding the natural history of the parasite inside the ventricular system or the subarachnoid space; evidence of calcifications in these locations is scarce. From the experience of one of us (A.E.), racemose cysticerci tend to show easily hyaline degeneration of the cyst wall with an associated inflammatory reaction. Once the hyalinization process is ended, calcium salts tend to be deposited in the cyst wall, but slowly; how long this takes to become calcified is unknown. A few cases of single calcified cysticercus in the fourth ventricle have been found.

When the parasite is located in the subarachnoid space, it also can cause a meningeal inflammatory process, with pleocytosis and increased protein on the CSF (7,29,67,70,72). The parasite degenerates to a hyaline mass and remains trapped inside the gummatous thickening of the leptomeninges, where the remains are surrounded by a granulomatous lesion with many multinucleated giant macrophages (9,72). Thus, identification of the parasites is made only by histologic examination of a stained section. As a sequel to this chronic intense inflammatory process, fibrosis and thickening of the leptomeninges also may lead to chronic hydrocephalus. Viewed with the naked eye, it is difficult to differentiate one specimen with basal meningitis from others with chronic infectious pathologies (e.g., tuberculous meningitis).

Gadolinium enhancement of MRI or contrast-enhanced CT clearly depict the leptomeningeal thickening along the cisterns ventral to the brain stem, perimesencephalic, and sylvian valley (66,67,85). If parenchymal calcified nodules coexist, the diagnosis may be indirectly reinforced (29). There may be vasculitis with secondary ischemic lesions (6,7,86–90).

CLINICAL FEATURES

Many concepts proclaimed >50 years ago in landmark articles (91–98) continue with no modification. MacArthur (92) observed that “cysticerci while alive enjoyed a relative tolerance on the part of the host, but after their death acted as foreign irritants. . . .” López-Albo (91) mentioned the spontaneous resolution of seizures and their subsequent recurrence. Clinical manifestations of NC have been extensively described in classic papers (95–99), which conclude that they are varied and depend on number and localization of cysts, as well as host immune response to the parasite. These authors confirmed the diagnosis of NC mainly by means of biopsy or necropsy. With the advent of CT in the 1970s, diagnosis of NC was

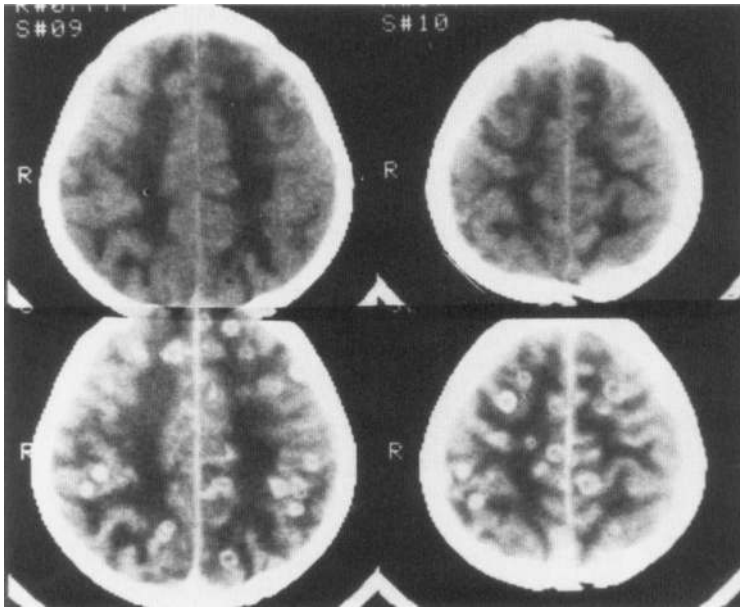


FIG. 6. Cysticercotic encephalitis. **Top:** Noncontrast computed tomography (CT) scans show diffuse low attenuation of subcortical white matter. **Bottom:** Contrast CT scans show multiple small, nodular and annular areas of abnormal enhancement in brain parenchyma.

improved; since then, countless publications confirmed that NC is characterized by clinical polymorphism, and that in almost every patient, the disease takes its own particular course. Most reports worldwide agree that the most frequent clinical manifestations are seizures, increased intracranial hypertension, focal neurologic deficits, and mental changes (6,7,16,86–99). Myriad syndromes were described, such as manifestations of brain stem dysfunction, cerebellar ataxia, sensory deficits, involuntary movements, stroke, dementia, and hydrocephalus, as well as some rare and exotic symptoms (6,7,16,100–118). Most of these clinical manifestations develop over a period of a few days, weeks, or months, with periods of remission and relapse, probably due to different evolutionary stages of the parasite.

Classification of NC

Before the advent of the CT scan, several authors published different classifications of NC based on varied clinical and anatomic criteria, causing difficulties in developing a uniform criterion for NC classification (100,118). A criterion based on the prognosis of the illness as malignant or benign seems useful but limits itself to that particular factor of prognosis (119). Sotelo et al. (77) proposed a classification of active and inactive forms of NC based on the evidence of cysts in imaging studies or inflammatory signs on CSF analysis as an indication of immune activity against the parasites. Included among the so-called active forms were cysts in a degenerative process. In this degenerative phase, the parasite is dead but there is a strong inflammatory reaction of the brain tissue adjacent to the cyst and marked cerebral edema; therefore, it belongs to another specific evolutionary stage with different clinical and therapeutic repercussions.

Carpio et al. (29) proposed an improved and widely accepted classification (31–33,71,108) based on the viability and location of the parasite in the CNS of the host: active, when the parasite is alive, transitional if it is in the degenerative phase, and inactive, if there is evidence of its death. Each viability category was subdivided into parenchymal and extraparenchymal forms. The viability criterion is very important, as it allows us to analyze the natural history of the parasite, and, according to the parasite's evolutionary stage, the production of physiopathologic changes in the host's CNS. On the basis of this classification, it is possible to relate clinical manifestations to each category of the proposed classification. For example, in a majority of 336 patients (29), seizures were the main symptom with active (82%) and transitional (88%) parenchymal forms in whom the inflammatory reaction of the adjacent brain tissue may also have been a contributing factor. On the other hand, cranial nerve abnormalities and intracranial hypertension syndromes were more frequent in meningeal forms due to the arachnoiditis process (Table 1).

Seizures or epilepsy as main clinical manifestation of NC

Almost all authors agreed that seizures are the most frequent clinical manifestation of NC (91–118). However, some authors (120–122) used the expression “seizures” indiscriminately for epilepsy, and vice versa. In fact, although all people with epilepsy experience seizures, not all individuals with seizures have epilepsy (123). This distinction is not only one of semantics; it is very important from a clinical and epidemiologic point of view to standardize definition criteria and to make studies comparable. Definitions recommended by the In-

TABLE 1. Classification and clinical manifestations in 336 patients with neurocysticercosis^a

Viability and location	Patients n (%)	Seizures n (%)	IH n (%)	MA n (%)	CNA n (%)
Active					
Parenchymal	90 (26.7)	74 (82)	9 (10)	22 (24)	14 (15)
Extraparenchymal	7 (2.1)	0	6 (86)	1 (14)	2 (10)
Both	28 (8.3)	12 (43)	24 (86)	8 (28)	10 (38)
Transitional					
Parenchymal	82 (24.4)	72 (88)	15 (18)	12 (14)	12 (14)
Meningeal	10 (2.9)	2 (20)	10 (100)	1 (10)	6 (60)
Both	18 (5.3)	6 (33)	16 (89)	6 (33)	14 (78)
Inactive					
Parenchymal	87 (25.9)	66 (75)	0	3 (3)	7 (8)
Meningeal	14 (4.1)	7 (50)	12 (86)	2 (14)	6 (4)
Total	336 (100)	239 (71)	92 (27)	55 (16)	71 (21)

IH, intracranial hypertension; MA, motor abnormalities; CNA, cranial nerve abnormalities.

^a From reference 29, Carpio et al.

ternational League Against Epilepsy (ILAE) (124,125) are currently used worldwide.

According to the definitions suggested by the ILAE (124,125), provoked or acute symptomatic seizures occur in close temporal association with an acute CNS lesion (e.g., infection, stroke, cranial trauma). Such seizures are often isolated epileptic events associated with acute conditions but may also recur or occur as status epilepticus as the acute condition recurs. Unprovoked seizures (considered to be epilepsy if the seizures recur) may occur in relation to a well-demonstrated antecedent condition, substantially increasing the risk of epileptic seizures. Unprovoked seizures are categorized into two major subgroups: (a) remote symptomatic unprovoked seizures due to conditions resulting in a static encephalopathy, such as infection, cerebral trauma, or cerebrovascular disease, which are generally presumed to be the result of a nonprogressive (static) lesion; and (b) symptomatic unprovoked seizures due to progressive CNS disorders.

Seizures occurring with NC may be categorized under either provoked or unprovoked, according to its evolutionary stages. People with cysticerci in the transitional form or degenerative phase develop acute symptomatic seizures because of the inflammatory response of the brain; on the other hand, a patient with seizures who has active, viable cysts or inactive, calcified parasites or both may be categorized as having unprovoked seizures. However, because NC has an unpredictable clinical course, it is difficult to categorize all cases into the proposed classification of the ILAE. For instance, some patients with chronic recurrent seizures whose imaging studies show several parenchymal calcifications should be categorized as having remote symptomatic unprovoked seizures because of conditions resulting in a static encephalopathy. Some years later, these same patients could develop hydrocephalus associated with intraventricular cysts or parenchymal transitional cysts. These

cases should be considered as manifesting multiple episodes—which increase the risk of epilepsy—but they should not be categorized as progressive symptomatic unprovoked seizures due to progressive CNS disorders.

Neurologists from developing countries frequently see patients whose first seizure occurred many years earlier; consultation occurs only after a second seizure, at which time the imaging study shows one or more calcifications and one cyst in the transitional form with perilesional edema. We can assume that when the first acute seizure occurred, the patient had cysts in a transitional form, which then became calcified. By the time the second seizure occurs, the patient presumably has new acute seizures. Should the seizures be categorized as isolated epileptic events associated with an acute recurrent condition (e.g., a transitional form of NC) or should the patient be categorized as having epilepsy? According to the ILAE, the former is probably the most accurate classification. Ultimately in patients with NC, differentiating between provoked or acute symptomatic seizures and recurrent unprovoked seizures (epilepsy) is vital in determining treatment and prognosis, as will be discussed below. One of the reasons for overdiagnosis of epilepsy in some studies in which there is no differentiation between seizures and epilepsy is the inclusion of acute symptomatic seizures that do not evolve into epilepsy.

There is no agreement regarding the frequency of seizure type in patients with NC. Although some authors reported a higher proportion of partial seizures (21,108, 120), others concluded that generalized seizures occur more frequently (81,122). These discrepancies may be due to such methodologic problems as described. In general, it seems that about half the cases are partial epilepsy and the other half generalized epilepsy, a proportion similar to that of the general population (126,127).

NC and the etiology of epilepsy

Studies of etiology of epilepsy in developing countries are few. Those that exist are of all seizures rather than epilepsy alone, and most are prevalent case series, which are not useful in identifying the cause of seizures. Nevertheless, the available information shows that the ratio of idiopathic (60–70%) to symptomatic (30–40%) epilepsy remains constant in comparison with studies from developed countries (128). Among the symptomatic group, infection and parasitic diseases—in particular neurocysticercosis, perinatal brain damage, and head trauma—are the most frequent disorders reported as a cause of epilepsy (105,128,129). It is extremely difficult to compare results of studies of epilepsy due to NC. In addition to broad differences in the definition (if any) of NC, there is also a failure to define criteria for diagnosis of either seizures or epilepsy. There is no information on the latency between the first acute symptomatic seizure and the first unprovoked seizure, and not even informa-

tion on the relative age of the patient at the time of onset of seizures and the time of diagnosis of NC.

Although NC is often cited as a major cause of epilepsy in countries where *T solium* is endemic (7,96,100, 120–122,130), few accurate data are available. There is anecdotal information as to the relation between epilepsy and cysticercosis in New Guinea (131,132), where cysticercosis was introduced by imported pigs in 1972, and there was an apparent increase in the number of burns that occurred when individuals having seizures fell into open fires, which are commonly used in this population. In a study from India (133), in which acute symptomatic seizures were excluded, only 5.3% of 253 patients with epilepsy had NC. Studies of highly selected patients with epilepsy (or seizures?) in hospital settings from Latin American countries (120–122), whose diagnoses were based on CT, report NC as the cause of epilepsy in 30–50% of patients. Surprisingly, the proportion of epilepsy cases associated with cysticercosis using an immunoserological test as a diagnostic tool is considerably lower than the proportion of NC cases using CT as a diagnostic tool. Only 12% of patients with epilepsy attending an outpatient clinic in Peru had serological evidence of *T solium* as shown by the EITB test (41,44).

Single inflammatory lesion and seizures

Single enhancing lesion on CT (SECTL), or hyperintense lesion on MRI, is a common finding in patients with seizures from developing countries. The lesion is usually small (~5–10 mm), well defined, annular or nodular contrast enhancing, cortical or subcortical, and generally associated with perilesional edema and minimal mass effect, but without any midline shift (see Fig. 5). The patients—mainly children and young adults—have some benign and transitory clinical manifestations, predominantly partial or partial secondarily generalized seizures, and, occasionally, Todd's paresis or focal neurologic deficits. The results of biopsy of these lesions have reported varied etiologies: cysticercus, tuberculomas, pyogenic abscess, meningoencephalitis, and even normal brain. In the majority of cases there were inflammatory changes; therefore, the name single inflammatory lesion (SIL) seems justified in referring to both the SECTL shown on CT and the hyperintense lesion shown on MRI. These lesions were described in the 1980s as a common neurologic syndrome in patients with epilepsy in India (63,64,134–138). They were also included in the neurocysticercosis literature of the West using a different nomenclature: "acute or focal encephalitic stage" (65), "solitary parenchymal lesions" (68,75), "acute lesions" (58), "single transitional forms" (29), or, simply, "cysticercosis granulomas" (24,138). The etiology of these lesions has been attributed mainly to cysticercosis (138,139) and tuberculosis (140); however, similar lesions have been reported in other inflammatory patholo-

gies, such as in cases of pyogenic abscess (141); histoplasmosis, blastomycosis, and sarcoidosis (24); postinfectious vasculitis; and primary and metastatic brain tumors (142). A vascular etiology was also argued (134): Cryptic or angiographically occult small vascular malformations such as cavernous angiomas could produce seizures and radiologically resemble SECTL; nevertheless, this assumption is no longer supported. Some authors believe that SECTL may be the result of seizures (143,144), which cause vasogenic edema resulting in the surrounding hypodensity; the enhancement may represent a break in the blood-brain barrier. However, CT scans performed ≥ 2 weeks after a seizure display SECTL, an indication that the seizure is not a trigger for the images on CT or MRI.

Initially, SIL had been labeled as intracranial tuberculomas (137,140). In some cases the diagnosis was achieved by biopsy but mostly by the disappearance of this lesion after therapy with antituberculous drugs or on the circumstantial evidence of tuberculous lesions elsewhere in the body. It was later noticed that, in most cases, these lesions disappeared or became calcified merely on treatment with anticonvulsant medications (AEDs; 63,134,136). Sethi et al. (134) reported a series of patients presenting partial seizures in which initial CTs showed a SECTL; on follow-up CT scans after 6 to 24 weeks of no specific treatment except AED, these abnormalities had disappeared. Other authors (143,144) also reported patients with partial seizures in whom CT demonstrated similar reversible abnormalities. Chandy et al. (145) reported a series of 30 patients in India with SECTL. On 10 patients (group B), a CT-guided stereotaxic biopsy was performed. On 15 patients (group C), an excision biopsy was performed. In all patients in group B, the lesions were reported as "chronic nonspecific inflammation," whereas seven of 15 patients in group C showed a cysticercus. Biopsy did not reveal a tuberculoma in any of these patients. The authors concluded that, in India, cysticercosis is the most common etiology in patients with epilepsy and SECTL.

Based on the assumption that the two most commonly considered diagnoses for SIL in patients from endemic areas are cysticercus or tuberculoma, Rajshekar et al. (146) attempted to identify features that may distinguish these two disease processes. They validated some diagnostic clinical and CT criteria for "solitary cerebral cysticercus granuloma" in patients with seizures. The clinical criteria are seizures as the initial symptom, with no evidence of persistent raised intracranial pressure, no progressive neurologic deficit, and no active systemic disease. The CT diagnostic criteria are evidence of a solitary contrast-enhancing lesion measuring ≤ 20 mm, without a shift of the midline structures due to surrounding edema. The authors compared these criteria with a "gold standard" also based on clinical and radiologic

grounds; therefore, the results could be questionable. The same authors (64) retrospectively compared visualization of "solitary cerebral cysticercus granulomas" on contrast-enhanced CT and MRI in 16 patients with seizures. MRI did not reveal additional granulomas or cysts in any of their patients, thus precluding the concern that MRI might reveal more lesions in patients in whom CT shows a solitary granuloma or transitional cyst. The natural history of SIL can usually take one of two forms: (a) it becomes isodense on CT or isointense on MRI and may be resolved entirely; or (b) a punctuate calcification may be left as a residue (see Fig. 5). The duration or time of resolution of the lesion seems to be quite variable, from a few weeks to >1 year (29,75,134,135,145,147), which leads us to think that the main etiology of SIL is NC. Based on the assumption that SIL is cysticercus, Rawlings et al. (148) empirically administered praziquantel, assuming that anticysticercal drugs would accelerate the resolution of the parasite. Later, other authors duplicated this procedure by using albendazole (149,150). Unfortunately, the latter authors did not perform a randomized, double-blind, placebo-controlled design. Padma et al. (151) reported the results of a clinical trial involving 75 patients (from age 3.5 to 50 years) with seizures and SECTL due to NC. Patients were randomized to receive albendazole or placebo. At the end of a 3-month follow-up, 35 of 40 patients who received albendazole and 33 of 35 patients who received placebo showed resolution of the lesions on CT scan. The authors thus concluded that the albendazole therapy was unnecessary.

Regarding the management of patients with SIL, in spite of the fact that spontaneous resolution of SECTL was reported early in 1985 (134) and that indisputable risks are related to brain biopsy, this procedure is still frequently used to confirm diagnosis (134,137,141,142,147,152–154). Complementary tests must be performed to discard etiologies other than NC. At present, the transitional forms of parenchymal cysticercosis are considered the stage associated with SIL. The lesions are benign and tend to resolve spontaneously, making anticysticercal drugs or surgery unnecessary because the parasite is already in the

degenerative phase and will eventually disappear or become calcified. The symptoms should be controlled by treatment such as AEDs (57,68,155–161).

EFFECT OF ANTICYSTICERCAL TREATMENT ON EPILEPSY

Although the first reports regarding treatment for NC with antihelminthic drugs such as metrifonate (162), mebendazole (163), fluobendazole (164), praziquantel (165), and albendazole (166) were published >15 years ago, there are no controlled clinical trials to establish the specific indications, definitive doses, and duration of treatment (155). Whereas it is generally assumed that either praziquantel or albendazole is an effective treatment for NC (166–176), a critical review of the literature suggests that the studies on which these assumptions are based are flawed in terms of patient selection, assignment to treatment, and selection and measurement of outcome variables (160,161,177). Many authors (176–183) appropriately criticized the publications on this topic to date and concluded that no adequate studies of efficacy have been reported. Other authors warned that, in some patients, antihelminthic therapy might be harmful, particularly in the subarachnoidal localization, because these drugs might cause arachnoiditis and arteritis, and consequently hydrocephalus (184,185).

A randomized clinical trial was performed on patients with newly identified active NC (156). Oral prednisolone alone (randomized to 27 patients) was compared with praziquantel and prednisolone (in 54 patients), or albendazole with prednisolone (in 57 patients). At 6 months and 1 year after treatment, there were no differences in the three treatment groups in terms of the proportion of cases free of cysts or the relative reduction of number of cysts. At 2 years, there was no difference in the proportion of cases free of seizures over the entire follow-up period (Table 2). According to these results, treatment with antihelminthic drugs does not modify the prognosis of seizures in patients with NC. This study, the largest single trial of NC treatment reported to date, ad-

TABLE 2. Treatment of neurocysticercosis: Number (proportion) of cases with disappearance of cysts on computed tomography (CT) scan within treatment groups, and clinical outcome^a

	CT scan ^b	Albendazole group n (%)	Praziquantel group n (%)	Control group n (%)	p value ^c
Single cyst	Follow-up 1	9 (39.1)	10 (50)	5 (41.7)	0.76
	Follow-up 2	13 (56.5)	14 (70)	7 (58.3)	0.64
Multiple cysts	Follow-up 1	7 (20.6)	7 (20.6)	0	0.1
	Follow-up 2	14 (41.2)	11 (32.4)	3 (20)	0.34
All cysts	Follow-up 1	16 (28.1)	17 (31.5)	5 (18.5)	0.46
	Follow-up 2	27 (47.4)	25 (46.3)	10 (37)	0.65
Freedom from seizures		33 (63)	26 (58)	12 (57)	0.61

^a From reference 156, Carpio et al.

^b Follow-up 1, CT scan 3–6 months after treatment; follow-up 2, CT scan 9–12 months after treatment.

^c χ^2 test.

dresses questions as to what extent and in which patients treatment with either praziquantel or albendazole is effective (see Fig. 2). The improvement attributed to antihelminthic drugs in previous studies may be related to the lack of appropriate controls and is likely to be a reflection of the natural history of NC (see Fig. 5). The authors pointed out the need to conduct a long-term, placebo-controlled trial with precise end points, proper randomization, sample-size calculations, and predetermined statistical calculations to evaluate properly the effectiveness and determine the indications of etiologic treatment for NC.

Some authors suggested that the control of seizures in patients with NC is better after a course of anticysticercal drugs than when the disease is left untreated (121,186) and that the chance of remaining seizure free after the withdrawal of AEDs seems to be greater in those patients who were previously treated with anticysticercal drugs (187). Another presumed effect of anticysticercal drugs is the normalization of the cellular immune functions (188). Again, such studies are flawed by lack of control groups or accurate patient selection. For example, in one study (121) seizures were reported to remit after treatment with praziquantel or albendazole but persisted in an untreated group selected from patients attending clinics for people with chronic and untreatable epilepsy. Although there was a decrease in the frequency of seizures in patients who received antiparasitic therapy, it is not clear that this was a result of therapy or of patient selection bias (182).

To our knowledge, there are no studies that separate NC patients with acute symptomatic seizures from patients with chronic recurrent seizures and patients with newly diagnosed recurrent seizures. We think these distinctions are crucial to select patients properly; otherwise, selection may be a main source of bias.

PROGNOSIS OF PATIENTS WITH EPILEPSY DUE TO NC

More than 50 years ago, Dixon and Lipscomb (96) observed that many patients with NC and epilepsy improved spontaneously and that "the prognosis is much better than has hitherto been thought." Many authors affirm that most NC patients with seizures or epilepsy have a good prognosis (68,134,156,158,189–191). However, at present there are no prospective cohort studies to ascertain the prognosis of NC. It can be assumed that prognosis of NC patients with epilepsy is similar to the figures of symptomatic epilepsy reported in well-known studies (123,192–196). Hauser and Hesdorffer (123) reported that, after an initial unprovoked seizure, seizures recurred among 16–61% of patients. The risk of recurrence increases among patients with a remote symptomatic etiology (as in the case of NC), partial seizures, and

an abnormal EEG. In a recent study, Cockerell et al. (197) reported that 61% of patients with remote symptomatic seizures achieved a 5-year remission.

Prospective studies regarding the discontinuation of AEDs in patients with NC are also lacking. In a retrospective study (187) in which AEDs were tapered in 40 patients with epilepsy caused by NC who had been free of seizures for 2 years, there was an overall relapse rate of 50%. The author suggested that patients with recurrent seizures before the start of albendazole therapy have the highest rate of relapse; however, these results were not compared with a control group. Besides, the reported rate is similar to those reported by Berg and Shinnar (198, 199) in a recent meta-analysis, in which the discontinuation of AEDs is associated with a 12–67% risk of relapse. There is no evidence that NC increases the risk of recurrent unprovoked seizures. In a reported case-control study of risk factors in 25 patients with epilepsy, Gracia et al. (200) did not find NC to be a risk factor for epilepsy when it was tested in serum.

So far, there are no studies specifically designed according to modern methods of epidemiology—either retrospective case-control or prospective cohort studies—that analyze factors associated with recurrence or remission of seizures in patients with NC. It is therefore impossible to establish how long treatment is needed before discontinuation of AEDs. Seizures due to inflamed cysticercal lesions should be considered acute symptomatic seizures. Therefore patients should be treated only for the duration of the acute condition, perhaps several months during which the inflammatory response is active (201). Once the lesion has resolved on neuroimaging and the EEG is normal, AEDs may be tapered. If seizures recur, AEDs should be restarted, and the patient may be treated for 1–2 years. If the patient has seizures and calcified lesions, treatment should last 1–2 years before being reduced (201). If this is the case, these general recommendations of management of symptomatic epilepsy, regardless of a specific etiology, should be followed.

Cysticercosis is a disease of poverty and social underdevelopment. Human cysticercosis may be prevented by improvements in sanitation, health care, and socioeconomic status. Until the condition is prevented, collaborative studies in endemic countries should be performed. To improve the knowledge of this parasitic disease, similar study methodology and definitions should be used.

REFERENCES

1. Schantz PM, Moore AC, Muñoz JL, et al. Neurocysticercosis in an orthodox Jewish community in New York City. *N Engl J Med* 1992;327:692–5.
2. Schantz PM. Cysticercosis in non-endemic countries: the example of the United States. In: Garcia HH, Martínez S, eds. *Teniasis/cisticercosis por T. solium*. Lima: Editorial Universo S.A., 1996:277–86.

3. Preux PM, Melaku Z, Druet-Cabanac M, et al. Cysticercosis and neurocysticercosis in Africa: current status. *Neurol Infect Epidemiol* 1996;1:63-8.
4. Carpio A. *Cisticercosis cerebral: enfermedad del subdesarrollo*. Cuenca: Facultad de Ciencias Medicas de la Universidad de Cuenca, 1985.
5. Sarti E, Schantz PM, Plancaarte A, et al. Prevalence and risk factors for *Taenia solium* taeniasis and cysticercosis in humans and pigs in a village in Morelos, México. *Am J Trop Med Hyg* 1992;46:677-85.
6. Carpio A, Santillán F, León P. Aspectos clinicos de la cisticercosis. *Rev Inst Inv Cienc Salud (Ecuador)* 1990;5:1-40.
7. McCormick GF, Zee CS, Heiden J. Cysticercosis cerebri. *Arch Neurol* 1982;39:534-9.
8. Faust EC, Russell PF, Jung RC. Cysticercosis. In: Faust EC, ed. *Clinical parasitology*. Philadelphia: Lea & Febiger, 1979:529-35.
9. Escobar A, Nieto D. Cysticercosis. In: Minkler J, ed. *The pathology of the nervous system*. New York: McGraw-Hill, 1972:2507-15.
10. Evans C. The immunology of taeniasis/cysticercosis: implications for prevention and treatment. In: Garcia HH, Martínez S, eds. *Teniasis/cisticercosis por T. solium*. Lima: Editorial Universo S.A., 1996:50-64.
11. Flisser A, Willms K, Lacleste JP, et al. *Cysticercosis. Present state of knowledge and perspectives*. New York: Academic Press, 1982.
12. Correa D, Dalma D, Espinoza B, et al. Heterogeneity of humoral immune components in human cysticercosis. *J Parasitol* 1985; 71:535-41.
13. Goodman K, Carpio A, Ballagh SA. Case-control study of seropositivity for cysticercosis in Cuenca, Ecuador. *J Neurol Sci* 1997;150:S326.
14. Spina-Franca A, Livramento JA, Bacheschi LA, Garcia-Lopez P. Cerebrospinal fluid immunoglobulins in cysticercosis of the central nervous system. *Arq Neuropsiquiatr* 1976;34:40-5.
15. Carpio A. Epidemiology of tropical neurology in South America. In: Rose FC, ed. *Recent advances in tropical neurology*. Amsterdam: Elsevier Sciences Publishers, 1995:31-42.
16. Carpio A. La neurocisticercosis en el Ecuador. In: Benitez R, Ordoñez G, eds. *Biopatología Andina y Tropical Ecuatoriana, Tomo III*. Quito: Academia Ecuatoriana de Medicina, 1995:1383-410.
17. García-Albea EE. *Cisticercosis cerebral: Aportaciones al conocimiento de una enfermedad endémica en España e Hispanoamérica*. Madrid: Aran Ediciones S.A., 1991.
18. García-Ramos G, Rubio-Donnadieu F. Neurocysticercosis in the adult. In: Palacios E, Rodríguez-Carbajal J, Taveras JM, eds. *Cysticercosis of central nervous system*. Springfield: Charles C Thomas, 1983:63-8.
19. Singhal BS, Ladiwala U. Neurocysticercosis in India. In: Rose FC, ed. *Recent advances in tropical neurology*. Amsterdam: Elsevier Sciences Publishers, 1995:31-42.
20. Bittencourt PRM, Costa AJ, Oliveira TV, et al. Clinical, radiological and cerebrospinal fluid presentation of neurocysticercosis: a prospective study. *Arq Neuropsiquiatr (Sao Paulo)* 1990;48: 286-95.
21. Bittencourt PRM, Adamolekun B, Bharucha N, et al. Epilepsy in the tropics: II. Clinical presentations, pathophysiology, immunologic diagnosis, economics and therapy. *Epilepsia* 1996;37: 1121-7.
22. Mervis B, Lotz JW. Computed tomography (CT) in parenchymatous cerebral cysticercosis. *Clin Radiol* 1980;31:521-8.
23. Byrd SE, Locke GE, Biggers S, Percy AK. The computed tomography appearance of cerebral cysticercosis in adults and children. *Radiology* 1982;144:819-23.
24. Enzman DR. *Imaging of infections and inflammations of the central nervous system*. New York: Raven Press, 1984:102-27.
25. Handler LC, Mervis B. Cerebral cysticercosis with reference to the natural history of parenchymal lesions. *AJNR* 1983;4:709-12.
26. Rodríguez-Carbajal J, Palacios G, Zeen Ch. Neuroradiology of the cysticercosis of the central nervous system. In: Palacios J, Rodríguez Carbajal J, Taveras J, eds. *Cysticercosis of the central nervous system*. Springfield: Charles C. Thomas, 1983:101-43.
27. Suss RA, Maravilla KR, Thompson J. MR imaging of intracranial cysticercosis: comparison with CT and anatomopathologic features. *AJNR* 1986;7:235-42.
28. Martínez HR, Rangel-Guerra R, Elizondo G, et al. MR imaging in neurocysticercosis: a study of 56 cases. *AJNR* 1989;10:1011-9.
29. Carpio A, Placencia M, Santillán F, Escobar A. Proposal for a new classification of neurocysticercosis. *Can J Neurol Sci* 1994; 21:43-7.
30. Carpio A. Clasificación de la neurocisticercosis. In: Garcia HH, Martínez S, eds. *Teniasis/cisticercosis por T. solium*. Lima: Editorial Universo S.A., 1996:139-52.
31. Arriagada C, Matus C, Nogales-Gaete J. Tomografía computada en neurocisticercosis. In: Arriagada C, Nogales-Gaete J, Apt W, eds. *Neurocisticercosis. Aspectos epidemiológicos, patológicos, inmunológicos, clínicos, imagenológicos y terapéuticos*. Santiago-Chile: Arrynog Ediciones, 1997:161-207.
32. Paez F. *Neuroimagen: texto de docencia medica*. Quito: Color-Offset, 1997.
33. Dumas JL, Visy JM, Belin C, Gaston A, Goldlust D, Dumas M. Parenchymal neurocysticercosis: follow-up and staging by MRI. *Neuroradiology* 1997;39:12-8.
34. Allan JC, Mencos F, Garcia-Noval J, et al. Dipstick dot-ELISA for detection of *Taenia* coproantigens in humans. *Parasitology* 1993;107:79-85.
35. Schenone H, Villarroel F, Rojas A, Ramírez R. Epidemiology of human cysticercosis in Latin America. In: Flisser A, Willms K, Lacleste JP, et al. *Cysticercosis: present state of knowledge and perspectives*. New York: Academic Press, 1982:25-38.
36. Díaz F, García HH, Gilman RH, et al. Epidemiology of taeniasis and cysticercosis in a Peruvian village. *Am J Epidemiol* 1992; 135:875-82.
37. Ramos-Kuri M, Montoya RM, Padilla A, et al. Immunodiagnosis of neurocysticercosis: disappointing performance of serology (enzyme-linked immunosorbent assay) in an unbiased sample of neurological patients. *Arch Neurol* 1992;49:633-6.
38. Palacios R, Alvarado M, Carpio A, Santillán F, Palacios M. Valoración de las técnicas inmunológicas en el diagnóstico de la cisticercosis cerebral. *Rev Inst Inv Cienc Salud (Ecuador)*. 1988; 3:1-19.
39. Nieto D. Cysticercosis of the nervous system: diagnosis by means of the spinal fluid complement fixation. *Neurology* 1956;6:725-38.
40. Tsang VC, Brand JA, Boyer AE. An enzyme-linked immunoelectrotransfer blot assay and glycoproteins antigens for diagnosing human cysticercosis (*Taenia solium*). *J Infect Dis* 1989;159:50-9.
41. Tsang VC, Garcia HH. Immunoblot diagnostic test (EITB) for *Taenia solium* cysticercosis and its contribution to the definition of this under-recognized but serious public health problem. In: Garcia HH, Martínez S, eds. *Teniasis/cisticercosis por T. solium*. Lima: Editorial Universo S.A., 1996:259-68.
42. Wilson M, Gryan R, Fried J, et al. Clinical evaluation of the cysticercosis enzyme-linked immunoelectrotransfer blot in patients with neurocysticercosis. *J Infect Dis* 1991;164:1007-9.
43. García HH, Martínez M, Gilman R, et al. Diagnosis of cysticercosis in endemic regions. *Lancet* 1991;338:549-51.
44. García HH, Gilman R, Martínez M, Tsang VCW. Cysticercosis as a major cause of epilepsy in Peru. *Lancet* 1993;341:197-200.
45. Moore AC, Lutwick LI, Schantz PM, et al. Seroprevalence of cysticercosis in an orthodox Jewish community. *Am J Trop Med* 1995;53:439-42.
46. Cruz I. Epidemiología de la neurocisticercosis en el Ecuador. In: Garcia HH, Martínez S, eds. *Teniasis/cisticercosis por T. solium*. Lima: Editorial Universo S.A., 1996:303-11.
47. Palacio LG, Tobón M, Sanchez JL, Jiménez M, Jiménez I. Prevalencia de neurocisticercosis en individuos con epilepsia en Medellín, Colombia. In: Garcia HH, Martínez S, eds. *Teniasis/cisticercosis por T. solium*. Lima: Editorial Universo S.A., 1996: 291-302.
48. Grill J, Rakotomalala W, Andriantsimahavandy A, et al. High prevalence of serological markers of cysticercosis among epileptic Malagasy children. *Ann Trop Paediatr* 1996;16:185-91.
49. García HH, Gilman RH, Tsang VC, Gonzalez AE. Clinical significance of neurocysticercosis in endemic villages: The Cysti-

- cercosis Working Group in Peru. *Trans R Soc Trop Med Hyg* 1997;91:176-8.
50. García-Noval J, Allan JC, Fletes C, et al. Epidemiology of *Taenia solium* taeniasis and cysticercosis in two rural Guatemalan communities. *Am J Trop Med Hyg* 1996;55:282-9.
 51. Schantz PM, Sarti E, Plancarte A, et al. Community-based epidemiological investigations of cysticercosis due to *Taenia solium*: comparison of serological screening tests and clinical findings in two populations in México. *Clin Infect Dis* 1994;18:879-85.
 52. García HH, Herrera G, Gilman RH, et al. Discrepancies between cerebral computed tomography and Western blot in the diagnosis of neurocysticercosis. *Am J Trop Med Hyg* 1994;50:152-6.
 53. Cruz ME, Davis A, Dixon H, Pawlowski ZS, Proaño J. Operational studies on the control of *Taenia solium* taeniasis/cysticercosis in Ecuador. *Bull WHO* 1989;67:401-7.
 54. Keilbach NM, de Aluja AS, Sarti-Gutierrez E. A program to control taeniasis-cysticercosis (*T. solium*): experiences in a Mexican village. *Acta Leiden* 1989;57:181-9.
 55. Diaz-Camacho SP, Candil-Ruiz A, Suate V, et al. Epidemiologic study and control of *Taenia solium* infections with praziquantel in a rural village of Mexico. *Am J Trop Med Hyg* 1991;45:522-31.
 56. Gilman RH, García HH, Gonzales AE, et al. Métodos para controlar la transmisión de la cisticercosis. In: García HH, Martínez S, eds. *Teniasis/cisticercosis por T. solium*. Lima: Editorial Universo S.A., 1996:327-39.
 57. Carpio A, Placencia M. Definition of contemporary surgical management in cysternal and parenchymatous cysticercosis cerebri. *Neurosurgery* 1992;30:968-9.
 58. Kramer LD, Locke GE, Byrd SE, Daryabagi J. Cerebral cysticercosis: documentation of natural history with CT. *Radiology* 1989;171:459-62.
 59. Machado LR, Nobrega JP, Barros NG, Livramento JA, Bacheschi LA, Spina-Franca A. Computed tomography in neurocysticercosis: a 10-year long evolution analysis of 100 patients with an appraisal of a new classification. *Arq Neuropsiquiatr (Sao Paulo)* 1990;48:414-8.
 60. Martínez HR, Rangel-Guerra R, Arredondo-Estrada JH, Marfil A, Onofre J. Medical and surgical treatment in neurocysticercosis: a magnetic resonance study of 161 cases. *J Neurol Sci* 1995;130:25-34.
 61. Miller B, Grinnell V, Goldberg MA, et al. Spontaneous radiographic disappearance of cerebral cysticercosis: three cases. *Neurology* 1983;33:1377-9.
 62. Cuetter AC, García-Bobadilla J, Guerra LG, Martínez FM, Kaim B. Neurocysticercosis: focus on intraventricular disease. *Clin Infect Dis* 1997;24:157-64.
 63. Rajshekhhar V. Etiology and management of single small CT lesions in patients with seizures: understanding a controversy. *Acta Neurol Scand* 1991;84:465-70.
 64. Rajshekhhar V, Chandy MJ. Comparative study of CT and MRI in patients with seizures and a solitary cerebral cysticercus granuloma. *Neuroradiology* 1996;38:542-6.
 65. Rodríguez-Carbajal J, Salgado P, Gutiérrez-Alvarado R, Escobar-Izquierdo A, Aruffo C, Palacios E. The acute encephalitic phase of neurocysticercosis: computed tomographic manifestations. *AJNR* 1983;4:51-5.
 66. Zee CS, Segall HD, Destian S, Ahmadi J, Apuzzo MLJ. MRI of intraventricular cysticercosis: surgical implications. *J Comput Assist Tomogr* 1993;17:932-9.
 67. Teitelbaum GP, Otto RJ, Watanabe AT, et al. MR imaging of neurocysticercosis. *AJNR* 1989;10:709-18.
 68. Mitchel WG, Snodgrass SR. Intraparenchymal cerebral cysticercosis in children: a benign prognosis. *Pediatr Neurol* 1985;1:151-6.
 69. Mazer S, Antoniuk A, Ditzel LFS, Araujo JC. The computed tomographic spectrum of cerebral cysticercosis. *Comput Radiol* 1983;7:373-8.
 70. Lotz J, Hewlett R, Alheit B, Bowen R. Neurocysticercosis: correlative pathomorphology and MR imaging. *Neuroradiology* 1988;30:35-41.
 71. Arriagada V, Arriagada C, Terra E, Manen R, Julio D. Imagen de resonancia magnética en neurocisticercosis. In: Arriagada C, Nogales-Gaete J, Apt W, eds. *Neurocisticercosis: aspectos epidemiológicos, patológicos, inmunológicos, clínicos, imagenológicos y terapéuticos*. Santiago, Chile: Arrynog Ediciones, 1997:209-78.
 72. Escobar A. The pathology of neurocysticercosis. In: Palacios E, Rodríguez-Carbajal J, Taveras JM, eds. *Cysticercosis of central nervous system*. Springfield: Charles C Thomas, 1983:27-54.
 73. Trelles JO, Trelles L. Cysticercosis of the nervous system. In: Vincken PJ, Bruyn GW, eds. *Handbook of clinical neurology*. Amsterdam: North-Holland, 1978:291-320.
 74. Wadia NS, Desai S, Bhatt M. Disseminated cysticercosis: new observations, including CT scan findings and experience with treatment by praziquantel. *Brain* 1988;111:507-614.
 75. Mitchel WG, Crawford TO. Intraparenchymal cerebral cysticercosis in children: diagnosis and treatment. *Pediatrics* 1988;82:76-82.
 76. Rodríguez-Carbajal J, Placencia M, Carpio A. Calcificaciones intracraniales anormales: 135 casos estudiados por T.A.C. *Neurol Neurocir Psiquiatr* 1983;24:49-60.
 77. Sotelo J, Guerrero J, Rubio F. A new classification based on active and inactive forms. *Arch Intern Med* 1988;148:442-5.
 78. Stepień L. Cerebral cysticercosis in Poland: clinical symptoms and operative results in 132 cases. *J Neurosurg* 1962;19:505-13.
 79. Rangel R, Torres B, Del Brutto O, et al. Cysticercotic encephalitis: a severe form in young females. *Am J Trop Med Hyg* 1987;36:387-92.
 80. Noboa C. Encefalitis cisticercosa: análisis de 10 casos. *Rev Ecuat Neurol* 1992;1:61-71.
 81. López-Hernández A, Garaizar C. Manifestations of infantile cerebral cysticercosis. In: Palacios E, Rodríguez-Carbajal J, Taveras JM, eds. *Cysticercosis of central nervous system*. Springfield: Charles C Thomas, 1983:69-83.
 82. Madrazo I, García-Rentería JA, Sandoval M, Lopez-Vega FJ. Intraventricular cysticercosis. *Neurosurgery* 1983;12:148-52.
 83. Salazar A, Sotelo J, Martínez H, Escobedo F. Differential diagnosis between ventriculitis and fourth ventricle cyst in neurocysticercosis. *J Neurosurg* 1983;59:660-3.
 84. Apuzzo MLJ, Dobkin WR, Zee C-S, et al. Surgical considerations in treatment of intraventricular cysticercosis: an analysis of 45 cases. *J Neurosurg* 1984;60:400-7.
 85. Kioumeh F, Dadsetan MR, Feldman N, et al. Postcontrast MRI of cranial meninges: leptomeningitis versus pachymeningitis. *J Comput Assist Tomogr* 1995;19:713-20.
 86. Alarcón F, Hidalgo F, Moncayo J, Viñán I, Dueñas G. Cerebral cysticercosis and stroke. *Stroke* 1992;23:224-8.
 87. Alarcón F, Vanormeligen K, Moncayo J, Viñán I. Cerebral cysticercosis as a risk factor for stroke in young and middle-aged people. *Stroke* 1992;23:1563-5.
 88. Cantú C, Barinagarrementeria F. Cerebrovascular complications of neurocysticercosis: clinical and neuroimaging spectrum. *Arch Neurol* 1996;53:233-9.
 89. Barinagarrementeria F, Cantú C. Arteritis cerebral cisticercosa. In: Arriagada C, Nogales-Gaete, Apt W, eds. *Neurocisticercosis: aspectos epidemiológicos, patológicos, inmunológicos, clínicos, imagenológicos y terapéuticos*. Santiago-Chile: Arrynog Ediciones, 1997:139-52.
 90. Carpio A, Ochoa M, Bustamante J, et al. Meningitis crónica: estudio clínico de 47 casos. *Rev Inst Inv Cienc Salud (Ecuador)* 1987;2:5-19.
 91. Lopez-Albo W. Cisticercosis del neuro-ocjo y de las meninges. *An Med Int (Madrid)* 1932;1:849-78.
 92. MacArthur WP. Cysticercosis as a cause of epilepsy in man. *Trans R Soc Med Hyg* 1933;26:525-8.
 93. MacArthur WP. Cysticercosis seen in the British Army with special reference to the production of epilepsy. *Trans R Soc Med Hyg* 1934;27:343-63.
 94. Stepień L, Chorobski J. Cysticercosis cerebri and its operative treatment. *Arch Neurol Psychiatry* 1949;61:499-527.
 95. Dixon HBF, Hargreaves WH. Cysticercosis (*T. solium*): a further 10 years study covering 284 cases. *Q J Med* 1944;13:107-21.
 96. Dixon HBF, Lipscomb FM. *Cysticercosis: an analysis and follow-up of 450 cases*. Med Res Council. Spec.rep. no. 299. London: Her Majesty's Stationery Office, 1961:1-58.

97. Lombardo L, Mateos JH. Cerebral cysticercosis in Mexico. *Neurology* 1961;11:824-8.
98. Lopez-Albo W. *Aspectos clínicos de la cisticercosis del sistema nervioso central*. Mexico: Multa Pavcis Médica, 1945.
99. Escobar A. Cisticercosis cerebral: estudio de 20 casos. *Arch Mex Neurol Psiquiatr* 1952;145-67.
100. Bittencourt PRM, Gracia CM, Lorenzana P. Epilepsy and parasitosis of the central nervous system. *Recent adv epilepsy*. 1988; 4:123-59.
101. Montenegro R, Placencia M, Paredes V, et al. Síndromes cerebrovasculares asociados a cisticercosis cerebral. *Rev Ecuat Neurol* 1993;2:104.
102. Alarcón T, Olivares L. Cisticercosis cerebral: manifestaciones clínicas en un medio de alta prevalencia. *Rev Invest Clin* 1975; 27:209-15.
103. Otero E, Cordova S, Diaz F, García-Teruel I, Del Brutto OH. Acquired epileptic aphasia (the Landau-Kleffner syndrome) due to neurocysticercosis. *Epilepsia* 1989;30:569-72.
104. Shandera WX, White AC, Chen AC, Diaz P, Armstrong R. Neurocysticercosis in Houston, Texas. *Medicine* 1994;73:37-52.
105. Bittencourt PRM, Adamolekun B, Bharucha N, et al. Epilepsy in the tropics: I. Epidemiology, socioeconomic risk factors, and etiology. *Epilepsia* 1996;37:1121-7.
106. Chinchilla N, De Andres C, Roldan SG. Frecuencia de neurocisticercosis en un hospital de Madrid. *Arch de Neurobiol* 1989;52: 287-94.
107. Earnest MP, Reller LB, Filley CM, Grk AJ. Neurocysticercosis in the United States: 35 cases and a review. *Rev Infect Dis* 1987;9: 961-76.
108. Martínez SM. Controversias clínicas y terapéuticas en neurocisticercosis. In: García HH, Martínez SM, eds. *Teniasis/cisticercosis por T. solium*. Lima: Editorial Universo S.A., 1996:207-16.
109. Obrador S. Cysticercosis cerebri. *Acta Neurochir* 1972;3:320-64.
110. Stepien L. Cerebral cysticercosis in Poland: clinical symptoms and operative results in 132 cases. *J Neurosurg* 1962;19:505-13.
111. Placencia M, Paredes V, Franco J, et al. Clinical profile of 182 patients with epileptic seizures associated with brain cysticercosis. *Epilepsia* 1991;32:108-9.
112. Richards FO Jr, Schantz PM, Ruiz-Tiben E, Sorvillo FJ. Cysticercosis in Los Angeles County. *JAMA* 1985;254:3444-8.
113. Scharf D. Neurocysticercosis: two hundred thirty-eight cases from a California hospital. *Arch Neurol* 1988;45:777-80.
114. Monteiro L, Almeida-Pinto J, Stocker A, Sampaio-Silva M. Active neurocysticercosis, parenchymal and extraparenchymal: a study of 38 patients. *J Neurol* 1993;241:15-21.
115. Monteiro L, Nunes B, Mendonca D, Lopes J. Spectrum of epilepsy in neurocysticercosis: a long-term follow-up of 143 patients. *Acta Neurol Scand* 1995;92:1,33-40.
116. Forlenza OV, Filho AH, Nobrega JP, et al. Psychiatric manifestations of neurocysticercosis: a study of 38 patients from a neurology clinic in Brazil. *J Neurol Neurosurg Psychiatry* 1997;62: 612-6.
117. Placencia M, Paredes V, Madera A, Arroyo R, Franco J. *La cisticercosis cerebral en epidemiología de epilepsia*. Vademecum Farmacéutico, Tercera Edición, Quito: Edifarma, 1993.
118. Nogales-Gaete J, Arriagada C, González J. Síndromes anatomoclínicos de la neurocisticercosis. In: Arriagada C, Nogales-Gaete, Apt W, eds. *Neurocisticercosis: aspectos epidemiológicos, patológicos, inmunológicos, clínicos, imagenológicos y terapéuticos*. Santiago-Chile: Arrynog Ediciones, 1997:117-38.
119. Estañol B, Corona T, Abad P. A prognostic classification of cerebral cysticercosis: therapeutic implications. *J Neurol Neurosurg Psychiatry* 1986;49:1131-4.
120. Medina MT, Rosas E, Rubio-Donnadieu F, Sotelo J. Neurocysticercosis as the main cause of late-onset epilepsy in Mexico. *Arch Intern Med* 1990;150:325-32.
121. Vázquez V, Sotelo J. The course of seizures after treatment for cerebral cysticercosis. *N Engl J Med* 1992;327:696-701.
122. Del Brutto OH, Santibañez R, Noboa CA, Aguirre R, Diaz E, Alarcón TA. Epilepsy due to neurocysticercosis: analysis of 203 patients. *Neurology* 1992;42:389-92.
123. Hauser WA, Hesdorffer DH. *Epilepsy: frequency, causes and consequences*. New York: Demos Press, 1990.
124. Commission on Epidemiology and Prognosis of the International League Against Epilepsy. Guidelines for epidemiological studies on epilepsy. *Epilepsia* 1993;34:592-6.
125. Commission on Epidemiology and Prognosis of the International League Against Epilepsy. The epidemiology of the epilepsies: future directions. *Epilepsia* 1997;38:614-8.
126. Hauser WA. Recent developments in the epidemiology of epilepsy. *Acta Neurol Scand* 1995;162:17-21.
127. Sander JWAS, Shorvon SD. Epidemiology of the epilepsies. *J Neurol Neurosurg Psychiatry* 1996;61:433-43.
128. Carpio A, Hauser WA. The distribution and etiology of epilepsy in the tropics of America. *Rev Ecuat Neurol* 1993;2:137-45.
129. Adamolekun A, Carpio A, Carvalho-Filho F, et al. Relationship between epilepsy and tropical diseases. *Epilepsia* 1994;35:89-93.
130. Arruda WO. Etiology of epilepsy: a prospective study of 200 cases. *Arq Neuropsiquiatr* 1991;49:251-4.
131. Bending J, Cafford J. Epidemic of burns in New Guinea due to cerebral cysticercosis. *Lancet* 1983;330:922.
132. Gadjusek DC. Introduction of *T. solium* in West New Guinea with a note on an epidemic of burns from cysticercus epilepsy in the Ekari people of the Wissel Lakes area. *PNG Med J* 1978;21:239.
133. Ahuja GK, Mohanta A. Late onset epilepsy. *Acta Neurol Scand* 1982;66:216-26.
134. Sethi PK, Ku,ar BR, Madan VS, Mohan V. Appearing and disappearing CT scan abnormalities and seizures. *J Neurol Neurosurg Psychiatry* 1985;48:866-9.
135. Bhatia S, Tandon PN. Solitary "microlesions" in CT: a clinical study and follow-up. *Neurol India* 1988;36:139-50.
136. Bansal BC, Dua A, Gupta R, Gupta MS. Appearing and disappearing CT scan abnormalities in epilepsy in India: an enigma. *J Neurol Neurosurg Psychiatry* 1989;52:1185-7.
137. Wadia RS, Makhale CN, Kelkar AN, Grant KB. Focal epilepsy in India with special reference to lesions showing ring or disc like enhancement on contrast computed tomography. *J Neurol Neurosurg Psychiatry* 1987;50:1298-301.
138. Rajshekhar V, Chacko G, Haran RP, Chandy MJ, Chandi SM. Clinicoradiological and pathological correlations in patients with solitary cysticercus granuloma and epilepsy: focus on presence of the parasite and oedema formation. *J Neurol Neurosurg Psychiatry* 1995;59:284-6.
139. Wani MA, Benerji AK, Tandom PN, Bhargava S. Neurocysticercosis: some uncommon presentations. *Neurol India* 1981;29:58-63.
140. Tandom PM, Bhargava S. CNS tuberculosis: lessons learnt from CT studies. *Neurol India* 1980;28:207-12.
141. Basauri L, Zuleta A, Loayza P, Olivares A. Microabscesses and presumptive inflammatory nodules of the brain. *Acta Neurochir* 1983;68:27-32.
142. Michael AS, Levy JM, Paige ML. Cysticercosis mimicking brain neoplasm. *J Comput Assist Tomogr* 1990;14:708-11.
143. Jayakumar PN, Taly AB, Mohan PK. Transient computerized tomographic (CT) abnormalities following partial seizures. *Acta Neurol Scand* 1985;72:26-9.
144. De Beyl DZ, Hermanus N, Cille H, Goldman S. Focal seizures with reversible hypodensity in the CT scan. *J Neurol Neurosurg Psychiatry* 1985;48:187.
145. Chandy MJ, Rajshekhar V, Ghosh S, et al. Single small enhancing CT lesions in India patient with epilepsy: clinical, radiological and pathological considerations. *J Neurol Neurosurg Psychiatry* 1991;54:702-5.
146. Rajshekhar V, Chandy MJ. Validation of diagnostic criteria for solitary cerebral cysticercus granuloma in patients presenting with seizures. *Acta Neurol Scand* 1997;96:76-81.
147. Ahuja GK, Behari M, Goulatia RK, Jaiikhani BL. Disappearing CT lesions in epilepsy: is tuberculosis or cysticercosis the cause? *Neurol Neurosurg Psychiatry* 1989;52:915-6.
148. Rawlings D, Ferreiro DM, Messing RO. Early CT reevaluation after empiric praziquantel therapy in neurocysticercosis. *Neurology* 1989;39:739-41.
149. Del Brutto OH. The use of albendazole in patients with single lesions enhanced on contrast CT. *N Engl J Med* 1993;328:356-7.
150. Rajshekhar V. Albendazole therapy for persistent solitary cysti-

- cercus granulomas in patient with seizures. *Neurology* 1993;43:1238-40.
151. Padma MV, Behari M, Misra NK, Ahuja NK. Albendazole in single CT ring lesions in epilepsy. *Neurology* 1994;44:1344-6.
 152. Hitchcock ER. Cysticercosis in the UK. *J Neurol Neurosurg Psychiatry* 1985;50:1080-2.
 153. Case records of the Massachusetts General Hospital. Case 20, 1990. *N Engl J Med* 1990;322:1446-58.
 154. Case records of the Massachusetts General Hospital. Case 26, 1994. *N Engl J Med* 1994;330:188-93.
 155. Carpio A. Efecto del tratamiento antiparasitario en la epilepsia secundaria a neurocisticercosis. In: García HH, Martínez S, eds. *Teniasis/cisticercosis por T. solium*. Lima: Editorial Universo S.A., 1996:193-206.
 156. Carpio A, Santillán F, León P, Flores C, Hauser WA. Is the course of neurocysticercosis modified by treatment with antihelminthic agents? *Arch Intern Med* 1995;155:1982-8.
 157. Kar AM, Garg RK. Management of small solitary enhancing (ring or disc) CT lesion in patients with epilepsy: does it need change in strategy? *Adv Clin Neurosci* 1995;5:303-10.
 158. Garg RK. Childhood neurocysticercosis: issues in diagnosis and management. *Indian Pediatr* 1995;32:1023-9.
 159. Garg RK, Agrawal A. Medical treatment for cysticercosis. *Arch Neurol* 1996;53:295.
 160. Kramer LD. Medical treatment of cysticercosis: ineffective. *Arch Neurol* 1995;52:101-2.
 161. Kramer LD. Anthelmintic therapy for neurocysticercosis. *Arch Neurol* 1990;47:1059-60.
 162. Salazar M, Gonzáles D. Ensayo terapéutico de la cisticercosis con metrifonato. *Rev Inst Salud Pública (Méx)* 1972;32:1.
 163. Velasco-Suárez M. Medical treatment of neurocysticercosis. In: Palacios E, Rodríguez-Carbajal J, Taveras JM, eds. *Cysticercosis of central nervous system*. Springfield, IL: Charles C Thomas, 1983:149-54.
 164. Tellez-Giron E, Ramos MC, Montante M. *The effect of fluobendazole against cysticercus cellulosae in pig*. San Luis Potosí: University of San Luis, Department of Biochemistry, 1980.
 165. Robles C, Chavarría M. Presentación de un caso clínico de cisticercosis cerebral tratado médicamente con un nuevo fármaco: praziquantel. *Salud Pública Mex* 1979;21:603-18.
 166. Xiao ZX, Zhao CY, Liu LP. Albendazole treatment in cerebral cysticercosis. *Chin J Int Med* 1986;25:100-2.
 167. Alarcón F, Escalante L, Dueñas G, et al. Neurocysticercosis: short course of treatment with albendazole. *Arch Neurol* 1989;46:1231-6.
 168. Escobedo F, Penagos P, Rodríguez J, Sotelo J. Albendazole therapy for neurocysticercosis. *Arch Intern Med* 1987;147:738-41.
 169. Sotelo J, Escobedo F, Rodríguez-Carbajal J, Torres B, Rubio-Donnadieu F. Therapy of parenchymal brain cysticercosis with praziquantel. *N Engl J Med* 1984;310:1001-7.
 170. Takayanagui OM, Jardim E. Therapy for neurocysticercosis: comparison between albendazole and praziquantel. *Arch Neurol* 1992;49:290-4.
 171. Van Dellen JR, McKeown CP. Praziquantel in active cerebral cysticercosis. *Neurosurgery* 1988;22:92-5.
 172. Botero D, Tanowitz HB, Weiss LM, Wittner M. Taeniasis and cysticercosis. *Parasit Dis* 1993;7:683-97.
 173. Cruz M, Cruz I, Horton J. Albendazole versus praziquantel in the treatment of cerebral cysticercosis: clinical evaluation. *Trans R Soc Trop Med Hyg* 1991;85:244-7.
 174. Robles C, Sedano AM, Vargas-Tentori N, Galindo-Virgen S. Long-term results of praziquantel therapy in neurocysticercosis. *J Neurosurg* 1987;66:359-63.
 175. Proano JV, Madrazo I, García L, García E, Corea D. Albendazole and praziquantel treatment in neurocysticercosis of the fourth ventricle. *J Neurosurg* 1997;87:29-33.
 176. García HH, Gilman RH, Horton J, et al. Albendazole therapy for neurocysticercosis: a prospective double-blind trial comparing 7 versus 14 days of treatment: Cysticercosis Working Group in Peru. *Neurology* 1997;48:1421-7.
 177. Salinas R, Garner P. Neurocysticercosis. *Arch Neurol* 1996;53:213.
 178. García HH, Gilman R. Medical treatment of cysticercosis: ineffective vs. effective. *Arch Neurol* 1996;52:941.
 179. Garg RK, Kar AM, Jain S. Failure of albendazole therapy in two common types of parenchymal neurocysticercosis. *J Assoc Physicians India* 1995;43:706-7.
 180. Hachinski VC. Medical treatment of cysticercosis. *Arch Neurol* 1995;52:104.
 181. Moodley M, Moosa A. Treatment of neurocysticercosis; is praziquantel the new hope? *Lancet* 1989;1:262-3.
 182. White AC. Neurocysticercosis: a major cause of neurological disease worldwide. *Clin Infect Dis* 1997;24:101-15.
 183. Caplan LR, Estanol B, Mitchel WG, Loyo-Varela M. How to manage patients with neurocysticercosis. *Eur Neurol* 1997;37:124-31.
 184. Loyo-Varela M. How to manage patients with neurocysticercosis: surgical treatment of cerebral cysticercosis. *Eur Neurol* 1997;37:129-30.
 185. Estanol B. How to manage patients with neurocysticercosis: medical treatment of cerebral cysticercosis. *Eur Neurol* 1997;37:125-6.
 186. Medina MT, Genton P, Montoya MC, et al. Effect of anticysticercal treatment on the prognosis of epilepsy in neurocysticercosis: a pilot trial. *Epilepsia* 1993;34:1024-7.
 187. Del Brutto OH. Prognostic factors for seizures recurrence after withdrawal of antiepileptic drugs in patients with neurocysticercosis. *Neurology* 1994;44:1706-9.
 188. Rolfs A, Mühlischlegel F, Jansen-Rossek R, et al. Clinical and immunologic follow-up study of patients with neurocysticercosis after treatment with praziquantel. *Neurology* 1995;45:532-8.
 189. Manreza ML. Neurocysticercosis in children. In: Fejerman N, Chamoses NAN, eds. *Trends in pediatric neurology*. Amsterdam: Elsevier Science Publishers B.V., 1993:295-8.
 190. Antoniuk SA, Bruck I, Wittig E, Accorsi A. Neurocysticercosis in infancy. *Arq Neuropsiquiatr (Sao Paulo)* 1991;49:47-51.
 191. Rosenfeld EA, Byrd SE, Shulman ST. Neurocysticercosis among children in Chicago. *Clin Infect Dis* 1996;23:262-8.
 192. Annerges JF, Hauser WA, Elveback LR. Remission of seizures and relapse in patients with epilepsy. *Epilepsia* 1979;20:729-37.
 193. Hauser WA, Anderson E, Loewenson RB, McRoberts SM. Seizure recurrence after a first unprovoked seizure. *N Engl J Med* 1982;307:522-8.
 194. Elwes RDC, Johnson AL, Shorvon SD, Reynolds EH. The prognosis for seizure disorders in newly diagnosed epilepsy. *N Engl J Med* 1984;311:944-7.
 195. Hauser WA, Rich SS, Annerges JF, Anderson VF. Seizure recurrence after a first unprovoked seizure: an extended follow-up. *Neurology* 1990;40:1163-70.
 196. Shinnar S, Berg AT, Moshé SL, et al. Risk of seizure recurrence following a first unprovoked seizure in childhood: a prospective study. *Pediatrics* 1990;85:1076-85.
 197. Cockerell OC, Johnson AL, Sander JWAS, Shorvon SD. Prognosis of epilepsy: a review and further analysis of the first nine years of British National General Practice Study of Epilepsy, a prospective population-based study. *Epilepsia* 1997;38:47-55.
 198. Shinnar S, Vining EP, Mellitis ED, et al. Discontinuing antiepileptic medication in children with epilepsy after two years without seizures: a prospective study. *N Engl J Med* 1985;313:976-80.
 199. Berg AT, Shinnar S. Relapse following discontinuation of anti-epileptic drugs: a meta-analysis. *Neurology* 1994;44:601-8.
 200. Gracia FJ, Loo S, Castillo Luis, et al. Epidemiology of epilepsy in Guaymi Indians from Bocas del Toro province, Republic of Panama. *Epilepsia* 1990;31:718-23.
 201. Mitchel WG. How to manage patients with neurocysticercosis: pediatric neurocysticercosis in North America. *Eur Neurol* 1997;37:126-9.