



タイトル Title	De novo Ring Chromosome 6 in a Child with Multiple Congenital Anomalies
著者 Author(s)	Ahzad, Hadi Ahmad / Ramli, Siti Fatimah / Loong, Tan May / Salahshourifar, Iman / Zilfalil, Bin Alwi / Yusoff, Narazah Mohd
掲載誌・巻号・ページ Citation	The Kobe journal of the medical sciences,56(2):79-84
刊行日 Issue date	2010
資源タイプ Resource Type	Departmental Bulletin Paper / 紀要論文
版区分 Resource Version	publisher
権利 Rights	
DOI	
JaLCDDOI	10.24546/81002600
URL	http://www.lib.kobe-u.ac.jp/handle_kernel/81002600

De novo Ring Chromosome 6 in a Child with Multiple Congenital Anomalies

HADI AHMAD AHZAD¹, SITI FATIMAH RAMLI¹,
TAN MAY LOONG², IMAN SALAHSHOURIFAR³,
BIN ALWI ZILFALIL^{3*}, and NARAZAH MOHD YUSOFF¹

¹ *Human Genetics Unit, Advanced Medical and Dental Institute, Universiti Sains Malaysia, Lot 29, Taman Bertam Indah, Kepala Batas, Penang, Malaysia*

² *Paediatrics Unit, Hospital Kulim, Kedah Darul Aman, Malaysia*

³ *Human Genome Centre, Universiti Sains Malaysia, Kota Bharu, Kelantan, Malaysia*

Received 22 January 2010/ Accepted 1 February 2010

Key Words: Ring Chromosome 6, Developmental Delay, Microcephaly, Conventional Karyotyping, Whole Chromosome Paint

Ring chromosome 6, especially if it is de novo, is a rare occurrence. The phenotype of patients with ring chromosome 6 can be highly variable ranging from almost normal to severe malformations and mental retardation. The size and structure of the ring chromosome as well as the level of mosaicism are important factors in determining the clinical phenotype. Here we report an eight month-old child, a product of a non consanguineous marriage, who presented with developmental retardation, hypertelorism, microcephaly, flat occiput, broad nasal bridge, large ears, micrognathia, wide spaced nipples, protruding umbilicus, short stubby fingers, clinodactyly, single palmar crease, short neck with no obvious webbing, and congenital heart defect. Conventional karyotyping and Whole Chromosome Paint of the peripheral leukocytes showed 46,XY,r(6)(p25q27) karyotype with plausible breakpoints at p25 and q27 end. Conventional karyotyping of both parents showed normal karyotype. To the best of our knowledge, this is the first report of a Malay individual with ring chromosome 6, and this report adds to the collective knowledge of this rare chromosome abnormality.

Human ring chromosome was first recognized in 1956 in tumor cells and later noted in other autosomes and X chromosome related disease (1). Since it was first described, ring chromosome has been reported in all the 23 pairs of chromosome. The first published case of ring chromosome 6 found in peripheral lymphocytes was in 1973 by Moore et al (2). Since then, more journals have reported cases of variable phenotypes of ring chromosome 6. The definitive cause of the ring formation is yet to be determined. We report a case of a Malay baby diagnosed to have ring chromosome 6 by conventional karyotyping and Whole Chromosome Paint (WCP).

MATERIALS AND METHODS

Case report

The baby was delivered via emergency lower segment caesarean section (EMLSCS) for fetal distress with thick meconium stained liquor. He is the only child born to a non related young couple. Both parents are healthy. There was no family history of miscarriage, birth

defects or mental retardation. Chromosomal analyses were done for both parents and the karyotyping results showed normal karyotype.

At 12 weeks of life, his length and weight increased but the head circumference was almost static. He was noted to have hypertelorism, microcephaly, flat occiput, broad nasal bridge, large ears, micrognathia, wide space nipples, protruding umbilicus, short stubby fingers, clinodactyly, single palmar crease, short neck with no obvious webbing and congenital heart defect (Figure 1). Further review at 20 weeks of life showed slight delay in his developmental milestone and mild growth retardation. All parameters were below the third centile, however, the parameters showed steady increment and followed the normal growth curve. Currently at eight months old, he is able to sit, stand with support, smile, turn to call, and hold the milk bottle with both hands.

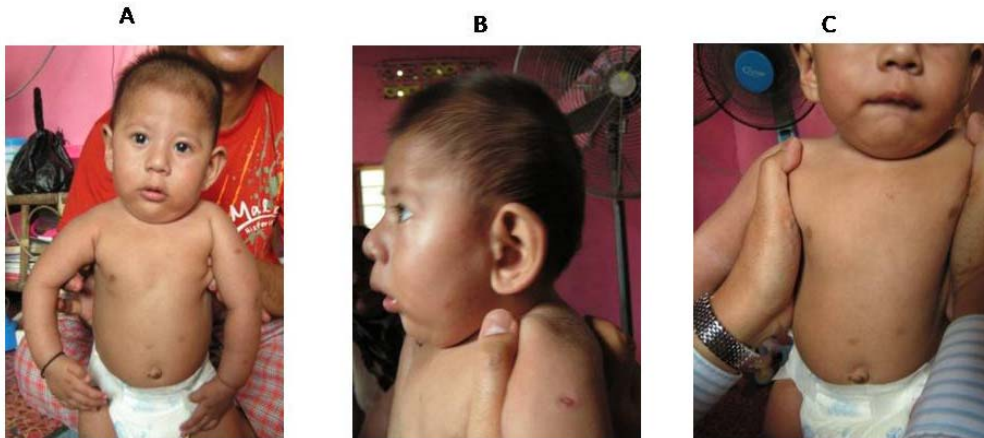


Figure 1. (A) Note the hypertelorism, wide spaced nipple, large low set ears, broad nasal bridge, protruding umbilicus, (B) Note the low set and large ears, micrognathia, short neck and flat occiput, (C) Note the wide spaced nipple, protruding umbilicus

Cytogenetic Analysis

Chromosome analysis was performed on peripheral leucocytes from freshly collected blood sample using Giemsa banding (G-banding). Subsequently Fluorescent *in situ* Hybridization (FISH) was used for confirm the abnormality.

RESULTS

The karyotype was 46,XY,r(6)(p25q27). In all the slides prepared and observed, the chromosome 6 has a ring configuration. The ring chromosome 6 was identified from the banding pattern (Figure 2A), and subsequently was confirmed with FISH. WCP specific for chromosome 6 was applied to distinguish it from other chromosomes (Figure 2B).

RING CHROMOSOME 6 WITH MULTIPLE ANOMALIES

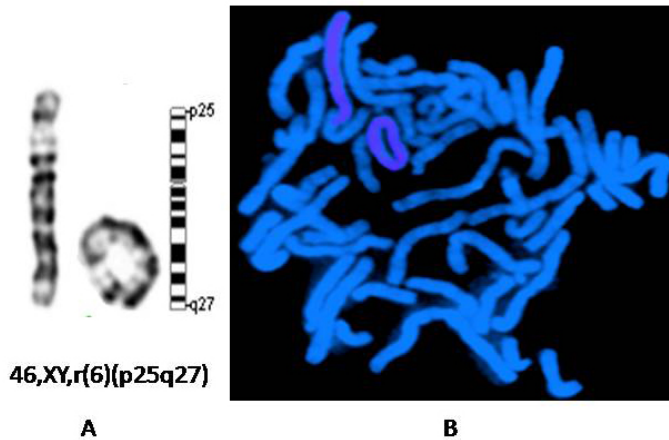


Figure 2. (A) This figure shows G banding of ring formation at the chromosome 6, with possible breakpoint at p25 and q27 and (B) Fluorescent in situ hybridization (FISH), with chromosome paint (WCP) specific for chromosome 6. The picture shows chromosome 6 in a slightly purple color compared to others, and one of them is in the ring formation

The abnormally looking chromosome 6 has a single monocentric ring in all the metaphase observed. Comparing the chromosome with the normal homologue, the most plausible breakpoints were at the p25 and q27. From the banding pattern, small proportion of the chromosomal material was noticed to be absent at the site of the ring formation. This lost of genetic material most likely contributed to the phenotype of the patient.

DISCUSSION

Ring chromosome is a very rare finding. Only a handful of literature and journals have discussed this rare syndrome. Some of the cases of de novo ring chromosome 6 were diagnosed prenatally, but most were diagnosed after childbirth (3). Children with ring chromosome 6 were mostly born at term and within normal birth weight, although some were small for gestational age.

In most cases of ring chromosome 6 that were observed and discussed, they suffered from almost normal to severe mental retardation. Our patient has mild to moderate degree of physical abnormality and remains to be seen if he will develop mental retardation later in life. He demonstrated features of mild growth retardation, hypertelorism, microcephaly, flat occiput, broad nasal bridge, large ears, micrognathia, wide space nipples, protruding umbilicus, short stubby fingers, clinodactyly, single palmar crease and short neck with no obvious webbing, and congenital heart defect. Cases reviewed by Peeden et al. (4), with total cases of 14 patients, concluded that the phenotype correlations varied and suggest difficulty in phenotype-karyotype correlation. A study by Jalal et al. (5), suggested that there are similarities of phenotypes between correlated cases of ring chromosome 6 and cases of chromosome 6p partial deletion. When comparing the cases of ring chromosome 6 and cases of chromosome 6 with partial deletion of genetic material, the phenotypes were almost similar. These instances reflected the relative lost of genetic material at the p and q arm.

Table I. Phenotype comparison between reported cases with ring chromosome 6 and the present case.

References	2	13	9	12	10,11	8	The present case
Clinical Features							
Birth weight (g)	2910	2900	1960	3380	2433	2525	2690
Breakpoints	NA	NA	p23 or p24 and q26 or q27	NA	p25 and q27	25 and q26, or p24 and q27	P25 and q27
Mental retardation	+	+	+	+	+	+	NA
Development retardation	+	+	+	+	+	+	+
Bone age retardation			+		+	+	NA
Seizures	-	-	-	-	-	+	-
Microcephaly	+	+	+	+	+	+	+
Flat occiput							+
Microphthalmia	+	+	+	-		-	-
Strabismus	-	+	-	-		-	-
Nystagmus	-	+	-	-		-	-
Iris coloboma	-	-	+	-		-	NA
Optic atrophy	-	-	+	-		-	NA
Megalocornea	-	-	+	-		-	-
Embryotoxon	-	+	+	-		-	NA
Epicanthus bilateral	+	-	+	+	+	+	+
Hypertelorism	-	-	+	-	+	+	+
Flat or broad nasal bridge	+	-	+	+		+	+
Ears low and/or malformed	+	+	+	+	+	+	+
Micrognathia	+	-	+	-	+	+	+
Microstomia	+	-	+	-			-
Palate high-arched	+	+	+	-		+	-
Neck short and/or webbed	+	-	+	+		+	+
Congenital heart defect	-	-	+	-		-	+
Hemivertebrae	-	-	+			-	NA
Talipes equinovarus					+	-	-
Pes equinus	+	-	-			-	-
Con. hip dislocation			+		+	-	-
Talus valgus	-	-	+			-	-
Soles-hyperkeratosis	+	-	-			-	-
Nevus pigmentosus	-	+	-			-	-
Cephalohematoma				+		-	-
Umbilical hernia							+
Wide space nipple							+

RING CHROMOSOME 6 WITH MULTIPLE ANOMALIES

Another factor that may be attributed to the phenotypes is the ability and stability of the ring itself in maintaining its shape and structure in cells and tissues (2, 6, 7). A study by Pezzolo et al. (6) suggested that the mechanism involved in ring formation itself might well contribute to the phenotypic features. In his study, he found the patients having a ring chromosome without losing any genetic material also has some of the phenotypic features of patients with partially deleted genetic material in the ring formation, and concluded that this is caused by ring instability. Different cases of ring chromosome 6 reviewed in several studies showed different deletion at different breakpoint (Table I).

Some features are common in all reported cases, which include developmental retardation, microcephaly and ears abnormality. In a case study by Kini et al. (8) the suggested breakpoint is at p25 and q26, while Salamanca-Gomez et al. (9) showed breakpoints at p23 or p24 and q26 or q27, and Wurster et al. (10) and Wurster-Hill et al. (11) showed breakpoints at p25 and q27. In our patient, when compared with the normal homologue of chromosome 6, the most likely breakpoint is at p25 and q27. Despite having similar breakpoints with those reported earlier, the phenotypic features were not the same. This is most likely contributed by the instability of the ring which is also known as ring syndrome. The amount of genetic material lost also contributed to this phenomenon. Further investigation is needed to ascertain the genes that were deleted at the breakpoints.

To the best of our knowledge, this is the first report of a Malay individual with ring chromosome 6. This report adds to the worldwide data of this rare chromosome abnormality.

ACKNOWLEDGEMENTS

We are grateful to the family of this patient for allowing us to publish the pictures. We would also like to acknowledge our gratitude to all those involved in this publication, and medical laboratory technologists involved in the karyotyping of this patient. We are also grateful to all the support given by Advanced Medical and Dental Institute, Universiti Sains Malaysia.

REFERENCES

1. **Hoefnagel, D., Schroede, T.M., Benyics, K.** 1967. A Child with a Group-G Ring Chromosome. *Humangenetik* **4**: 52-58.
2. **Moore, C.M., Heller, R.H., Thomas, G.H.** 1973. Developmental Abnormalities Associated with a Ring Chromosome 6. *J Med Genet* **10**: 299-303.
3. **Andrieux, J., Devisme, L., Valat, A.S., Robert, Y., Frnka, C., Savary, J.B.** 2005. Prenatal diagnosis of ring chromosome 6 in a fetus with cerebellar hypoplasia and partial agenesis of corpus callosum: case report and review of the literature. *Eur J Med Genet* **48**: 199-206.
4. **Peeden, J.N., Scarbrough, P., Taysi, K., Wilroy, R.S., Finley, S., Luthardt, F., Martens, P., Howard-Peebles, P.N.** 1983. Ring chromosome 6: Variability in phenotypic expression. *Am J Med Genet* **16**: 563-573.
5. **Jalal, S.M., Macias, V.R., Roop, H., Morgan, F., King, P.** 1989. Two rare cases of 6p partial deletion. *Clin Genet* **36**:196-199.
6. **Pezzolo, A., Gimelli, G., Cohen, A., Lavaggetto, A., Romano, C., Fogu, G., Zuffardi, O.** 1993. Presence of telomeric and subtelomeric sequences at the fusion points of ring chromosomes indicates that the ring syndrome is caused by ring instability. *Hum Genet* **92**: 23-27.
7. **Gisselsson, D., Höglund, M., Mertens, F., Johansson, B., Dal Cin, P., Van den**

- Berghe, H., Earnshaw, W.C., Mitelman, F., Mandahl, N.** 1999. The structure and dynamics of ring chromosomes in human neoplastic and non-neoplastic cells. *Hum Genet* **104**: 315-325.
8. **Kini, K.R., Van Dyke, D.L., Weiss, L., Logan, M.S.** 1979. Ring Chromosome 6: Case Report and Review of Literature. *Hum Genet* **50**: 145-149.
 9. **Salamanca-Gomez, F., Nava, S., Armendares, S.** 1975. Ring chromosome 6 in a malformed boy. *Clin Genet* **8**:370-375.
 10. **Wurster, D., Pomeroy, J., Benirschke, K., Hoefnagel, D.** 1969. Mental deficiency and malformations in a boy with a group-C ring chromosome: 46,XY,Cr. *Journal of Mental Deficiency Research* **13**: 184-190.
 11. **Wurster-Hill, D.H., Hoefnagel, D.** 1975. Banding identification of chromosomal abnormalities in four patients: ring (6), translocation (2q;15q+), translocation (21q;21q) and deletion (22q-). *J Ment Defic Res* **19**: 145-150.
 12. **Fried, K., Rosenblatt, M., Mundel, G., Krikler, R.** 1975. Mental retardation and congenital malformations associated with a ring chromosome 6. *Clin Genet* **7**: 192-196.
 13. **Van den Berghe, H., Fryns, J.P., Cassiman, J.J., David, G.** 1974. Ring chromosome 6. Karyotype 46, XY, r (6)-45, XY,-6. *Ann Genet* **17**: 29-35.