

# Deciphering logopenic primary progressive aphasia: a clinical, imaging and biomarker investigation

Marc Teichmann,<sup>1,2</sup> Aurélie Kas,<sup>3,4</sup> Claire Boutet,<sup>5</sup> Sophie Ferrieux,<sup>1</sup> Marie Nogues,<sup>1</sup> Dalila Samri,<sup>1</sup> Christina Rogan,<sup>1</sup> Didier Dormont,<sup>2,4,5</sup> Bruno Dubois<sup>1,2</sup> and Raffaella Migliaccio<sup>2,6</sup>

1 Department of Neurology, Centre de référence 'Démences Rares', Hôpital de la Pitié Salpêtrière, AP-HP, Paris, France

2 INSERM UMRS 975 – CRICM. Hôpital de la Pitié Salpêtrière, Paris, France

3 Service de Médecine Nucléaire, Hôpital de la Pitié-Salpêtrière, AP-HP, Paris, France

4 Université Pierre et Marie Curie-Paris 6, INSERM, UMR-S 678, Paris, France

5 Service de Neuroradiologie Diagnostique et Fonctionnelle, Hôpital de la Pitié-Salpêtrière, AP-HP, Paris, France

6 Department of Psychology, Catholic University, Milan, Italy

Correspondence to: Marc Teichmann,  
Department of Neurology, Centre de référence 'Démences Rares',  
Hôpital de la Pitié Salpêtrière, 47-83,  
boulevard de l'Hôpital. 75013 Paris. France  
E-mail: marc.teichmann@psl.aphp.fr

Within primary progressive aphasia the logopenic variant remains less understood than the two other main variants, namely semantic and non-fluent progressive aphasia. This may be because of the relatively small number of explored patients and because of the lack of investigations with a comprehensive three-level characterization of cognitive, brain localization and biological aspects. The aim of the present study was to decipher the logopenic variant through a multimodal approach with a large cohort of 19 patients (age  $66.5 \pm 8.7$  years, symptom duration  $3.2 \pm 0.6$  years) using detailed cognitive and linguistic assessments, magnetic resonance imaging and perfusion single-photon emission computed tomography as well as cerebrospinal fluid biomarkers screening for Alzheimer pathology. The linguistic assessment unveiled that language dysfunction is not limited to the typical feature of word finding and verbal working memory impairments but that it extends into the language system affecting to some degree syntactic production, phonological encoding and semantic representations. Perfusion tomography revealed damage of the temporal-parietal junction with a peak of significance in the superior temporal gyrus (Brodmann area 42), and of some less significant prefrontal areas (Brodmann areas 8, 9 and 46), whereas hippocampal cortices were unaffected. Magnetic resonance imaging, which was visually assessed in a larger group of 54 patients with logopenic, non-fluent, semantic variants as well as with posterior cortical atrophy, confirmed that the logopenic variant demonstrates predominant atrophy of left temporal-parietal junction, but that this atrophy pattern has a relatively poor sensitivity and specificity for clinical diagnosis. Finally, the biomarker study revealed that two-thirds of the logopenic patients demonstrated a profile indicative of Alzheimer pathology whereas one-third had a non-Alzheimer profile. Splitting the two groups showed that logopenic aphasia due to probable Alzheimer pathology is a more aggressive variant characterized by more extensive language/cognitive disorders affecting, in addition to lexical processes and verbal working memory, also phoneme sequencing, semantic processing and ideomotor praxis. Concordantly, logopenic aphasia due to probable Alzheimer pathology demonstrated more extensive brain hypoperfusion involving larger regions throughout the inferior parietal, the posterior-superior and the middle temporal cortex. These findings allow for unfolding logopenic aphasia into two subvariants differing by disease severity, lesion nature and lesion distribution, which has important implications for diagnosis, patient management and for potential future trials with

**anti-Alzheimer drugs. The present data therefore provide novel insight into the cognition and brain damage of logopenic patients while unveiling the existence of distinct diseases constituting a 'logopenic aphasia complex'.**

**Keywords:** logopenic progressive aphasia; temporal-parietal junction; Alzheimer's disease; logopenic subvariants

**Abbreviations:** PIB = Pittsburgh compound B; PPA = primary progressive aphasia; SPECT = single-photon emission computed tomography

## Introduction

Primary progressive aphasia (PPA) is an umbrella term which identifies a group of neurodegenerative diseases that predominantly affect language processing. It encompasses three main variants (non-fluent/agrammatic, semantic and logopenic PPA), which can be distinguished by their aphasia profile and atrophy pattern. The prevalence of PPA has been estimated at about 7/100 000 upon epidemiologic data drawn from frontal-temporal lobar degeneration, which comprises non-fluent and semantic PPA but not the logopenic variant (Ratnavalli *et al.*, 2002; Knopman and Roberts, 2011). Likewise, diagnostic criteria of PPA initially only comprised non-fluent and semantic PPA (Neary *et al.*, 1998; Mesulam, 2001) whereas logopenic PPA has been included only recently (Gorno-Tempini *et al.*, 2011). This rather late consideration of logopenic PPA might primarily relate to the fact that research on this PPA variant has been limited in terms of number of studies and of explored patients. The characterization of logopenic PPA therefore remains still fragmentary and its potentially important prevalence within the PPA spectrum encourages a comprehensive specification of logopenic PPA features. Such a specification is furthermore crucial because logopenic PPA may represent a potential candidate for therapeutic trials with anti-Alzheimer drugs given that several studies have suggested a high proportion of underlying Alzheimer pathology (Mesulam *et al.*, 2008; Migliaccio *et al.*, 2009; Leyton *et al.*, 2011).

Previous studies have shown that logopenic PPA is primarily characterized by a word finding impairment, related to a pathological 'word-on-the-tip-of-the-tongue' phenomenon, and by repetition and comprehension difficulties for sentences due to verbal working memory deficits (Gorno-Tempini *et al.*, 2004, 2008). Several authors have shown that cortical atrophy mainly affects the left temporal-parietal junction (Gorno-Tempini *et al.*, 2004; Migliaccio *et al.*, 2009; Rohrer *et al.*, 2010b), which is known to implement both lexical representations (Indefrey and Levelt, 2004) and phonological working memory (Paulesu *et al.*, 1993; Jonides *et al.*, 1998). Furthermore, several studies suggest that logopenic PPA is primarily due to underlying Alzheimer pathology as reflected by neuropathological data (Mesulam *et al.*, 2008; Ridgway *et al.*, 2012; Rohrer *et al.*, 2012) and by *in vivo* findings from neuropathological surrogates such as <sup>11</sup>C-Pittsburgh compound B (PIB)-PET imaging (Rabinovici *et al.*, 2008; Leyton *et al.*, 2011) or CSF biomarkers (Rohrer *et al.*, 2010b, 2012; Hu *et al.*, 2010). However, these findings derive from investigations including relatively small logopenic PPA samples and/or from studies that did not provide a comprehensive three-level characterization with respect to cognitive patterns, brain localization

(imaging) and causative pathological mechanisms (neuropathology or surrogate markers). In this vein, studies focusing on brain localization or pathological mechanisms rarely provide a detailed language/neuropsychological characterization, and conversely, studies investigating the cognitive/linguistic profile of logopenic PPA mostly lack either imaging or neuropathological markers. Moreover, imaging studies in logopenic PPA primarily used MRI voxel-based morphometry whereas PET and single-photon emission computed tomography (SPECT) imaging, which provide sensitive markers of cortical dysfunction (Habert *et al.*, 2011), have only been applied to small cohorts (Gorno-Tempini *et al.*, 2008; Rabinovici *et al.*, 2008; Josephs *et al.*, 2010) or within studies lacking language data (Kas *et al.*, 2012). Finally, diagnostic criteria for logopenic PPA (Gorno-Tempini *et al.*, 2011), which are based on the expertise of PPA specialists may need additional support from comprehensive larger scale studies. It therefore appears crucial to enrich current research on PPA by investigating a large sample of logopenic PPA patients using a multi-modal approach. With the aim of ensuring clinical usefulness, establishing such a picture should furthermore be based on the application of tools that are commonly available in neurological centres while eventually avoiding high-level techniques such as voxel-based morphometry or PET-PIB.

In the present study, we therefore explored a large cohort of 19 patients with logopenic PPA using standardized language/neuropsychological tests, MRI and SPECT imaging, as well as CSF biomarkers. We furthermore aimed at individualizing cognitive and imaging phenotypes of logopenic PPA subforms as a function of CSF results, which should also allow for uncovering non-invasive predictors of Alzheimer pathology.

## Materials and methods

### Patients

Within a time interval of 2 years we recruited 61 patients at the neurological department of the Pitié Salpêtrière Hospital who satisfied the International Diagnostic Criteria of PPA (Gorno-Tempini *et al.*, 2011). All patients had isolated or largely predominant language disorders that evolved insidiously and for which only a degenerative mechanism could account. The patients were further classified into the three PPA main variants according to Gorno-Tempini *et al.* (2011) yielding 19 patients with logopenic PPA (31.1%), 24 patients with semantic PPA (39.3%) and 11 patients with non-fluent/agrammatic PPA (18.0%). Seven patients (11.5%) did not fulfil the criteria of any of these variants and were considered as non-classifiable PPA. For the purpose of the present study we subsequently focused on the

19 patients with logopenic PPA who were selected upon rigorous classification criteria. First, we applied the gold standard, namely a patient classification based on the judgement of three senior PPA experts (B.D., M.T., R.M.) that carefully screened language performance conforming to the international consensus criteria (Gorno-Tempini *et al.*, 2011). In accordance with these criteria all patients demonstrated the logopenic PPA core feature of word-finding difficulties and sentence repetition impairment. Furthermore, with respect to Gorno-Tempini *et al.* (2011), and according to previous reports on logopenic PPA (Gorno-Tempini *et al.*, 2008), syntactic, semantic and phonological impairments were only accepted when these were mild and clearly less prominent than the logopenic PPA core feature. To ensure accurate distinction of logopenic from semantic PPA we did not include any patient with predominant disorders of single-word comprehension. Likewise, to ensure accurate distinction of logopenic from non-fluent/agrammatic PPA, we did not include any patient with 'frank agrammatism' and/or with 'motor speech disorders' (Gorno-Tempini *et al.*, 2011). As the term 'frank agrammatism' is open to interpretation, we used the four-point scale of Leyton *et al.* (2011) which showed that no patient had 'severe' agrammatism as opposed to 'mild', 'questionable' or 'absent' disorders. Furthermore, we quantified in each patient the number of syntactic errors and the number of word-finding pauses occurring after determiners (e.g. 'this is a [pause], a... cookie'). Word finding pauses were at least four times more frequent than syntactic errors. Finally, we revised the annual speech recordings of our logopenic PPA patients to give additional confidence to the logopenic PPA diagnosis. This procedure showed that no patient had definite syntactic or semantic disorders 1 year before the inclusion whereas all patients demonstrated the language core feature of logopenic PPA.

All patients were recruited from the clinic follow-up of our neurological department. They had no previous neurological or psychiatric history. During the diagnostic procedure, MRI was used to exclude non-degenerative causes of brain damage including vascular white matter disease. Among the 19 patients with logopenic PPA, two had a parent with a neurocognitive disease, one with late onset Alzheimer's disease and another with fronto-temporal dementia. Demographic data of the patients with logopenic PPA are summarized in Table 1. All biological and clinical data were generated during a routine clinical work-up. Therefore, according to French legislation, explicit informed consent was waived. However, regulations concerning electronic filing were followed, and patients and their relatives were informed that anonymized data might be used in clinical research studies.

## Cognitive level: language and general cognitive assessment

All patients underwent a language and a general cognitive battery which contained published tests with normative scores. The language battery was composed of four subtests of the Boston Diagnostic Aphasia Evaluation (Mazaux and Orgogozo, 1982), a picture naming test (DO80; Deloche and Hannequin, 1997) and a verbal fluency test comprising phonemic and category fluency (Cardebat *et al.*, 1990). The subtests of the Boston Diagnostic Aphasia Evaluation comprised: (i) an evaluation of aphasia severity taking into account spontaneous speech and the description of the 'cookies theft' picture; (ii) a sentence repetition test; (iii) a sentence comprehension test; and (iv) a single-word comprehension task (pointing to pictures upon auditory word presentation). As the DO80 naming test contains 80 pictures depicting relatively high frequency nouns ( $34 \pm 59$  per million according to the LEXIQUE 2 database; New *et al.*, 2004) we added 35 low frequency

**Table 1** Demographic data

	LPA (means $\pm$ standard deviations)
Number of patients	19
Gender female/male	6/13
Age (years)	66.5 $\pm$ 8.7
Years of education	11.8 $\pm$ 3.8
Handedness (right/left)	19/0
Symptom duration (years)	3.2 $\pm$ 0.6
Age at disease onset	63.4 $\pm$ 8.8

LPA = logopenic PPA.

items that corresponded to parts of the represented objects (e.g. picture representing a horse: high frequency item 'horse', low frequency item = 'mane'). Low frequency nouns had a lexical frequency of  $13 \pm 23$  per million, which was sought to enhance the sensitivity of the assessment. Normative scores for the naming of the low frequency items were obtained with 30 healthy adults who were matched with the patients with logopenic PPA on age and number of years of education (both  $F$ 's  $< 1$ ). Finally, two experienced speech therapists (S.F., M.N.) evaluated the presence or absence of speech apraxia (phonetic disorders), disorders of phoneme sequencing (phonological encoding) and syntactic errors during the different tests of the battery as well as during spontaneous speech. Testing took  $\sim 1$ h. Altogether, the language battery assessed several core domains of language processing comprising semantics, lexical processing, syntax, phonology and verbal working memory. More specifically, 'single-word comprehension' and 'category fluency' mainly assessed semantic capacities (the latter also probing for lexical capacities), 'picture naming' and 'phonemic fluency' primarily assessed lexical abilities, and 'sentence repetition' probed for verbal working memory. 'Sentence comprehension' is a more composite task assessing at a time verbal working memory, semantic word knowledge and syntactic competency. Furthermore, detailed evaluation of syntactic errors, phoneme sequencing errors and speech apraxia provided proxy markers for syntactic, phonological and phonetic abilities, respectively.

The general cognitive battery included the Mattis Dementia Rating Scale (Mattis, 1976), the Mini-Mental State Examination (Folstein *et al.*, 1975), the Frontal Assessment Battery (Dubois *et al.*, 2000) and a verbal span assessment (Wechsler, 1981). We also evaluated the presence or absence of ideomotor apraxia using the apraxia scale of Mahieux-Laurent *et al.* (2009). Testing took  $\sim 45$  min.

## Biological level: cerebrospinal fluid biomarkers

Thirteen patients (mean age 66.0 years  $\pm 7.6$ , symptom duration 3.2 years  $\pm 0.7$ ) had a lumbar puncture with subsequent quantification of total tau (tau), phosphorylated tau at threonine 181 (P-tau) and amyloid- $\beta$  peptide 1–42 (Ab42). CSF samples were centrifuged for 10 min at 1500 rpm at 48°C to remove cells, aliquoted to 0.4 ml samples in polypropylene tubes and stored at -80°C until analysis. CSF biomarker levels of tau, P-Tau and Ab42 were measured in duplicate using the double sandwich ELISA method (Innogenetics®). We also calculated derived ratios from single biomarkers, including tau/Ab42, P-Tau/Ab42 and the Innostest amyloid tau index (IATI) ratio (Ab-42/[240 + (1.18  $\times$  tau)]). Analyses for all patients were performed in the Biochemistry Department at the Pitié-Salpêtrière Hospital, with all operators being blind to clinical and imaging information. With respect to

biomarker values predictive of Alzheimer's disease, a previous study of our department has provided two main cut-offs, namely a P-tau/Ab42 cut-off of  $\geq 0.211$  pg/ml and a tau/Ab42 cut-off of  $\geq 1.23$  pg/ml (Cruz de Souza *et al.*, 2011). These cut-offs had respective sensitivities of 91.7% and 95%, and respective specificities of 89.1% and 84.8% in distinguishing Alzheimer's disease from frontal-temporal lobar degeneration. We predicted that using such markers would allow for splitting the whole logopenic PPA group into a subgroup of patients with probable underlying Alzheimer's disease (logopenic PPA+) and a subgroup of patients who presumably do not have Alzheimer disease (logopenic PPA–).

## Brain level: imaging

### Atrophy rating on magnetic resonance imaging

MRI scans included 3D  $T_1$  (inversion recovery-fast spoiled gradient-echo; field of view = 250 mm<sup>2</sup>; acquisition matrix = 288 × 256; voxel resolution = 0.5 × 0.5 × 1.2 mm; slice thickness = 1.2 mm; space between slices = 1.2 mm),  $T_2$  propeller, FLAIR and diffusion images. The scans were obtained with standard parameters on a 3T General Electric scanner with a standard head coil for signal reception. Atrophy rating was performed on 3D  $T_1$ -weighted sequences by two experienced evaluators (C.B., R.M.; Boutet *et al.*, 2012) who visually assessed the scans of our logopenic PPA patients within a large patient set ( $n = 54$ ) comprising also non-fluent/agrammatic PPA, semantic PPA and posterior cortical atrophy. This procedure allowed for minimizing potential rating biases by randomizing the scans across patient groups and by blinding both evaluators to disease diagnosis and to the number of patients per group. Furthermore, the assessment of different PPA variants provided a basis for calculating the specificity and sensitivity of MRI-based logopenic PPA detection. The rating procedure followed a fully standardized protocol. First, we selected in both hemispheres eight regions of interest which were derived from previous imaging findings in PPA (Gorno-Tempini *et al.*, 2004). This selection comprised four temporal (pole, posterior-superior, anterior-superior and medial), two parietal (inferior and superior) and two frontal regions (dorsolateral and inferior). The occipital lobe was evaluated as a whole. All regions were identified on six coronal reference planes, perpendicular to the hippocampal axis, while using six precise landmarks along an anterior-posterior axis: (i) anterior-to-genu; (ii) anterior commissure; (iii) posterior commissure; (iv) posterior-to-splenium; (v) mid-cuneus; and (vi) midpoint between mid-cuneus and occipital pole. Evaluators rated atrophy for each patient applying a 3-point scale (0 = absent, 1 = slight, 2 = severe). In case of score discrepancy between the two evaluators, consensus was to be reached upon an additional rating session.

The procedure was applied to 15 of 19 patients with logopenic PPA for whom adequate MRI acquisitions were available (mean age 65.1 years  $\pm$  9.2, symptom duration 3.2 years  $\pm$  0.7). According to CSF profiles, the logopenic PPA group was further split into two subgroups: logopenic PPA+ ( $n = 8$ , mean age 65.9 years  $\pm$  8.5, symptom duration 3.3 years  $\pm$  0.7) and logopenic PPA– ( $n = 5$ , mean age 66.2 years  $\pm$  6.9, symptom duration 3.2 years  $\pm$  0.7). Patients with atrophy in both the left posterior-superior temporal and the left inferior parietal region, which anatomically compose the temporal-parietal junction were considered to have an imaging pattern of logopenic PPA. The specificity and the sensitivity for detecting logopenic PPA was calculated by contrasting patients with logopenic PPA with nine patients with non-fluent PPA (mean age 69.1 years  $\pm$  7.5, symptom duration 3.0 years  $\pm$  1.3), 10 with semantic PPA (mean age 65.2 years  $\pm$  7.8, symptom duration 3.2 years  $\pm$  1.7) and 20 patients

with posterior cortical atrophy (mean age 61.9 years  $\pm$  8.0, symptom duration 3.9 years  $\pm$  1.8). These three subgroups corresponded respectively to the international diagnosis criteria of PPA variants (Gorno-Tempini *et al.*, 2011) and of posterior cortical atrophy (McMonagle *et al.*, 2006). Symptom duration and age at disease onset were similar in all patient groups.

### Cortical perfusion on single-photon emission computed tomography

Sixteen patients with logopenic PPA (mean age 68.1 years  $\pm$  8.3, symptom duration 3.7 years  $\pm$  0.8, years of education: 11.8 years  $\pm$  3.8) and 24 healthy controls (mean age 69.0 years  $\pm$  6.9, years of education 10.6 years  $\pm$  4.1, Mini-Mental State Examination 28.8  $\pm$  0.7) underwent a brain perfusion SPECT. According to their CSF profiles, the logopenic PPA group was further divided into two subgroups: logopenic PPA+ ( $n = 8$ , mean age 65.7 years  $\pm$  8.4, symptom duration 3.5 years  $\pm$  0.6, years of education 13 years  $\pm$  4.2) and logopenic PPA– ( $n = 3$ , mean age 63 years  $\pm$  4.6, symptom duration 3.5 years  $\pm$  1.1, years of education 10.7 years  $\pm$  1.5). Finally, we also included 24 patients with an amnesic syndrome of the hippocampal type and with CSF biomarkers indicative of underlying Alzheimer pathology thus fulfilling the revised diagnostic criteria of Alzheimer's disease (Dubois *et al.*, 2007). These typical Alzheimer's disease patients (mean age 65.1 years  $\pm$  11, symptom duration 3.7 years  $\pm$  2.1, years of education 8.6 years  $\pm$  5.5) were matched to the logopenic PPA+ group for age, symptom duration and years of education. Clinical and cognitive characteristics of the patients with typical Alzheimer's disease and the healthy subjects, as well as the procedures of SPECT acquisition and imaging preprocessing have been previously described in Kas *et al.* (2011). The following sets of analyses were performed: (i) logopenic PPA versus healthy controls to unveil the overall hypoperfusion pattern in the patient population; (ii) logopenic PPA+ versus healthy controls and logopenic PPA– versus healthy controls to explore differences in hypoperfusion patterns among logopenic PPA subtypes according to their CSF biomarker profiles; and (iii) typical Alzheimer's disease versus healthy controls and logopenic PPA+ versus typical Alzheimer's disease to individualize in patients with positive CSF biomarkers the cortical regions which are specifically involved in logopenic PPA+ as compared to typical amnesic Alzheimer's disease.

All Statistical Parametric Mapping T-maps were obtained using a statistical significance threshold of  $P < 0.05$  corrected for multiple tests using the family-wise error rate (FWE) method except for the direct comparison between logopenic PPA and typical Alzheimer's disease. In this case, considering the small number of subjects and considering the direct contrast between pathological brains, a threshold of  $P < 0.001$  uncorrected was accepted. To decrease the risk of false positive results, clusters of  $< 300$  voxels were not considered. Age was entered as a nuisance variable.

## Results

### Cognitive level

We calculated mean scores and standard deviations of the different tests of the language and the general cognitive battery and confronted them with normative values (Table 2). Patients with logopenic PPA had abnormal scores on all tests of the general cognitive battery whereas the performances on language tests showed a more differentiated picture with predominant impairment of picture naming, sentence repetition, phonemic fluency

**Table 2** Mean scores of patients with logopenic PPA on the general cognitive and the language battery

	Means $\pm$ SD	Normal threshold
<b>General cognitive battery</b>		
MMSE	21.3 $\pm$ 4.4*	$\geq$ 27
MDRS	116.5 $\pm$ 12.3*	$\geq$ 137
FAB	11.2 $\pm$ 2.7*	$\geq$ 16
Verbal span (standard note)	5.1 $\pm$ 3.2	$\geq$ 6
<b>Language battery</b>		
Severity rating scale BDAE	3.4 $\pm$ 0.7	$>$ 4
Sentence repetition BDAE	10.1 $\pm$ 2.8*	$\geq$ 14
Sentence comprehension BDAE	7.4 $\pm$ 2.3	$\geq$ 8
Single-word comprehension BDAE	66.1 $\pm$ 8.7	$\geq$ 68
Category fluency ('fruits' per 2 min)	8.7 $\pm$ 5.1*	$\geq$ 15
Phonemic fluency ('P' per 2 min)	8.3 $\pm$ 4.7*	$\geq$ 15
<b>Picture Naming</b>		
DO80 (low frequency items)	21.3 $\pm$ 8.6*	$\geq$ 30
DO80 (HFI)	62.2 $\pm$ 16.2	$\geq$ 75
DO80 HFI nb semantic paraphasias	2.9 $\pm$ 3.5	–
DO80 HFI nb phonemic paraphasias	0.5 $\pm$ 1.0	–
DO80 HFI nb non-responses	10.4 $\pm$ 11.4	–

HFI = high frequency items; SD = standard deviation. MMSE = Mini-Mental State Examination; MDRS = Mattis Dementia Rating Scale; FAB = Frontal Assessment Battery; BDAE = Boston Diagnostic Aphasia Examination. \*Scores  $>$  1 SD below the normal threshold.

and category fluency. In addition, we found moderate disorders in syntactic production, single-word comprehension and phonological encoding. The mean aphasia severity score was  $3.4 \pm 0.7$  corresponding to the ability to have a meaningful conversation which becomes information-limited when complex topics have to be elaborated. Overall speech output was fluent, yet disrupted by transient pauses due to word finding difficulties which mostly occurred after determiners preceding content words.

With the aim of assessing the proportion of patients with logopenic PPA who were effectively impaired on a given test we calculated the number of patients who had abnormal performance with respect to the normative scores corresponding to the age and to the years of education for each patient. Concerning apraxia of speech, phonological sequencing errors, syntax disorders and ideomotor apraxia, abnormal performance was assumed when a given disorder was scored as present. The results are illustrated in Fig. 1. More than 80% of the patients had impaired performance on the general cognitive tests comprising the Mattis Dementia Rating Scale, the Frontal Assessment Battery and the Mini-Mental State Examination. Verbal spans were impaired in 63% of the patients and moderate ideomotor apraxia causing a spatial gesture disorder was found in 53%. No patient was disorientated in time or space as shown by Mini-Mental State Examination subscores. Language testing confirmed that 100% of the patients with logopenic PPA had abnormal capacities of sentence repetition and of picture naming concerning low frequency nouns. Naming of high frequency nouns was impaired in 68% and phonemic and category fluency was abnormal in 68% and 63% of the patients, respectively. Sentence comprehension was hampered in a smaller range (47%) and moderately impaired scores of single-word

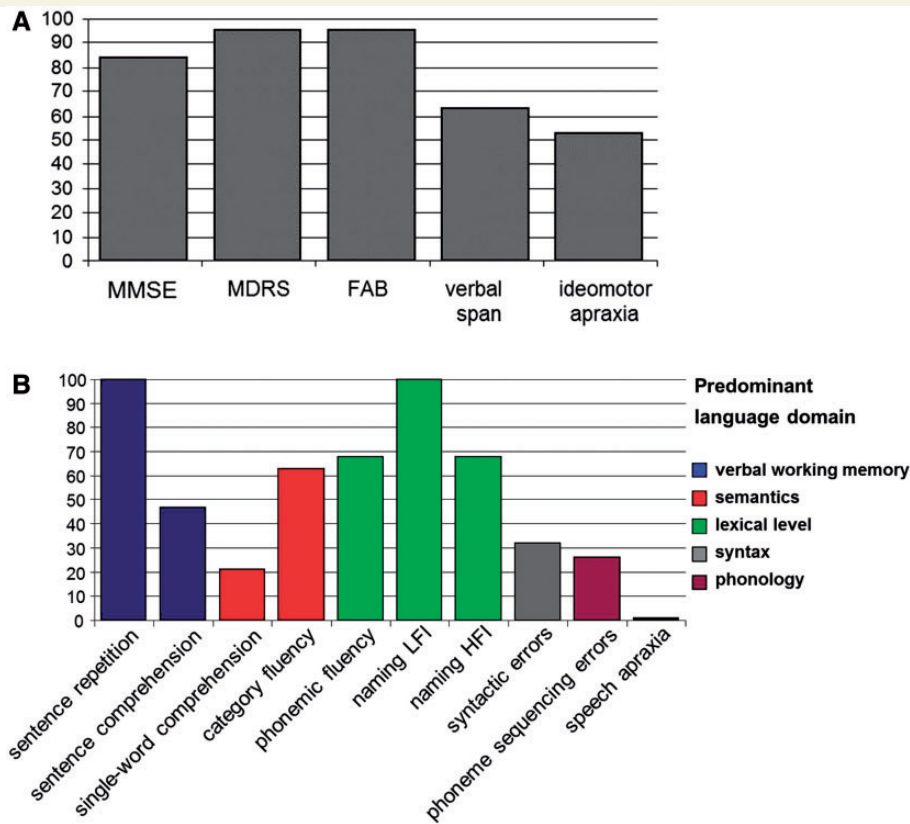
comprehension were observed in 21% of the patients. Some syntax errors such as violations of phrase structures rules, omission of function words and incorrect gender agreements or verb conjugation were found in 32% of the patients. Finally, 26% had moderate difficulties with phoneme sequencing. No patient had speech apraxia.

Given that anomia is a core feature in logopenic PPA which was present in all patients, we also characterized error types during picture naming. The results show that 75% of the naming errors corresponded to non-responses, 21% were tied to semantic paraphasias and 4% to phonemic paraphasias.

We furthermore conducted correlation analyses on the scores of the general cognitive and the language battery in order to determine tests patterning together and to specify links between impairments in the different test domains (Table 3). With respect to general cognitive tests, Mattis Dementia Rating Scale scores correlated with Mini-Mental State Examination and Frontal Assessment Battery scores. Furthermore, the scores of these three tests correlated with picture naming capacities suggesting that poor performance with general cognitive tests are primarily related to word finding problems. Aphasia severity scores correlated with picture naming and with single-word comprehension capacities suggesting that the degree of language impairment is related to the severity of word finding difficulties and that concomitant semantic disorders enhance this impairment. In addition, the analyses showed that several tests pattern one with another indicating their respective usefulness as proxy markers for specific language/cognitive domains. In particular, verbal span scores patterned with sentence repetition abilities indicating that both tasks tap into verbal working memory which appears to be hampered in patients with logopenic PPA. Furthermore, picture naming and phonemic fluency were correlated one with another suggesting that the underlying impairment in logopenic PPA is tied to deficient lexical access. Likewise, category fluency and single-word comprehension correlate one with each other indicating that they require similar resources, namely semantic knowledge which appears to be moderately impaired in logopenic PPA.

## Biological level: cerebrospinal fluid biomarkers

The results of the CSF analyses allowed for dividing the logopenic PPA population into a patient subgroup that demonstrated biomarker results indicative of Alzheimer's disease (logopenic PPA+;  $n = 8$ , 61.5% of the patients) and a subgroup for which biomarkers were not indicative of underlying Alzheimer's disease (logopenic PPA–;  $n = 5$ , 38.5% of the patients). The P-tau/Ab42 cut-off of 0.211 pg/ml and the tau/Ab42 cut-off of 1.23 pg/ml yielded consistent results assigning the same patients to the same subgroup. Furthermore, analysing the distribution of CSF data in the two subgroups revealed a bimodal distribution of P-tau / Ab42 coordinates (Fig. 2). Logopenic PPA+ and logopenic PPA– were similar with respect to age (logopenic PPA+: 65.9 years  $\pm$  8.5, logopenic PPA–: 66.2 years  $\pm$  6.9;  $F < 1$ ), sex [logopenic PPA+: four males, four females, logopenic PPA–: three males, two females;  $F(1,11) = 1.09$ ,  $P = 0.32$ ], number

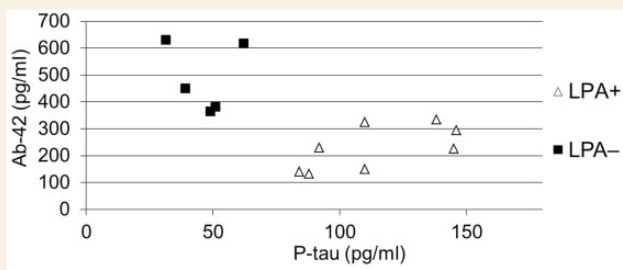


**Figure 1** Percentage of patients with logopenic PPA with impaired performance on the tests of the general cognitive battery (A) and the language battery (B). Aphasia severity = aphasia severity scale of the Boston Diagnostic Aphasia Evaluation; naming HFI = DO80 picture naming of high frequency items; naming LFI = DO80 picture naming of low frequency items. FAB = Frontal Assessment Battery; MDRS = Mattis Dementia Rating Scale; MMSE = Mini-Mental State Examination.

**Table 3** Correlation analyses between test scores of the general cognitive and the language battery

	General cognitive tests					Language tests				
		FAB	MDRS	Span	Aphasia severity	Verbal WM	Lexical processing		Semantics	
							Picture naming	Phonemic fluency	Category fluency	Single-word comprehension
MMSE	R	0.351	0.612*	0.119	0.283	0.021	0.613*	0.423	0.393	0.302
	P	0.141	0.005	0.628	0.241	0.931	0.005	0.071	0.096	0.209
FAB	R		0.707*	0.026	0.264	0.472*	0.474*	0.378	0.119	0.069
	P		0.001	0.915	0.274	0.042	0.040	0.111	0.626	0.778
MDRS	R			0.062	0.446	0.217	0.536*	0.604*	0.195	0.215
	P			0.801	0.055	0.372	0.018	0.006	0.423	0.377
Span	R				0.288	0.522*	0.352	0.073	0.094	0.345
	P				0.232	0.022	0.140	0.767	0.701	0.148
Aphasia severity	R					0.133	0.485*	0.211	0.203	0.688*
	P					0.588	0.036	0.387	0.405	0.001
Sentence repetition	R						0.040	0.036	0.117	0.056
	P						0.872	0.882	0.633	0.818
Picture naming	R							0.460*	0.414	0.447
	P							0.048	0.078	0.055
Phonemic fluency	R								0.582*	0.383
	P								0.009	0.106
Category fluency	R									0.465*
	P									0.045

R = correlation coefficient, \*P is significant at the 0.05 level (two-tailed). Verbal WM = verbal working memory. Span = direct verbal span; aphasia severity = aphasia severity scale of the Boston Diagnostic Aphasia Evaluation; picture naming = DO80 picture naming.



**Figure 2** Distribution of P-tau and Ab42 values in patients with logopenic PPA+ (open triangles) and logopenic PPA– (filled squares) revealing a bimodal distribution pattern. LPA = logopenic PPA.

of years of education [logopenic PPA+: 13.0 years  $\pm$  4.2, logopenic PPA–: 10.2 years  $\pm$  2.6;  $F(1, 11) = 1.97$ ,  $P = 0.19$ ], age of disease onset (logopenic PPA+: 62.6 years  $\pm$  8.6, logopenic PPA–: 63.0 years  $\pm$  7.1;  $F < 1$ ) and symptom duration (logopenic PPA+: 3.3  $\pm$  0.7, logopenic PPA–: 3.2 years  $\pm$  0.8;  $F < 1$ ). Biomarker results are illustrated in Table 4. Overall, ANOVAs showed that Ab42 levels were lower in logopenic PPA+ than in logopenic PPA– and that tau and P-tau levels were higher in logopenic PPA+ than in the logopenic PPA–. Moreover, Innostest amyloid tau index ratios were smaller for logopenic PPA+ patients than for logopenic PPA– patients.

### Links between biomarker and cognitive/language data

With the aim of individualizing clinical markers predictive of probable underlying Alzheimer pathology we compared logopenic PPA+ and logopenic PPA– patients with respect to test scores of the general cognitive and the language battery. ANOVAs were performed to detect significant differences between both subgroups. Results are summarized in Table 4. Logopenic PPA+ and logopenic PPA– groups had similar performance with respect to general cognitive tests including the Mini-Mental State Examination, the Mattis Dementia Rating Scale and the Frontal Assessment Battery. In contrast, analyses on language scores showed significant differences between both subgroups tied to poorer performance of logopenic PPA+ patients for proxy markers of semantics ('single-word comprehension', 'category fluency') and of phonology ('phoneme sequencing'). Furthermore, the logopenic PPA+ subgroup demonstrated poorer performance with ideomotor praxis than the logopenic PPA– subgroup. Taking into account the number of patients demonstrating normal and abnormal performance on these four tests we found different values of sensitivity and specificity for distinguishing logopenic PPA+ from logopenic PPA–. Impaired category fluency and the existence of ideomotor apraxia had a high sensitivity for logopenic PPA+ (100% and 87.5%, respectively) whereas their specificity was less important (both 80%). Conversely, disorders of phoneme sequencing and errors on single-word comprehension had a high specificity for logopenic PPA+ (100% and 80%, respectively) whereas their sensitivity was relatively poor (62.5% and 50%, respectively).

## Brain level: imaging

### Atrophy rating on magnetic resonance imaging

The ratings of the evaluators reached a high level of inter-evaluator consistency. More specifically, we found full rating concordance with respect to regions that were scored as either atrophied or not atrophied. Some scarce inter-evaluator discrepancies concerned the rating of atrophy severity but consensus was easily reached upon an additional rating session. At the visual assessment all patients with logopenic PPA demonstrated predominant brain atrophy in the left hemisphere which primarily affected parietal and temporal regions. In particular, all patients with logopenic PPA but two had severe, predominant and relatively isolated atrophy of the left temporal-parietal junction. Some patients with logopenic PPA had also atrophy in left superior parietal regions (severe 20%, slight 60%), in the left temporal pole (severe 0%, slight 33%), in the left medial temporal region (severe 20%, slight 40%) and in the frontal lobe involving the left dorsolateral (severe 13%, slight 33%) and the left inferior frontal region (severe 7%, slight 13%). Rare regions of slight atrophy were identified in the right hemisphere (temporal and parietal areas). No differences were found between logopenic PPA+ and logopenic PPA– patients. Concerning the three other groups, non-fluent/agrammatic PPA patients had predominant atrophy in left inferior and dorso-lateral frontal regions, patients with semantic PPA were mostly affected in the left temporal pole, and posterior cortical atrophy patients mainly had bilateral damage in superior and inferior parietal and occipital regions. To calculate the sensitivity and specificity of the assessment we posited the imaging criteria for logopenic PPA diagnosis as an atrophy pattern affecting predominantly and most severely the left temporal-parietal junction while relatively sparing regions affected in semantic PPA (anterior temporal cortex), non-fluent/agrammatic PPA (left inferior and dorso-lateral frontal cortex) and posterior cortical atrophy (bilateral parietal-occipital regions). We found sensitivity and a specificity of 60.0% and 71.8%, respectively, for detecting patients with logopenic PPA within this large population of PPA and posterior cortical atrophy.

### Cortical perfusion on single-photon emission computed tomography

At the visual assessment all patients with logopenic PPA had severe brain hypoperfusion of the left temporal-parietal junction. Five group contrasts were analysed and the results are illustrated in Fig. 3 and Table 5.

The contrast of the whole logopenic PPA group versus healthy controls yielded a large area of severe hypoperfusion in left parietal-temporal cortices (FWE  $P < 0.05$ ) with a peak of significance in the superior temporal gyrus [Brodmann area (BA) 42]. This pattern also involved the left precuneus. Smaller and less significant areas of hypoperfusion were also found in the left frontal lobe encompassing the dorsolateral prefrontal cortex (BA8, BA9, BA46) and the premotor cortex (BA6). The hippocampus was spared bilaterally (FWE  $P < 0.05$ ). No areas of hypoperfusion were found in the right hemisphere (FWE  $P < 0.05$ ).

**Table 4** Comparison between logopenic PPA due and not due to Alzheimer's disease on CSF biomarkers

	LPA+ (n = 8)	LPA- (n = 5)	LPA+ versus LPA-
<b>CSF biomarkers</b>			
Ab42	256 pg/ml ± 127	452 pg/ml ± 195	$F(1,11) = 4.93, P = 0.048^*$
Tau	745 pg/ml ± 392	271 pg/ml ± 46	$F(1,11) = 7.02, P = 0.023^*$
P-tau	103 pg/ml ± 43	46 pg/ml ± 12	$F(1,11) = 7.79, P = 0.018^*$
IATI	0.23 ± 0.06	0.82 ± 0.40	$F(1,11) = 17.40, P = 0.002^*$
Tau / Ab42	2.88 ± 1.12	0.69 ± 0.27	$F(1,11) = 17.89, P = 0.001^*$
P-tau / Ab42	0.42 ± 0.17	0.12 ± 0.05	$F(1,11) = 14.59, P = 0.003^*$
<b>General cognitive assessment</b>			
MMSE	21.3 ± 4.1	22.6 ± 4.2	$F < 1$
MDRS	117.1 ± 12.7	122.6 ± 8.4	$F < 1$
FAB	11.0 ± 2.4	11.4 ± 3.4	$F < 1$
Verbal span (standard note)	4.5 ± 2.6	4.0 ± 3.0	$F < 1$
Ideomotor apraxia	87.5 ± 35.4 <sup>a</sup>	20.0 ± 44.7 <sup>a</sup>	<b><math>F(1,11) = 9.21, P = 0.011^*</math></b>
<b>Language assessment</b>			
Severity rating scale BDAE	3.3 ± 0.9	3.4 ± 0.5	$F < 1$
Sentence repetition BDAE	9.1 ± 2.9	10.0 ± 3.4	$F < 1$
Sentence comprehension BDAE	7.4 ± 2.8	6.4 ± 1.5	$F < 1$
Single-word comprehension BDAE	global <sup>b</sup> : 61.9 ± 12.2 errors <sup>b</sup> : 2.9 ± 2.6	global <sup>b</sup> : 69.5 ± 2.7 errors <sup>b</sup> : 0.2 ± 0.4	$F(1,11) = 1.83, P = 0.204$ <b><math>F(1,11) = 4.88, P = 0.049^*</math></b>
Category fluency ('fruits' per 2 min)	5.6 ± 4.1	14.2 ± 4.7	<b><math>F(1,11) = 12.04, P = 0.005^*</math></b>
Phonemic fluency ('P' per 2 min)	7.6 ± 4.5	11.6 ± 4.9	$F(1,11) = 2.22, P = 0.164$
DO80 (LFI)	21.3 ± 8.3	22.8 ± 10.6	$F < 1$
DO80 (HFI)	57.1 ± 18.3	71.0 ± 10.3	$F(1,11) = 2.36, P = 0.153$
Number of semantic paraphasias (HFI)	4.0 ± 5.0	2.8 ± 1.3	$F < 1$
Number of phonemic paraphasias (HFI)	0.5 ± 1.1	0.8 ± 1.3	$F < 1$
Number of non-responses (HFI)	13.0 ± 13.3	5.4 ± 8.3	$F(1,11) = 1.29, P = 0.280$
Syntactic disorders	25.0 ± 46.3 <sup>a</sup>	40.0 ± 54.8 <sup>a</sup>	$F < 1$
Disorders of phoneme sequencing	62.5 ± 51.8 <sup>a</sup>	0 ± 0 <sup>a</sup>	<b><math>F(1,11) = 7.05, P = 0.022^*</math></b>

BDAE = Boston Diagnostic Aphasia Evaluation; FAB = Frontal Assessment Battery; IATI = Innotest amyloid tau index; LFI = low frequency items; LPA = logopenic PPA; HFI = high frequency items; MDRS = Mattis Dementia rating Scale; MMSE = Mini-Mental State Examination.

\* $P$  is significant at the 0.05 level (bold characters).

<sup>a</sup>Corresponds to the percentage of impaired patients.

<sup>b</sup>The global score of single-word comprehension accounts for both errors and response latencies.

Analysing logopenic PPA subgroups showed that the 'logopenic PPA- versus healthy controls' contrast yielded a pattern of bilateral but asymmetric hypoperfusion in the occipito-temporo-parietal junction centred on left inferior parietal areas (FWE  $P < 0.05$ ). Smaller and less severe areas of hypoperfusion were also found within the left dorsolateral prefrontal cortex (BA8) (FWE  $P < 0.05$ ). The hippocampus was spared bilaterally (FWE  $P < 0.05$ ). Conversely, the 'logopenic PPA+ versus healthy controls' contrast showed severe hypoperfusion in the left parietal cortex mainly involving the angular gyrus (BA39) and extending to the posterior temporal cortex (FWE  $P < 0.05$ ). This hypoperfusion of the temporal-parietal junction was more extensive throughout the inferior parietal, the posterior-superior and the middle temporal cortex than in the logopenic PPA- group. Furthermore, analyses showed hypoperfusion of the left precuneus (FWE  $< 0.05$ ).

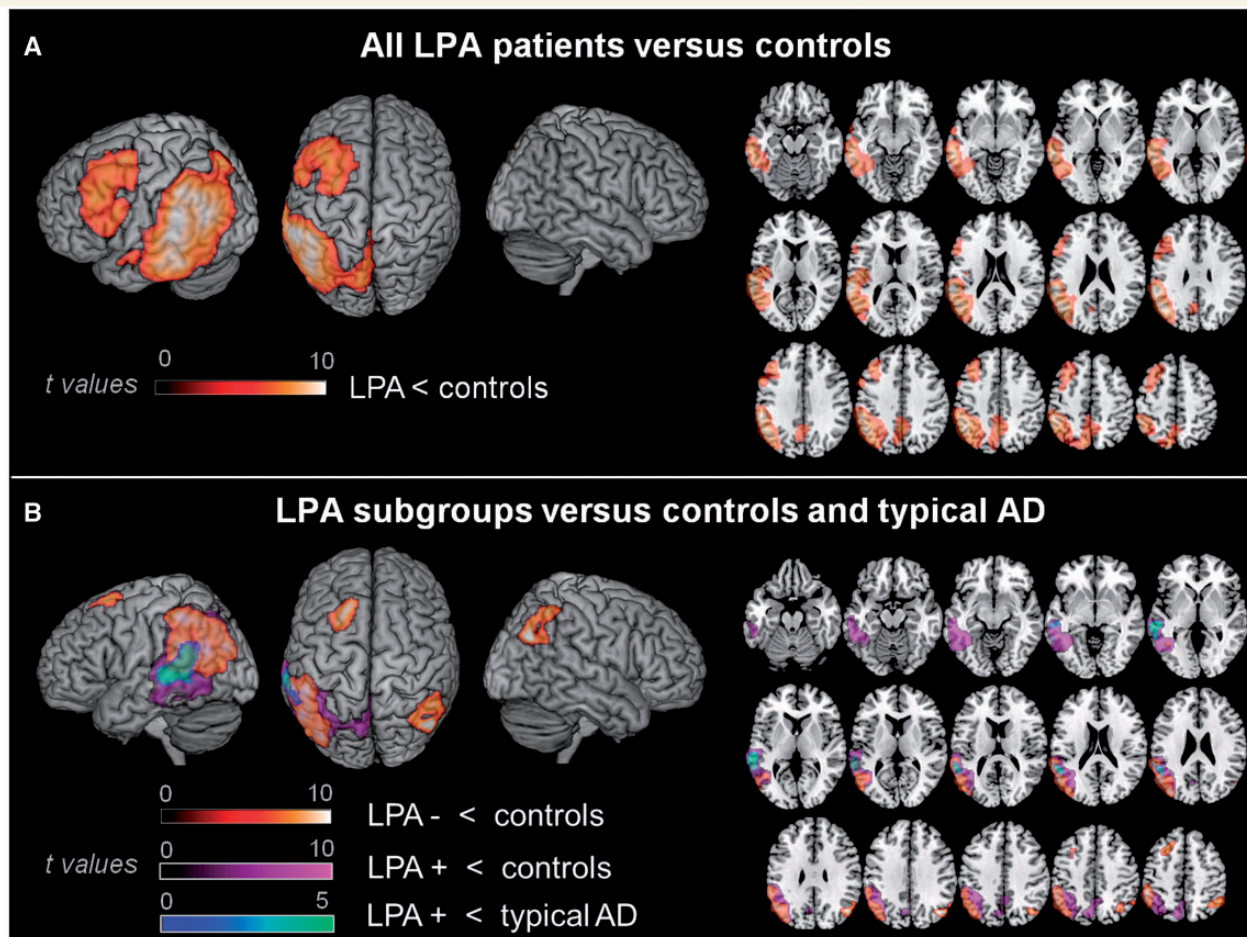
Concerning comparisons with the amnesic Alzheimer group, the 'Alzheimer versus healthy controls' contrast provided a typical Alzheimer's disease pattern showing bilateral and symmetrical hypoperfusion throughout the posterior cortex including the precuneus and extending to hippocampal regions and the dorsolateral

prefrontal cortex (FWE  $P < 0.05$ ). Furthermore, the 'logopenic PPA+ versus amnesic Alzheimer' contrast showed that the left superior temporal gyrus (BA22) was more severely hypoperfused in patients with logopenic PPA+ as compared with patients with typical amnesic Alzheimer's disease ( $P < 0.001$ , uncorrected). Conversely, hypoperfusion of the left hippocampus region was only found in the amnesic Alzheimer group. No regions of hypoperfusion were found in the hippocampal areas in logopenic PPA+.

## Discussion

This study explored a large cohort of 19 stringently diagnosed patients with logopenic PPA and provided a three-level characterization including cognitive/linguistic features, brain localization and biological aspects. It also allowed for revealing the important prevalence of logopenic PPA within the PPA spectrum accounting for about 31% of all patients with PPA. Thus, logopenic PPA appears to be the second most frequent PPA variant behind semantic PPA (39%) and before the non-fluent/agrammatic variant (18%). Our demographic data furthermore indicated that logopenic





**Figure 3** Brain hypoperfusion patterns in patients with logopenic PPA (LPA) using Statistical Parametric Mapping: comparison with healthy controls and patients with typical Alzheimer's disease (AD).  $T$ -score hypoperfusion maps of (A) the entire logopenic PPA group compared with healthy age-matched controls; (B) logopenic PPA patients classified according to their CSF biomarkers profiles. The 'logopenic PPA– versus controls' (red to white tints) and the 'logopenic PPA+ versus controls' contrast (purple to violet tints) showed hypoperfusion of the left temporal-parietal junction with a more extensive defect in the latter group contrast affecting larger portions of the temporal cortex. The 'logopenic PPA+ versus typical amnesic Alzheimer's disease' contrast (blue to green tints) showed that the left superior temporal gyrus was more specifically affected in logopenic PPA+ as compared to typical Alzheimer's disease.  $T$ -maps are projected onto a surface rendering and onto axial views of the customized MNI template. The axial slices are shown in accordance with neurological convention (right is right).

PPA is an early-onset disease corresponding to a mean onset age of ~63 years.

Our language/cognitive findings showed that, according to the diagnostic criteria of Gorno-Tempini *et al.* (2011), all patients with logopenic PPA had picture naming and sentence repetition difficulties which were quantitatively the most severe disorders. The second most impaired faculties were phonemic and category fluency, followed by sentence comprehension, syntactic production, phoneme sequencing and single-word comprehension. Correlation analyses showed that naming difficulties patterned with scores of phonemic fluency suggesting that the underlying language disorder in logopenic PPA is linked to impaired access to lexical representations or to genuine damage of the output lexicon. Such naming errors did not correlate with proxy markers of semantics and were primarily related to non-responses thus arguing against a top-down mechanism tied to semantic damage. In contrast, the

input lexicon seems to be relatively preserved in logopenic PPA given that single-word comprehension was only moderately hampered. Furthermore, single-word comprehension patterned with category fluency which rather suggests a concomitant yet slight damage of semantic representations. In line with these results the overall severity of aphasia correlated with the intensity of lexical disorders as well as with the concomitant impairment of semantic representations. Lexical dysfunction in logopenic PPA also impacts on standard neuropsychological tests such as the Mini-Mental State Examination, the Frontal Assessment Battery or the Mattis Dementia Rating Scale, the poor outcome of which significantly correlated with naming scores. Beyond lexical impairment, the second main disorder in logopenic PPA is the reduction of verbal working memory which is corroborated by the fact that both verbal span and sentence repetition yielded poor test scores which furthermore correlated one with another. Our results also

**Table 5** Quantitative statistical parametric mapping results: logopenic PPA and comparisons with healthy control subjects and typical Alzheimer's disease

Region (Brodmann area)	Coordinates (x, y, z)	T-value	P-value	Cluster size
<b>All patients with logopenic PPA &lt; controls</b>				
<b>Left superior temporal gyrus (42)</b>	<b>−64, −36, 18</b>	<b>10.9</b>	<b>&lt;0.000</b>	<b>16 025</b>
Left angular gyrus (39)	−50, −62, 28	10.0		
Left inferior parietal gyrus (40)	−50, −42, 48	9.9		
<b>Left superior frontal gyrus (6)</b>	<b>−30, 2, 68</b>	<b>8.1</b>	<b>&lt;0.000</b>	<b>3180</b>
Left middle frontal gyrus (9,8)	−40, 26, 38	8.0		
Left middle frontal gyrus (9,8)	−36, 20, 46	7.6		
<b>Peculiar hypoperfused areas in logopenic PPA+ and logopenic PPA−</b>				
<b>Logopenic PPA− &lt; controls</b>				
<b>Right angular gyrus (39)</b>	<b>46, −68, 32</b>	<b>9.6</b>	<b>&lt;0.000</b>	<b>687</b>
Right inferior parietal gyrus (40)	50, −54, 52	6.7		
Right inferior parietal gyrus (40)	56, −58, 30	5.8		
<b>Left inferior parietal gyrus (40)</b>	<b>−64, −40, 24</b>	<b>8.3</b>	<b>&lt;0.000</b>	<b>3696</b>
Left inferior parietal gyrus (40)	−54, −44, 48	8.0		
Left angular gyrus (39)	−56, −62, 24	7.8		
<b>Left superior frontal gyrus (8)</b>	<b>−20, 22, 54</b>	<b>7.8</b>	<b>&lt;0.000</b>	<b>615</b>
Left middle frontal gyrus (8)	−34, 8, 44	5.1		
<b>Logopenic PPA+ &lt; controls</b>				
<b>Left angular gyrus (39)</b>	<b>−44 −64 28</b>	<b>12.1</b>	<b>&lt;0.001</b>	<b>9004</b>
Left inferior parietal gyrus (40)	−54 −44 44	9.4		
Left middle temporal gyrus (21)	−40 −50 −8	9.3		
<b>Left precuneus (31)</b>	<b>−8 −68 28</b>	<b>7.5</b>	<b>&lt;0.001</b>	<b>745</b>
Left precuneus (31)	−1 −54 42	6.3		
<b>Logopenic PPA+ &lt; typical Alzheimer's disease</b>				
<b>Left superior temporal gyrus (22)</b>	<b>−62, −30, 2</b>	<b>4.1</b>	<b>&lt;0.05</b>	<b>709</b>
Left superior temporal gyrus (22)	−58, −48, 20	3.5		

Coordinates are in millimetres relative to the anterior commissure, corresponding to the MNI space. Statistical maps were thresholded for significance at  $P < 0.05$  FWE-corrected except for the comparison between logopenic PPA+ and typical Alzheimer's disease ( $P < 0.001$  uncorrected). Cluster extent was set at 300 voxels. Bold characters indicate areas with the most severe hypoperfusion for a given group contrast.

demonstrate that cognitive disorders in logopenic PPA extend even deeper into the language system as well as beyond it, affecting syntactic processing and phoneme sequencing, causing the above mentioned degradation of semantic representations and leading to ideomotor apraxia.

With respect to biological aspects, CSF biomarkers which were used as a surrogate of underlying neuropathology showed that 61.5% of the patients with logopenic PPA had probable Alzheimer's disease (logopenic PPA+) whereas in 38.5% the profile was not indicative of Alzheimer's disease (logopenic PPA−). Multiple comparisons showed that both subgroups were matched on age, number of years of education, symptom duration and standard neuropsychological tests but that patients with logopenic PPA+ demonstrate significantly poorer performance in the domains of phonology, semantics and ideomotor praxis. Pathological test scores in these domains had a relatively high sensitivity and specificity in detecting logopenic PPA related to Alzheimer's disease, which reached 100% sensitivity for impaired category fluency scores and 100% specificity for phoneme sequencing disorders.

Regarding neuroimaging, our results highlight that patients with logopenic PPA demonstrate a typical lesion pattern, namely damage of the left temporal-parietal junction. Visual MRI analysis

showed that 87% of the patients with logopenic PPA had atrophy of the left temporal-parietal junction but it also reveals that such an assessment has a relatively poor sensitivity (60%) and specificity (72%) for detecting logopenic PPA among the different PPA variants and posterior cortical atrophy. Analysing brain perfusion on SPECT revealed that 100% of the patients with logopenic PPA had hypoperfusion of the left temporal-parietal junction. Comparing the logopenic PPA group as a whole with healthy age-matched controls further allowed for quantifying the temporal-parietal junction disorder which corresponded to the most prominent and significant hypoperfusion cluster. This finding replicates previous imaging results on logopenic PPA including both PET and voxel-based morphometry studies (Gorno-Tempini *et al.*, 2004; Josephs *et al.*, 2010; Rohrer *et al.*, 2010b) while emphasizing the imaging-supported logopenic PPA diagnosis of our patients (Gorno-Tempini *et al.*, 2011). Moreover, the comparison with typical amnesic Alzheimer's disease strengthened the distinctive imaging pattern of logopenic PPA which specifically involves the left superior-posterior temporal gyrus in patients with logopenic PPA having biomarkers indicative of Alzheimer pathology. In addition, unlike in typical Alzheimer's disease, hippocampal regions were spared in logopenic PPA+. However, the partial overlap of

impaired regions including posterior temporal-parietal regions and the precuneus suggests the existence of a shared 'core network' the alteration of which may be characteristic of Alzheimer's disease (Warren *et al.*, 2012). Finally, SPECT data also indicated that the cortical perfusion pattern might differentiate logopenic PPA+ from logopenic PPA– by showing that the former subgroup has more widespread hypoperfusion exceeding the temporal-parietal junction and affecting larger regions throughout the inferior parietal, the posterior-superior and the middle temporal cortex. In addition to the temporal-parietal junction, we also found hypoperfusion of the precuneus and of the left dorsolateral prefrontal cortex which is in line with previous atrophy data drawn from voxel-based morphometry studies on patients with logopenic PPA with similar symptom durations (Migliaccio *et al.*, 2009; Rohrer *et al.*, 2010b). One hypothesis is therefore that neural degeneration in logopenic PPA directly affects distinct cortical sites and notably the temporal-parietal junction and the dorsolateral prefrontal cortex. Conversely, it might be hypothesized that cortical damage primarily affects the left temporal-parietal junction causing profound disconnection of dorsolateral prefrontal regions through the alteration of superior components of the superior longitudinal fasciculus as evidenced by Galantucci *et al.* (2011). Disentangling such hypotheses requires further studies tracking and correlating the time course of damage affecting the prefrontal cortex and connexion fibres of the superior longitudinal fasciculus.

Finally, with respect to logopenic PPA– it should be noted that one may ask whether these patients had genuine logopenic PPA given that 40% had syntactic disorders and because they demonstrated temporal-parietal junction and frontal hypoperfusion on SPECT. At first glance such a profile could suggest non-fluent/agrammatic PPA rather than logopenic PPA. However, in-depth analyses of the data easily overcome this doubt. First, our parsimonious patient selection procedure showed that all five logopenic PPA– had predominant word finding and sentence repetition difficulties whereas syntactic disorders were only mild in two of them. No patient had 'frank agrammatism' but all had frank lexical and verbal working memory disorders. The same pattern, with even less syntactic errors, was found on speech recordings realized 1 year before study inclusion. Second, according to imaging-supported logopenic PPA criteria (Gorno-Tempini *et al.*, 2011) our SPECT results of the logopenic PPA– group showed clearly predominant hypoperfusion of the left temporal-parietal junction. Reviewing the individual SPECT data of the two mildly syntax-impaired patients also evidenced this temporal-parietal junction pattern (Supplementary Fig. 1). Finally, the hypoperfused area within the prefrontal cortex (BA8) which was found in the voxel-based analyses was smaller, less severe and did not affect syntax-related language areas such as BA45 or BA44, which are typically involved in agrammatic PPA (Gorno-Tempini *et al.*, 2004).

## The language–brain pattern of logopenic primary progressive aphasia

Our results substantiate that the core feature in logopenic PPA comprehends hampered access or damage of the output lexicon and reduced verbal working memory which are associated with

primary dysfunction of the left temporal-parietal junction. These findings are coherent with previous studies on logopenic PPA showing predominant impairment of single-word retrieval and sentence repetition (Gorno-Tempini *et al.*, 2004, 2008; Hu *et al.*, 2010; Rohrer *et al.*, 2010b; Leyton *et al.*, 2011) and left-sided temporal-parietal junction atrophy on voxel-based morphometry (Gorno-Tempini *et al.*, 2004; Migliaccio *et al.*, 2009; Rohrer *et al.*, 2010b). They are also in line with functional imaging results with healthy adults providing evidence that lexical processing is tied to inferior parietal (Tyler *et al.*, 2005) and posterior temporal cortices (Kotz *et al.*, 2002), and that phonological short time memory is linked to the supramarginal gyrus (Paulesu *et al.*, 1993; Jonides *et al.*, 1998). In addition, our findings provide novel evidence allowing for refining the linguistic profile of logopenic PPA and indicating the neural substrates of its different components.

Concerning the functional profile, our results show that processing disorders in logopenic PPA extend deeper into the language system affecting also semantic representations, syntactic production and phonological mechanisms of phoneme encoding. At first glance this seems surprising because studies on logopenic PPA did not explicitly report such disorders except the possible existence of phonological difficulties mentioned in the consensus criteria of Gorno-Tempini *et al.* (2011). However, detailed analysis of language data from studies on logopenic PPA readily suggest syntactic disorders as reflected by poor scores on sentence comprehension tasks (Gorno-Tempini *et al.*, 2004, 2008; Rohrer *et al.*, 2010b). As such comprehension tasks draw not only on syntax but also on verbal working memory, poor performance was commonly attributed to a sentence length effect rather than to syntactic complexity *per se*. In contrast, the present study assessed sentence processing in the production modality, which is independent from verbal input working memory, unveiling various grammatical errors that confirm syntactic dysfunction in logopenic PPA. Similarly, semantic deficits have been mostly overlooked although detailed inspection of the data of Gorno-Tempini *et al.* (2008) shows that two of six patients with logopenic PPA had semantic difficulties, one of whom demonstrated 10% errors on single-word comprehension. This difficulty of single-word comprehension becomes even more salient during disease evolution as substantiated in a recent study reporting clinical follow-up of 13 patients with logopenic PPA (Leyton *et al.*, 2013). Thus, the total range of language impairments is more widespread than usually acknowledged comprehending additional disorders that might increase over time and ultimately expose patients with logopenic PPA to potential misdiagnosis within the PPA spectrum. SPECT imaging, however, should contribute to a correct logopenic PPA diagnosis by showing predominant hypoperfusion of the left temporal-parietal junction at least for the first 3 years of evolution.

Although we did not conduct lesion-function correlations the present SPECT results provide some hints with respect to the brain substrates underpinning the three additional language disorders. More specifically, the hypoperfusion pattern suggests that these disorders presumably are not related to cortical dysfunction of regions which are classically dedicated to semantic, syntactic or phonological processing. In particular, the temporal pole which is a key region for semantic knowledge (Patterson *et al.*, 2007), the

posterior-inferior frontal cortex that is crucial to phonological encoding (Papoutsis *et al.*, 2009) and posterior-inferior frontal and antero-superior temporal cortices that are core areas for syntactic processing (Friederici *et al.*, 2003; Pallier *et al.*, 2011) were largely spared in our logopenic PPA population. One plausible hypothesis is therefore that such additional language disorders are related to previously reported damage of the white matter underneath the temporal-parietal junction region (Rohrer *et al.*, 2010b; Migliaccio *et al.*, 2012) which encompasses fibre bundles running from superior temporal/inferior parietal cortices to posterior frontal areas (Catani *et al.*, 2005) and possibly to the temporal pole (Acosta-Cabronero *et al.*, 2011). Such damage might therefore lead to functional disconnections between lexical representations in the left temporal-parietal junction cortex and remote cortical areas which underpin phonological spell-out of words, syntactic concatenation and semantic processing. In particular, progressive disconnection of the temporal pole presumably leads to deficits in semantic processing tasks whereas progressive disconnection of the posterior-inferior frontal cortex causes deficits in syntactic and phonological encoding. This view is substantiated by recent DTI tractography data showing that brain damage in logopenic PPA affects several components of the superior longitudinal fasciculus including the arcuate (Galantucci *et al.*, 2011) which projects to the posterior-inferior frontal cortex (Catani *et al.*, 2005; Rilling *et al.*, 2008). Likewise, several authors (Galantucci *et al.*, 2011; Mahoney *et al.*, 2013) have reported abnormal diffusivity values in the anterior and posterior portion of the inferior longitudinal fasciculus of patients with logopenic PPA suggesting damage of this pathway, which has been shown to project onto the temporal pole (Catani *et al.*, 2003). Finally, damage of the temporal-parietal portion of the arcuate as evidenced by Galantucci *et al.* (2011) might affect fibre contingents within this tract which, according to Acosta-Cabronero *et al.* (2011), might connect the temporal-parietal junction and the temporal pole. However, it should be noted that, in addition to the probable disconnection of the temporal pole, damage of the temporal-parietal junction cortex as such might also contribute to semantic processing disorders in logopenic PPA. Accordingly, several functional imaging studies with healthy adults have reported that the temporal-parietal junction was involved when participants performed lexical-semantic tasks (Binder *et al.*, 2003; Spitsyna *et al.*, 2006). It should also be noted that progressive disconnection of white matter pathways directly hampers the transmission of linguistic information to the connected cortical sites but that it does not necessarily cause cortical damage on SPECT or PET (Metter *et al.*, 1988). In the same vein, Josephs *et al.* (2012) have shown that a PPA-related syndrome (primary progressive apraxia of speech) comprehends damage of the left premotor cortex and of the underlying superior longitudinal fasciculus, yet without any cortical dysfunction of the parietal/temporal endpoints of this fibre bundle on PET. Finally, using functional MRI Sonty *et al.* (2003) have explored patients with PPA with single word-finding problems and atrophy of the left temporal-parietal junction region, showing that these patients had impaired performance on phonological processing despite normal activation of the posterior-inferior frontal cortex. To sum up, logopenic PPA seems to be characterized by a left-lateralized network-level dysfunction

including primarily the temporal-parietal junction cortex but affecting also major white matter pathways of language processing. This proposal is in line with findings of Rohrer *et al.* (2010b) who posited that logopenic PPA is a network-based syndrome that implicates distributed dominant hemisphere cortices and white matter connections. Clinical, PET and DTI follow-up studies are now needed to explore whether the ongoing neural degeneration progressively disconnects and ultimately alters the function of key areas of the language cortex thus transforming logopenic PPA insidiously into a global aphasia disease.

## Variants of logopenic primary progressive aphasia

Our findings also highlight that the unique language-brain entity of logopenic PPA should be considered as a clinical and topographic syndrome without presuming its underlying pathology, especially at the individual level. Our CSF data suggested, however, that the temporal-parietal junction region appears to be more vulnerable to Alzheimer's disease (61.5% of the patients) than to non-Alzheimer's disease (38.5%). This result tightly fits the findings of the largest neuropathological logopenic PPA cohort ( $n = 11$ ) which has revealed an Alzheimer's disease proportion of 64% whereas one-third of the cases were related to lesions characteristic of frontal-temporal lobar degeneration such as ubiquitine-positive (27%) or tau-positive pathology (9%) (Mesulam *et al.*, 2008). The same tendency has been shown by previous studies using surrogate markers such as PET-PIB and CSF biomarkers indicating that 58% (Hu *et al.*, 2010) to 92% of logopenic PPA cases (Leyton *et al.*, 2011) are related to underlying Alzheimer's disease. Finally, two case studies have suggested that logopenic PPA might be linked to a fourth neurodegenerative mechanism, namely Lewy body disease (Caselli *et al.*, 2002; Teichmann *et al.*, 2013). This multiplicity of causative mechanisms thus warrants caution when considering a given patient with logopenic PPA and invites re-discussion of the proposal that logopenic PPA represents an atypical form of Alzheimer's disease (Migliaccio *et al.*, 2009). In clinical practice, several language/cognitive parameters may contribute to disentangle logopenic PPA related to probable Alzheimer's disease from such non-Alzheimer subvariants. More specifically, given a symptom duration of  $\sim 3$  years, we showed that significant difficulties with phonological encoding, semantic processing and ideomotor praxis strongly suggest underlying Alzheimer disease. Such supplementary disorders also indicate that logopenic PPA+ is an aggressive and rapidly expanding disease whereas logopenic PPA- seems to demonstrate a more circumscribed evolution. Our SPECT data are in accordance with this view showing that, compared with logopenic PPA-, logopenic PPA+ affects a larger cortical region extending beyond the temporal-parietal junction. In this vein, deficits with ideomotor praxis are presumably related to damage affecting additional regions of the left parietal cortex whereas semantic and phonological disorders might reflect the above mentioned disruption of connection fibres projecting to remote cortices involved in semantics and phonology. Altogether, we propose that logopenic PPA might be subdivided into an expansive variant due to Alzheimer's

disease and a more localized variant not linked to Alzheimer pathology. Some caution is, however, warranted given that the present SPECT exploration included a relatively small sample of patients with logopenic PPA–. Nonetheless our proposal is coherent with previous findings showing that early-onset Alzheimer's disease, as opposed to the typical late-onset form, is an aggressive disease characterized by a high lesion burden leading to spreading atrophy and causing more extensive and rapid cognitive decline (Jacobs *et al.*, 1994; Rogava, 2002; Frisoni *et al.*, 2007). In addition, one should note that expansive structural damage and supplementary linguistic disorders including syntax and semantics have also been reported in patients with logopenic PPA with mutations of the progranulin gene (Rohrer *et al.*, 2010a, b). Four of our five logopenic PPA– patients had plasma measures of progranulin which were not indicative of gene mutations thus suggesting possible lesions of non-progranulin-related frontal-temporal lobar degeneration, which might lead to a more limited damage pattern. Longitudinal studies confronting clinical data with amyloid biomarkers, such as PET-PIB, and genetic data should further contribute to disentangle the distinct logopenic PPA subvariants while unveiling their respective damage dynamics. At a clinical level, such studies may also validate the non-invasive cognitive/linguistic markers which should contribute to sub-classify logopenic PPA variants.

## Logopenic and non-classifiable primary progressive aphasia

From a pragmatic point of view, our findings are also relevant for the clinical necessity to correctly classify patients with PPA. They provide answers to the doubt about the existence of logopenic PPA which was formulated by Sajjadi *et al.* (2012) and they may clarify why some authors report a relatively high proportion of non-classifiable or mixed variants within the PPA spectrum (Grossman and Ash, 2004; Deramecourt *et al.*, 2010; Leyton *et al.*, 2011; Sajjadi *et al.*, 2012). Questioning the mere existence of logopenic PPA, Sajjadi *et al.* (2012) have reported that within PPA, typical logopenic PPA is scarce (4% of their patients) whereas mixed or non-classifiable PPA is a frequent finding accounting for 41% of the patients. In striking contrast to this view, our results have revealed that predominant word-finding and sentence repetition disorders that positively define the logopenic PPA phenotype frequently co-occur in PPA (31% of our patients with PPA). Moreover, in all these patients SPECT has shown hypoperfusion of the same cortical region, namely the left temporal-parietal junction. Interestingly, when analysing in detail the data of Sajjadi *et al.* (2012) the seeming discrepancies almost fade away. Eighteen of their 19 mixed-labelled patients with PPA demonstrated naming and sentence repetition disorders. In addition, they also had syntactic, semantic or phonological difficulties, which is coherent with our data showing that mainly logopenic PPA+ patients have rather wide spread language disorders including semantic and phonological impairments. Unfortunately, the authors did not provide imaging data and it remains unknown whether their mixed-labelled patients had predominant damage of the temporal-parietal junction, which would be coherent with

the findings of the present study. Generally speaking, a certain proportion of so-called mixed or non-classifiable PPA could reflect the natural evolution of the expansive variant of logopenic PPA due to Alzheimer pathology. In addition, some mixed phenotypes might also arise from gene mutations as reported by Rohrer *et al.* (2010a, b) who described the association of naming, sentence repetition, semantic and grammatical disorders in patients with PPA with mutations of the progranulin gene. Follow-up studies are needed to further substantiate that logopenic PPA due to Alzheimer's disease might evolve to particular forms of 'mixed' or 'non-classifiable' PPA and that other atypical phenotypes should motivate clinicians to actively research non-degenerative or genetic causes.

## Limitations

As mentioned above, the proposed interpretation of our data has several limitations that need to be considered. First, even if the whole patient set of this study is one of the most important logopenic PPA samples, the subgroups that were contrasted in the SPECT and CSF analyses were relatively small. Thus, the distinctive imaging and cognitive/linguistic patterns of logopenic PPA due to probable Alzheimer's disease and of logopenic PPA– require further substantiation through larger-scale multi-centre studies. In the same vein, CSF biomarker results and subsequent analyses of subgroups need to be confirmed by replicating our results with other markers comprehending amyloid imaging like PET-PIB and ultimately neuropathological data as gold standard. Concerning the disease severity of logopenic PPA+, longitudinal investigations using size-equalized comparator groups should reinforce our proposal by providing a dynamic picture of the multifaceted logopenic PPA spectrum while distinguishing aggressive from less aggressive disease variants. Finally, the links between brain and language damage in logopenic PPA were inferred upon neurolinguistic findings on language implementation but need further support from correlation analyses linking language data to precise cortical and subcortical structures through for example, voxel-based morphometry and fibre-tracking. Nonetheless our results represent a first step towards the refining of knowledge about the language and imaging profile in logopenic PPA while unveiling that it unfolds into at least two variants due, or not, to probable Alzheimer pathology. The distinction of such entities with respect to cognitive patterns, anatomical profiles and disease severity has important implications for patient management as well as for potential future therapies.

## Funding

The research leading to these results has received funding from the program "Investissements d'avenir" ANR-10-IAIHU-06 (Agence Nationale de la Recherche - Institut Hospitalo-Universitaire). Furthermore, Raffaella Migliaccio received funding from the NeRF (Neuropole de Recherche Francilien) and from the "France Alzheimer" foundation.

## Supplementary material

Supplementary material is available at *Brain* online.

## References

- Acosta-Cabrero J, Patterson K, Fryer TD, Hodges JR, Pengas G, Williams GB, et al. Atrophy, hypometabolism and white matter abnormalities in semantic dementia tell a coherent story. *Brain* 2011; 134: 2025–35.
- Binder JR, McKiernan KA, Parsons ME, Westbury CF, Possing ET, Kaufman JN, et al. Neural correlates of lexical access during visual word recognition. *J Cogn Neurosci* 2003; 15: 372–93.
- Boutet C, Chupin M, Colliot O, Sarazin M, Mutlu G, Drier A, et al. Alzheimer's Disease Neuroimaging Initiative. Is radiological evaluation as good as computer-based volumetry to assess hippocampal atrophy in Alzheimer's disease? *Neuroradiology* 2012; 54: 1321–30.
- Cardebat D, Doyon B, Puel M, Goulet P, Joannette Y. Evocation lexicale formelle et sémantique chez des sujets normaux. Performances et dynamiques de la production en fonction du sexe, de l'âge et du niveau d'étude. *Acta Neurol Belg* 1990; 90: 207–17.
- Caselli RJ, Beach TG, Sue LI, Connor DJ, Sabbagh MN. Progressive aphasia with Lewy bodies. *Dement Geriatr Cogn Disord* 2002; 14: 55–8.
- Catani M, Jones DK, Donato R, Ffytche DH. Occipitotemporal connections in the human brain. *Brain* 2003; 126: 2093–107.
- Catani M, Jones DK, Ffytche DH. Perisylvian language networks of the human brain. *Ann Neurol* 2005; 57: 8–16.
- Cruz de Souza L, Lamari F, Belliard S, Jardel C, Houillier C, De Paz R, et al. Cerebrospinal fluid biomarkers in the differential diagnosis of Alzheimer's disease from other cortical dementias. *J Neurol Neurosurg Psychiatry* 2011; 82: 240–6.
- Deloche G, Hannequin D, editors. *Test de denomination orale d'images*. Paris: les Éditions du Centre de Psychologie Appliquée; 1997.
- Deramecourt V, Lebert F, Debachy B, Mackowiak-Cordoliani MA, Bombois S, Kerdraon O, et al. Prediction of pathology in primary progressive language and speech disorders. *Neurology* 2010; 74: 42–9.
- Dubois B, Feldman HH, Jacova C, Dekosky ST, Barberger-Gateau P, Cummings J, et al. Research criteria for the diagnosis of Alzheimer's disease: revising the NINCDS-ADRDA criteria. *Lancet Neurol* 2007; 6: 734–46.
- Dubois B, Slachevsky A, Litvan I, Pillon B. The FAB, a frontal assessment Battery at bedside. *Neurology* 2000; 55: 1621–6.
- Folstein M, Folstein S, McHugh PR. Mini-Mental state: a practical method for grading the cognitive state of patients for the clinician. *J Psychiatr Res* 1975; 12: 189–98.
- Friederici A, Ruschemeyer SA, Hahne A, Fiebach CJ. The role of left inferior frontal and superior temporal cortex in sentence comprehension: localising syntactic and semantic processes. *Cereb Cortex* 2003; 13: 70–7.
- Frisoni GB, Pievani M, Testa C, Sabattoli F, Bresciani L, Bonetti M, et al. The topography of grey matter involvement in early and late onset Alzheimer's disease. *Brain* 2007; 130: 720–30.
- Galantucci S, Tartaglia MC, Wilson SM, Henry ML, Filippi M, Agosta F, et al. White matter damage in primary progressive aphasias: a diffusion tensor tractography study. *Brain* 2011; 134: 3011–29.
- Gorno-Tempini ML, Brambati SM, Ginex V, Ogar JM, Dronkers NF, Marcone A, et al. The logopenic/phonological variant of primary progressive aphasia. *Neurology* 2008; 71: 1227–34.
- Gorno-Tempini ML, Dronkers NF, Rankin KP, Ogar JM, Phengrasamy L, Rosen HJ, et al. Cognition and anatomy in three variants of primary progressive aphasia. *Ann Neurol* 2004; 55: 335–46.
- Gorno-Tempini ML, Hillis AE, Weintraub S, Kertesz A, Mendez M, Cappa SF, et al. Classification of primary progressive aphasia and its variants. *Neurology* 2011; 76: 1006–14.
- Grossman M, Ash S. Primary progressive aphasia: a review. *Neurocase* 2004; 10: 3–18.
- Habert MO, Horn JF, Sarazin M, Lotterie JA, Puel M, Onen F, et al. Brain perfusion SPECT with an automated quantitative tool can identify prodromal Alzheimer's disease among patients with mild cognitive impairment. *Neurobiol Aging* 2011; 32: 15–23.
- Hu WT, McMillan C, Libon D, Leight S, Forman M, Lee V-Y, et al. Multimodal predictors for Alzheimer disease in nonfluent primary progressive aphasia. *Neurology* 2010; 75: 595–602.
- Indefrey P, Levelt WJM. The spatial and temporal signatures of word production components. *Cognition* 2004; 92: 101–44.
- Jacobs D, Sano M, Marder K, Bell K, Bylsma F, Lafleche G, et al. Age at onset of Alzheimer's disease: relation to pattern of cognitive dysfunction and rate of decline. *Neurology* 1994; 44: 1215–20.
- Jonides J, Schumacher EH, Smith EE, Koeppel RA, Awh E, Reuter-Lorenz PA, et al. The role of parietal cortex in verbal working memory. *J Neurosci* 1998; 18: 5026–34.
- Josephs KA, Duffy JR, Fossett TR, Strand EA, Claassen DO, Whitwell JL, et al. Fluorodeoxyglucose F18 positron emission tomography in progressive apraxia of speech and primary progressive aphasia variants. *Arch Neurol* 2010; 67: 596–605.
- Josephs KA, Duffy JR, Strand EA, Machulda MM, Senjem ML, Master AV, et al. Characterizing a neurodegenerative syndrome: primary progressive apraxia of speech. *Brain* 2012; 135: 1522–36.
- Kas A, de Souza LC, Samri D, Bartolomeo P, Lacomblez L, Kalafat M, et al. Neural correlates of cognitive impairment in posterior cortical atrophy. *Brain* 2011; 134: 1464–78.
- Kas A, Uspenskaya O, Lamari F, de Souza LC, Habert MO, Dubois D, et al. Distinct brain perfusion pattern associated with CSF biomarkers profile in primary progressive aphasia. *J Neurol Neurosurg Psychiatry* 2012; 83: 695–8.
- Knopman DS, Roberts RO. Estimating the number of persons with frontotemporal lobar degeneration in the US population. *J Mol Neurosci* 2011; 45: 330–5.
- Kotz SA, Cappa SF, von Cramon DY, Friederici AD. Modulation of the lexical-semantic network by auditory semantic priming: an event-related functional MRI study. *Neuroimage* 2002; 17: 1761–72.
- Leyton CE, Hsieh S, Mioshi E, Hodges JR. Cognitive decline in logopenic aphasia: more than losing words. *Neurology* 2013; 80: 897–903.
- Leyton CE, Villemagne VL, Savage S, Pike KE, Ballard KJ, Piguet O, et al. Subtypes of progressive aphasia: application of the International Consensus Criteria and validation using  $\beta$ -amyloid imaging. *Brain* 2011; 134: 3030–43.
- Mahieux-Laurent F, Fabre C, Galbrun E, Dubrulle A, Moroni C. Validation d'une batterie brève d'évaluation des praxies gestuelles pour consultation Mémoire. Evaluation chez 419 témoins, 127 patients atteints de troubles cognitifs légers et 320 patients atteints d'une démence. *Rev Neurol* 2009; 165: 560–7.
- Mahoney CJ, Malone IB, Ridgway GR, Buckley AH, Downey LE, Golden HL, et al. White matter tract signatures of the progressive aphasias. *Neurobiol Aging* 2013; 34: 1687–99.
- Mattis S. Mental status examination for organic mental syndrome in elderly patients. In: Bellak L, Karasu TB, editors. *Geriatric psychiatry*. New York: Grune & Stratton; 1976. p. 77–121.
- Mazaux JM, Orgogozo JM. Boston diagnostic aphasia examination. Adaptation française. Editions ECPA; 1982 (Harold Goodglass and Edith Kaplan—Publisher: The Psychological Corporation, Paris).
- McMonagle P, Deering F, Berliner Y, Kertesz A. The cognitive profile of posterior cortical atrophy. *Neurology* 2006; 66: 331–8.
- Mesulam MM. Primary progressive aphasia. *Ann Neurol* 2001; 49: 425–32.
- Mesulam MM, Wicklund A, Johnson N, Rogalski E, Léger GC, Rademaker A, et al. Alzheimer and frontotemporal pathology in subsets of primary progressive aphasia. *Ann Neurol* 2008; 63: 709–19.
- Metter EJ, Riege WH, Hanson WR, Jackson CA, Kempler D, van Lancker D. Subcortical structures in aphasia. An analysis based on (F-18)-fluorodeoxyglucose, positron emission tomography, and computed tomography. *Arch Neurol* 1988; 45: 1229–34.

- Migliaccio R, Agosta F, Possin KL, Rabinovici GD, Miller BL, Gorno-Tempini ML. White matter atrophy in Alzheimer's disease variants. *Alzheimers Dement* 2012; 8: 578–87.
- Migliaccio R, Agosta F, Rascovsky K, Karydas A, Bonasera S, Rabinovici GD, et al. Clinical syndromes associated with posterior atrophy: early age of onset AD spectrum. *Neurology* 2009; 73: 1571–8.
- Neary D, Snowden JS, Gustafson L, Passant U, Stuss D, Black S, et al. Frontotemporal lobar degeneration A consensus on clinical diagnostic criteria. *Neurology* 1998; 51: 1546–54.
- New B, Pallier C, Brysbaert M, Ferrand L. Lexique 2: a new French lexical database. *Behav Res Methods Instrum Comput* 2004; 36: 516–24.
- Pallier C, Devauchelle AD, Dehaene S. Cortical representation of the constituent structure of sentences. *Proc Natl Acad Sci USA* 2011; 108: 2522–7.
- Papoutsis M, de Zwart JA, Jansma JM, Pickering MJ, Bednar JA, Horwitz B. From phonemes to articulatory codes: an fMRI study of the role of Broca's area in speech production. *Cereb Cortex* 2009; 19: 2156–65.
- Patterson K, Nestor PJ, Rogers TT. Where do you know what you know? The representation of semantic knowledge in the human brain. *Nat Rev Neurosci* 2007; 8: 976–87.
- Paulesu E, Frith CD, Frackowiak RS. The neural correlates of the verbal component of working memory. *Nature* 1993; 362: 342–5.
- Rabinovici GD, Jagust WJ, Furst AJ, Ogar JM, Racine CA, Mormino EC, et al. A $\beta$  amyloid and glucose metabolism in three variants of primary progressive aphasia. *Ann Neurol* 2008; 64: 388–401.
- Ratnavalli E, Brayne C, Dawson K, Hodges JR. The prevalence of frontotemporal dementia. *Neurology* 2002; 58: 1615–21.
- Ridgway GR, Lehmann M, Barnes J, Rohrer JD, Warren JD, Crutch SJ, et al. Early-onset Alzheimer disease clinical variants: multivariate analyses of cortical thickness. *Neurology* 2012; 79: 80–4.
- Rilling JK, Glasser MF, Preuss TM, Ma X, Zhao T, Hu X, et al. The evolution of the arcuate fasciculus revealed with comparative DTI. *Nat Neurosci* 2008; 11: 426–8.
- Rogaeva E. The solved and unsolved mysteries of the genetics of early-onset Alzheimer's disease. *Neuromolecular Med* 2002; 2: 1–10.
- Rohrer JD, Crutch SJ, Warrington EK, Warren JD. Progranulin-associated primary progressive aphasia: a distinct phenotype? *Neuropsychologia* 2010a; 48: 288–297.
- Rohrer JD, Ridgway GR, Crutch SJ, Hailstone J, Goll JC, Clarkson MJ, et al. Progressive logopenic/phonological aphasia: erosion of the language network. *Neuroimage* 2010b; 49: 984–93.
- Rohrer JD, Rossor MN, Warren JD. Alzheimer's pathology in primary progressive aphasia. *Neurobiol Aging* 2012; 33: 744–52.
- Sajjadi SA, Patterson K, Arnold RJ, Watson PC, Nestor PJ. Primary progressive aphasia: a tale of two syndromes and the rest. *Neurology* 2012; 78: 1670–7.
- Sonty SP, Mesulam MM, Thompson CK, Johnson NA, Weintraub S, Parrish TB, et al. Primary progressive aphasia: PPA and the language network. *Ann Neurol* 2003; 53: 35–49.
- Spitsyna G, Warren JE, Scott SK, Turkheimer FE, Wise RJ. Converging language streams in the human temporal lobe. *J Neurosci* 2006; 26: 7328–36.
- Teichmann M, Migliaccio R, Kas A, Dubois B. Logopenic progressive aphasia beyond Alzheimer's – an evolution towards dementia with Lewy bodies. *J Neurol Neurosurg Psychiatry* 2013; 84: 113–4.
- Tyler LK, Marslen-Wilson WD, Stamatakis EA. Differentiating lexical form, meaning, and structure in the neural language system. *Proc Natl Acad Sci USA* 2005; 102: 8375–80.
- Warren JD, Fletcher PD, Golden HL. The paradox of syndromic diversity in Alzheimer disease. *Nat Rev Neurol* 2012; 8: 451–64.
- Wechsler D. Wechsler adult intelligence scale-revised manual. New York: Psychological Corporation; 1981.