

# Decomposition patterns of buried remains at different intervals in the Central Highveld region of South Africa

A Marais-Werner<sup>1,\*</sup>, J Myburgh<sup>2</sup>, A Meyer<sup>2</sup>, WC Nienaber<sup>2</sup> and M Steyn<sup>3</sup>

<sup>1</sup>School of Health Care Sciences, Faculty of Health Sciences, University of Pretoria, South Africa

<sup>2</sup>Forensic Anthropology Research Centre, Department of Anatomy, School of Medicine, Faculty of Health Sciences, University of Pretoria, South Africa

<sup>3</sup>School of Anatomical Sciences, University of the Witwatersrand, Johannesburg, South Africa

\*Corresponding author: A Marais-Werner, School of Health Care Sciences, University of Pretoria, Private Bag x 323, Arcadia, 0007, South Africa. Email: natssutherland@gmail.com

## Abstract

Burial of remains is an important factor when one attempts to establish the post-mortem interval as it reduces, and in extreme cases, excludes oviposition by *Diptera* species. This in turn leads to modification of the decomposition process. The aim of this study was to record decomposition patterns of buried remains using a pig model. The pattern of decomposition was evaluated at different intervals and recorded according to existing guidelines. In order to contribute to our knowledge on decomposition in different settings, a quantifiable approach was followed. Results indicated that early stages of decomposition occurred rapidly for buried remains within 7–33 days. Between 14 and 33 days, buried pigs displayed common features associated with the early to middle stages of decomposition, such as discoloration and bloating. From 33 to 90 days advanced decomposition manifested on the remains, and pigs then reached a stage of advanced decomposition where little change was observed in the next ±90–183 days after interment. Throughout this study, total body scores remained higher for surface remains. Overall, buried pigs followed a similar pattern of decomposition to those of surface remains, although at a much slower rate when compared with similar post-mortem intervals in surface remains. In this study, the decomposition patterns and rates of buried remains were mostly influenced by limited insect activity and adipocere formation which reduces the rate of decay in a conducive environment (i.e. burial in soil).

**Keywords:** Forensic anthropology, post-mortem interval, decomposition, total body score, buried remains, decomposition patterns

## Introduction

Burial is a popular choice for assailants who are looking to dispose of human remains. Digging of graves requires time and effort, and the longer the assailants are in contact with the remains the more likely they are to be apprehended with the remains in their possession. Therefore the digging of shallow graves for victims seems to be the obvious choice. Remains that are buried, submerged in water or even placed in the open will look much different from each other, even after the same post-mortem interval (PMI).<sup>1</sup> Buried remains generate a unique environment much different to those of surface remains.

Gennard<sup>2</sup> found that the decomposition pattern in buried remains mainly depended on the season of burial and soil temperature. Soil provides an efficient insulation barrier to solar radiation and restricts access of insects to the body; therefore decomposition in soil occurs at a much slower rate.<sup>3</sup> It has, however, been reported that very shallow graves (supposedly <20 cm) are likely to be affected by fluctuations of temperatures above ground, as loose soil over the remains contains rocks that heat up in high temperatures. In some instances this can lead to fluctuation in temperature.<sup>4</sup> This influence should decrease in deeper burials. Factors such as temperature are deemed important for decomposition, as bacteria need optimal conditions (between 25°C and 35°C) for development which is hindered by lower in-soil temperatures.<sup>3</sup>

Grave soil is known to undergo biochemical changes as the result of movement of fluids, nutrients and microbes. These biochemical changes provide potential in estimating the PMI and in identifying clandestine grave sites. Microbial analyses offer an additional biometric for estimating the PMI.<sup>5</sup> Exposed and buried remains produce different environmental conditions. Wilson et al.<sup>6</sup> confirmed that buried remains modify the faunal environment of the grave during decomposition, contributing to increased microbial load and production of liquid and gaseous by-products of decomposition. Moisture-rich soil is conducive to adipocere formation, while well-drained soil can promote mummification and soil acidity can decrease microbiological activity and decomposition. The nature of soil will therefore influence the rate and pattern of decomposition.<sup>1</sup> Burial, for instance, (depending on the soil texture and depth of remains) may prevent oviposition and development of larvae, thereby slowing down the decomposition process,<sup>7</sup> as access by insects has a very significant effect on the biomass reduction of remains.

Physical changes to remains can be observed in various stages of decomposition. During the fresh stage of decomposition, the body undergoes depletion of internal oxygen<sup>8</sup> (internal, aerobic microorganisms deplete the soft tissue of oxygen), which leads to observable bloating of the body.<sup>9</sup> This results in colour changes, odour formation and bloating of the remains, also known as putrefaction. These changes are observable within 48 hours after death.<sup>8</sup>

Putrefaction begins during the early stage of decomposition (up to 1 week post mortem) with a greenish discoloration on the abdominal area as the anaerobic bacteria in the body begin to digest the tissue. This results in the production of gases and inflation of the abdomen, an enlarged scrotum and protrusion of the eyes and tongue. Internal pressure caused by gases results in the putrefactive fluids purging from the nostrils, ears and mouth, as well as a distinct odour of decomposing flesh.<sup>9-12</sup> Up to 1 month post mortem a change in colour from green to purple to black is observed.

The outer layer of the skin separates from the dermis (skin slippage) and the gases from the abdomen escape as the body deflates, leading to the excretion of urine and faeces.<sup>10</sup> A definite increase in numerous species of insect feeding on the remains is observable, which contributes to rapid mass loss.<sup>9</sup> Mass loss is also largely attributed to the loss of fluids through seepage.<sup>13</sup> By the end of this decomposition stage, *Calliphoridae* (blow flies) and *Sarcophagidae* (flesh flies) would have completed development and left the remains. *Diptera* larvae will have removed most of the flesh, leaving only skin, bone and cartilage.<sup>9</sup>

Advanced decomposition is marked by the progressive drying of the remains (up to 2 months post mortem)<sup>10</sup> and bone exposure particularly on the extremities. Stages vary in length of time and are dependent on factors such as insect abundance and activity, geographic location,

temperature, humidity, rainfall, habitat, season and carcass size.<sup>14,15</sup> Decomposition is largely inhibited during this stage due to the loss of cadaveric material. The putrid odour is absent and a considerable part of the soft tissue is removed, which leads to reduced insect activity on the remains.

Lastly, skeletonisation of remains can develop within months and/or years depending on internal and external factors that may influence the decomposition process. This stage is reached when remaining soft tissue disappears and only bones and hair remain.<sup>9,10,16</sup> The higher the temperature and humidity, the greater the rate of decomposition and skeletonisation.<sup>11,17</sup> Disarticulation is a common phenomenon with skeletonised remains. Even if each bone is in place, a skeleton is considered disarticulated when the soft tissues do not join the bones together.<sup>11</sup>

Decompositional stages follow one another, but no clear distinction can be made between when one stage ends and the other begins due to the variation in time of onset, overlap of changes, environmental factors, and the rate of progression of putrefaction.<sup>3</sup> A number of studies have been conducted on post-mortem changes within different settings;<sup>3,7,9,14,15,18-20</sup> however, none refer to decomposition patterns of buried remains within South Africa.

## Materials and methods

This study was conducted at the Forensic Anthropology Body Farm (FABF) on the Miertjie le Roux Experimental Farm (45 km east of Pretoria) located in the Cullinan District, Gauteng Province and belongs to the Faculty of Natural and Agricultural Sciences of the University of Pretoria. *Sus scrofa*, or domestic pig carcasses, were used in this study as their pattern of decomposition and body size is similar to that of humans.<sup>3,21</sup> In South Africa, pigs serve as acceptable proxies for decomposition studies due to ethical reasons, and also the justice system does not allow for human bodies to be used in research studies other than educational anatomical dissections performed at an approved education institution. Furthermore, difficulty would be expected in obtaining cadavers, identifying suitable areas to conduct these studies and the impact of negative public opinion. Pigs are easier to obtain and entomological studies have shown that they are the most appropriate animal model for decomposition studies.<sup>3,22</sup> It should, however, be kept in mind that decomposition is a complicated process, and differences in anatomy and intestinal bacteria can lead to variations in this process.

Pig carcasses ( $N = 40$ ) were donated from two local farmers for research purposes, and placed within 24 hours after death. Only pigs that died of natural causes and had known dates of death were included in the study. In commercial piggeries, death is commonly caused by *E. coli* (*Escherichia coli*), which is an intestinal infection, and Salmonellosis (*Salmonella choleraesuis*) which leads to respiratory distress. Only 25 pigs are reported in this study as the remaining carcasses showed signs of carnivore activity and/or the graves were waterlogged to such an extent that data could not be retrieved due to heavy rainfall the week prior and during excavation. All pigs in this study had a weight range of between 45 and 80 kg, with an average weight of 64 kg. Pigs were on average 118.12 cm in length (excluding the tail length), 46.08 cm in height, 22.4 cm in width and a belly height of 29.72 cm.

In order to allow for good control over the excavation process, which involved the removal of soil in equal layers to prevent damage, remains were buried and excavated by means of archaeological techniques (shovels, brushes and trowels).<sup>23</sup> Also, in an attempt to maximise

recovery and documentation of decomposing remains, no mechanical equipment was used during excavation.

This cross-sectional study was conducted over a period of 10 months from September 2014 to June 2015. Five pigs were buried at an average depth of 0.75 m and excavated for each predetermined time category (7 days, 14 days, 33 days, 92 days and 183 days). The degree of decomposition for each pig was observed, photographed and recorded using the scoring guidelines presented in Megyesi et al.<sup>24</sup> Point values were assigned to three separate anatomical regions (head and neck, trunk and limbs) in order to quantify the qualitative observation. The assigned point values of each region were then added to determine the total body score (TBS) of each pig from a minimum of three to a maximum of 35 points.

An additional observer recorded the stages of decomposition and the resulting TBS of 10 pigs from randomly chosen time categories. This was performed as a means to determine the repeatability of the method used for scoring the decomposition process.

## Results

The observed TBS scores ranged from 8 (early decomposition) after 7 days of burial to a maximum of 25 (advanced decomposition) excavated after 183 days of burial. Early decomposition (TBS scores above 3) was marked by skin slippage, bloating and discoloration especially on the abdomen. The final stages of early decomposition (TBS scores averaging 16) were characterised by a dark (black) colour. Advanced decomposition (TBS scores of 19+) began with the sagging of the thoracic and abdominal cavities as bodily fluids purged from the natural openings. The purging of fluids led to dehydration of soft tissue, causing the skin to turn leathery. No cases reached advanced decomposition up to the point of skeletonisation (TBS scores of 27+) within the 6 month (183 days) interval of this study. The most advanced decomposition observed within this time frame (TBS of 25) for buried remains was limited to moist decomposition with bone exposure less than one-half of the area being scored.

Table 1 summarises the average TBS for all anatomical regions scored on buried remains. The most prominent change in decomposition was observed during the early stages of decomposition (7–14 days), which slows down considerably after 33 days of burial. When regions are viewed individually, a gradual increase in the rate of decomposition is evident. From Table 1 it can be argued that decomposition progressed more rapidly in the head and neck regions than the rest of the body.

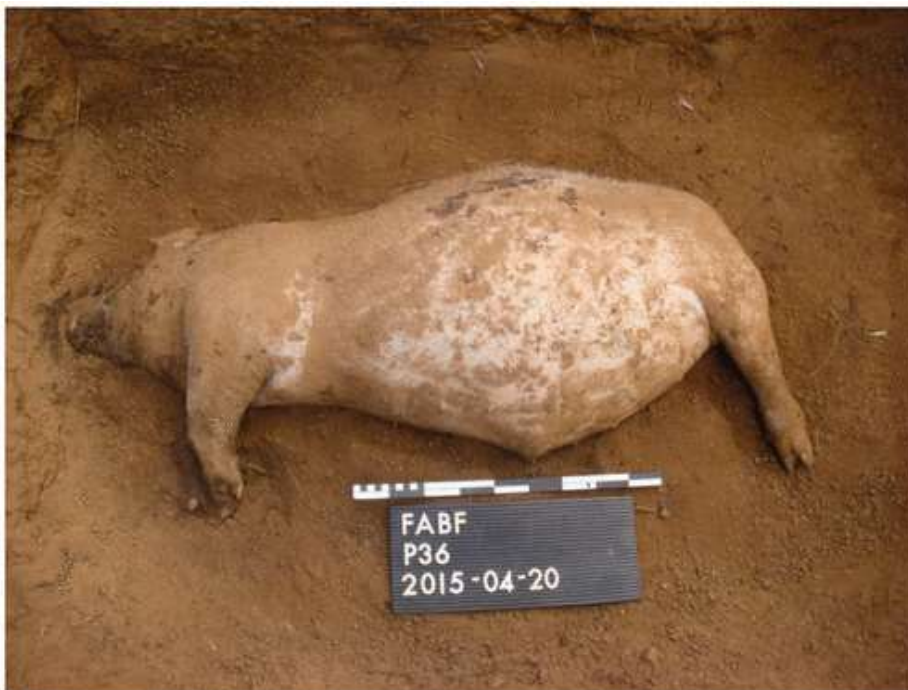**Table 1.** Summary of average TBS scores of all anatomical regions of buried remains.

	PMI 7	PMI 14	PMI 33	PMI 92	PMI 183	Mean	Standard deviation
Head and neck	4.0	5.0	6.8	8.4	9.0	6.6	2.1
Trunk	3.2	5.8	6.0	6.4	7.2	5.7	1.5
Limbs	2.4	2.6	4.6	4.6	6.0	4.0	1.5
TBS	9.6	13.4	17.4	19.4	22.2	16.3	5.1

After a PMI of 7 days pigs exhibited variations in the decomposition process and the TBS scores ranged between 8 and 11, averaging at 9.6. All pigs within this time frame had a mild odour that is associated with the early stages of decomposition.<sup>11,21,25</sup> Three pigs showed a very dark purple and grey discoloration on the lower abdomen and trunk and oily skin (Figure 1), whereas the remaining two pigs in this time frame had a fairly fresh pink skin on the abdomen with little to no discoloration (Figure 2).



**Figure 1.** Pig 33 exhibiting bloating of the abdomen with dark discoloration of the abdomen after 7 days of interment.



**Figure 2.** Pig 36 exhibiting bloating of the abdomen with relatively fresh skin after 7 days of interment.



All 7 day PMI carcasses showed bloating of the trunk and limbs, intact hooves, purging of decomposition fluids from the mouth and anus, protrusion of the eyes, skin slippage and blisters on the abdomen and thorax. The epidermis became fragile and tore easily, resulting in large skinless areas when exhumed. According to Galloway et al.,<sup>26</sup> remains which are in direct contact with soil show very moist decomposition patterns, therefore skin slippage is a common feature in buried remains, as was also observed here. No insect activity was observed in any of the carcasses, although masses of blowflies (Diptera: *Calliphoridae*) colonised the carcasses within minutes after exposure during excavation.

After 14 days post mortem, pigs displayed some common features associated with the early stages of decomposition with narrow TBS scores ranging between 13 and 14, averaging at 13.4. Pigs showed obvious sagging/deflation of the abdomen, a dark pink discoloration especially on the head, decomposition fluids purging out of the natural openings of the carcass and skin slippage on the extremities (Figure 3). A considerable putrid smell was noticeable from all carcasses in this time frame. In addition, all five graves caved in above the trunk area as soon as excavation started on the burial pits. The unstable surfaces for these graves were not evident before excavation started. This secondary depression of the burial pits is caused by the collapse of the abdomen during the decomposition process.



**Figure 3.** After 14 days PMI pigs displayed a deflated abdomen, dark discoloration on the head, purging fluids from the snout and skin slippage.

After a PMI of 33 days, pigs still displayed features described during early decomposition. The TBS scores ranged between 16 and 20, averaging at 17.4. Observations included bloating, skin slippage, detachable hooves, a strong putrid odour and purging of decomposition fluid from natural openings (snout, anus) and a greasy whitish texture (adipocere formation) on the abdomen with a black soil-skin interface (Figure 4).



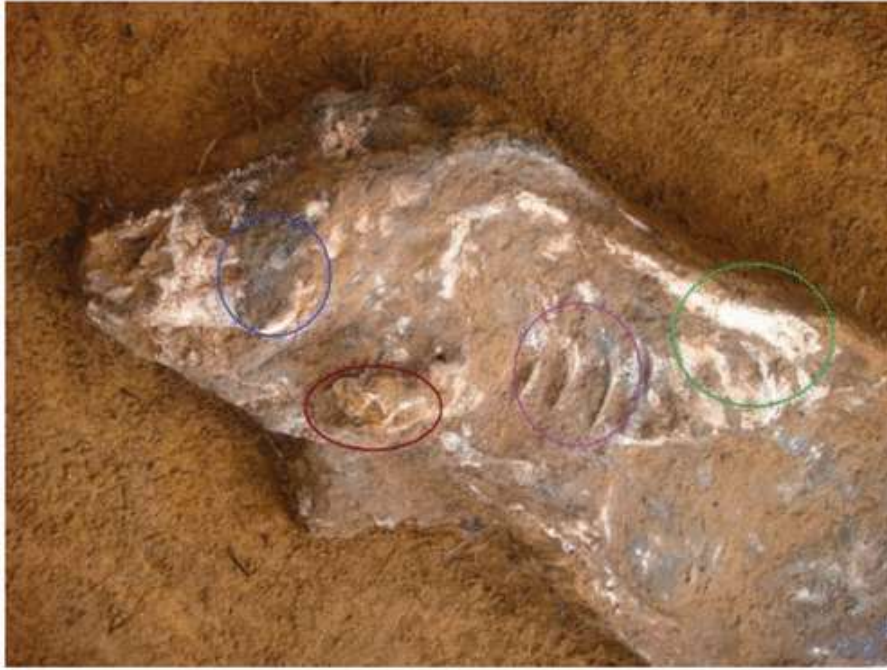**Figure 4.** Bloating of the abdomen (a), adipocere formation, black soil-skin interface on the head, purging of decompositional fluid (b) and detached hooves (c) after 33 days of interment.

After 92 days post mortem, pigs showed black skin–soil interface on the majority of the remains. Only two pigs displayed pink and black patches on the extremities and head. All remains within this time frame exhibited a mild ammonium smell, partial skeletonisation of the head, adipocere formation, collapse/flattening of the trunk, disarticulated hooves and very leathery skin (especially on the vertebrae) (Figure 5). TBS ranged between 19 and 21, (averaging 20.4) indicating a narrow range when comparing TBS after 33 days of interment.



**Figure 5.** Collapsed abdomen (a), partial skeletonisation of the head (b), adipocere formation on the back extremity and leathery skin (c).

After 183 days post mortem, pigs had TBS scores ranging between 21 and 25, averaging at 22.2, displaying features described in advanced decomposition (Figure 6) with black skin–soil interface, collapsed abdomen, skeletonised heads with some areas of leathery skin and hair still present with disarticulated limbs and hooves. Leathery skin patches resulted in the protection of the underlying tissue, leading to the retention of some moisture. Greasy skin and adipocere formation were visible on all remaining flesh in this time frame. A very strong putrid smell (ammonia) was distinct for all carcasses.



**Figure 6.** Pig 4 showing the black skin–soil interface and desiccated tissue on the skull (blue), a disarticulated front limb (brown), visible rib cage (purple) and adipocere/grease formation on the spine (green).

## Discussion

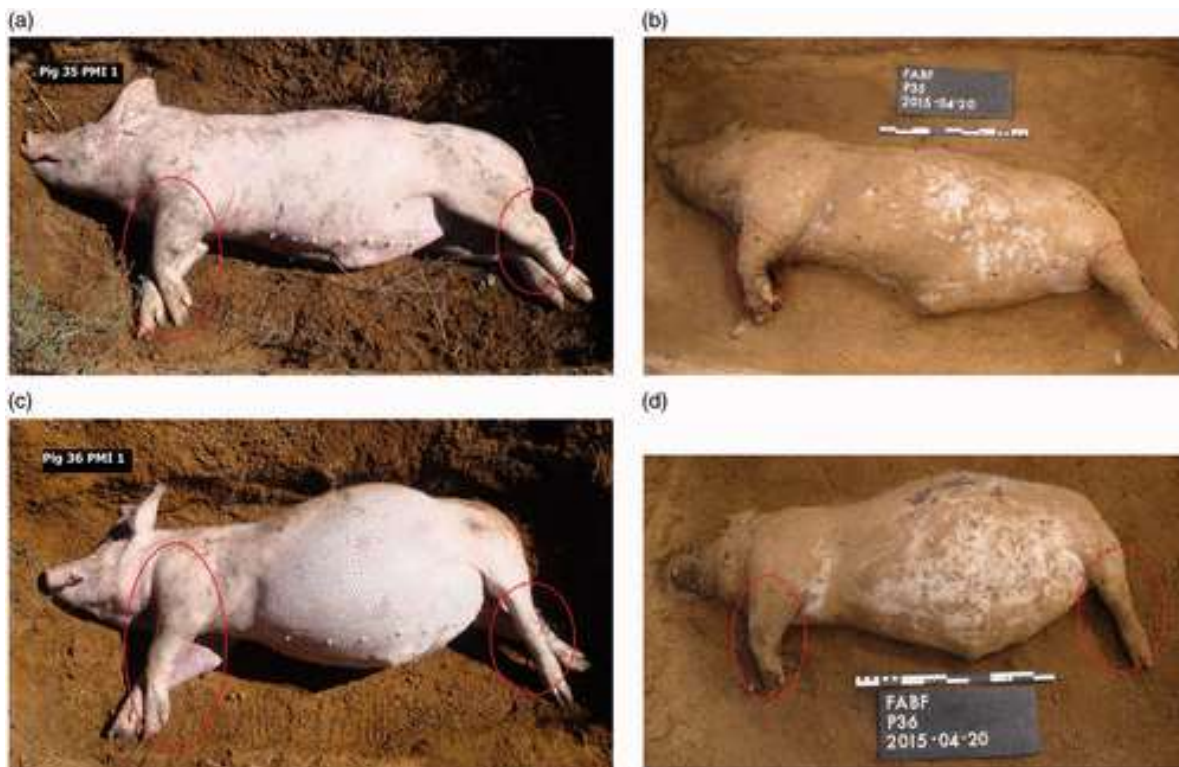
Buried remains followed decomposition patterns where minimal putrefaction is observed during the fresh phase (no discoloration), followed by bloating, discoloration of some regions, blisters and purging of fluids. Literature reports on a distinct foul smell, observable maggot masses, skeletonised head, expulsion of liquids from the mouth, collapse of the abdomen and spilling of intestines after 13 days of death.<sup>11,21,25,27</sup> The current study observed that the flesh on the head was still relatively fresh at between 7 and 14 days after burial. Remains bloated, a mild odour was present, no observable insect activities were noted on the remains and the epidermis became fragile. As decomposition progressed (between 14 and 33 days of interment) the remains displayed a great loss of mass as a result of purging of decompositional fluids, and the odour became very distinct. Between 33 and 92 days of interment, a black skin–soil interface was observed together with adipocere formation. When advanced decomposition manifested on the remains (between 92 and 183 days of interment), the skin became leathery, the flesh caved in and bone exposure was visible especially on the head, ribs and vertebrae.

From the TBS scores of the anatomical regions it can be argued that decomposition progressed more rapidly in the head and neck regions than the rest of the body. As cells become deprived of oxygen soon after death and the acidity increases due to the toxic by-products of chemical reactions, enzymes start to digest cell membranes and leak out as the cells break down. This usually begins in the brain, which has a high water content.<sup>28</sup> Following rigor mortis and the predictable pattern known as Nystens' Law, rigor first appears in the small muscles of the face, and then spreads to the neck, trunk, upper limbs and lower limbs.<sup>10</sup> Also, due to the small amount of fat and biomass on the head and ample bacteria in the mouth, it is possible that decomposition could progress faster in the head and neck regions.<sup>28</sup> As is expected, decomposition is slowest in the limbs. Buried remains displayed much less variance in the decomposition process when compared with surface remains as the



circumstances surrounding burial are more homogenous. Decomposition of buried remains slowed down gradually up to the stage where decomposition reached what seemed to be a plateau phase where little change was noted after 33 days PMI. A similar plateau phase indicating little change during advanced decomposition was also observed in the studies by Myburgh et al.<sup>14</sup> and Sutherland et al.<sup>15</sup> This suggests a consistent environment for decomposition when buried, resulting in a plateau phase where very little change in the decomposition pattern takes place. Although temperature fluctuations occur in the soil, the temperature changes are not as large when compared with remains decomposing on the surface. It therefore seems that this plateau phase presents itself regardless of size and whether remains were decomposing in soil or on the surface. This emphasises the importance of the effects of temperature (for surface remains) and time (for buried remains) on the decomposition process.

With a multitude of factors affecting decomposition, it can be assumed that variation in the pattern and rate of decomposition exist. Megyesi et al.<sup>24</sup> state that limbs do not bloat. However, bloating of the limbs was observed during early decomposition, more specifically on the 7 day PMI pigs. Two pigs showed distinct bloating of the limbs especially around the joint areas of the extremities (Figure 7).



**Figure 7.** Pigs 35 and 36 showing bloating of limbs after 7 days of interment (encircled in red).

For the 14 day PMI category, it was mentioned earlier that all five graves caved in as soon as excavation started on the burial pits. This secondary depression for these graves was not evident before excavation started. It can therefore be assumed that secondary depressions may not necessarily only be visible over time when the trunk collapses completely. Movement in or above the area of the burial pit resulting in surface pressure may cause collapse of the burial pit much sooner than anticipated.

The soil in the research area for this study was identified as a clay soil. Bodies buried in clay soil show slower decomposition rates and higher retention of organic matter in comparison with sandy soil.<sup>29</sup> Compactness of soil would most probably inhibit gaseous diffusion and moisture availability, resulting in limited microbial activity, which prolongs decomposition.<sup>8,30,31</sup> This could explain the longer preservation of the remains for the latter two pigs in the 7 day PMI category. Clay soil has the ability to entrap decomposition fluids around the remains, which aids in adipocere formation.<sup>32</sup> Adipocere was first noticed when buried remains were excavated after 33 days PMI. Adipocere also presented itself on both 92 and 183 day PMI carcasses. In total, 15 out of the 25 buried pigs showed signs of adipocere formation. Adipocere commonly develops in the subcutaneous tissues, and its importance is in the preservation of remains, aiding in identification and recognition of injuries.<sup>33</sup> The presence of adipocere during this project is attributed to the fact that heavy rainfall was experienced at the research site during Spring and Summer (November to February). Also, the natural water table was very shallow at certain areas within the site, retaining moisture, which aids in the formation of adipocere.<sup>11</sup> The absence of insects and/or minimal insect activity may also have played a role in increased adipocere formation. Due to minimal insect activity, carcasses retained a large amount of soft, moist tissue, and since the temperature of carcasses did not increase (due to the lack of insect activity and the fact that they were buried), the environment was more favourable for the formation of adipocere.<sup>34</sup>

According to Caspers' Rule, 1 week of decomposition is equivalent to 8 weeks buried in soil, given the environmental temperatures are similar.<sup>35</sup> Temperature is one of the most important taphonomic factors contributing to degradation or preservation of buried remains.<sup>7,36</sup> Putrefaction is limited at temperatures below 10°C as the optimum temperature for soft tissue degradation is between 20°C and 40°C.<sup>33,36</sup> Temperature data show that soil provides an efficient insulation from solar radiation, resulting in a reduced rate of decomposition. Rodriguez and Bass<sup>37</sup> states that thermal stabilisation normally occurs at 0.60 m of depth, while at depths of 0.30 m and or less, the in-soil temperature is very similar to the ambient temperature. According to Troutman et al.,<sup>1</sup> the delay in decomposition is mostly ascribed to the lower in-soil temperature and accessibility by insects of the remains. As the burial pits were dug to an average of 0.75 m, remains may have been insulated from temperature fluctuations, therefore the rate of decomposition were less variable than remains on the surface. Keep in mind that in the Central Highveld region we seldom, if ever, experience temperatures below 0°C, therefore decomposition should still progress at a faster rate than remains decomposing in countries where temperatures drop below 0°C.

## **Conclusion**

The standard use of quantitative variables such as TBS facilitates the comparison of data regardless of environmental factors. Variables such as insect activity and temperature are related to aspects of decomposition. While insects are considered the most significant environmental decomposer,<sup>38</sup> temperature is considered the most important variable.<sup>7</sup> Buried remains in this study were protected from these elements by limited insect access and lower in-soil temperatures due to their burial depth. In addition, soil characteristics (clay soil) and moisture content surrounding the remains played a role in decreasing the rate of decomposition of buried remains.

As the burial pits were dug to an average of 0.75 m, temperature fluctuations were suggested not to play a major role on the buried remains. Also, with increased burial depth, soil displayed higher moisture content due to reduced evaporation and the closer proximity to

natural underground water tables. The soil (clay) found at the FABF exhibits poor drainage (retains moisture) and would be more likely to assist in the formation of adipocere,<sup>39</sup> which has been reported to preserve remains.<sup>11</sup> This has been the case during this study. The delay in the onset of dry decomposition can be ascribed to the amount of soft tissue still present on the remains, as the majority of skin and hair remained on the carcasses and moisture loss was particularly slow.

It is generally agreed that variables may alter decomposition differently between remains exposed to similar conditions. This was also observed within this study, more specifically on the 7 day PMI pigs. Two of the five pigs showed little to no discoloration, whereas the remaining three pigs showed dark purple discoloration in the abdomen. Even within a small catchment area, underlying geology and soil structure can alter decomposition patterns of buried remains (i.e. differences in discoloration rates of remains). In this case the difference in appearance is likely due to oxygen available to the carcass once buried. Compact soil (i.e. clay) could inhibit gaseous diffusion and moisture availability, resulting in limited microbial activity, which prolongs decomposition.<sup>8,30-31</sup> This could explain the longer preservation of the remains for these two pigs in this particular time frame. This emphasises the importance of taking both extrinsic (i.e. insect activity) and intrinsic (i.e. constitution of the body) factors into account when interpreting the environment at the death scene to aid in PMI estimations.

Overall, buried and surface pigs decompose with similar patterns, but buried pigs decompose at a much slower rate, reaching lower TBS values relative to similar PMIs in surface remains. This suggests that burial does have a significant effect on the rate of decomposition. Results from this study suggest that when using TBS guidelines on buried remains in the Central Highveld region of South Africa, buried remains will have, on average, a lower TBS score (7.4) than surface remains within a similar PMI.

## **Acknowledgements**

The help and assistance of the staff from the Faculty of Natural and Agricultural Sciences, staff and students from the Department of Anatomy and students in the Department of Archaeology is gratefully acknowledged. Thank you to the farmers for donating the pigs used in this study, and the South African Weather Services who supplied temperature and rainfall data for the duration of the study.

## **Funding**

This research was funded by the University of Pretoria and the National Research Foundation (NRF) of South Africa (through M Steyn). Any opinions, findings and conclusions expressed in the article are those of the authors and therefore the University and NRF do not accept any liability in regard thereto.

## **References**

1. Troutman, L, Moffat, C, Simmons, T. A preliminary examination of differential decomposition patterns in mass graves. *J Forensic Sci* 2014; 59(3): 621–626.
2. Gennard D. *Forensic entomology: An introduction*. Hoboken, NJ, USA: Wiley-Blackwell, 2012; pp.35–36.
3. Campobasso, CP, Di Vella, G, Introna, F. Factors affecting decomposition and Diptera

- colonization. *Forensic Sci Int* 2001; 120: 18–27.
- Sorg MH, Haglund WD and Wren JA. Current research in forensic taphonomy. In: *A companion to forensic anthropology*. 1<sup>st</sup> Edition. Dirkmaat DC: Blackwell Publishing Ltd, 2012, pp.477–525.
4. Finley, SJ, Benbow, ME, Javan, GT. Microbial communities associated with human decomposition and their potential use as postmortem clocks. *Int J Legal Med* 2014, pp. 1–10.
  5. Wilson, AS, Janaway, RC, Holland, AD. Modelling the buried human body environment in upland climes using three contrasting field sites. *Forensic Sci Int* 2007; 169: 6–18. .
  6. Mann, RW, Bass, WM, Meadows, L. Time since death and decomposition of the human body: Variables and observations in case and experimental field studies. *J Forensic Sci* 1990; 35(1): 103–111.
  7. Carter, DO, Yellowlees, D, Tibbett, M. Cadaver decomposition in terrestrial ecosystems. *Naturwissenschaften* 2007; 94: 12–24.
  8. Goff, ML. Early post-mortem changes and stages of decomposition in exposed cadavers. *Exp Appl Acarol* 2009; 49: 21–36.
  9. Tracqui, A Time since death. In: Siegel, J, Saukko, PJ, Knupfer, GC (eds). *Encyclopaedia of Forensic Sciences*, London: Academic Press, 2000, pp. 1357–1363.
  10. Pinheiro, J Decomposition process of a cadaver. In: Schmitt, A, Cunha, E, Pinheiro, J (eds). *Forensic Anthropology and Medicine: Complementary sciences from recovery to cause of death*, New Jersey: Humana Press, 2006, pp. 85–116.
  11. Bristow, J, Simms, Z, Randolph-Quinney, P Taphonomy. In: Black, S, Ferguson, E (eds). *Forensic Anthropology 2000 to 2010*, Taylor and Francis Group: CRC Press, 2011, pp. 279–317.
  12. Catts, EP. Problems in estimating the postmortem interval in death investigations. *J Agric Entomol* 1992; 9(4): 245–255.
  13. Myburgh, J, L'Abbé, EN, Steyn, M. Estimating the postmortem interval (PMI) using accumulated degree-days (ADD) in a temperate region of South Africa. *Forensic Sci Int* 2013; 229: 165e1–165e6.
  14. Sutherland A (now Marais-Werner), Myburgh J, Steyn M, et al. The effect of body size on the rate of decomposition in a temperate region of South Africa. *Forensic Sci Int* 2013; 231: 257–262.
  15. Vass, AA. Dust to dust. The brief, eventful afterlife of a human corpse. *Scientific America* 2010; 303: 56–59.
  16. Clark, MA, Worrell, MB, Pless, JE Postmortem changes in soft tissue. In: Haglund, WD, Sorg, MH (eds). *Forensic taphonomy: The post mortem fate of human remains*, Boca Raton: CRC Press, 1997, pp. 151–164.
  17. Dix, J, Graham, M. *Time of death, decomposition and identification: An atlas*, Boca Raton: CRC Press, 2000, pp. 10–12.
  18. Vass, AA. Beyond the grave – understanding human decomposition. *Microbiol Today* 2001; 28: 190–192.
  19. Adlam, RE, Simmons, T. The effect of repeated physical disturbance on soft tissue decomposition – are taphonomic studies an accurate reflection of decomposition? *J Forensic Sci* 2007; 52(5): 1007–1014.
  20. Schoenly, KG, Haskell, NH, Mills, DK. Recreating death's acre in the school yard: Using pig carcasses as model corpses to teach concepts of forensic entomology & ecological

- succession. *Am Biol Teach* 2006; 68(7): 402–410.
22. Schultz, JJ, Collins, ME, Falsetti, AB. Sequential monitoring of burials containing large pig cadavers using ground-penetrating radar. *J Forensic Sci* 2006; 51(3): 607–616.
  23. Joukowsky, M. *A complete manual of field archaeology. Tools and techniques of field work for archaeologists*, Englewood Cliffs, USA: Prentice-Hall, 1980.
  24. Megyesi, MS, Nawrocki, SP, Haskell, NH. Using accumulated degree-days to estimate the post-mortem interval from decomposing human remains. *J Forensic Sci* 2005; 50(3): 618–626.
  25. Parsons HR. *The postmortem interval: A systematic study of pig decomposition in West Central Montana*. MSc Thesis, University of Montana, Montana, 2009.
  26. Galloway, A, Birkby, WH, Jones, AM. Decay rates of human remains in an arid environment. *J Forensic Sci* 1989; 34(3): 607–616.
  27. Niederegger, S, Schermer, J, Höfig, J. Case report: Time of death estimation of a buried body by modeling a decomposition matrix for a pig carcass. *Legal Med* 2015; 17: 34–38.
  28. Costandi M. Life after death: The science of human decomposition. *Forensic Science: Neurophilosophy* 2015; <http://www.theguardian.com/science/neurophilosophy/2015/may/05/life-after-death>.
  29. Van Veen, JA, Kuikman, PJ. Soil structural aspects of decomposition of organic matter by micro-organisms. *Biogeochemistry* 1990; 11: 213–233.
  30. Vass, AA, Bass, WM, Wolt, J. Time since death determinations of human cadavers using soil solutions. *Forensic Sci* 1992; 37: 1236–1253.
  31. Carter, DO, Yellowlees, D, Tibbett, M. Moisture can be the dominant environmental parameter governing cadaver decomposition in soil. *Forensic Sci Int* 2010; 200: 60–66.
  32. Hau, TC, Hamzah, NH, Lian, HH. Decomposition process and post mortem changes: Review. *Sains Malaysiana* 2014; 43(12): 1873–1882.
  33. Pounder, DJ Postmortem interval. In: Siegel, J, Saukko, PJ, Knupfer, GC (eds). *Encyclopaedia of Forensic Sciences*, London: Academic Press, 2000, pp. 1167–1172.
  34. Brown, C, Peckmann, T. Decomposition rates and taphonic changes associated with the estimation of time since death in a summer climate: A case study from Urban Nova Scotia. *Can Soc Forensic Sci J* 2013; 46(4): 209–230.
  35. Anand A. Signs of death and changes following death. In: *Forensic Medicine and Toxicology for MBBS. 1st Edition*. Avichal Publishing Company, 2016, Chapter 9.
  36. Prangnell, J, McGowan, G. Soil temperature calculation for burial site analysis. *Forensic Sci Int* 2009; 191: 104–109.
  37. Rodriguez, WC, Bass, WM. Decomposition of buried bodies and methods that may aid in their location. *J Forensic Sci* 1985; 30(3): 836–852.
  38. Simmons, T, Cross, PA, Adlam, RE. The influence of insects on decomposition rate in buried and surface remains. *J Forensic Sci* 2010; 55(4): 889–892.
  39. Schotsmans, EMJ, van de Voorde, W, de Winne, J. The impact of shallow burial on differential decomposition to the body: A temperate case study. *Forensic Sci Int* 2011; 206: e43–e48.