

## Dengue: a new challenge for neurology

Marzia Puccioni-Sohler,<sup>1</sup> Marco Orsini,<sup>2</sup> Cristiane N. Soares<sup>3</sup>

<sup>1</sup>*Serviço Patologia Clínica, Hospital Universitário Clementino Fraga Filho/Universidade Federal do Rio de Janeiro (HUCFF/UFRJ); Unidade de Neuroinfecção, Hospital Universitário Gaffree e Guinle/Universidade Federal do Estado do Rio de Janeiro (HUGG/UNIRIO) and Neurolife Laboratory, Rio de Janeiro;*

<sup>2</sup>*Secretaria de Saúde de Nova Iguaçu, Hospital Geral de Nova Iguaçu HGN, Rio de Janeiro;*

<sup>3</sup>*Serviço de Neurologia, Hospital dos Servidores do Estado and Hospital Quinta D'Or, Rio de Janeiro, Brazil*

### Abstract

Dengue infection is a leading cause of illness and death in tropical and subtropical regions of the world. Forty percent of the world's population currently lives in these areas. The clinical picture resulting from dengue infection can range from relatively minor to catastrophic hemorrhagic fever. Recently, reports have increased of neurological manifestations. Neuropathogenesis seems to be related to direct nervous system viral invasion, autoimmune reaction, metabolic and hemorrhagic disturbance. Neurological manifestations include encephalitis, encephalopathy, meningitis, Guillain-Barré syndrome, myelitis, acute disseminated encephalomyelitis, polyneuropathy, mononeuropathy, and cerebromeningeal hemorrhage. The development of neurological symptoms in patients with positive Immunoglobulin M (IgM) dengue serology suggests a means of diagnosing the neurological complications associated with dengue. Viral antigens, specific IgM antibodies, and the intrathecal synthesis of dengue antibodies have been successfully detected in cerebrospinal fluid. However, despite diagnostic advancements, the treatment of neurological dengue is problematic. The launch of a dengue vaccine is expected to be beneficial.

### Introduction

Dengue is an RNA virus that is grouped into four serotypes (DENV-1 through DENV-4) belonging to the genus *Flavivirus* (family

Flaviviridae).<sup>1</sup> Dengue infection represents the most destructive arboviral disease for humans. The number of countries reporting outbreaks has increased 10-fold in the last 30 years and includes more than 100 countries in the Pacific-Asian region, the Americas, the Middle East, and Africa.<sup>2</sup> Approximately 50-100 million infections occur each year resulting in approximately 25,000 deaths.<sup>3-6</sup> The mosquitoes *Aedes aegypti* and *Aedes albopictus* are the vectors that deliver the virus to humans.<sup>4</sup> The disease has become more common in high-income countries as a result of vector dissemination and increased travel. Dengue represents the second leading cause of acute fever in travellers.<sup>5</sup>

The clinical spectrum of the disease ranges from dengue hemorrhagic fever (DHF) and dengue shock syndrome to mild dengue fever to even oligosymptomatic or asymptomatic infection.<sup>6</sup> Because dengue infection can be asymptomatic, the actual number of cases of dengue infection has been underestimated. Recently, neurological manifestations have been increasingly described in oligosymptomatic dengue, making it challenging to correlate neurological symptoms to the infection.<sup>6</sup> The incidence of infection associated to neurological manifestations ranges from 1% to 5%.<sup>7,8</sup> Therefore, new guidelines for the diagnosis of neurological dengue are required, especially for clinicians who are unfamiliar with its wide array of clinical presentations. The most common neurological presentations are encephalitis and encephalopathy, although every year cases of meningitis, Guillain-Barré syndrome (GBS), myelitis, acute disseminated encephalomyelitis, myositis, and neuropathy have been reported.<sup>6-8</sup>

In this review, we analyze neurological complications related to dengue infection, focusing on new concepts regarding the association of central and peripheral nervous system involvement and dengue infection that have recently emerged. Mild cases of dengue encephalitis with normal cerebrospinal fluid (CSF), patients with GBS without any signs or symptoms of the preceding infection, the intrathecal synthesis of specific antibodies, and new laboratory techniques are several of the new findings related to neurological dengue that are discussed in this review.<sup>9-11</sup>

### Neuropathogenesis

The mechanisms of neuropathogenesis following dengue infection seem to be related to the specific type of neurological disease (Table 1). Viral and host factors have an important role in the disease pathogenesis.

Correspondence: Marzia Puccioni-Sohler, Praia do Flamengo 66B- sl.319-320 - Flamengo, RJ/RJ, Brazil.

Tel./Fax: +55.21.25574731.

E-mail: mpuccioni@hucff.ufrj.br

Key words: dengue, neurological manifestations, treatment.

Acknowledgements: the authors would thank Fundação á Pesquisa do Rio de Janeiro/ Sistema Único de Saúde (FAPERJ/SUS), a government agency that supports the researchs in Rio de Janeiro state.

Conflict of interests: the authors report no conflict of interests.

Received for publication: 21 December 2011.

Revision received: 2 April 2012.

Accepted for publication: 29 June 2012.

This work is licensed under a Creative Commons Attribution NonCommercial 3.0 License (CC BY-NC 3.0).

©Copyright M. Puccioni-Sohler et al., 2012  
Licensee PAGEPress, Italy  
*Neurology International* 2012; 4:e15  
doi:10.4081/ni.2012.e15

### Metabolic disturbance causing encephalopathy

Several factors secondary to the infection, such as cerebral anoxia, shock, edema and/or toxicity, caused by liver failure, thrombocytopenia leading to hemorrhages, and electrolyte dysfunction are determinants of dengue encephalopathy and not of encephalitis. It is crucial to differentiate both conditions that usually occur during DHF and dengue shock syndrome.<sup>12</sup> Secondary to thrombocytopenia and dengue-associated coagulopathy and vasculopathy, an ischemic stroke could be triggered.<sup>13,14</sup> Pathological studies in fatal cases revealed non-specific lesions, edema, vascular congestion, and focal hemorrhages.<sup>15</sup>

### Direct central nervous system viral invasion

Dengue virus was detected in CSF as early as 1996, as was the presence of viral antigens in the central nervous system (CNS).<sup>16,17</sup> DENV-2 and DENV-3 serotypes are most frequently associated with neurological complications.<sup>16,18</sup> Immunoreactivity to DENV-4 has also been detected in neurons, microglia and

endothelial cells.<sup>19</sup> However, the mechanisms underlying neuroinvasion and neurovirulence are not fully understood. The role of viral factors in dengue neuropathogenesis was demonstrated by mutating three amino acids in DENV-1, mapping to the structural protein E and non-structural protein NS3 helicase domains. The E protein seems to be involved in the pathogenesis of the disease, through the mediation of host-cell tropism. These mutations produced a neurovirulent virus, and the result was an extensive encephalitis and leptomeningitis in mice.<sup>20</sup>

Encephalitis is the most common manifestation secondary to direct viral involvement and usually develops during the acute phase of infection. In a study using mice infected by dengue virus, it was possible to demonstrate that there was a breakdown of the blood-brain barrier leading to cerebral vasogenic edema. A dengue-induced cytokine immune response was responsible for this reaction and it seems to occur in humans.<sup>21</sup> However, it is still not known if the virus passively crosses the blood-brain barrier during the course of systemic infection or whether it actively invades the CNS.

Other neurological diseases that accompany the acute febrile period and are related to viral invasion are meningitis, myositis and myelitis.<sup>22-24</sup> Specifically, in cases of myelitis associated with dengue infection, viral invasion of the spinal cord produces a specific local immune response in the early stage of neurological disease (intrathecal synthesis of dengue Immunoglobulin G antibodies).<sup>9</sup> Detection of the local synthesis of monospecific antibodies may be associated with the pathogenesis of the disease and indicates viral neurotropism.

## Autoimmune reaction

The postinfectious character related to the immunoallergic mechanism can determine acute disseminated encephalomyelitis, neuromyelitis optica, optic neuritis, myelitis or simply a post-infectious encephalopathy.<sup>24,25</sup> The first brain autopsy to confirm this theory showed a perivenous demyelinating leukoencephalopathy.<sup>26</sup> This delayed form of disease is most frequently observed in adults within 1-3 weeks of the onset of infection. Similarly, peripheral involvement, as observed in Guillain Barré syndrome, might have a similar postinfectious mechanism.<sup>15</sup>

## Neurological complications

Neurological involvement in dengue infection was considered to be a rare complication. However, recent reports of several dengue

cases with neurological complications have changed this view.<sup>7-8,16,27</sup>

## Encephalitis and meningitis

Encephalitis is the most common neurological manifestation of dengue infection.<sup>28</sup> Its frequency has been reported to range from 4.2% to as much as 51%.<sup>10,17,28</sup> This difference in frequency depends on the predominant serotype DENV-2 and DENV-3 during epidemics. The clinical criteria for dengue encephalitis are:<sup>29</sup> i) fever; ii) acute signs of cerebral involvement, such as altered consciousness or personality, seizures, or focal neurological signs; iii) presence of anti-dengue Immunoglobulin M antibodies or dengue genomic material in the serum and/or cerebrospinal fluid (which of these should be assayed for should be determined according to time from onset of infection); iv) exclusion of other causes of viral encephalitis and encephalopathy.

The main symptoms are seizures, altered consciousness, and headaches. Unexpectedly, the typical symptoms of dengue infection (myalgias, diarrhea, joint or abdominal pain, rash, and bleedings) are reported in only 50% of encephalitis cases.<sup>29,30</sup> Therefore, dengue virus would not ordinarily be suspected to be the cause of the neurological disease.<sup>31</sup>

The computed tomography (CT) and magnetic resonance imaging (MRI) findings are diverse. Normal parameters are not uncommon but hemorrhages, diffuse cerebral edema, and focal abnormalities involving the globus pallidus, the hippocampus, the thalamus, and the internal capsule can also be found. These lesions are hyper-intense as visualized by MRI.<sup>24</sup> Analysis of CSF can demonstrate inflammatory reaction, with lymphomononuclear pleocytosis and normal glucose levels. However, normal CSF cellularity has been shown in more than half of patients with dengue encephalitis.<sup>10</sup> The absence of pleocytosis in CSF has been described in 5% of viral encephalitis cases; we speculate that this number is underestimated with regard to dengue infection.<sup>32</sup> Therefore, the diagnosis of encephalitis should not be discarded because of normal CSF cellularity.<sup>10</sup>

The incidence of meningitis among serologically confirmed dengue cases ranges from 24.4% to 30% in children.<sup>28</sup> Dengue meningitis rarely manifests in adults.<sup>22</sup> Clinical signs are similar to other viral meningitis.

## Acute disseminated encephalomyelitis

Acute disseminated encephalomyelitis (ADEM) is rarely described in association with dengue infection.<sup>25,33-36</sup> One of the reported cases was neuromyelitis optica, an exceptional form of ADEM.<sup>25</sup> The diagnosis of ADEM was based on the onset of neurological symptoms following the hyperpyrexia phase of dengue. As with other viruses, the pathogenetic mechanisms underlying ADEM suggest that the symptoms result from an immune system-mediated process. White matter lesions occur in several areas of the brain, such as the centrum semiovale, the corona radiata, the callosal-septal interface, and the thalamus. Thoracic spinal cord can also be involved, showing demyelinating lesions.<sup>34</sup>

An autopsy was described in only one case in the literature. Histopathology from the lesions showed perivenous demyelination, macrophages and hemorrhages. As this patient had dengue hemorrhagic fever, the focal hemorrhages seen in the lesions were probably related to the patient's thrombocytopenia.<sup>36</sup>

Encephalomyelitis secondary to dengue infection usually has a favorable outcome, although some patients exhibit persistent neurological symptoms. Glucocorticoid is effective in treating encephalomyelitis, which is why an early diagnosis is critical for a good prognosis.<sup>34-36</sup>

## Myelitis

Myelitis due to dengue infection is an uncommon neurological manifestation. Its frequency ranges from 9.5% to 15%.<sup>8,27</sup> Dengue myelitis appears between seven and 30 days following the onset of dengue infection.<sup>27</sup>

**Table 1. Neurological complications according to pathogenesis.**

Metabolic disturbance	Viral invasion	Autoimmune reaction
Encephalopathy	Encephalitis Meningitis Myositis Myelitis	Acute disseminated encephalomyelitis Neuromyelitis optica Optic neuritis Myelitis Post-infectious encephalopathy Guillain Barré syndrome

Neurological symptoms may persist and may include paraparesis and sphincter dysfunction. MRI usually demonstrates lesions at the thoracic spinal level where there is a hyperintense signal (Figure 1).<sup>24</sup> A unique case in which a gray matter abnormality was observed using MRI in a region corresponding to the anterior horn from the cervical to thoracic cord has been reported.<sup>37</sup> Analysis of CSF reveals an increase in the albumin quotient (Alb Q) indicating a dysfunction of the blood-CSF barrier and the intrathecal synthesis of Immunoglobulin G (IgG) dengue antibodies.<sup>9</sup> Based on specific antibody index, Puccioni-Sohler *et al.* found intrathecal synthesis of dengue IgG antibodies only in patients with myelitis despite also examining cases of encephalitis and GBS.<sup>9,38,39</sup>

### Guillain Barré syndrome and mononeuropathies

In isolated reports, dengue virus was described as a causative agent of GBS. In a pre-

vious study, Soares *et al* reported that GBS accounted for 30% of the neurological manifestations of dengue infection.<sup>27</sup> However, dengue infection may have been underestimated as a causative agent of GBS.<sup>40</sup> The authors reported seven cases (46.6% of all included GBS cases), presenting with dengue positive IgM in serum but with little to no clinical symptoms of the previous infection. The neurological picture of GBS cases induced by dengue infection is similar to that described in the literature concerning GBS caused by other infections in which ascending paraparesis is the principal manifestation.<sup>41-45</sup> Treatment is usually effective and the prognosis is good. A single case of Miller Fisher that had dengue infection was also reported to have recovered spontaneously.<sup>46</sup>

Evidence suggests that the clinical manifestations of GBS are the result of cell-mediated immunological reactions. Activated T cells could cross the vascular endothelium (blood-brain barrier) and recognize an antigen in the endoneural compartment. T cells produce cytokines and chemokines which open the blood-brain barrier allowing antibodies to enter and Schwann cells to attack.<sup>47</sup> Dengue

virus would initiate this immunological event, leading to the disease. Myelin or axons could be the target of this immune response.<sup>15</sup>

In conclusion, oligosymptomatic dengue underestimates the number of cases of GBS associated with dengue infection. This situation is complicated by the long period of time between onset of infection and neurological symptoms. In endemic areas, dengue infection should be tested as a possible etiological agent in cases of GBS. Finally, rare cases of long thoracic neuropathy, oculomotor palsy, and phrenic neuropathy have been related to dengue infection.<sup>48-50</sup>

### Myositis

Several viruses have been associated with inducing benign acute myositis. In a study in India, 50% of benign acute childhood myositis cases were attributed to dengue infection.<sup>23</sup> Myositis has a wide clinical spectrum, ranging from mild proximal asymmetrical weakness of the lower limbs to severe, rapidly progressing,

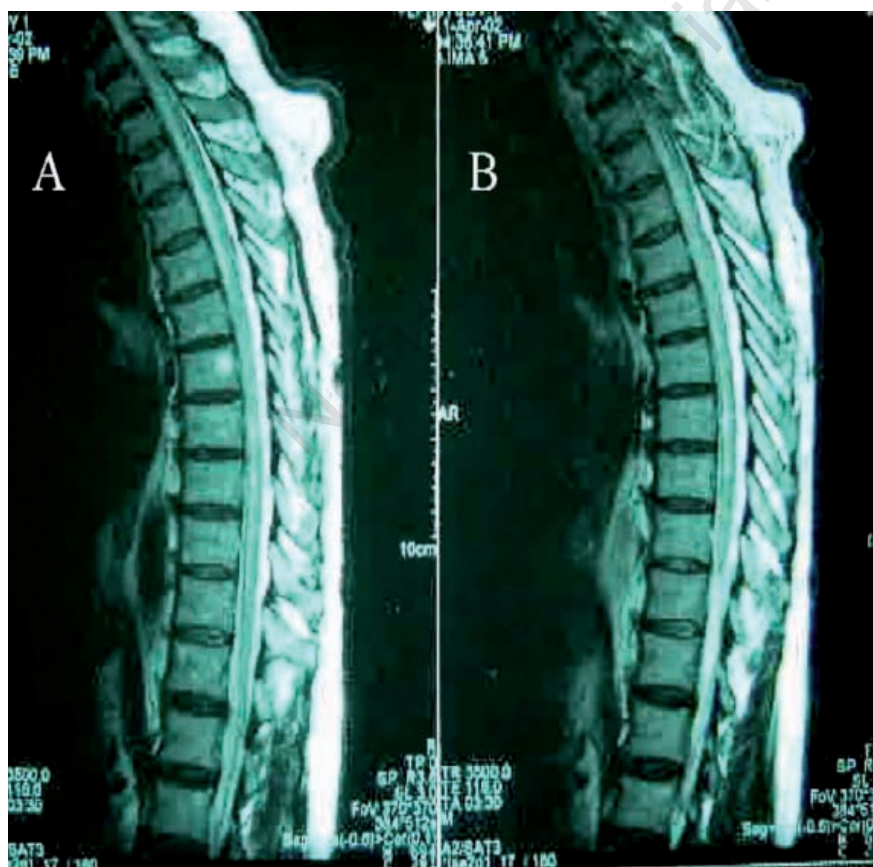

Figure 1. A and B Magnetic resonance image of dorsal spinal cord showing an enhanced signal in a patient presenting acute myelitis. Sagittal plane, T2 sequence.




Figure 2. Two percent agarose gel electrophoresis demonstrating the sized amplicons for dengue Multiplex RT-PCR. Lane 1: molecular size standard (100 bp), Lane 2: Dengue 3 in plasma (290 bp), Lanes 3-4: negative samples, Lanes 5-6: Dengue 2 (119 bp) in both samples, Lane 7: negative sample, Lane 8: Dengue 2 control (119 bp), Lane 9: Dengue 3 control (290 bp), Lane 10: negative control.

limb, trunk, and respiratory muscle weakness. Usually, myositis is considered a benign illness in which severe fulminant cases are rare. Serum creatine phosphokinase levels are always elevated, and a possible correlation between these values and the severity of the weakness has been proposed.<sup>51</sup> Muscle biopsies have revealed histopathological changes, including perivascular mononuclear infiltrate, lipid accumulation, foci of myonecrosis, and an increase in the number of mitochondria.<sup>52</sup>

The pathogenesis of myositis is not clear. Direct viral invasion and immune-mediated damage of muscle fibers have been suggested to be possible mechanisms. Immune-mediated damage of muscle fibers has also been implicated in rhabdomyolysis. In addition, biochemical and hematologic abnormalities, such as thrombocytopenia, leukopenia, and hypokalemia, are potential factors that influence the severity and prognosis of dengue myositis.<sup>53,54</sup>

## Laboratory studies

The diagnosis of acute dengue infection is based on the detection of viral antigens or antibodies in blood.<sup>55-57</sup> Viral antigens may be detected in blood or CSF during the first week after the onset of symptoms by such technique as cell culture or tissue fixation, enzyme-linked immunosorbent assay (ELISA), or polymerase chain reaction (reverse-transcriptase PCR or real-time PCR) (Figure 2).<sup>11,16,31,58</sup> The detection of dengue IgM antibodies in serum or the increase of dengue IgG antibody titer in paired samples can be used to confirm serological diagnosis of a recent infection.<sup>55,59,60</sup> Specific serum reactivity for IgM may be found five days after the onset of symptoms and may persist for 30-60 days. Meanwhile, an increase in dengue IgG antibodies occurs during the first or second day in cases of secondary infection. Specific IgG antibody levels return to baseline levels after 30-40 days.<sup>55</sup> The detection of specific antibodies is usually accomplished by ELISA but may also be detected by a complement fixation technique, a neutralization test, a hemagglutination inhibition assay, or an immunochromatographic rapid test.<sup>55</sup> Serum cross-reactivity is common in the serological tests with other flaviviruses, such as St. Louis encephalitis, Japanese encephalitis, West Nile fever, and yellow fever.<sup>60</sup>

Analysis of CSF contributes to the neurological diagnosis associated with dengue by the demonstration of: i) inflammatory reaction in the CNS (pleocytosis, hyperproteinorhachia, blood-CSF barrier dysfunction, and intrathecal synthesis of total IgG) in cases of encephalitis, myelitis, and meningitis; ii) protein-cytological dissociation in Guillain Barré syndrome; iii) hemorrhagic CSF in cases of cerebro-

meningeal hemorrhage; iv) exclusion of other infectious diseases; and v) detection of specific antibodies and viral antigens.<sup>9,11,31</sup> However, normal CSF does not exclude the possibility of neurological complications associated with dengue. Complications may occur, especially in cases of encephalitis.<sup>10</sup> Specific IgM and IgG antibodies have been found in CSF in the early stages of dengue CNS infection up until 5-7 days after the onset of neurological symptoms. The dengue IgM immune response in CSF detected by ELISA shows a high specificity (97-100%) the neurological diagnosis associated with dengue to be confirmed.

The sensitivity of IgM detection in CSF ranges between 0% and 73%, depending on the method used. The absence of specific IgM detection in CSF does not exclude dengue as the causative agent.<sup>7,11,17,27,61</sup> On the other hand, specific IgG in CSF is not useful as a diagnostic tool, as these antibodies may result from a prior infection, and they cross the blood-CSF barrier. The presence of intrathecal synthesized specific antibodies is a potential marker of myelitis associated with dengue and seems to be related with the neuroinvasive properties of the virus.<sup>9</sup> Non-structural 1 antigen (NS1 Ag) was found in the CSF of dengue patients by ELISA as detected by an assay that exhibited a sensitivity of 50% and specificity of 100%.<sup>11</sup> The combined use of NS1 Ag and specific IgM antibodies increased the sensitivity of dengue analysis in CSF to 92%.<sup>11</sup> The frequency of detection of dengue viral RNA, using PCR techniques (RT-PCR or real-time PCR) has had variable success in CSF (0-83%).<sup>7,8,16,31</sup> It depends on the neurovirulent and neuroinvasive phenotype of studied dengue virus, the stage of the disease, and which method is employed. In fact, not all neurological complications associated with dengue are caused by the direct virus neuroinvasion.

## Diagnosis

A diagnosis of neurological disease associated with dengue is made by detecting the presence of positive dengue IgM or viral antigens in patients with acute neurological symptoms.<sup>6</sup> Diagnosis may be difficult because of the possible development of neurological complications in oligosymptomatic dengue cases, and the routine test of CSF is not specific. Blood tests, CSF analysis and MRI images contribute to the differential diagnoses, as do a number of other inflammatory, neoplastic, and vascular diseases. Routine hematologic, biochemical, and liver function tests for rheumatic diseases, B/C hepatitis, and human immunodeficiency virus-1 (HIV-1) should be carried out in all patients. Routine CSF analyses include a cell

count, a determination of protein and glucose/lactate concentration, a smear and culture for bacteria and fungi, an assessment of blood-CSF barrier function by albumin quotient (CSF/serum), a detection of intrathecal synthesis of total IgG, and a measurement of specific antibodies against syphilis, cytomegalovirus, Epstein-Barr, and herpes simplex viruses.

## Treatment and prognosis

There is no licensed vaccine or specific treatment to prevent dengue or the neurological diseases associated with it.<sup>62</sup> The only preventative measure is to avoid catastrophic dengue epidemics through the control of dengue vectors.<sup>2</sup> Neurological diseases associated with dengue may be treated according to diagnosis. The majority of patients have a benign evolution with spontaneous recovery, especially those who have encephalitis or Guillain-Barré syndrome.<sup>27</sup> The prognosis and the characteristics of Guillain-Barré syndrome seem to be similar to those reported for other infectious diseases. Neurological sequelae occur in 20-30% of reported cases;<sup>8,27,38</sup> these include spastic paraparesis and urinary retention associated with cases of myelitis. Mental confusion and personality alterations have remained in some patients with dengue encephalitis. Mortality from dengue infection is 3-5%.<sup>6</sup> The mortality rate of patients who develop neurological complication associated with dengue depends on the clinical picture of the disease and ranges between 5% and 30%.<sup>7,24,27,28,38</sup> In general, this mortality results from cases of DHF or dengue shock syndrome.

## Conclusions

Diagnosis of neurological dengue needs to be reevaluated, especially for clinicians who are unfamiliar with its wide array of clinical presentations. Diagnosis is currently based on the detection of specific IgM antibodies or antigens in the blood. In addition, analysis of CSF (for the detection of specific antibodies and viral antigens) has demonstrated great potential as a diagnostic tool for neurological dengue as well as for providing a better understanding of the dengue neuropathogenesis. In endemic areas or in cases of recent travel to endemic regions, dengue infection should be considered in the differential diagnosis of encephalitis, myelitis, Guillain-Barré syndrome, and meningitis, even in the absence of a previous history of dengue fever. The neurological complications associated with dengue may be underestimated, especially in cases in whom there was a prior oligosymptomatic/asymptomatic dengue infec-

tion. Improving the accuracy of diagnosis is important for the early treatment of the neurological complications, thereby avoiding unnecessary therapy and longer hospitalization, while searching for the presence of other diseases. More than ever, the development of a dengue vaccine needs to be the focus of research efforts seeking to control the disease.

## References

- Chang GJ. Molecular biology of dengue viruses. Gubler DJ, Kuno G, eds. *Dengue and dengue hemorrhagic fever*. London: CAB International; 1997. pp. 175-198..
- Simmons CP, Farrar J. Changing patterns of dengue epidemiology and implications for clinical management and vaccines. *PLoS Med* 2009;6:e1000129.
- San Martín JL, Brathwaite O, Zambrano B. The epidemiology of dengue in the Americas over the last three decades: a worrisome reality. *Am J Trop Med Hyg* 2010;82:128-35.
- Guzman MG, Kouri G. Dengue and dengue hemorrhagic fever in the Americas: lessons and challenges. *J Clin Virol* 2003;27:1-13.
- Freedman DO, Weld LH, Kozarsky PE, et al. Spectrum of disease and relation to place of exposure among ill returned travelers. *N Engl J Med* 2006;354:119-30.
- World Health Organization. *Dengue haemorrhagic fever: diagnosis, treatment, prevention and control*. 2nd edition. Geneva: WHO; 1997.
- Pancharoen C, Thisyakorn U. Neurological manifestation in dengue patients. *Southeast Asian J Trop Med Public Health* 2001;32:341-5.
- Solomon T, Dung NM, Vaughan DW, et al. Neurological manifestations of dengue infection. *Lancet* 2000;355:1053-8.
- Puccioni-Sohler M, Soares CN, Papaiz-Alvarenga R, et al. Neurologic dengue manifestations associated with intrathecal specific immune response. *Neurology* 2009;73:1413-7.
- Soares CN, Cabral-Castro MJ, Peralta JM, et al. Review of the etiologies of viral meningitis and encephalitis in a dengue endemic region. *J Neurol Sci* 2011;303:75-9.
- Araújo FM, Brilhante RS, Cavalcanti LP, et al. Detection of the dengue non-structural 1 antigen in cerebral spinal fluid samples using a commercially available enzyme-linked immunosorbent assay. *J Virol Methods* 2011;177:128-31.
- Hommel D, Talarmin A, Deubel V, et al. Dengue encephalitis in French Guiana. *Res Virol* 1998;149:235-8.
- Liou LM, Lan SH, Lai CL. Dengue fever with ischemic stroke: a case report. *Neurologist* 2008;14:40-2.
- Mathew S, Pandian JD. Stroke in patients with dengue. *J Stroke Cerebrovasc Dis* 2010;19:253-6.
- Murthy JM. Neurological complication of dengue infection. *Neurol India* 2010;58:581-4.
- Lum LC, Lam SK, Choy YS, et al. Dengue encephalitis: a true entity? *Am Trop Med Hyg* 1996;54:256-9.
- Thisyakorn U, Thisyakorn C, Limpitikul W, Nisalak A. Dengue infection with central nervous system manifestations. *Southeast Asian J Trop Med Public Health* 1999;30:504-6.
- Miagostovich MP, dos Santos FB, Fumian TM, et al. Complete genetic characterization of a Brazilian dengue virus type 3 strain isolated from a fatal outcome. *Mem Inst Oswaldo Cruz* 2006;101:307-13.
- Ramos C, Sánchez G, Pando RH et al. Dengue virus in the brain of a fatal case of hemorrhagic dengue fever. *J Neurovirol* 1998;4:465-8.
- Bordignon J, Strottmann DM, Mosimann AL, et al. Dengue neurovirulence in mice: identification of molecular signatures in the E and NS3 helicase domains. *J Med Virol* 2007;79:1506-17.
- Chaturvedi UC, Dhawan R, Khanna M, Mathur A. Breakdown of the blood-brain barrier during dengue virus infection of mice. *J Gen Virol* 1991;72:859-66.
- Soares CN, Cabral-Castro MJ, Peralta JM, et al. Meningitis determined by oligosymptomatic Dengue virus type 3 infection: report of a case. *J Int Infect Dis* 2010;14:150-2.
- Rajajee S, Ezhilarasi S, Rajarajan K. Benign acute childhood myositis. *Indian J Pediatr* 2005;72:399-400.
- Wasay M, Channa R, Jumani M, et al. Encephalitis and myelitis associated with dengue viral infection clinical and neuroimaging features. *Clin Neurol Neurosurg* 2008;110:635-40.
- Sousa AM, Puccioni-Sohler M, Dias AB, et al. Post-dengue neuromyelitis optica: case report of a Japanese-descendent Brazilian child. *J Infect Chemother* 2006;12:396-8.
- Chimelli L, Hahn MD, Netto MB, et al. Dengue: neuropathological findings in 5 fatal cases from Brazil. *Clin Neuropathol* 1990;9:157-62.
- Soares CN, Faria LC, Peralta JM, et al. Dengue infection: neurological manifestations and cerebrospinal fluid (CSF) analysis. *J Neurol Sci* 2006;249:19-24.
- Jackson ST, Mullings A, Bennett F, et al. Dengue infection in patients presenting with neurological manifestations in a dengue endemic population. *West Indian Med J* 2008;57:373-6.
- Soares CN, Puccioni-Sohler M. Dengue encephalitis: suggestion for case definition. *J Neurol Sci* 2011;306:165.
- Varatharaj A. Encephalitis in the clinical spectrum of dengue infection. *Neurol India* 2010;58:585-91.
- Domingues RB, Kuster GW, Onuki-Castro FL, et al. Involvement of the central nervous system in patients with dengue virus infection. *J Neurol Sci* 2008;267:36-40.
- Kennedy PG. Viral encephalitis: causes, differential diagnosis, and management. *J Neurol Neurosurg Psychiatry* 2004;75:10-5.
- Brito CA, Sobreira S, Cordeiro MT, Lucena-Silva N. Acute disseminated encephalomyelitis in classic dengue. *Rev Soc Bras Med Trop* 2007;40:236-8.
- Yamamoto Y, Takasaki T, Yamada K, et al. Acute disseminated encephalomyelitis following dengue fever. *J Infect Chemother* 2002;8:175-7.
- Gera C, George U. Acute disseminating encephalomyelitis with hemorrhage following dengue. *Neurol India* 2010;58:595-6.
- Sundaram C, Shantveer G, Uppin SG, et al. Acute disseminated encephalomyelitis following dengue hemorrhagic fever. *Neurol India* 2010;58:599-601.
- Kunishige M, Mitsui T, Tan BH, et al. Preferential gray matter involvement in dengue myelitis. *Neurology* 2004;63:1980-1.
- Misra UK, Kalita J, Syam UK, Dhole TN. Neurological manifestations of dengue virus infection. *J Neurol Sci* 2006;244:117-22.
- Miagostovich MP, Ramos RG, Nicol AF, et al. Retrospective study on dengue fatal cases. *Clin Neuropathol* 1997;16:204-8.
- Soares CN, Cabral-Castro MJ, Oliveira C, et al. Oligosymptomatic dengue infection: a potential cause of Guillain Barré syndrome. *Arq Neuropsiquiatr* 2008;66:234-7.
- Esack A, Teelucksingh S, Singh N. The Guillain Barré syndrome following dengue fever. *West Indian Med J* 1999;48:36-7.
- Paul C, Dupont B, Pialoux G. Polyradiculonévrite aiguë secondaire à une dengue. *Presse Med* 1990;19:1503.
- Sainte Foie S, Niel L, Moreau JP, et al. Un cas de polyradiculonévrite associé à une dengue chez une patiente originaire de la Guyane Française. *Bull Soc Pathol Exot* 1993;86:117-8.
- Kumar S, Subhashini P. Guillain Barré syndrome occurring in the course of dengue fever. *Neurol India* 2005;53:250-1.
- Sulekha C, Kumar S, Philip J. Guillain Barré syndrome following dengue fever: report of 3 cases. *Indian Pediatr* 2004;41:948-50.
- Gaultier C, Angibaude G, Laille M, Lacassin F. Probable syndrome de Miller Fisher au

- cours d'une dengue de type 2. *Rev Neurol* 2000;156:169-71.
47. Hughes RAC, Hadden RDM, Gregson NA, Smith KJ. Pathogenesis of Guillain Barré syndrome. *J Neuroimmunol* 1999;100:74-97.
48. Chappuis F, Justaf J, Duchunstan L, et al. Dengue fever and long thoracic nerve palsy in a traveller returning from Thailand. *J Travel Med* 2004;11:112-4.
49. Donnio A, Beral L, Olindo S, et al. Dengue, a new etiology in oculomotor paralysis. *Can J Ophthalmol* 2010;45:183-4.
50. Ansari MK, Jha S, Nath A. Unilateral diaphragmatic paralysis following dengue infection. *Neurol India* 2010;58:596-8.
51. Paliwal VK, Garg RK, Juyal R, et al. Acute dengue virus myositis: a report of seven patients of varying clinical severity including two cases with severe fulminant myositis. *J Neurol Sci* 2011;300:14-8.
52. Malheiros SMF, Oliveira ASB, Schimidt B, et al. Dengue. Muscle biopsy findings in 15 patients. *Arq Neuropsiquiatr* 1993;51:159-64.
53. Warke RV, Becerra A, Zawadzka A, et al. Efficient dengue virus (DENV) infection of human muscle satellite cells upregulates type I interferon response genes and differentially modulates MHC I expression on bystander and DENV-infected cells. *J Gen Virol* 2008;89:1605-15.
54. Davis JS, Bourke P. Rhabdomyolysis associated with dengue virus infection. *Clin Infect Dis* 2004;38:109-11.
55. Guzmán MG, Kouri G. Dengue diagnosis, advances and challenges. *Int J Infect Dis* 2004;8:69-80.
56. Lima MR, Nogueira RM, Schatzmayr HG, dos Santos FB. Comparison of three commercially available dengue NS1 antigen capture assays for acute diagnosis of dengue in Brazil. *PLoS Negl Trop Dis* 2010;4:e738.
57. Huhtamo E, Hasu E, Uzcátegui NY, et al. Early diagnosis of dengue in travelers: comparison of a novel real-time RT-PCR, NS1 antigen detection and serology. *J Clin Virol* 2010;47:49-53.
58. Yong YK, Thayan R, Chong HT, et al. Rapid detection and serotyping of dengue virus by multiplex RT-PCR and real-time SYBR green RT-PCR. *Singapore Med J* 2007;48:662-8.
59. Sa-NGasang A, Anantapreecha S, A-Nuegoonpipat A, et al. Specific IgM and IgG responses in primary and secondary dengue virus infections determined by enzyme-linked immunosorbent assay. *Epidemiol Infect* 2006;134:820-5.
60. De Paula SO, Fonseca BA. Dengue: a review of the laboratory tests a clinician must know to achieve a correct diagnosis. *Braz J Infect Dis* 2004;8:390-8.
61. Cam BV, Fonsmark L, Hue NB, et al. Prospective case-control study of encephalopathy in children with dengue hemorrhagic fever. *Am J Trop Med Hyg* 2001;65:848-51.
62. Schmitz J, Roehrig J, Barrett A, Hombach J. Next generation dengue vaccines: a review of candidates in preclinical development. *Vaccine* 2011;29:7276-84.