



UNIVERSITÀ  
DEGLI STUDI  
FIRENZE

## FLORE

# Repository istituzionale dell'Università degli Studi di Firenze

### **Denosumab treatment of inoperable or locally advanced giant cell tumor of bone - Multicenter analysis outside clinical trial**

Questa è la versione Preprint (Submitted version) della seguente pubblicazione:

*Original Citation:*

Denosumab treatment of inoperable or locally advanced giant cell tumor of bone - Multicenter analysis outside clinical trial / Rutkowski, Piotr\*; Gaston, Louie; Borkowska, Aneta; Stacchiotti, Silvia; Gelderblom, Hans; Baldi, Giacomo Giulio; Palmerini, Emanuela; Casali, Paolo; Gronchi, Alessandro; Parry, Michael; Campanacci, Domenico Andrea; Scoccianti, Guido; Wagrodzki, Michal; Ferrari, Stefano; Dijkstra, Sander; Pieńkowski, Andrzej; Grimer, Robert. - In: EUROPEAN JOURNAL OF SURGICAL ONCOLOGY. - ISSN 0748-

*Availability:*

This version is available at: 2158/1148273 since: 2021-04-02T15:33:21Z

*Published version:*

DOI: 10.1016/j.ejso.2018.03.020

*Terms of use:*

Open Access

La pubblicazione è resa disponibile sotto le norme e i termini della licenza di deposito, secondo quanto stabilito dalla Policy per l'accesso aperto dell'Università degli Studi di Firenze (<https://www.sba.unifi.it/upload/policy-oa-2016-1.pdf>)

*Publisher copyright claim:*

(Article begins on next page)

## **Denosumab treatment of inoperable or locally advanced Giant Cell Tumor of Bone - multicenter analysis outside clinical trial**

Piotr Rutkowski<sup>1\*</sup>, Louie Gaston<sup>2</sup>, Aneta Borkowska<sup>3</sup>, Silvia Stacchiotti<sup>4</sup>, Hans Gelderblom<sup>5</sup>, Giacomo Giulio Baldi<sup>6</sup>, Emanuela Palmerini<sup>7</sup>, Paolo Casali<sup>4</sup>, Alessandro Gronchi<sup>4</sup>, Michael Parry<sup>2</sup>, Domenico Andrea Campanacci<sup>8</sup>, Guido Scoccianti<sup>8</sup>, Michal Wagrodzki<sup>9</sup>, Stefano Ferrari<sup>7</sup>, Sander Dijkstra<sup>5</sup>, Andrzej Pieńkowski<sup>1</sup>, Robert Grimer<sup>2</sup>

<sup>1</sup>Department of Soft Tissue/Bone Sarcoma and Melanoma, <sup>3</sup>Department of Radiation Oncology, <sup>9</sup>Department of Pathology, Maria Sklodowska-Curie Institute – Oncology Center, Warsaw, Poland

<sup>2</sup>The Royal Orthopaedic Hospital NHS Foundation Trust, Birmingham, UK

<sup>4</sup>Sarcoma Unit, Cancer Medical Department, Istituto Nazionale Tumori, Milan, Italy

<sup>5</sup>Leiden University Medical Center, Leiden, the Netherlands

<sup>6</sup>UO Oncologia Medica, Nuovo Ospedale di Prato "S.Stefano", Prato, Italy

<sup>7</sup>Chemotherapy Unit, Istituto Ortopedico Rizzoli, Bologna, Italy

<sup>8</sup>Orthopedics Oncology Department, Azienda Ospedaliero-Universitaria Careggi, Florence, Italy

\*To whom correspondence should be addressed:

Piotr Rutkowski MD, PhD

Department of Soft Tissue/Bone Sarcoma and Melanoma; Maria Sklodowska-Curie Institute – Oncology Center

Roentgena 5; 02-781 Warsaw; Poland

Tel. +48 22 6439375;

fax. + 48 22 6439791;

e-mail: piotr.rutkowski@coi.pl

## Abstract

**Background:** Giant cell tumor of bone (GCTB) is an osteolytic, locally aggressive, rarely metastasizing bone tumor. This is a retrospective study evaluating a large series of GCTB patients treated with denosumab in routine practice in 6 European reference centers.

**Methods:** Patients with locally advanced, unresectable or metastatic GCTB, treated with denosumab outside clinical trials were eligible. Primary end-point was progression-free survival (PFS) for all patients; secondary end-points were: type of surgery, relapse rate and event-free survival for patients after preoperative denosumab + surgery.

**Results:** We identified 138 patients treated in the period 2011-2016. In 40/43 cases the diagnosis was confirmed by *H3F3A* gene mutation. Median follow-up time was 23 months (range 6-48). Primary tumor was located in lower limb (38%) - mostly in femur and tibia, in upper limb (34%), and in pelvis/axial skeleton/ribs (28%). 110 (80%) patients had primary tumors, 28 (22%) recurrent tumors after previous surgical procedures (+/- radiotherapy). 89/138 patients had locally advanced GCTB and underwent neoadjuvant denosumab. The median denosumab treatment duration was 8 months (median number of cycles 11), 98% had clinical benefit from therapy. 39 (44%) had wide en-bloc resection - WE (+ implantation of the prosthesis in 17 cases), the other 50 (56%) cases had intralesional curettage - C. Progression after surgical treatment was observed in 19 patients, 16 of them after C (32%); 13 patients underwent denosumab re-challenge, and all responded. Two-year progression-free survival (PFS; from denosumab start) rate was 81%; 2-year EventFS (from surgery) was significantly better in WE group (93%) vs 55% in C group ( $p=0.006$ ). Treatment was well tolerated with only 2 cases of grade 3 toxicity and one osteonecrosis of the jaw.

**Conclusion:** Our retrospective study confirms that denosumab is extremely efficient in unresectable/metastatic disease as well as in a neoadjuvant setting. Our data confirm excellent efficacy and short-term tolerability of this drug. Our data suggest that neoadjuvant therapy with denosumab is the option for treatment of initially locally advanced tumors to facilitate complete surgical resection or avoid mutilating surgery. The risk of recurrences after curettage of GCTB following denosumab raises questions about the optimal management of such cases.

**Key words:** denosumab, RANKL, giant cell tumor of bone, neoadjuvant therapy

**Highlights:**

Denosumab is extremely efficient in unresectable/metastatic giant cell tumor (GCTB) of bone as well as in a neoadjuvant setting.

Our data confirm excellent efficacy and short-term tolerability of this drug.

Our data suggest that neoadjuvant therapy with denosumab became the option for treatment of initially locally advanced tumors to facilitate complete surgical resection or avoid mutilating surgery.

In cases in which we expect to perform an enbloc surgery in a locally advanced GCTB denosumab is recommended preoperatively.

The risk of recurrences after curettage of GCTB following denosumab raises questions about the optimal management.

## Introduction

Giant cell tumor of bone (GCTB) is an osteolytic, locally aggressive tumor, with low metastatic potential [1-5]. The pathogenesis of GCTB is related to RANK-RANKL (receptor activator of nuclear factor kB ligand) interactions, because RANKL is highly expressed by neoplastic mononuclear mesenchymal stromal cells, whereas RANK is expressed on osteoclast-like cells, which are recruited secondarily in the tumor and responsible for the aggressive osteolytic activity [4,6-12]. The main treatment modality is surgery, mostly in the form of curettage, however the important challenge in the management of GCTB is relatively high local recurrence after primary therapy, especially in case of soft tissue extension of the tumor [2-4,13-15]. En bloc resection should be considered in case of multiple recurrent or locally advanced GCTB, impossible joint salvage, extensive cortex destruction (i.e., insufficient cortex left to curette), and extensive soft tissue involvement. Until recently there were limited options in case of locally advanced/unresectable or metastatic disease. The introduction of denosumab – a RANKL inhibitor, revolutionized the medical therapy of surgically unsalvageable cases and its high efficacy was confirmed in two phase II clinical studies [15-18]. However, the long-term and real practice data of denosumab therapy, as well as the combination strategy with surgery, have not been well explored [19-22].

In current study we analyzed a large series of GCTB patients treated with denosumab in real-life practice outside clinical trials in 6 European reference centers. Additionally, we have better evaluated the cohort of patients treated preoperatively with denosumab.

## **Patients and Methods**

Consecutive patients with histologically confirmed GCTB treated with denosumab in 6 European referral centers (Warsaw, Poland; Birmingham, UK; Leiden, the Netherlands; Bologna, Italy; Milan, Italy; Prato and Careggi-Firenze, Italy) outside clinical trial between 2011 and 2016 with minimum 6 months of follow-up were included into the analysis. All pathological diagnoses were reviewed by an expert pathologist in the field of bone sarcomas in each center and confirmed by mutation in *H3F3A* gene when clinically indicated or per institution procedure.

All cases were evaluated by multidisciplinary team (MDT) consisting of surgeon, orthopedic, medical oncologist, radiation oncologist and radiologist before start of therapy with denosumab. The study has been approved by the local Bio-Ethics Committee in Warsaw, Poland according to Good Clinical Practice Guidelines. Patients did not undergo any further selection.

All patients were treated with subcutaneous injections of denosumab in dose 120 mg every 28 days, with additional doses on days 8 and 15 of the first month, with concurrent supplementation with Calcium 1000 mg/day and Vitamin D 400 IU/day. Treatment was conducted until the complete tumor resection was feasible (as assessed by MDT), tumor progression or unacceptable toxicity. Some patients on longer therapy had less dense schedule of denosumab injections: every 2-3 months. Tumor status was assessed every 3-6 months with computed tomography or magnetic resonance imaging, or plain X-ray according to local standards by dedicated expert radiologists from each center and by MTD when required.

89 patients (64%) at the data cut-off date had undergone surgery. 61 patients still continues denosumab therapy (twelve as rechallenge of a salvage therapy after tumor recurrence after surgery).

## Safety

Adverse events were recorded and graded according to National Cancer Institute Common Terminology Criteria for Adverse Events (CTCAE) version 4.0.

## Statistical analysis

All statistical analyses were performed using the R language environment version 3.3.3 (The R Foundation for Statistical Computing) statistical program. For the survival analysis, the Kaplan-Meier estimator was used with the log-rank tests for bivariate comparisons. The primary objective of the study was to assess the progression-free survival (PFS) of advanced GCTB patients treated with denosumab. PFS time was calculated from the date of the start of denosumab treatment to the date of the most recent follow-up, or progression of the disease defined according to modified Response Evaluation Criteria in Solid Tumors (RECIST; version 1.1) [23]. The secondary objectives were based on the cohort of patients who underwent surgery after neoadjuvant denosumab therapy, and comprised: type of surgery, relapse rate after surgery and the event-free survival (EFS) calculated from the date of surgery to the date of the most recent follow-up or relapse of the disease. Clinical benefit of denosumab therapy was defined as at least stabilization of the disease for no less than 6 months. The differences were considered statistically significant if the p-values were  $<0.05$ .

## Results

To the analysis 138 consecutive patients were included. Baseline patient characteristics are shown in Table I. Median age was 32 years.

The lesions were located in lower limb (38%; n=52) mostly in femur (23%; n=32), in upper limb (34%; n=47) and in axial skeleton (28%; n=39).

110 patients had newly diagnosed tumors with diagnostic biopsy only, 28 (20%) had recurrent tumors after previous surgical procedures (+/- radiotherapy). Twenty three cases (17%) were assessed as definitively unresectable, mostly in axial location, three cases (2%) were metastatic, all other patients had locally advanced tumors with soft tissue involvement (grade 3 according to Campanacci grading system), with penetration to the joint, pathological fracture, not amenable for limb-sparing surgery or with very high risk of tumor recurrence.

Forty three pathologically cases were examined for mutation in *H3F3A* gene, all except three with positive results.

Median follow-up time was 23 months (range: 6 – 55 months).

### *Treatment outcomes in the entire group of patients*

The median denosumab treatment duration was 8 months (median number of cycles 11, range 4-57). In patients, who had not yet had surgery (or those who were considered as definitively unresectable), and continued on denosumab, the median number of denosumab doses was 20 (postoperatively few patients were treated up to 6 months). Treatment was well tolerated, only one case of osteonecrosis of the jaw was observed, which resolved with intervention and stopping denosumab therapy. In



two cases grade 3 toxicity was observed (hypophosphatemia and hypocalcemia). About 10% of patients (14) had grade II adverse events (Table II).

Ninety eight percent of patients reached clinical benefit (at least stabilization of disease) from denosumab therapy mostly in the form of the calcification of the tumor [Fig. 1]. Three patients progressed early during denosumab treatment, two of them had applied radiotherapy 6.5 and 3 years earlier and high grade sarcoma was diagnosed 3 and 7 months after treatment start, none of them was tested for *H3F3A* mutation; two of them were initially considered unresectable, one was potentially resectable but with amputation only.

In the cohort of patients with unresectable/metastatic disease no further disease progression was observed, so long-term disease control rate was 92.3%.

Two-year PFS rate in the entire group of patients (including post-surgery relapses) was 81% (95% CI 78%-91%), 3-year PFS rate was 71.4% (95% CI: 60.6%-84.1%) (Fig. 1).

#### *Treatment outcome for patients with locally advanced GCTB treated with neoadjuvant denosumab and surgery*

Eighty nine patients were treated surgically after preoperative denosumab, the characteristics of the group is presented in Table 1. The axial location consisted only small percentage of the group unlike patients with locally advanced unresectable/metastatic disease. Twenty three of 112 potentially resectable cases remained on denosumab therapy at the time of analysis and will be planned to surgery or patients did not decided for surgery yet. In this group of patients who underwent operation median number of cycles was lower than in the entire group - 8

cycles (range: 4-16). Median time on denosumab before surgery was 6 months (range: 0.5-20.8 months). Patients who underwent prosthetic replacement had longer median preoperative duration of denosumab therapy as compared to patients undergoing surgery without prosthetic implantation. 17 patients received postoperatively denosumab up to 6 months at the decision of treating medical oncologist as indicated also in the phase II Amgen 20042006 study after pathological confirmation of partial or complete response..

The majority of cases - 50 patients (56%) had intralesional curettage; 39 patients (44%) had wide en-block resection (+prosthesis replacement in 17 cases);; no extremity amputation was performed (Fig. 3,4). All patients were considered for surgical therapy after MDT decision and type of surgery was decided on the local extent of the disease and expected ability to achieve radical removal of the tumor with surgical procedure.

Relapse rate (local recurrences only) after surgical treatment in neoadjuvant denosumab cohort was in 19 of 89 (21%) patients – in 16 of 50 patients after intralesional curettage (32%), and only in 3 of 39 patients after wide excision (7.7%; none after prosthetic replacement). The relapses were more common in recurrent GCTB at denosumab start 13 of 19 patients (68%) as compared to primary tumors - 5 of 80 patients (7%). There were no differences among patients treated postoperative short-term denosumab and patients who interrupted therapy at surgery, altogether we observed disease relapses in 4 patients (23.5%) treated with adjuvant denosumab.

Thirteen patients received rescue denosumab and all responded; six underwent the second surgery.

One-year event-free survival rate was 93% in patients who underwent wide excision and 77% in patients after curettage; two-year EFS rate was 93% in patients who underwent wide excision, as compared to 55% in group of patients after curettage (Fig. 2;  $p=0.006$ ).

## Discussion

Our large multi-center series of advanced GCTB patients treated with denosumab outside clinical trials confirms that denosumab is active in both the neoadjuvant and in the unresectable/metastatic cases, and it became the standard medical therapy in multidisciplinary management of GCTB [13,15,24]. We have presented excellent activity and short-term tolerability of this drug (Fig. 3, 4). The only three of 138 cases which progressed early on denosumab may constitute misdiagnosed high grade sarcomas from the beginning as they had not confirmed *H3F3A* mutational status [25], with positive anamnesis for radiotherapy exposure in 2 cases. This data reinforced the need for expert pathologist evaluation at the diagnosis of this rare disease.

Our study comprises also the largest group of locally advanced GCTB treated in preoperative setting in combination with local surgery (Fig. 3,4, 5 suppl). The most important challenge for primary treatment of GCTB is the relatively high recurrence rate after curettage, especially when extensive soft tissue involvement by the tumor occurs (21-65%). We also have observed high disease recurrence after curettage alone – it gives real concerns about curettage after denosumab as recurrence rate was as high as might have been expected with surgery alone. On the other hand, in many of these cases curettage was not feasible before denosumab and this may constitute the benefit of denosumab in the group of patients who initially are not candidates for curettage. Nevertheless, we may suggest that if intralesional surgery is planned after neoadjuvant denosumab, drug therapy should be administered for relatively short period of time (approximately 3 months) – the calcified rim can be too thick after 3 months of denosumab precluding radical curettage of the tumor cells.

Moreover, the definitive conclusions are difficult because we have not any data from randomized study in such clinical situation.

Our data may confirm also that when wide en-bloc resection is planned, especially with prosthetic replacement, longer preoperative therapy should be considered and the fully calcified tumor can facilitate or enable radical surgery, in our series we have observed excellent local control in such clinical scenario. We have to take into account, that all these tumors were very advanced locally with large soft tissue mass, penetration into the joint and/or with pathological fracture. Of course none of these features is *per se* an indication for denosumab therapy or extended resection and even in the case of pathological fracture curettage may be a reasonable option [26,27]. Nevertheless we present here consecutive series of patients who were assessed by experienced surgeons as initially ineligible for curettage or to achieve radical tumor excision or to perform limb-sparing surgery and they were referred to bone sarcoma expert centers for these reasons. A Canadian small prospective study remains in line of our observations that denosumab facilitates less aggressive surgical treatment, especially joint preservation, although recurrence rate was considerable [28].

The question if denosumab maintenance is necessary after surgery is still open. In the cohort of the phase II clinical trial 248 patients assessed for the effect of denosumab on planned surgery with observed downstaging in 157 patients that underwent surgery or no surgery in 91 patients [29]. Many patients received adjuvant denosumab for 6 months after surgery. Nevertheless, of the 157 patients who had surgery, local recurrence occurred in 34% of patients after curettage and - similarly to our data - in low percentage of cases (12%) after wide excision. For the same

reason, in selected cases with locally advanced tumors, denosumab alone might be preferred to denosumab combined with curettage.

There are also several patients, who are definitively inoperable and will stay on denosumab therapy probably life-long. Although the tolerance of treatment was excellent, the data on the long-term use of denosumab for metastatic/unresectable GCTB are still limited [22,24]. The reduction of the frequency of administrations in patients who have achieved long-term stable disease on denosumab deserves further investigations and is subject to an European Organisation for Research and Treatment of Cancer (EORTC) study in development.

### ***Conclusions***

To summarize, denosumab therapy in GCTB is associated with a high rate of tumor control with excellent profile. Denosumab today is the gold standard medical treatment in the unresectable locally advanced or metastatic disease. Data suggest that neoadjuvant therapy with denosumab may become the option for treatment of initially locally advanced, high-risk tumors to facilitate surgical resection or avoid mutilating surgery. In cases in which we expect to perform an en-bloc surgery in a locally advanced GCTB denosumab is recommended preoperatively, but the risk of recurrences after curettage of GCTB following denosumab therapy in these high risk tumors raises the question about the optimal duration of preoperative treatment, about the indication of denosumab when intralesional surgical treatment is planned approach, and it implies a careful selection of candidates to neoadjuvant denosumab and type of surgery planning in a multidisciplinary fashion. These questions should be

answered and they are worth investigating within prospective studies, which however are unlikely to be performed in the future.

### **Acknowledgments and conflict of interest statement**

Dr Rutkowski have received honoraria and was a member of Advisory Board for Novartis, Roche, BMS, MSD, Amgen, he has received honoraria from lectures from Pfizer and he served as a member of Advisory Board for Bayer and Blueprint Medicine. Dr Stacchiotti reported that he received honoraria from Amgen and research funding to her Institution for clinical studies in which she was involved. Dr Palmerini has served on an advisory board for Amgen, Daiichi Sankyo and Lilly, and has received research support from Bristol-Myers Squibb, Pfizer and PharmaMar. Dr Gelderblom's Institution received grant from Amgen. R. Grimer was member of Advisory Board for Amgen. Dr Ferrari has received research funds from Amgen and he has participated to an advisory board organized by Amgen. The study has not received any external funding.

The study has been presented preliminary as oral presentation during Connective Tissue Oncology Society 2016 and as a poster during ASCO Annual Meeting in 2017. We thank dr Alessandro Franchi for pathological and molecular evaluation of GCTB cases from Prato, Italy.

## References

1. Thomas DM, Skubitz KM, Giant cell tumor of bone. *Curr Opin Oncol.* 2009; 21(4): 338-44.
2. Skubitz KM. Giant Cell Tumor of Bone: Current Treatment Options. *Curr Treat Options Oncol* 2014; 15:507–518
3. Campanacci M, Baldini N, Boriani S, Sudanese A. Giant-cell tumor of bone. *J Bone Joint Surg Am* 1987;69:106-114.
4. van der Heijden L, Dijkstra PD, van de Sande MA, Kroep JR, Nout RA, van Rijswijk CS, et al. The clinical approach toward giant cell tumor of bone. *Oncologist* 2014; 19(5): 550-61.
5. Athanassou NA, Bensal M, Forsyth R, et al.: Giant cell tumor of bone: IARC Press, 2013:321-324. In: WHO Classification of Tumours of Soft Tissue and Bone. Christopher D.M. Fletcher et al. Lyon, 2013
6. Hemingway F, Taylor R, Knowles HJ, Athanasou NA. RANKL-independent human osteoclast formation with APRIL, BAFF, NGF, IGF I and IGF II. *Bone* 2011;48:938–944.
7. Wu PF, Tang JY, Li KH. RANK pathway in giant cell tumor of bone: pathogenesis and therapeutic aspects. *Tumour Biol.* 2015; 36(2): 495-501.
8. Chakarun CJ, Forrester DM, Gottsegen CJ, Patel DB, White EA, Matcuk GR Jr. Giant cell tumor of bone: review, mimics, and new developments in treatment. *Radiographics* 2013; 33: 197–211.



9. Thomas DM. RANKL, denosumab, and giant cell tumor of bone. *Curr Opin Oncol.* 2012; 24: 397–403.
10. Roux S, Amazit L, Meduri G, Guiochon-Matel A, Milgrom E, Mariette X. RANK (receptor activator of nuclear factor kappa B) and RANK ligand are expressed in giant cell tumors of bone. *Am J Clin Pathol.* 2002;117:210–216.
11. Morgan T, Atkins GJ, Trivett MK, Johnson SA, Kansara M, Schlicht SL, et al. Molecular profiling of giant cell tumor of bone and the osteoclastic localization of ligand for receptor activator of nuclear factor kappaB. *Am J Pathol.* 2005;167:117–128.
12. López-Pousa A, Martín Broto J, Garrido T, Vazquez J. Giant cell tumour of bone: new treatments in development. *Clin Transl Oncol.* 2015;17(6): 419-30.
13. Gaston CL, Grimer RJ, Parry M, Stacchiotti S, Dei Tos AP, Gelderblom H, Ferrari S, Baldi GG, Jones RL, Chawla S, Casali P, LeCesne A, Blay JY, Dijkstra SP, Thomas DM, Rutkowski P. Current status and unanswered questions on the use of Denosumab in giant cell tumor of bone. *Clin Sarcoma Res.* 2016; 6(1): 15.
14. Jeys LM, Suneja R, Chami G, Grimer RJ, Carter SR, Tillman RM. Impending fractures in giant cell tumors of the distal femur: Incidence and outcome. *Int Orthop* 2006;30:135-8.
15. Jagiello-Wieczorek E, Pieńkowski A, Rutkowski P. Denosumab for treating giant cell tumor of bone. *Expert Opinion on Orphan Drugs* 2015; 3: 1219-1229.
16. Chawla S, Henshaw R, Seeger L, Choy E, Blay JY, Ferrari Sm et al. Safety and efficacy of denosumab for adults and skeletally mature adolescents with giant cell

tumour of bone: interim analysis of an open-label, parallel-group, phase 2 study.  
Lancet Oncol. 2013; 14(9): 901-8.

17. Thomas D, Henshaw R, Skubitz K, Chawla S, Staddon A, Blay JY, et al.  
Denosumab in patients with giant-cell tumour of bone: an open-label, phase 2 study.  
Lancet Oncol. 2010; 11(3): 275-80.

18. Rutkowski P, Ferrari S, Grimer RJ, Stalley PD, Dijkstra SP, Pienkowski A, et al.  
Surgical Downstaging in an Open-Label Phase II Trial of Denosumab in Patients with  
Giant Cell Tumor of Bone. Ann Surg Oncol. 2015; 22(9): 2860-8.

19. Branstetter DG, Nelson SD, Manivel JC, Blay JY, Chawla S, Thomas DM, et. al.  
Denosumab induces tumor reduction and bone formation in patients with giant-cell  
tumor of bone. Clin Cancer Res. 2012;18(16):4415-24.

20. Borkowska A, Goryń T, Pieńkowski A, Wągradzki M, Jagiełło-Wieczorek E,  
Rogala P, Szacht M, Rutkowski P. Denosumab treatment of inoperable or locally  
advanced giant cell tumor of bone. Oncol Lett 2016; 12(6):4312-4318.

21. Bukata SV, Sudan M, Mendanha W, Chawla NS, Sankhala K, Eckhardt MA, et al.  
Considerations for long-term maintenance treatment with denosumab for stable  
inoperable Giant Cell Tumor: making a case for spacing of doses after initial  
response. Connective Tissue Oncology Society 2015, abstract 047, Salt Lake City 4-  
7 November 2015.

22. Palmerini E, Chawla NS, Ferrari S, Sudan M, Picci P, Marchesi E, et al.  
Denosumab in advanced/unresectable giant cell tumor of bone (GCTB): for how  
long? Eur J Cancer 2017; 76: 118e124.

23. Eisenhauer EA, Therasse P, Bogaerts J, et al. New response evaluation criteria in solid tumours: revised RECIST guideline (version 1.1). *Eur J Cancer* 2009; 45: 228–47.
24. Palmerini E, Blay JY, Le Cesne A, Reichardt P, Rutkowski P, Gelderblom H, et al. Long-term efficacy of denosumab in giant cell tumor of bone: results of an open label phase 2 study. *Ann Oncol* 2017; 28 (suppl\_5): v605-v649. ESMO 2017 Congress; LBA56.
25. Behjati S, Tarpey PS, Presneau N, et al.: Distinct H3F3A and H3F3B driver mutations define chondroblastoma and giant cell tumor of bone. *Nat Genet.* 2013;45:1479–1482.
26. van der Heijden L, Dijkstra PD, Campanacci DA, Gibbons CL, van de Sande MA. Giant cell tumor with pathologic fracture: should we curette or resect? *Clin Orthop Relat Res.* 2013; 471(3): 820-9.
27. Salunke AA, Chen Y, Chen X, Tan JH, Singh G, Tai BC, Khin LW, Puhaindran ME. Does pathological fracture affect the rate of local recurrence in patients with a giant cell tumour of bone?: a meta-analysis. *Bone Joint J.* 2015; 97-B (11):1566-71.
28. Traub F, Singh J, Dickson BC, Leung S, Mohankumar R, Blackstein ME, Razak AR, Griffin AM, Ferguson PC, Wunder JS. Efficacy of denosumab in joint preservation for patients with giant cell tumour of the bone. *Eur J Cancer.* 2016; 59: 1-12.
29. Rutkowski P, Palmerini E, Bukata S, Vaz G, Grimer RJ, Stalley PD, et al. Surgical Outcomes and Recurrence Following Neoadjuvant Denosumab Treatment in Patients

With Resectable Giant Cell Tumor of Bone (GCTB): Results of a Phase 2 Open-  
Label Trial. Connective Tissue Oncology Society 8-11 November 2017, poster 077.

Table 1. Patient characteristics.

	<b>The entire group N=138 (%)</b>	<b>Surgically treated cohort after neoadjuvant therapy N = 89 (%)</b>
Gender		
Male	55 (40%)	35 (39%)
Female	83 (60%)	54 (61%)
Age – median (range) [years]	32 (14-81)	31 (15-70)
Primary tumor location		
Lower limb	52 (38%)	47 (52%)
Femur	32 (23%)	18 (20%)
Tibia	21 (15%)	19 (21%)
Pelvis/axial skeleton	39 (28%)	12 (13%)
Upper limb	47 (34%)	30 (34%)
Primary tumor	110 (80%)	80
Recurrent tumor (after surgery +/- radiotherapy)	28 (20%)	19
Locally advanced, potentially resectable with mutilating surgery or with high risk of	112 (81%)	89 (100%)

disease recurrence		
Localized, definitively unresectable	23 (17%)	
Metastatic	3 (2%)	
Surgical procedure after Denosumab		
Intralesional curettage		50 (56%)
Wide en-block resection [+ implantation of the prosthesis]		39 (44%) [17 (19%)]

Table 2. Adverse events during Denosumab therapy; n= 138 (%)

Osteonecrosis of jaw (resolved)	1 (0.7)
<b>Grade 3, n (%)</b>	2 (1.4)
Hypophosphatemia	1 (0.7)
Hypocalcemia	1 (0.7)
<b>Grade 2, n (%)</b>	14 (10.1)
Hypophosphatemia	6 (4.3)
Hypocalcemia	4 (2.8)
Joints pain	2 (1.4)
Osteopenia	1 (0.7)
Stress reaction	1 (0.7)

Fig. 1. Progression – free survival on denosumab therapy in the entire group of patients (including cases with post-surgery progression; from the date of start of denosumab therapy) [with 95%CI].

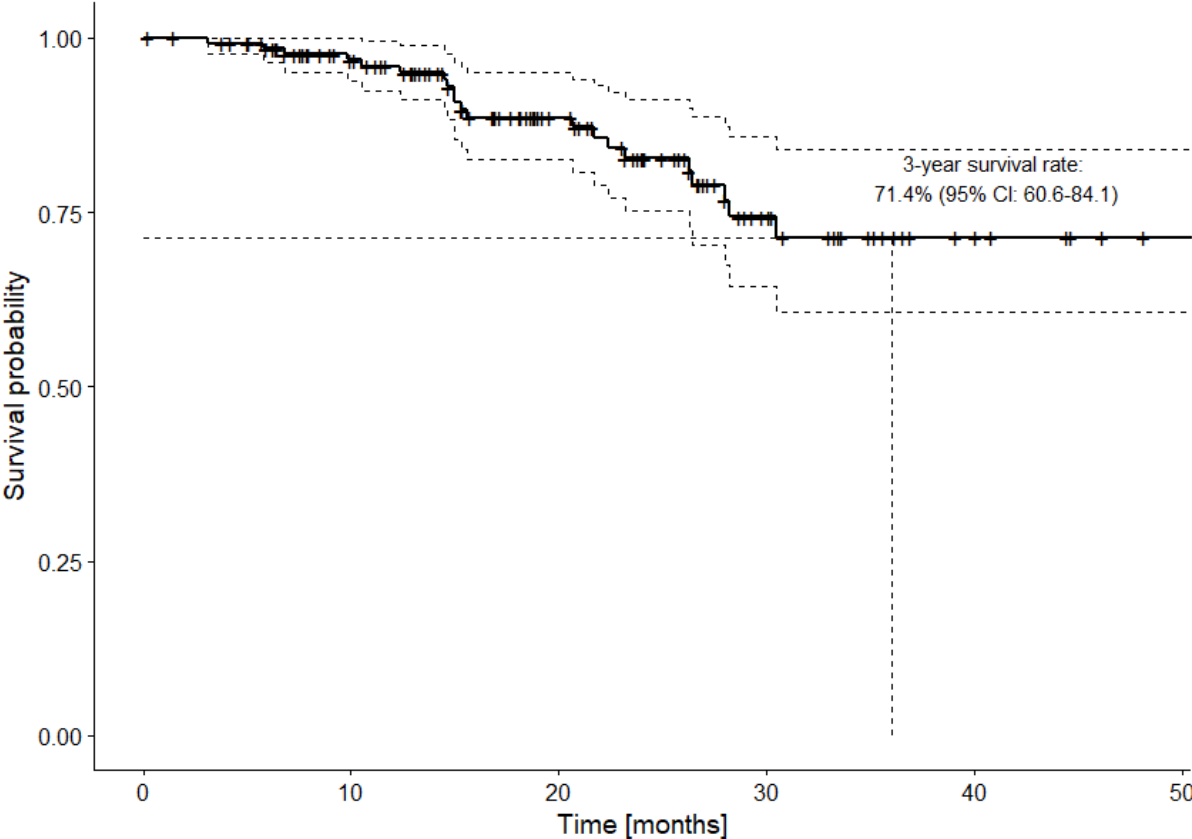




Fig. 2. EFS according to post-denosumab type of surgery (calculated from the date of surgery; p=0.006) [with 95% CI]

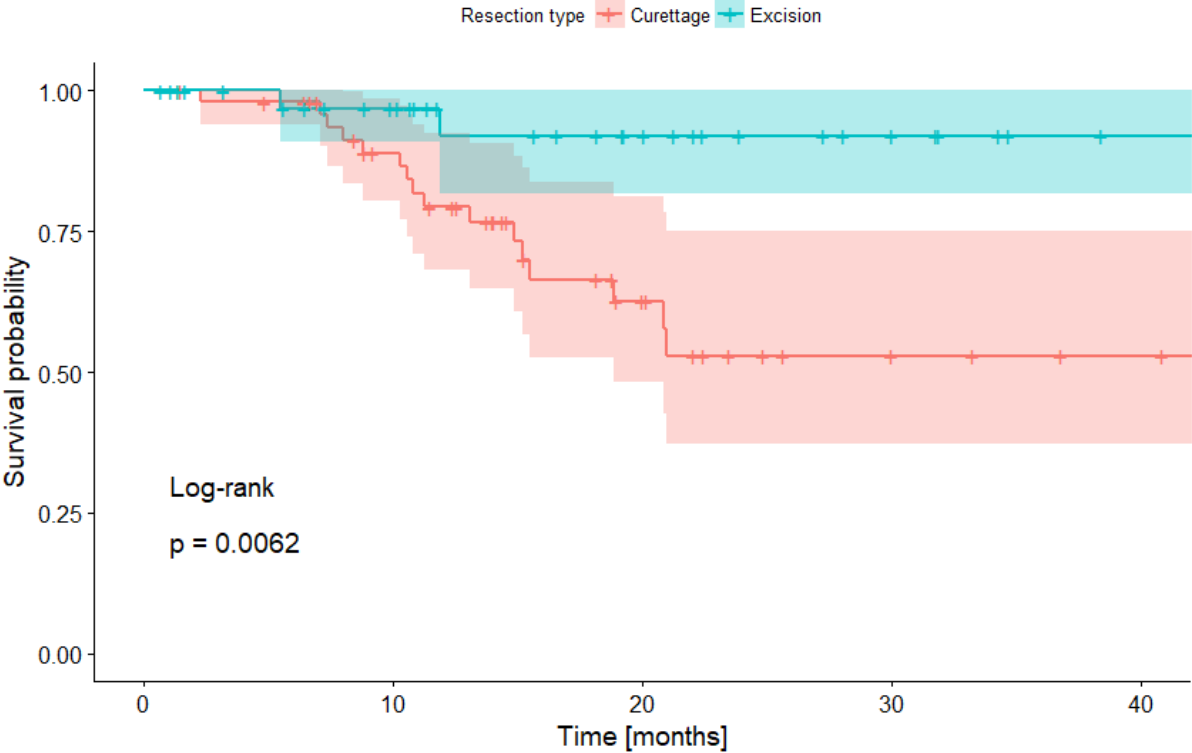


Fig. 3. Recurrent GCTB of distant radius (after curettage), X-rays: A - before denosumab therapy, B - after 12 months of therapy, C - after radical wide resection with implantation of custom-made prosthesis

A.

B.

C.

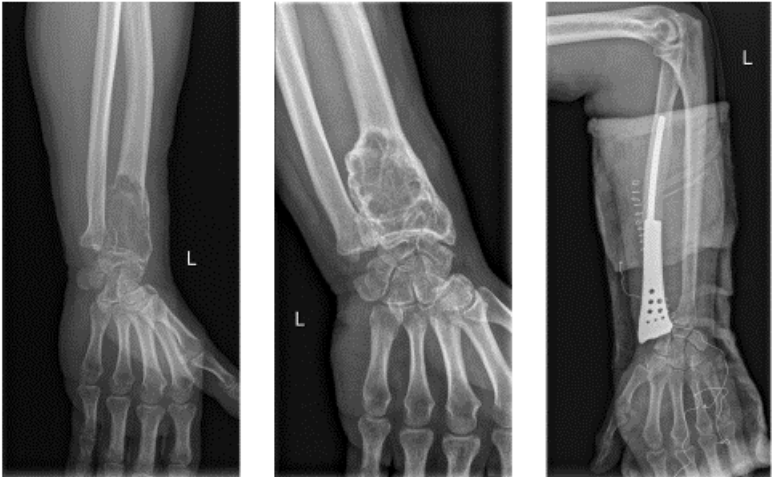


Fig. 4. Response to denosumab therapy and curettage die to GCTB of distal radius

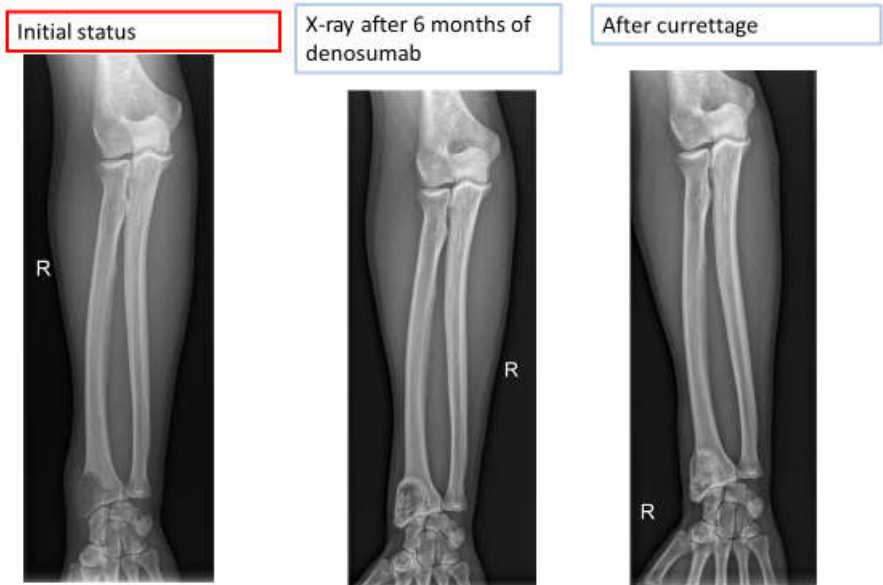
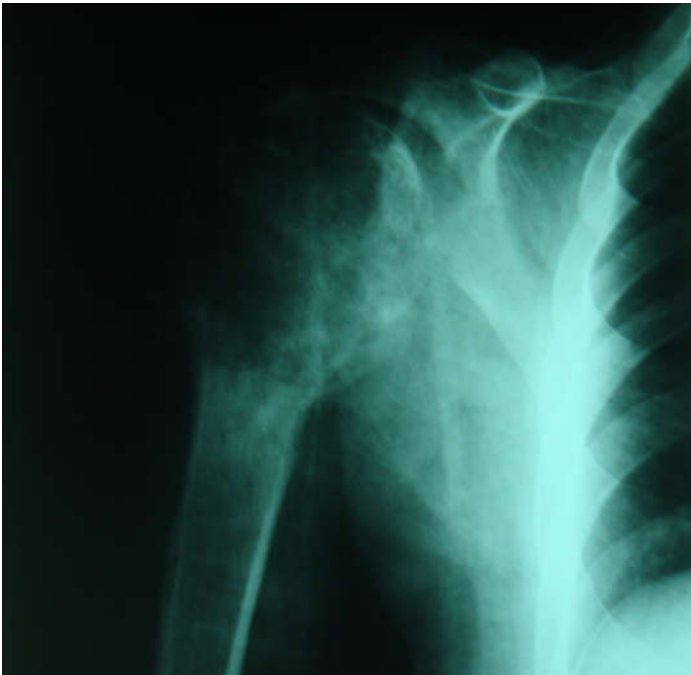
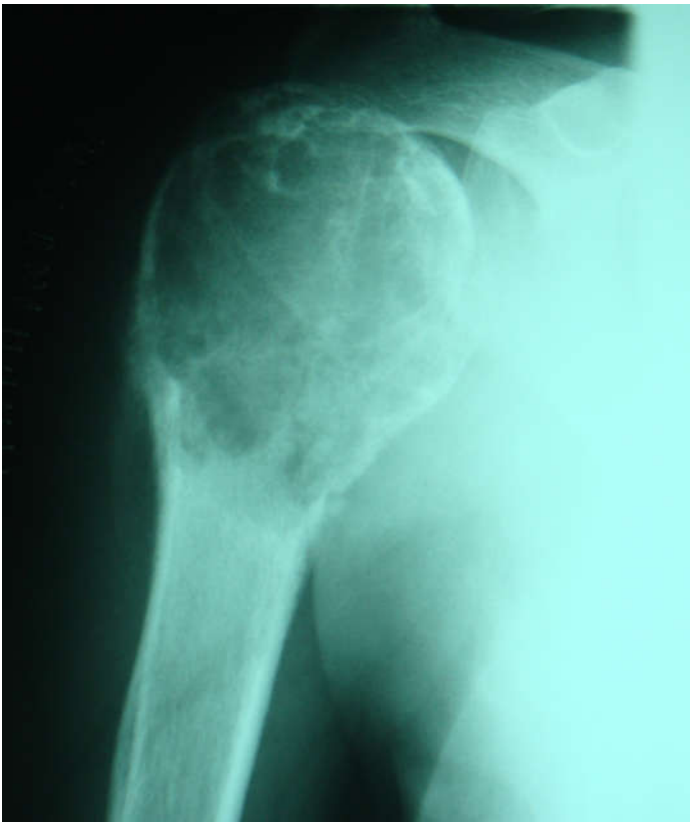

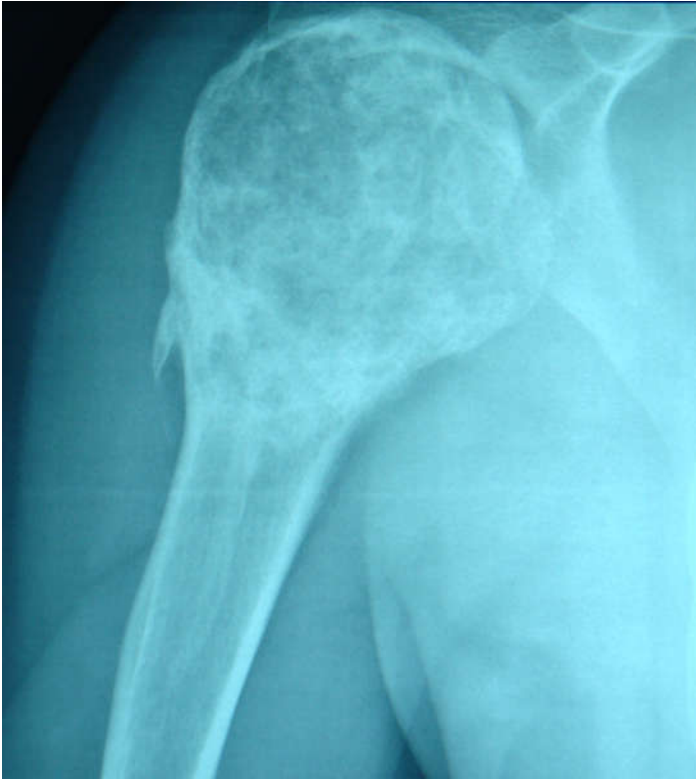Fig. 5. supplementary - X-rays demonstrating response to denosumab therapy locally advanced GCTB of proximal humerus with pathological fracture.



A. before therapy



B. after two months of therapy



C. after 6 months of therapy