

# Depressed Acne Scars—Effective, Minimal Downtime Treatment with a Novel Smooth Motion Non-Insulated Microneedle Radiofrequency Technology

Yoram Harth<sup>1,2\*</sup>, Monica Elman<sup>3</sup>, Einat Ackerman<sup>2</sup>, Ido Frank<sup>2</sup>

<sup>1</sup>Medical OR Center, Herzlyia, Israel

<sup>2</sup>EndyMed Medical, Caesarea, Israel

<sup>3</sup>Beit Harofeim, Holon, Israel

Email: \*[skin58@gmail.com](mailto:skin58@gmail.com)

Received 25 April 2014; revised 19 May 2014; accepted 25 June 2014

Copyright © 2014 by authors and Scientific Research Publishing Inc.

This work is licensed under the Creative Commons Attribution International License (CC BY).

<http://creativecommons.org/licenses/by/4.0/>



Open Access

---

## Abstract

**Background:** The microneedle fractional RF handpiece used in our study (Intensif Handpiece, EndyMed Medical, Caesarea, Israel) is a novel handpiece that uses a tip with 25 non-insulated, gold plated microneedle electrodes. The needles are inserted into the skin by a specially designed electronically controlled, smooth motion motor minimizing patient discomfort. RF emission delivered over the whole dermal portion of the needle allows effective coagulation resulting in minimal or no bleeding, together with bulk volumetric heating. **Study Design/Materials and Methods:** The study included 20 patients, treated for depressed acne scars using the Intensif™ Microneedles handpiece (EndyMed PRO Platform System, EndyMed Medical, Caesarea, Israel). The degree of clinical improvement was assessed by the global aesthetic improvement scale (GAIS) and subjects satisfaction by post treatment questionnaires. **Results:** The number of treatments per patient varied between 1 and 6 (average 3.3 treatments per patient). Eleven patients (55%) reported none to minimal pain, six (30%) moderate discomfort and only three (15%) reported significant pain. **Objective evaluation of the improvement by a board certified dermatologist showed improvement in 95% of patients. 25% showed excellent improvement, 50% experienced good improvement, and the 20% showed minimal improvement. One patient showed no improvement. Conclusions:** The presented results show that the tested electronically controlled motorized insertion, non-insulated microneedle treatment technology provides a minimal discomfort, minimal downtime, effective and safe treatment for depressed acne scars.

---

\*Corresponding author.

## Keywords

**Microneedles, Radio-Frequency, Acne Scars, RF, Multisource, Fractional Lasers, Non-Insulated**

### 1. Introduction

Acne scars are one of the most difficult disorders to treat in aesthetic dermatology. Depressed acne scars are divided into 3 categories: boxcar, ice pick and rolling scars. The pathogenesis of the scars relates most probably to thickened bands of collagen under the scars causing a retraction of skin surface. Based on the study of Zheng *et al.* that found that depressed scars may reach a depth of 0.7 mm; an effective treatment will have to reach further into the depth to remodel the retracting collagen fibers under the scar [1]. Based on these findings we may assume that the optimal treatment system for atrophic depressed scars will need to have deep volumetric dermal heating for collagen remodeling in the dermis up to at least 2.5 or 3 mm, and the ability to mechanically disrupt the dystrophic scar tissue. For the patient we will need to allow minimal discomfort, minimal downtime and minimal post treatment side effects.

Fractional ablative or non-ablative lasers are used for minimally invasive treatment of depressed. Ong *et al.* published an extensive review on these lasers found in different studies improvement range of 26 - 83 percent for ablative fractional lasers and lower (26% - 50%) for the non-ablative fractional lasers [2].


Although minimally invasive, the treatment of acne scars with fractional lasers, was accompanied by significant downtime and pain; causing prolonged erythema for up to 11.5 days after ablative fractional laser treatment and up to 7.5 days after fractional non-ablative laser treatment. Pain levels were (5.9 - 8.1) for ablative and (3.9 - 5.6) for non-ablative (on the pain scale of 10). Post inflammatory hyperpigmentation (PIH) incidence was also significant; 0% - 93% (for up to 6 months) after ablative fractional laser treatment and 0% - 13% (for up to 7.5 days) after the non-ablative fractional laser treatment.

Radiofrequency (RF) is non-ionizing electromagnetic radiation used in medicine for nearly 100 years. In contrast to most lasers that target specific chromophores, RF is chromophore-independent and has better penetration to the dermis and hypodermis as compared to light based technologies. Clinical treatment systems using radiofrequency energy (RF) were proven in the last decade to be safe and effective for both non-ablative skin tightening of the face and body, and fractional RF skin resurfacing for skin [3]-[5].

The first generation of microneedle RF delivery technology used insulated needles for skin rejuvenation and acne scars with promising results. These microneedles allowed the heating of small volume of tissue near their needle tip while the rest of the needle was insulated. With these needles the energy flows only through the tip of the needle, resulting in a small coagulated sphere-like shape in the dermis. These devices have several disadvantages, including micro-bleeding during the treatment and the need to perform several passes on the skin at different depths to affect the entire the dermis [5] [6].

Cho *et al.* described treatment of atrophic acne scars with insulated microneedle radiofrequency devices [6]. These authors used needles in which the entire needle electrode is nonconductive except the tip, (beginning 0.3 mm from the distal end) inserted to a maximum depth of 2 mm. They reported reduction of large pores in 70% of the patients treated. Skin surface roughness, dermal density, and microscopic and composite images also improved, whereas TEWL and sebum measurement did not change. Eight weeks after two sessions of treatment, the grade of acne scars improved in 22 patients (73.3%), did not change in seven (23.3%), and became aggravated in one (3.3%). The mean duration of visible erythema after treatment was  $7.8 \pm 2.6$  days. Pain persisted for longer than 1 day in 10 patients (33.3%) and for longer than 3 days in five (16.7%). Folliculitis was observed in two patients (6.7%).

The microneedle fractional RF handpiece used in our study (Intensif Handpiece, EndyMed Medical, Caesarea, Israel) is a novel FDA cleared handpiece that uses a sterile treatment tip with 25 non-insulated gold plated microneedle electrodes (max diameter of 300 micron at their base gradually tapered to an extra sharp edge) (Figure 1). Penetration depth is up to 3.5 millimeter with digitally controlled increments of 0.1 mm. Maximal power is 25 Watts with a maximal pulse duration is 200 milliseconds [7]. The needles are inserted into the skin by a specially designed, electronically controlled, smooth motion motor minimizing patient discomfort. When the needles reach the pre-defined insertion depth the RF is emitted selectively heating the dermis while sparing the epidermis. The difference in electrical impedance between the epidermis (high impedance) and the dermis (low



**Figure 1.** Left: EndyMed's Intensif Handpiece. Right: Thermal image of a treatment of laboratory skin model with impedance similar to dermal impedance (Flir Systems, ThermaCAM SC 640).

impedance) further increase selectivity—enhancing RF flow through the dermis. The RF emission delivered over the whole dermal portion of the needle allows effective coagulation resulting in minimal or no bleeding, combined with deep dermal heating.

## 2. Study Design/Materials and Methods

The study included 20 patients treated by two board certified dermatologists for depressed acne scars. We used the EndyMed PRO platform system (EndyMed medical, Caesarea, Israel) equipped with the Intensif™ micro-needle RF handpiece. Topical anesthetic cream was applied to the patient skin for 40 minutes before the fractional microneedle RF treatments. The microneedle RF collagen remodeling treatments were performed once a month, (1 to 5 sessions). Patients were photographed by a professional photography assessment system (Fotofinder Systems, Germany and Reveal Imager, Canfield Imaging systems, USA).

The degree of clinical improvement was then given a global aesthetic improvement scale for each patient by the investigator assigning an overall value for reduction in number of scars, reduction in depth of scars and improvement of color uniformity. Excellent improvement (defined as >75% improvement), very good improvement (defined as 51% - 75% improvement), good improvement (defined as 26% - 50% improvement), minimal improvement (defined as 5% - 25% improvement), and no improvement (<5%).

The score was calculated based on blinded comparative analysis of baseline picture and post treatment photographs.

Subjects' satisfaction was assessed by questionnaires that included specific questions about the treatment discomfort and downtime. Subjective assessment of was categorized to excellent, good to very good, moderate to good or none to minimal.

## 3. Results

Twenty patients, fifteen females and five males were included in the study. Treatment was performed by two different board certified dermatologist. Fitzpatrick's skin type was II-2 patients, III-11 patients, IV-5 patients and V-2 patients. Mean age was  $32.6 \pm 11.9$  years. Number of treatments varied between one and six, with an average of 3.3 treatments per patient.

Eleven patients (55%) reported none to minimal pain, six (30%) moderate discomfort and only 3 (15%) reported significant pain.

When asked about subjective improvement 19 out of 20 patients (95%) of the treated patients experienced some improvement. 25% experienced very good to excellent improvement (defined as >50% improvement) additional 30% experienced good improvement (defined as 26% - 50% improvement) and the rest reported some improvement (up to 25%). Only one patient did not notice any improvement.

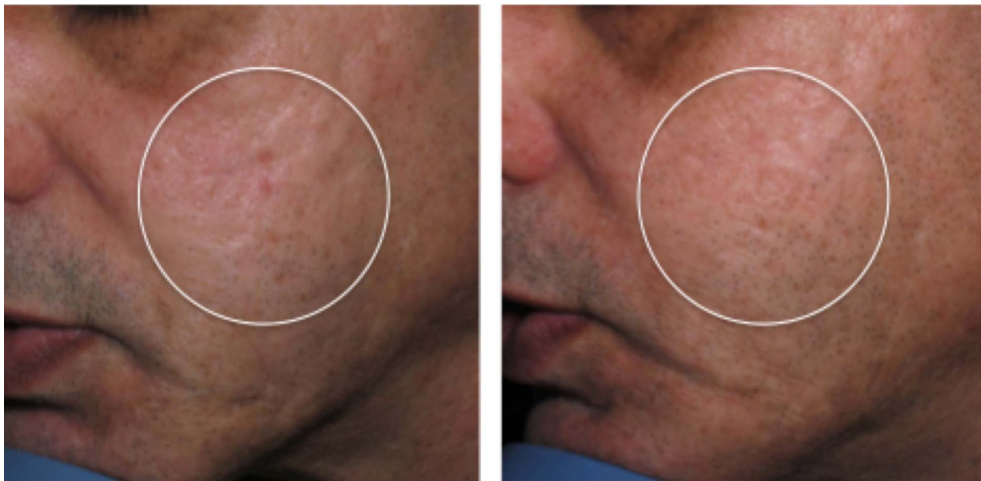
Regarding downtime: 80% of patient reported mild erythema for less than 48 hours (50% percent reported an erythema of a few hours; an additional 30% reported erythema of 1 - 2 days). The rest 20% reported erythema of 72 hours. Edema subsided in less than 24 hours for all patients.

Eighty percent of patients didn't have micro crusts or had a minimal number (up to 5). Twenty percent reported moderate number of visible micro crusts that disappeared in 4 - 5 days. Ninety percent of patients were back to normal activities in less than 48 hours. 65% in less than 24 hours, 25% needed 48 hours and 10 percent needed 72 hours.

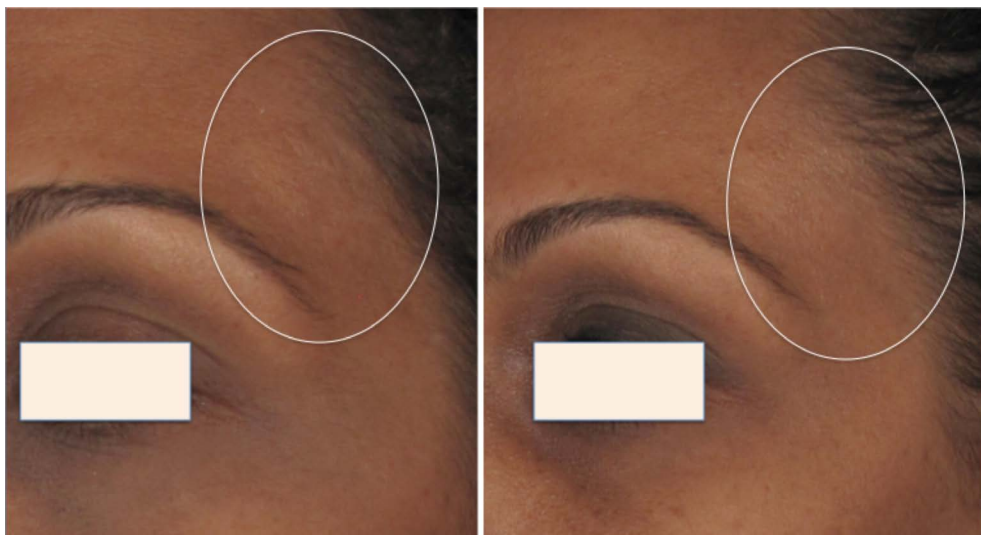No adverse events occurred during the treatments.

Seventy percent of patients said they would recommend the treatment to their friends 25% were not sure and only one patient (5%) said he would not recommend the treatment. Improvement in acne scars was noted starting at 4 weeks after the first treatment improving to a maximum at 3 months follow-up.

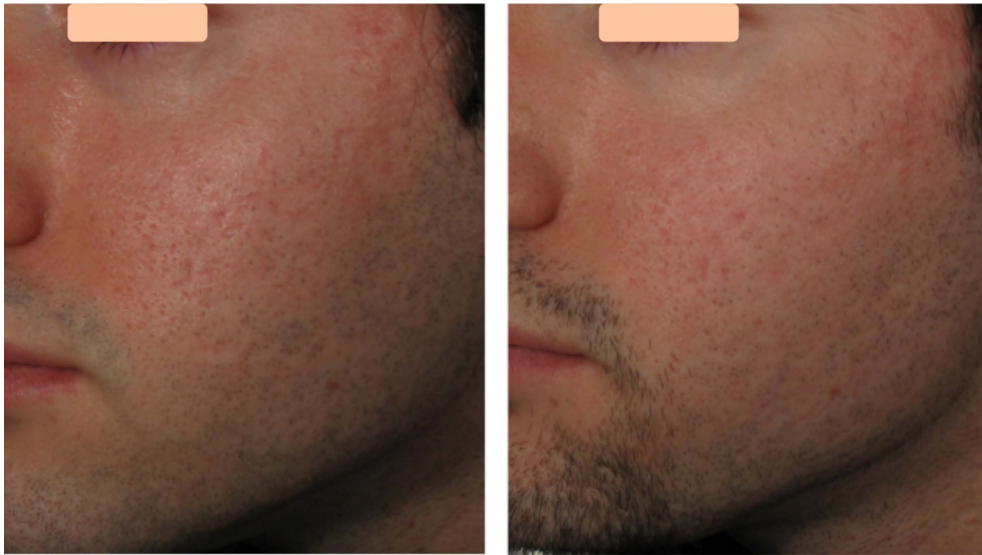
Objective evaluation of the improvement by a board certified dermatologist showed improvement in 95% of patients. 25% showed excellent improvement (defined as >75% improvement) additional 50% experienced good improvement (defined as 26% - 50% improvement) and the 20% showed minimal improvement. One patient showed no improvement. None of the patients experienced worsening in their skin condition (**Figures 2-5**).



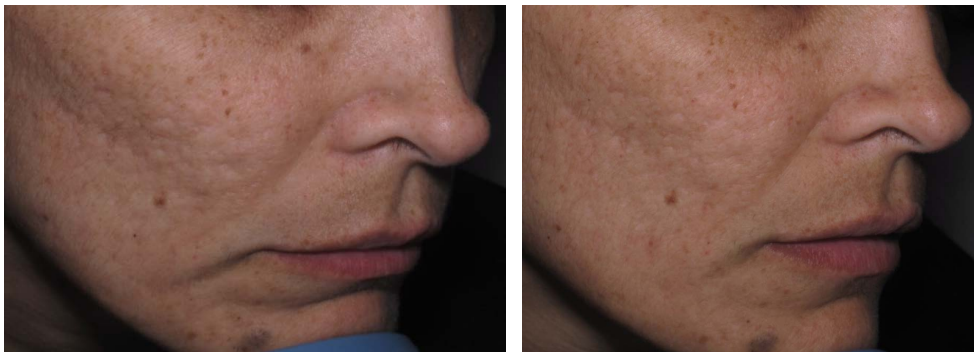**Figure 2.** Left: Baseline. Right: One month after three microneedle RF treatments sessions. Significant decrease in the depth of the scars and general texture improvement.



**Figure 3.** Left: Baseline. Right: One month after three microneedle RF treatments sessions. Significant reduction in the number and depth of the scars, with general texture improvement.



**Figure 4.** Left: Baseline. Right: One month after two microneedle RF treatments sessions. Significant texture improvement with decrease in the depth and number of atrophic and ice pick scars.



**Figure 5.** Left: Baseline. Right: One month after two microneedle RF treatments sessions. Decrease in the number and depth of the scars.

#### 4. Discussion

The current study as a few previous studies proves the efficacy and safety of the microneedles radiofrequency technology in the treatment of depressed acne scars. The efficacy seem to be in the same effectiveness range of ablative fractional lasers and somewhat higher than the non-ablative fractional lasers.

This difference can be explained by considerable higher skin penetration of the microneedles (up to 3.5 mm) vs lower penetration of fractional lasers (up to 0.7 mm) and the additional benefit of the mechanical scar disruption.

Based on recent reviews ablative fractional laser are usually associated with longer post treatment erythema and higher percentage of post inflammatory hyperpigmentation as compared to microneedle RF treatment. Pain is also more significant in ablative and non-ablative fractional lasers than in microneedle RF treatments. This fact may be explained by the ability to use topical anesthesia in microneedles RF treatments. (Not possible for some of the fractional laser procedures.)

Microneedle RF handpieces can be differentiated based on two main features. First is the mode of insertion into the skin (Fixed needles inserted manually, needles inserted mechanically using a “spring” and the latest generation using electronically controlled motorized gradual insertion). Second important differentiating feature involves the needle quality basically the sharpness and coating material.

Our study shows that motorized electronically controlled smooth insertion of the needles allows a minimal pain and downtime procedure with minimal unnecessary trauma to the epidermis and no bleeding. Unlike tech-

nologies that use fixed needles with manual insertion, where the user can't control the depth of penetration, the accurate predefined penetration depth enabled by the Intensif system, allows precise treatment for different skin thickness with high safety and efficacy.

Our data show comparable or better clinical results with lower pain level, lower downtime and lower PIH level as compared to fractional ablative or non-ablative lasers [3].

The advantage in efficacy can be explained by considerable higher skin penetration of the microneedles (up to 3.5 mm) vs lower penetration of fractional lasers (up to 0.7 mm) and the mechanical scar disruption effect of the microneedle RF devices.

The lower incidence of PIH may be explained by the difference in physical effects of light and RF. Long term PIH is believed to be caused by damage to the dermo-epidermal junction and dropping of melanin to the dermis. By definition the fractional lasers coagulate or ablate the epidermis with thermal damage to the dermal epidermal junction and upper part of the dermis. We hypothesize that the non-thermal penetration of the epidermis with the smooth motion, extra sharp microneedle is less traumatic to the epidermis and epidermal dermal junction leading to a decreased chance of PIH in microneedle RF treatments.

The reduced pain experience in microneedle RF treatment may be related to sharpness of the needles and the unique smooth needle motorized insertion.

The clinical efficacy of insulated needles is limited by the small volume of heat produced through the small non-insulated part near the tip and significant micro-bleeding through the treatment.

We believe that the use of gold plated non-insulated needles allows multiple clinical advantages over insulated and stainless steel needles. In contrast to the insulated needles that emit RF through a small area near their tip the novel non-insulated gold plated needle emit RF through the whole length allowing heating of 3× the volume. While RF is delivered when the needle is inserted to its maximal penetration and dermal impedance is lower than epidermal impedance the RF will flow through the dermis with no epidermal coagulation.

Gold plating allows better RF conductivity than stainless needles and thus better treatment efficacy. In addition, RF emission through the whole needle provides a coagulation effect eliminating micro-bleeding improving the patient experience.

Fixed microneedle RF treatment handpiece have a few disadvantages. Insertion in the skin is manual and thus more uncontrolled and more traumatic. Fixed length of needles would lead to the use of a few tip per patient which will be more costly to the doctor. This may lead to increased pain and risk of PIH. Digitally controlling the penetration depth of the needles with automatic motorized insertion allows better control of patient experience reducing discomfort and side effects.

## 5. Conclusion

This recently introduced FDA cleared non-insulated fractional RF treatment system allows controlled heating to a pre-defined depth of the dermis without epidermal coagulation. This eliminates most of the micro crusting, reduces the risk of post-inflammatory hyperpigmentation associated with epidermal injury, and allows return to normal routine after 24 hours or less. A specially designed smooth motion electronically controlled motor assures minimal trauma to the epidermis and significantly decreases discomfort to the patient. The presented results show that microneedle RF technology with electronically controlled smooth insertion motor and non-insulated gold plated needles is a safe and effective treatment option for atrophic acne scars, providing a minimally invasive, minimal discomfort and minimal downtime for all skin types. This study shows high objective and subjective satisfaction rates with minimal downtime or adverse effects.

## References

- [1] Zheng, Z., Goo, B., *et al.* (2014) Histometric Analysis of Skin-Radiofrequency Interaction Using a Fractionated Microneedle Delivery System. *Dermatologic Surgery*, **40**, 134-141. <http://dx.doi.org/10.1111/dsu.12411>
- [2] Elsaie, M.L., Choudhary, S., Leiva, A. and Nouri, K. (2010) Nonablative Radiofrequency for Skin Rejuvenation. *Dermatologic Surgery*, **36**, 577-589. <http://dx.doi.org/10.1111/j.1524-4725.2010.01510.x>
- [3] Ong, M.W. and Bashir, S.J. (2012) Fractional Laser Resurfacing for Acne Scars: A Review. *British Journal of Dermatology*, **166**, 1160-1169. <http://dx.doi.org/10.1111/j.1365-2133.2012.10870.x>
- [4] De la Torre, J.R., Moreno-Moraga, J., Muñoz, E. and Navarro, P.C. (2011) Multisource, Phase-Controlled Radiofrequency for Treatment of Skin Laxity: Correlation between Clinical and *In-Vivo* Confocal Microscopy Results and

Real-Time Thermal Changes Multisource, Phase-Controlled Radiofrequency for Treatment of Skin Laxity: Correlation between Clinical and *In-Vivo* Confocal Microscopy Results and Real-Time Thermal Changes. *Journal of Clinical and Aesthetic Dermatology*, **4**, 28-35.

- [5] Elman, M. and Harth, Y. (2011) Novel Multi-Source Phase-Controlled Radiofrequency Technology for Nonablative and Micro-Ablative Treatment of Wrinkles, Lax Skin and Acne Scars. *Laser Therapy*, **20**, 139-144. <http://dx.doi.org/10.5978/islsm.20.139>
- [6] Cho, S.I., Chung, B.Y., *et al.* (2012) Evaluation of the Clinical Efficacy of Fractional Radiofrequency Microneedle Treatment in Acne Scars and Large Facial Pores. *Dermatologic Surgery*, **38**, 1017-1024. <http://dx.doi.org/10.1111/j.1524-4725.2012.02402.x>
- [7] Harth, Y. and Frank, I. (2013) *In Vivo* Histological Evaluation of Non-Insulated Microneedle Radiofrequency Applicator with Novel Fractionated Pulse Mode. *Journal of Drugs in Dermatology*, **12**, 1430-1433.