

# Dermoscopic Examination of Nail Pigmentation

Sandra Ronger, MD, PhD; Sandrine Touzet, MD; Claire Ligeron, MD; Brigitte Balme, MD; Anne Marie Viillard, MD; Danièle Barrut, MD; Cyrille Colin, MD, PhD; Luc Thomas, MD, PhD

**Background:** Diagnosis of longitudinal melanonychia is usually difficult, and neither a single clinical criterion nor a combination of symptoms currently can be used to clearly distinguish malignant from benign bandlike pigmented nail lesions. Biopsy is painful and often leaves definitive dystrophic scars.

**Objectives:** To describe and evaluate dermoscopic patterns associated with longitudinal nail pigmentation.

**Patients and Methods:** A total of 148 unselected consecutive cases of longitudinal melanonychia were included over a period of 4 years (20 melanoma, 37 nevi, 16 drug-induced nail pigmentation, 45 nail apparatus lentigo of various types, 8 ethnic-type nail pigmentation, and 22 subungual hemorrhages). All patients were recruited from the dermatology unit outpatient clinic of the Hôtel Dieu de Lyon. All cases were photographed in vivo under oil immersion (dermoscopy). Patterns were recorded prior to final pathologic diagnosis. An independent biostatistics unit performed statistical evaluation using 7 semiologic patterns.

**Results:** Melanoma cases were significantly associated with a brown coloration of the background and the pres-

ence of irregular longitudinal lines ( $P = .001$ ). Blood spots were mostly observed in subungual hemorrhages ( $P = .001$ ); however, their presence could not rule out melanoma. Micro-Hutchinson sign was observed only in melanoma, but its rare occurrence did not allow any statistical evaluation of its specificity. Nail apparatus nevi were significantly associated with a brown coloration of the background and the presence of regular lines ( $P = .001$ ). Nail apparatus lentigo, ethnic-type pigmentation, and drug-induced pigmentation were significantly associated with homogeneous longitudinal thin gray lines and gray coloration of the background ( $P = .001$ ). Microscopic longitudinal grooves were unspecific, occurred in several conditions, and were associated with any type of unguinal discoloration.

**Conclusions:** We believe that dermoscopic examination of the nail plate in cases of longitudinal melanonychia provides useful information that could help clinicians to more accurately decide if a nail apparatus biopsy should be performed; however, histopathologic diagnosis remains the gold standard in doubtful cases.

*Arch Dermatol.* 2002;138:1327-1333

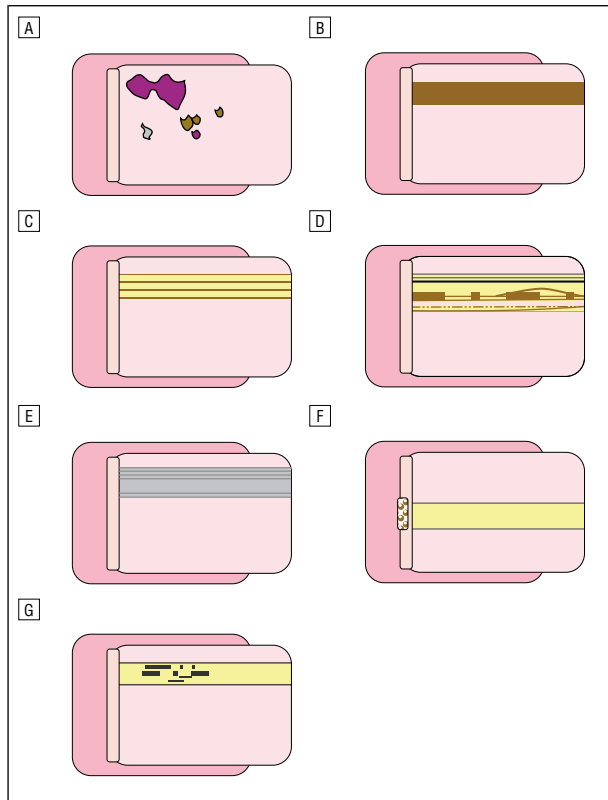
From the Dermatology Unit, Hôtel Dieu de Lyon (Drs Ronger, Ligeron, Balme, Viillard, Barrut, and Thomas), INSERM U346 (Drs Ronger and Thomas), and the Technology Assessment Unit, Department of Medical Information, Hôpitaux de Lyon (Drs Touzet and Colin), Lyon, France.

**E**ARLY DIAGNOSIS of nail apparatus melanoma in its pigmented form is difficult because several benign conditions share the same clinical features (ie, longitudinal melanonychia).<sup>1-14</sup> Several clinical criteria have been proposed to help clinicians more accurately distinguish suggestive cases,<sup>15</sup> but neither a single clinical criterion nor a combination of symptoms currently can be used to avoid numerous useless painful nail matrix biopsies that may leave dystrophic scars.<sup>16-19</sup> Longitudinal melanonychia is suggestive when it is unique, polychrome, increasing in width, or accompanied by the Hutchinson sign (pigmentation of the cuticle). Also suggestive are onset during adulthood, absence of history of pigmentation-inducing treat-

ment, and ethnic origin not usually associated with nail pigmentation. Indications of probable benign multiple lesions are phototype V or VI skin or lesions present since childhood.<sup>15</sup>

*For editorial comment  
see page 1369*

The literature on dermoscopic examination of the nails is limited to very few published observations,<sup>20-23</sup> in contrast to the large body of information available on dermoscopy of pigmented lesions elsewhere on the skin.<sup>24-27</sup> The goals of our study were to (1) systematically examine under oil immersion (dermoscopy) a large consecutive cohort of patients referred to our center for pigmented band(s) on nails;

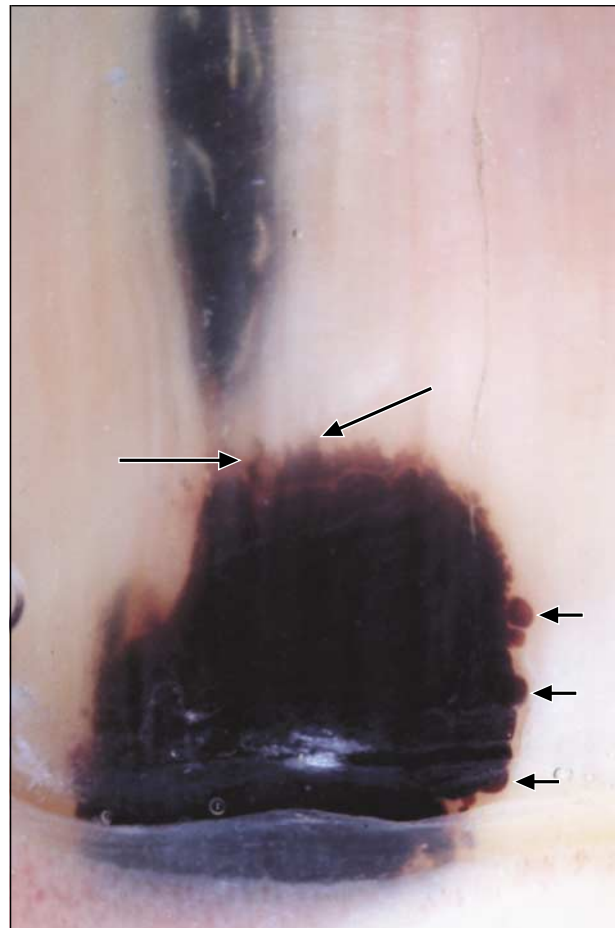


**Figure 1.** Schematic representations of the 7 dermoscopic patterns observed in longitudinal melanonychia: A, blood spots; B, brown coloration of the background; C, regular lines; D, irregular lines; E, grayish background and thin gray lines; F, micro-Hutchinson sign; and G, microscopic grooves.

(2) try to individualize relevant dermoscopic patterns; and (3) evaluate pattern correlation with 6 different etiologic diagnoses (melanoma, nevus, drug-induced nail pigmentation, nail apparatus lentigo, ethnic-type nail pigmentation, and subungual hemorrhages).

## PATIENTS AND METHODS

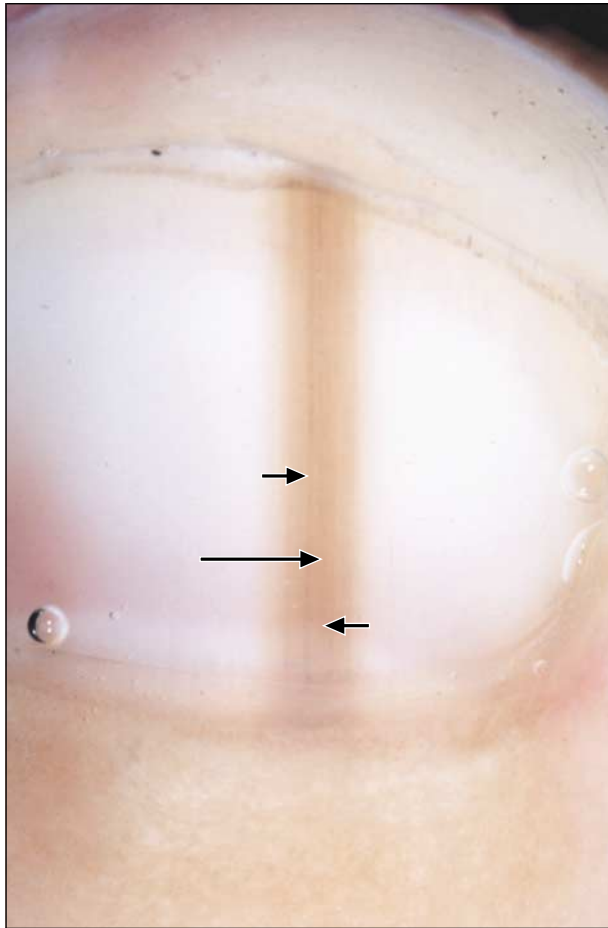
A total of 148 unselected consecutive cases of longitudinal melanonychia were included in this study over a period of 4 years (20 melanoma, 37 nevi, 16 drug-induced nail pigmentation, 45 nail apparatus lentigo of various types, 8 ethnic-type nail pigmentation, and 22 subungual hemorrhages). All patients were recruited from the dermatology unit outpatient clinic of the Hôtel Dieu de Lyon; informed consent was obtained. All cases were photographed under oil immersion with a dermoscopic camera (Heine Dermaphot, Herrshing, Germany). All pictures were taken prior to biopsy, and observed features were recorded without any knowledge of the final pathologic diagnosis. The final diagnosis was based on pathologic examination of a representative nail matrix biopsy specimen as well as records of the patient's medical history (especially pigmentation-inducing drug treatments and repetitive trauma or inflammation of the nail region), ethnic origin, total skin and mucous membrane examination (especially centered on the detection of the various types of lentiginoses such as Laugier-Hunziker disease), and postoperative evolution of the lesion with a minimum follow-up of 6 months. Twenty cases of melanoma were included (all acral lentiginous melanoma), with a mean Breslow thickness of 1.07 mm (range, 0.2-2.1 mm); 2 cases were Clark level I melanomas, all other cases were invasive. Thirty-seven cases were nail apparatus melanocytic nevi; 45 corresponded



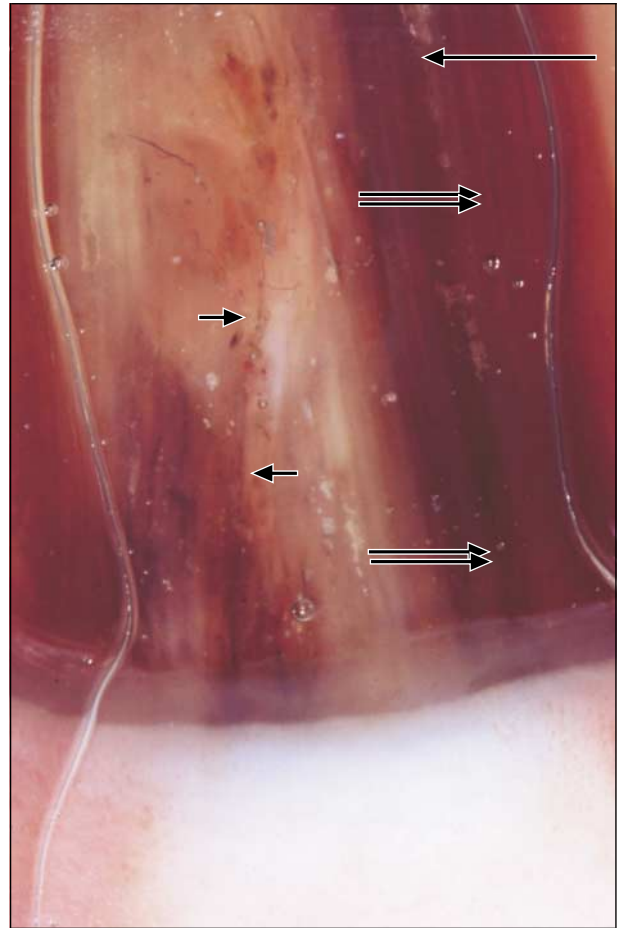
**Figure 2.** Purple to brown blood spots are seen in a subungual hemorrhage in a 67-year-old man. The proximal edge of the spot is usually rounded (short arrows), while the distal edge has a somewhat linear distortion pattern (long arrows).

to nail apparatus lentigo (among which 12 cases were part of a Laugier-Hunziker syndrome and 1 corresponded to Peutz-Jeghers-Touraine syndrome).

Previous observations allowed us to individualize 7 distinct dermoscopic features of longitudinal melanonychia (**Figure 1**). These features were recorded for all cases prior to biopsy: (1) *Blood spots* were characterized by proximally well-circumscribed dots or blotches. Their coloration varied from purple-blue in recent lesions to brown in older lesions, and the distal edge was in some cases distorted with a somewhat linear pattern, especially in older lesions (**Figure 2**). (2) *Brown coloration of the background* in the area of the clinically observed dark band varied from light to dark with sharply delimited lateral borders. The proximal border corresponded in most cases to the proximal nail plate immediately adjacent to the cuticle; the distal border corresponded to the distal edge of the nail plate (**Figures 3, 4, 5, and 6**). In most cases this background was associated with either regular or irregular lines. (3) *Regular lines*, usually associated with the brown background, displayed regularity in coloration, spacing, and thickness; no disruption in their parallelism was observed (**Figure 3**). (4) *Irregular lines* were also usually associated with a brown background and showed variations in coloration, spacing, and thickness. Some areas of disruption in parallelism were also observed (**Figures 4 and 5**). (5) *Grayish background* in the area of the clinically observed band varied from light to dark (**Figure 7**). Thin gray lines regular in coloration, thickness, and spacing were usually associated with this gray background (**Figure 8**).



**Figure 3.** Nail apparatus melanocytic nevus in an 8-year-old boy. Note the brown coloration of the background (long arrow) and the thin, darker longitudinal lines with regular thickness, spacing, and coloration (short arrows).



**Figure 4.** Nail apparatus acral lentiginous melanoma, Clark level III (1.7-mm Breslow thickness) in a 57-year-old woman. Dermoscopy disclosed a brown coloration of the background (long arrow) and darker longitudinal lines with irregular thickness, coloration, and spacing (double arrows). Disruptions of parallelism were also observed (short arrows).

(6) *Micro-Hutchinson sign* was defined by the visibility on dermoscopy of a pigmentation of the periungual tissues that could not be seen with the naked eye (Figure 6). (7) *Microscopic grooves* were observed in many cases, not always superimposed on the pigmented area. These grooves were either whitish or grayish and had a linear longitudinal disposition (**Figure 9**).

Observed features and final diagnoses were cross tabulated at the end of the study, and statistical analysis was performed by an independent biostatistics unit using the  $\chi^2$  test or, in case of a small number of recorded events, Fisher exact test (SAS software; SAS Institute, Cary, NC). Results gave significance scores for all differential diagnoses of melanoma. *P* values of .05 or lower were considered significant.

## RESULTS

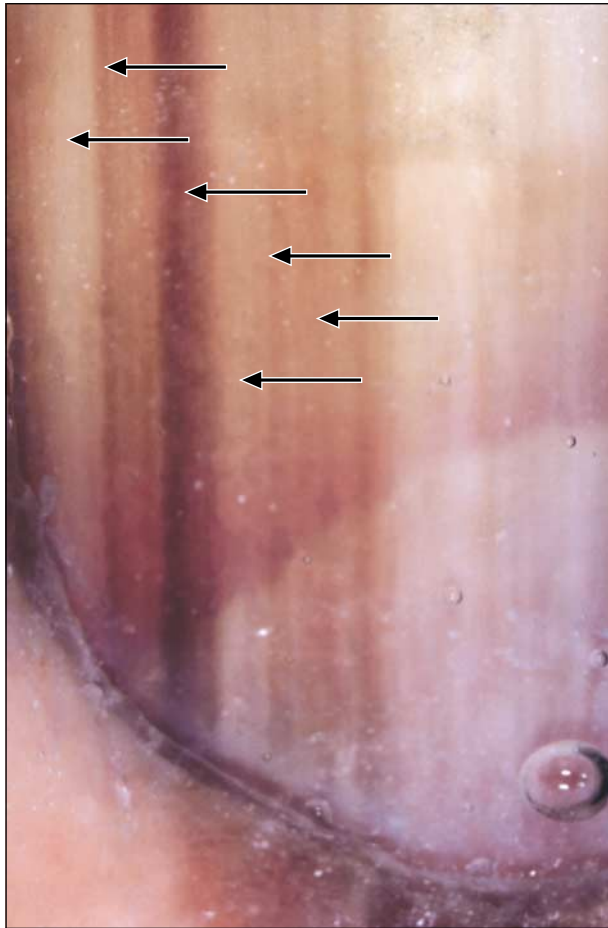
### NAIL APPARATUS MELANOMA

The results of all analyses are summarized in the **Table**. Twenty cases of nail apparatus melanoma were included in the study. Prominent dermoscopic features observed in melanoma were the association of brown pigmentation of the background (19/20; 95%) with longitudinal brown to black lines irregular in their coloration, spacing, thickness, and parallelism (19/20; 95%) (Table, Figures 1B, 1D, 4, and 5). The irregular pattern

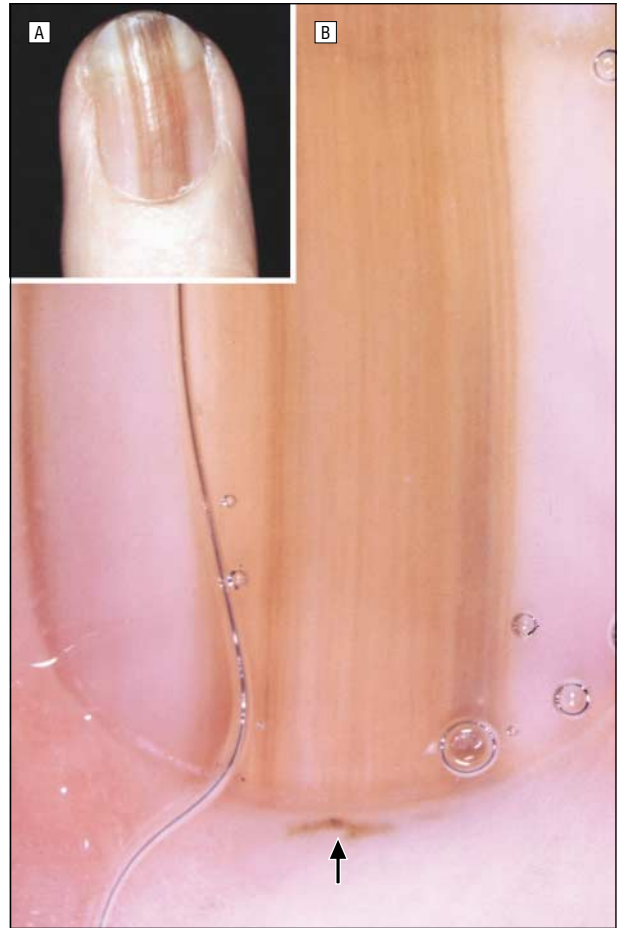of the lines was significantly associated with melanoma when compared with all other diagnoses ( $P = .001$ ) taken either individually or as a group ( $P = .001$  in all 5 differential diagnoses). Melanoma shared with melanocytic nevus the brown coloration of the background. The *micro-Hutchinson sign* as defined by the visibility of a pigmentation of the cuticle only on dermoscopy (Figure 1F and Figure 6) was observed in only 3 cases, but all were melanoma. This rare feature was also significantly associated with melanoma when compared with all other diagnoses ( $P = .001$ ). Interestingly blood spots were observed in 1 case of melanoma; their presence, therefore, cannot rule out this diagnosis.

### NAIL APPARATUS MELANOCYTIC NEVUS

Thirty-seven cases of melanocytic nevus of the nail were included in the study. Prominent observed features were the brown background (37/37; 100%) and the regular pattern of the longitudinal lines (35/37; 95%) (Figure 3). The presence of these lines, regular in their thickness, spacing, coloration, and parallelism, was found statistically sufficient to distinguish nevus from melanoma ( $P = .001$ ).



**Figure 5.** Nail apparatus acral lentiginous melanoma, Clark level II (0.9-mm Breslow thickness), in a 71-year-old man. Dermoscopy shows a brown background and longitudinal darker lines of irregular thickness, spacing, and coloration (arrows).



**Figure 6.** Nail apparatus acral lentiginous melanoma in situ, Clark level I (0.2-mm Breslow thickness), in a 72-year-old woman. A, The clinical view shows no evidence of pigment in the cuticle area; B, the dermoscopic image shows irregular lines overlying a brown background and a micro-Hutchinson sign (arrow).

### DRUG-INDUCED NAIL PIGMENTATION

Sixteen cases of drug-induced nail pigmentation were included in this study. In most cases the pigmentation was observed on several fingernails or toenails. The 3 most frequently recorded responsible drugs were zidovudine (AZT), hydroxyurea, and minocycline. The main dermoscopic features in these cases were a grayish coloration of the background (15/16; 94%) and the presence of thin longitudinal gray lines with regular thickness, spacing, coloration, and absence of parallelism disruption (Figure 7). These dermoscopic findings were not different from the ones observed in unguinal lentigo or ethnic-type pigmentation but significantly differed from melanoma ( $P = .001$ ).

### UNGUINAL LENTIGO

Forty-five cases of nail apparatus lentigo of various types were included in the study. Most cases were isolated, but 12 cases were part of a Laugier-Hunziker syndrome,<sup>28</sup> and 1 corresponded to Peutz-Jeghers-Touraine syndrome. Dermoscopic findings were similar to those observed in drug-induced pigmentation or in ethnic-type melanonychia. Prominent features were the grayish coloration of the background (44/45; 98%) and the presence of thin longitudi-

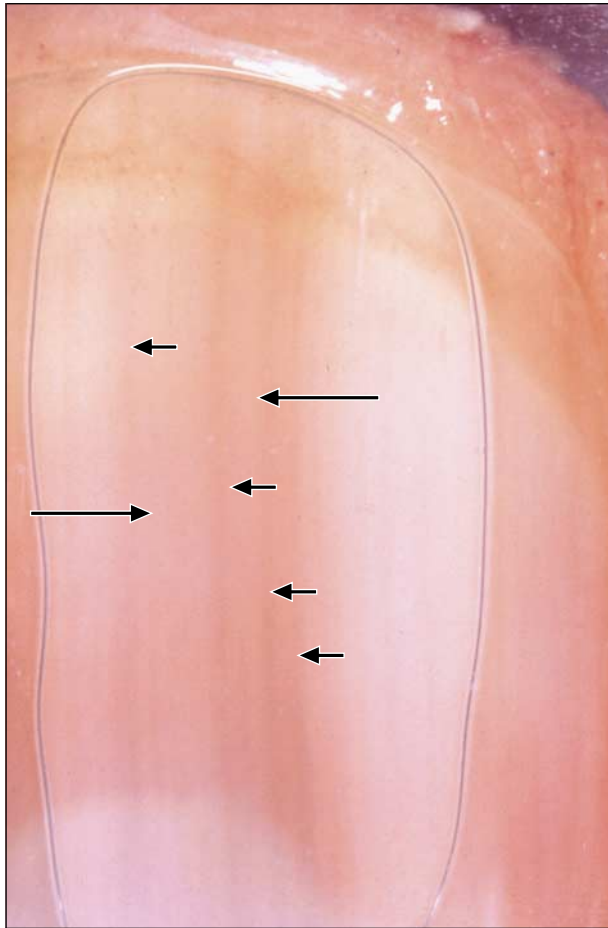
nal gray lines regular in their coloration, thickness, and spacing (42/45; 93%). The presence of these 2 criteria significantly differentiated nail lentigo from melanoma ( $P = .001$ ).

### ETHNIC-TYPE NAIL PIGMENTATION

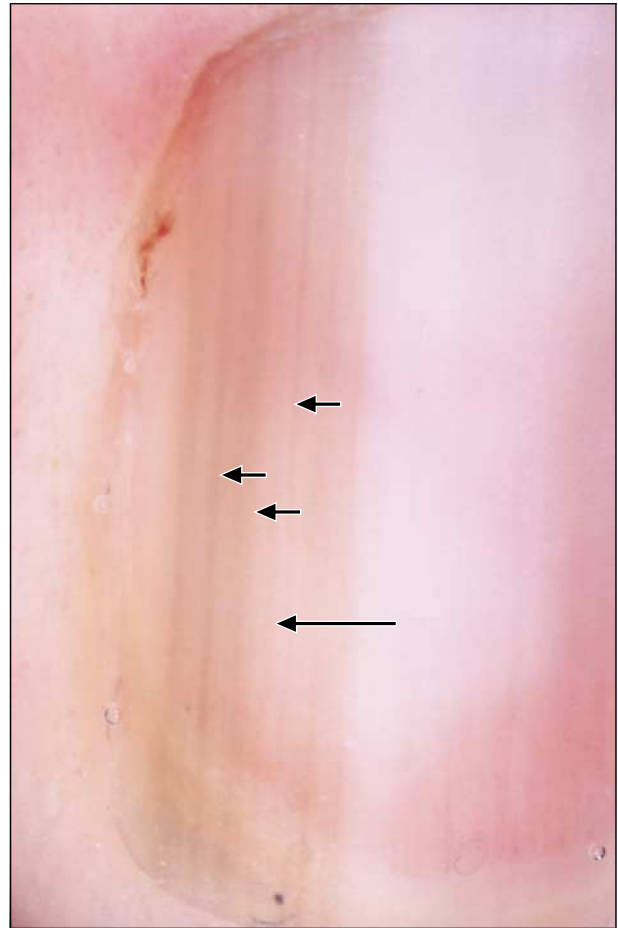
Eight cases of ethnic-type pigmentation of the nail were included in the study. In most cases the pigmented longitudinal bands were multiple on fingernails and/or toenails. The patterns in these cases were similar to those previously described in unguinal lentigo and drug-induced nail pigmentation but significantly different from those of melanoma ( $P = .001$ ). The 2 characteristic dermoscopic features of ethnic-type nail pigmentation were the grayish background (7/8; 87.5%) and the thin, regular gray lines (7/8; 87.5%).

### SUBUNGUINAL HEMORRHAGE

In the present study, 22 cases of subungual hemorrhage were included. Only cases with a longitudinal bandlike disposition of the pigmentation were included to evaluate situations in which melanoma could be included in the clinical differential diagnosis of the lesion. Blood spots characterized by a well-limited, rounded proximal edge



**Figure 7.** Hydroxyurea-induced longitudinal melanonychia in an 81-year-old man treated for chronic lymphocytic leukemia. Dermoscopy shows a grayish coloration of the background (long arrows) and thin regular longitudinal gray lines (short arrows).



**Figure 8.** Nail apparatus lentigo in a 37-year-old woman with Laugier-Hunziker disease. Dermoscopy reveals a brown coloration of the background (long arrow) and mostly regular, thin, longitudinal gray lines (short arrows).

and a purple to brown coloration were observed in all cases of subungual hemorrhages (22/22; 100%). The distal edge of older lesions showed a somewhat linear distortion that could rarely result in the formation of either regular or irregular lines. It is important to note that, even though the blood spot pattern was significantly associated with subungual hemorrhages when compared with melanoma ( $P = .001$ ), this easily recognizable pattern cannot be considered to be exclusive, and its presence is not sufficient to rule out melanoma.

#### COMMENT

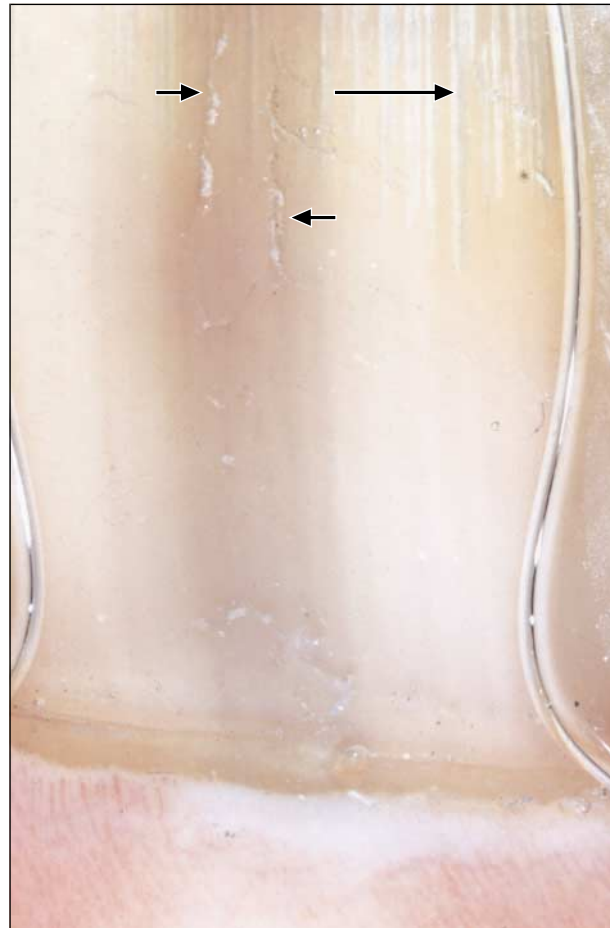Early diagnosis and treatment of melanoma hold out the only possibility of curative treatment.<sup>29-32</sup> Nail apparatus melanoma in its pigmented form is usually revealed by a longitudinal pigmentation of the nail plate or melanonychia striations.<sup>9-14</sup> This clinical presentation is common to several other diagnoses,<sup>33,34</sup> and positive diagnosis is based on histopathologic examination of a biopsy specimen of the nail matrix.<sup>35</sup> This procedure is usually painful and often followed by the creation of definitive nail dystrophy due to the surgical injury to the nail matrix.<sup>16-19</sup> Different opinions have been expressed about the management of longitudinal melanonychia.<sup>36-38</sup> Some authors recommend systematic bi-

opsy<sup>39</sup>; others propose histopathologic diagnosis in suggestive cases only.<sup>15</sup> From the clinical point of view, suggestive lesions have their onset during adulthood, are localized on only the nail, range in color from light brown to black, enlarge progressively, and are associated with a pigmentation of the eponychium called Hutchinson sign.<sup>40-44</sup> In contrast, lesions are more likely to be benign if there is a history of inflammatory disease of the nail or pigmentation-inducing drug intake, if similar lesions are found on several nails, if the onset of the lesion was in childhood,<sup>45-47</sup> if the pigmentation is regular, and if Hutchinson sign is absent.<sup>48</sup>

Dermoscopy is thought to be a useful tool in the diagnosis of skin pigmented lesions. Several algorithms have been proposed to accurately diagnose melanoma, nevi, seborrheic keratoses, pigmented basal cell carcinomas, and hemangiomas on skin.<sup>24-27</sup> Some dermoscopy studies of pigmentation of the nail have been published, but no clear attempt to establish a semiologic classification of such cases has been produced. In their textbook, Stolz et al<sup>22</sup> proposed 5 cases of dermoscopic examination of nail pigmentation. Two cases concerned subungual hemorrhages and showed features very similar to those classified as "blood spots" in the present study: the proximal edges of the spots were rounded, whereas the distal edges had a somewhat linear pattern. A third case was classified as mixed bacterial and

fungal infection. Our experience in such cases is similar, but we did not include this diagnosis in our study. The fourth case was an invasive acral lentiginous melanoma, and the observed pattern consisted of irregular lines with a brown background. The last case showed vascular changes in scleroderma, which was not the object of our work.

Johr and Izakovic<sup>21</sup> recently published a report of 4 cases of nail pigmentation observed by dermoscopy. In the first case, the longitudinal melanonychia was associated with



**Figure 9.** Ethnic-type nail pigmentation in a 42-year-old man of Gypsy lineage. Dermoscopy reveals a grayish coloration of the background and longitudinal microscopic grooves either associated (short arrows) or not (long arrow) with the pigmentation.

an epithelial inclusion cyst. No melanocytic hyperplasia was found, and the dermoscopic pattern was homogeneous and light grayish-brown, somewhat similar to the gray homogeneous pattern we observed in subungual lentigo. Their second case was an invasive acral lentiginous melanoma with a dermoscopic pattern of irregularly thick, spaced, and colored lines with a brown background. The third case was a histopathologically proven nail apparatus nevus, and the authors described a symmetrical disposition of parallel brown lines on dermoscopy. The last case corresponded to a benign possibly ethnic-type nail pigmentation with a grayish homogeneous pattern on dermoscopy. No biopsy was performed. These authors concluded that asymmetry in color and in disposition of the pigmentation suggested high-risk lesions. They proposed that dermoscopic examination be included in the clinical evaluation of longitudinal melanonychia prior to biopsy and suggested that biopsy be performed only in high-risk lesions. They also suggested that dermoscopic follow-up could help in the proper management of such cases.

Kawabata and coworkers<sup>20</sup> examined by dermoscopy 6 cases of nail apparatus melanoma and 18 cases of ungual nevi. Melanoma cases were characterized by an irregular pattern of the pigmented lines, whereas nevi showed a more regular pattern of pigmented lines. Our findings are therefore very similar to theirs regarding the pigmentation of the nail plate. These authors emphasize the semiologic value of the irregular pigmentation of the periungual tissues (Hutchinson sign) for the diagnosis of melanoma; they found this pigmentation in all 6 of their cases. However, in our cases, we could not calculate the significance score of this pigmentation because of its relative rarity. Members of our research group<sup>23</sup> recently described a distinct dermoscopic pattern with a rounded blue homogeneous coloration in a subungual blue nevus. However, this observation cannot be compared with the cases included in the present study because the lesion was not clinically characterized by a longitudinal melanonychia.

In the present study, our data indicate that brown coloration of the background is associated with prominent melanocytic hyperplasia either in subungual nevi or in melanoma. In contrast, lesions associated with mild hyperplasia of melanocytes (lentigo of various types) or hyperpigmentation of the epithelium without melanocytic hyperplasia (drug-induced or ethnic-type pigmen-

#### Cross Tabulation Between Dermoscopic Patterns and Dermatologic Diagnoses\*

Patterns	All Diagnoses			Drug-Induced Pigmentation			Ethnic-Type Pigmentation			Subungual Hemorrhages			
	Melanoma (n = 20)	but Melanoma (n = 128)	P Value	Nevus (n = 37)	P Value	Pigmentation (n = 16)	P Value	Lentigo (n = 45)	P Value	Pigmentation (n = 8)	P Value	Hemorrhages (n = 22)	P Value
Blood spots	1 (5.0)	23 (18.0)	.20	1 (2.7)	>.99	0	>.99	0	.31	0	>.99	22 (100)	.001
Brown background	19 (95.0)	40 (31.3)	.001	37 (100)	.35	1 (6.3)	.001	1 (2.2)	.001	1 (12.5)	.001	0	.001
Regular lines	1 (5.0)	35 (27.3)	.05	35 (94.6)	.001	0	>.99	0	.31	1 (12.5)	.50	1 (4.6)	>.99
Irregular lines	19 (95.0)	4 (3.1)	.001	2 (5.4)	.001	0	.001	1 (2.2)	.001	0	.001	1 (4.6)	.001
Grayish background	0	66 (51.6)	.001	0	...	15 (93.8)	.001	44 (97.8)	.001	7 (87.5)	.001	0	...
Thin regular gray lines	0	64 (50.0)	.001	0	...	15 (93.8)	.001	42 (93.3)	.001	7 (87.5)	.001	0	...
Micro-Hutchinson sign	3 (15.0)	0	.001	0	.04	0	.24	0	.03	0	.54	0	.10
Microscopic grooves	7 (35.0)	16 (12.5)	.02	4 (10.8)	.04	1 (6.3)	.05	4 (8.9)	.03	1 (12.5)	.37	6 (27.3)	.59

\*Data are number (percentage). Ellipses indicate not applicable.

tation) are characterized by a grayish coloration of the background. The most powerful criterion suggestive of melanoma was the irregularly colored, spaced, and thick pattern of the lines with areas of disruption of their parallelism. We confirmed that subungual hemorrhages are easily recognizable by their blue to black structureless blood spots with a rounded proximal edge. We would like to stress that the presence of such blood spots alone cannot rule out melanoma; the absence of other features, especially lines, must be confirmed to do that.

Our data confirm the previously expressed opinion that dermoscopy can help clinicians accurately decide if a biopsy of the nail apparatus is necessary in cases of longitudinal melanonychia. We did not demonstrate that dermoscopic follow-up of patients with nail pigmentation would be of any value, but we believe that further work should be done to clearly define criteria for high-risk lesions in cases of change in the dermoscopic pattern during follow-up.

In conclusion, our findings indicate that dermoscopy should be included in the clinical evaluation of longitudinal nail pigmentation. We believe that irregularly thick, spaced, parallel, and colored lines associated with a brown background are strongly suggestive of melanoma. We believe that careful examination under oil immersion of the nail in some cases of longitudinal melanonychia could avoid unnecessary painful surgery. Dermoscopy, of course, adds new criteria for diagnosis of unguinal pigmentation, but it does not replace histopathologic diagnosis, and biopsy should be performed in cases of doubtful lesions. Further studies are needed to evaluate the role of dermoscopic examination of the nails in the clinical follow-up of patients with nail pigmentation.

Accepted for publication April 16, 2002.

This work has been supported in part by the Institut National pour la Recherche Médicale, INSERM U346, and by research grants (appel d'offres 2000) from the Hospices Civils de Lyon (Dr Thomas), Lyon, France.

This study was presented in part at the First International Dermoscopy Meeting, Rome, Italy, February 24, 2001.

Corresponding author and reprints: Luc Thomas, MD, PhD, Dermatology Unit, Hôtel Dieu de Lyon, 69288 Lyon CEDEX 02, France (e-mail: luc.thomas@chu-lyon.fr).

## REFERENCES

- Blessing K, Kernohan NM, Park KG. Subungual malignant melanoma: clinicopathological features of 100 cases. *Histopathology*. 1991;19:425-429.
- Daly JM, Berlin R, Urmacher C. Subungual melanoma: a 25-year review of cases. *J Surg Oncol*. 1987;35:107-112.
- Fernando SS, Lauer CS. The diagnostic dilemma of subungual melanoma [letter]. *Med J Aust*. 1987;146:325.
- Finley RK III, Driscoll DL, Blumenson LE, Karakousis CP. Subungual melanoma: an eighteen-year review. *Surgery*. 1994;116:96-100.
- Haneke E, Baran R. Longitudinal melanonychia. *Dermatol Surg*. 2001;27:580-584.
- Ishihara Y, Matsumoto K, Kawachi S, Saida T. Detection of early lesions of "unguinal" malignant melanoma. *Int J Dermatol*. 1993;32:44-47.
- Kato T, Suetake T, Sugiyama Y, Tabata N, Tagami H. Epidemiology and prognosis of subungual melanoma in 34 Japanese patients. *Br J Dermatol*. 1996;134:383-387.
- O'Leary JA, Berend KR, Johnson JL, Levin LS, Seigler HF. Subungual melanoma: a review of 93 cases with identification of prognostic variables. *Clin Orthop*. 2000;378:206-212.
- Baran R, Kechijian P. Longitudinal melanonychia (melanonychia striata): diagnosis and management. *J Am Acad Dermatol*. 1989;21:1165-1175.
- Rigby HS, Briggs JC. Subungual melanoma: a clinico-pathological study of 24 cases. *Br J Plast Surg*. 1992;45:275-278.
- Saida T, Ohshima Y. Clinical and histopathologic characteristics of early lesions of subungual malignant melanoma. *Cancer*. 1989;63:556-560.
- Saida T. Heterogeneity of the site of origin of malignant melanoma in unguinal areas: "subungual" malignant melanoma may be a misnomer [letter]. *Br J Dermatol*. 1992;126:529.
- Scher RK, Silvers DN. Longitudinal melanonychia striata. *J Am Acad Dermatol*. 1991;24(6, pt 1):1035-1036.
- Tomizawa K. Early malignant melanoma manifested as longitudinal melanonychia: subungual melanoma may arise from suprabasal melanocytes. *Br J Dermatol*. 2000;143:431-434.
- Banfield CC, Dawber RP. Nail melanoma: a review of the literature with recommendations to improve patient management. *Br J Dermatol*. 1999;141:628-632.
- Baran R, Bureau H. Surgical management of some conditions in and about nails. *J Dermatol Surg*. 1976;2:308-312.
- Baran R, Sayag J. Nail biopsy: why, when, where, how? *J Dermatol Surg*. 1976;2:322-324.
- Fleegler EJ. A surgical approach to melanonychia striata. *J Dermatol Surg Oncol*. 1992;18:708-714.
- Rich P. Nail biopsy: indications and methods. *J Dermatol Surg Oncol*. 1992;18:673-682.
- Kawabata Y, Ohara K, Hino H, Tamaki K. Two kinds of Hutchinson's sign, benign and malignant. *J Am Acad Dermatol*. 2001;44:305-307.
- Johr RH, Izakovic J. Dermoscopy/ELM for the evaluation of nail-apparatus pigmentation. *Dermatol Surg*. 2001;27:315-322.
- Stolz W, Braun-Falco O, Bilek P, Landthaler M, Cognetta AB. Subungual pigmentations. In: Stolz W, Braun-Falco O, Bilek P, Landthaler M, Cognetta AB, eds. *Color Atlas of Dermoscopy*. Oxford, England: Blackwell Science Ltd; 1994:105-107.
- Causseret A, Skowron F, Viillard A, Balme B, Thomas L. Subungual blue nevus. *J Am Acad Dermatol*. In press.
- Bafounta ML, Beauchet A, Aegerter P, Saiag P. Is dermoscopy (epiluminescence microscopy) useful for the diagnosis of melanoma? results of a meta-analysis using techniques adapted to the evaluation of diagnostic tests. *Arch Dermatol*. 2001;137:1343-1350.
- Argenziano G, Soyer HP, De Giorgi V, et al. *Interactive Atlas of Dermoscopy* [book and CD-ROM]. Milan, Italy: Edra Medical Publishing and New Media; 2000.
- Argenziano G, Soyer H. Dermoscopy of pigmented skin lesions: a valuable tool for early diagnosis of melanoma. *Lancet Oncol*. 2001;2:443-449.
- Soyer H, Argenziano G, Talamini R, Chimenti S. Is dermoscopy useful for the diagnosis of melanoma? *Arch Dermatol*. 2001;137:1361-1363.
- Haneke E. Laugier-Hunziker-Baran syndrome. *Hautarzt*. 1991;42:512-515.
- Koh HK. Cutaneous melanoma. *N Engl J Med*. 1991;325:171-182.
- Thomas L, Tranchand P, Berard F, Secchi T, Colin C, Moulin G. Semiological value of ABCDE criteria in the diagnosis of cutaneous pigmented tumors. *Dermatology*. 1998;197:11-17.
- Freedberg KA, Geller AC, Miller DR, Lew RA, Koh HK. Screening for malignant melanoma: a cost-effectiveness analysis. *J Am Acad Dermatol*. 1999;41(5, pt 1):738-745.
- Koh HK, Geller AC. Public health interventions for melanoma: prevention, early detection, and education. *Hematol Oncol Clin North Am*. 1998;12:903-928.
- Shukla VK, Hughes LE. Differential diagnosis of subungual melanoma from a surgical point of view. *Br J Surg*. 1989;76:1156-1160.
- Shukla VK, Hughes LE. How common are benign subungual naevi? *Eur J Surg Oncol*. 1992;18:249-250.
- Molina D, Sanchez JL. Pigmented longitudinal bands of the nail: a clinicopathologic study. *Am J Dermatopathol*. 1995;17:539-541.
- Glat PM, Shapiro RL, Roses DF, Harris MN, Grossman JA. Management considerations for melanonychia striata and melanoma of the hand. *Hand Clin*. 1995;11:183-189.
- Glat PM, Spector JA, Roses DF, et al. The management of pigmented lesions of the nail bed. *Ann Plast Surg*. 1996;37:125-134.
- Hirsch RJ, Weinberg JM. Evaluation of pigmented lesions of the nail unit. *Cutis*. 2001;67:409-411.
- Aulicino PL, Hunter JM. Subungual melanoma—case report and literature review. *J Hand Surg Am*. 1982;7:167-169.
- Baran R, Kechijian P. Hutchinson's sign: a reappraisal. *J Am Acad Dermatol*. 1996;34:87-90.
- Kopf AW, Waldo E. Melanonychia striata. *Australas J Dermatol*. 1980;21:59-70.
- Kopf AW. Subtle clues to diagnosis by gross pathology: Hutchinson's sign of subungual malignant melanoma. *Am J Dermatopathol*. 1981;3:201-202.
- Levit EK, Kagen MH, Scher RK, Grossman M, Altman E. The ABC rule for clinical detection of subungual melanoma. *J Am Acad Dermatol*. 2000;42(2, pt 1):269-274.
- Miura S, Jimbow K. Clinical characteristics of subungual melanomas in Japan: case report and a questionnaire survey of 108 cases. *J Dermatol*. 1985;12:393-402.
- Buka R, Friedman KA, Phelps RG, Silver L, Calero F, Rudikoff D. Childhood longitudinal melanonychia: case reports and review of the literature. *Mt Sinai J Med*. 2001;68:331-335.
- Goettmann S. Pigmented lesions of the nail apparatus. *Rev Prat*. 2000;50:2246-2250.
- Goettmann-Bonvallet S, Andre J, Belaich S. Longitudinal melanonychia in children: a clinical and histopathologic study of 40 cases. *J Am Acad Dermatol*. 1999;41:17-22.
- Tosti A, Baran R, Piraccini BM, Cameli N, Fanti PA. Nail matrix nevi: a clinical and histopathologic study of twenty-two patients. *J Am Acad Dermatol*. 1996;34(5, pt 1):765-771.