



Descent of fetal head during active pushing: secondary analysis of prospective cohort study investigating ultrasound examination before operative vaginal delivery

B. H. KAHR^{1,2}, S. USMAN³, T. GHI⁴, A. YOUSSEF⁵, E. A. TORKILDSEN⁶, E. LINDTJØRN⁶, T. B. ØSTBORG⁶, S. BENEDIKTSDOTTIR^{7,8}, L. BROOKS⁹, L. HARMSSEN⁹, K. Å. SALVESEN^{1,2}, C. C. LEES³ and T. M. EGGEØ^{1,2}

¹National Center for Fetal Medicine, Trondheim University Hospital (St Olavs Hospital), Trondheim, Norway; ²Department of Clinical and Molecular Medicine, Norwegian University of Science and Technology, Trondheim, Norway; ³Centre for Fetal Care, Queen Charlotte's and Chelsea Hospital, Imperial College Healthcare NHS Trust, London, UK; ⁴Parma University Hospital, Parma, Italy; ⁵St Orsola Malpighi University Hospital, Bologna, Italy; ⁶Department of Obstetrics and Gynecology, Stavanger University Hospital, Stavanger, Norway; ⁷Department of Obstetrics and Gynecology, Clinical Sciences, Lund University, Lund, Sweden; ⁸Department of Obstetrics and Gynecology, Landspítali University Hospital, Reykjavik, Iceland; ⁹Hvidovre University Hospital, Copenhagen, Denmark

KEYWORDS: Cesarean section; duration of vacuum extraction; head–perineum distance; second stage of labor; transperineal ultrasound

CONTRIBUTION

What are the novel findings of this work?

Previous studies have shown that ultrasound examination during labor to determine fetal head station and position is more accurate than is digital vaginal examination. This study shows that measuring change in head–perineum distance using transperineal ultrasound during active pushing in women with prolonged second stage of labor provides an objective assessment of fetal head descent.

What are the clinical implications of this work?

Change in head–perineum distance measured using transperineal ultrasound during active pushing can be used to provide objective information to guide decision-making in the labor ward when prolonged second stage of labor is diagnosed.

ABSTRACT

Objectives To investigate if descent of the fetal head during active pushing is associated with duration of operative vaginal delivery, mode of delivery and neonatal outcome in nulliparous women with prolonged second stage of labor.

Methods This was a prospective cohort study of nulliparous women with prolonged second stage of labor, conducted between November 2013 and July 2016 in

five European countries. Fetal head descent was measured using transperineal ultrasound. Head–perineum distance (HPD) was measured between contractions and on maximum contraction during active pushing, and the difference between these values (Δ HPD) was calculated. The main outcome was duration of operative vaginal delivery, estimated using survival analysis to calculate hazard ratios (HRs) for vaginal delivery, with values > 1 indicating a shorter duration. HR was adjusted for prepregnancy body mass index, maternal age, induction of labor, augmentation with oxytocin and use of epidural analgesia. Pregnancies were grouped according to Δ HPD quartile, and delivery mode and neonatal outcome were compared between groups.

Results The study population comprised 204 women. Duration of vacuum extraction was shorter with increasing Δ HPD. Estimated mean duration was 10.0, 9.0, 8.8 and 7.5 min in pregnancies with Δ HPD in the first to fourth quartiles, respectively, and the adjusted HR for vaginal delivery, using increasing Δ HPD as a continuous variable, was 1.04 (95% CI, 1.01–1.08). Mean Δ HPD was 7 mm (range, –10 to 37 mm). Δ HPD was either negative or ≤ 2 mm in the lowest quartile. In this group, 7/50 (14%) pregnancies were delivered by Cesarean section, compared with 8/154 (5%) of those with Δ HPD > 2 mm ($P < 0.05$). There was no significant association between umbilical artery pH < 7.10 or 5-min Apgar score < 7 and Δ HPD quartile.

Correspondence to: Dr B. H. Kahrs, National Center for Fetal Medicine, Trondheim University Hospital (St Olavs Hospital), Trondheim, Norway (e-mail: birgitte.kahrs@me.com)

Accepted: 14 May 2019

Conclusion Minimal or no fetal head descent during active pushing was associated with longer duration of operative vaginal delivery and higher frequency of Cesarean section in nulliparous women with prolonged second stage of labor. © 2019 The Authors. *Ultrasound in Obstetrics & Gynecology* published by John Wiley & Sons Ltd on behalf of the International Society of Ultrasound in Obstetrics and Gynecology.

INTRODUCTION

Movement of the fetal head during active pushing is sometimes used as a clinical variable to inform decision-making regarding mode of delivery. Descent of the fetal head during contraction and return of the presenting part between contractions is what clinicians call the 'yo-yo-sign' and is considered to be predictive of successful vaginal delivery. However, evidence of this is not documented in obstetric scientific literature or textbooks. A study has shown that fetal head descent before vacuum extraction, determined subjectively as 'yes' or 'no', could predict outcome of vacuum extraction¹. Others have investigated the progress of labor using transperineal ultrasound and found a change in fetal head direction during contractions².

Examination of fetal head station is traditionally performed by palpation, although digital vaginal examination has been shown to be largely subjective and has poor reproducibility³. Ultrasound can be used during the active phase of labor, and the International Society of Ultrasound in Obstetrics and Gynecology (ISUOG) has recently published practical guidelines on intrapartum ultrasound. ISUOG recommends determining head position and descent using ultrasound when labor progress is slow and when operative delivery is considered⁴. Studies have shown that transabdominal ultrasound examination can give a more accurate diagnosis of fetal head position and is more reproducible than is digital vaginal examination^{5,6}. Head station can also be determined with ultrasound using different methods, such as transperineal ultrasound^{1,2,7-10}. It has been shown that women find transperineal ultrasound examination during labor less uncomfortable than they do digital vaginal examination^{11,12}. The predictive value of fetal head descent is not mentioned in guidelines with regards to assisted or operative vaginal delivery^{13,14}.

The aim of this study was to investigate if descent of the fetal head during active pushing, assessed using transperineal ultrasound, is associated with duration of operative vaginal delivery, mode of delivery and neonatal outcome in nulliparous women with prolonged second stage of labor.

METHODS

This is a secondary analysis of a multicenter cohort study of nulliparous women with slow progress in the second stage of labor at term. Duration of vacuum extraction, according to fetal head station and

rotation of the fetal head during vacuum extraction, has been reported previously^{15,16}. According to a power calculation, which was performed before the multicenter cohort study was undertaken, a study population of 220 women was needed. The main outcome of the primary study was duration of vacuum extraction, which was assessed using survival analyses. Head-perineum distance (HPD) of 25 mm corresponds to station +2 and was used to discriminate between groups. To identify a hazard ratio (HR) as low as 1.5 with 80% power, using a two-tailed test with an α -level of 5%, assuming that one-third of the women would have HPD > 25 mm and two-thirds would have HPD \leq 25 mm, and anticipating 10% censoring, 220 women needed to be included.

All included women had reassuring cardiotocography at the time of the ultrasound examination. The inclusion period was November 2013 to July 2016. Women were included at six delivery departments in five countries. The participating centers were Stavanger University Hospital, Norway; University Hospital of Bologna, Italy; Trondheim University Hospital, Norway; Queen Charlotte's and Chelsea Hospital, Imperial College Healthcare NHS Trust, UK; Lund University Hospital, Sweden; and Hvidovre University Hospital, Denmark.

Women were included when slow progress in the second stage of labor was diagnosed in accordance with local guidelines. The second stage was divided into a passive phase (< 2 h) and an active phase with pushing. The birth attendant responsible for the delivery made the diagnosis of slow progress, according to the local protocol. An ultrasound examination was performed when the woman had pushed for at least 45 min and vacuum extraction was considered. The cut-off of 45 min was chosen because Norwegian guidelines recommend that vacuum extraction should be considered after 1 h of active pushing. Fetuses were included regardless of position.

HPD was first measured between contractions and thereafter during maximum contraction with active pushing (Figure S1). Descent of the fetal head (Δ HPD) was calculated as the difference between HPD measured between contractions and HPD measured during active pushing. The main outcome was duration of operative vaginal delivery, which was estimated using survival analyses with HRs for vaginal delivery. Additionally, pregnancies were grouped according to Δ HPD quartile, and mode of delivery (vaginal delivery or Cesarean section) and neonatal outcome (pH < 7.10 in the umbilical artery and 5-min Apgar score < 7) were compared between groups.

HPD was measured as described previously^{8,15}. When measuring HPD, the woman was placed in a semirecumbent position with the legs flexed at the hips and knees at angles of 45° and 90°, respectively, ensuring that the bladder was empty. HPD was measured as the shortest distance between the outer bony limit of the fetal skull and the perineum in a transverse plane on transperineal ultrasound examination. The transducer was placed in the posterior fourchette between the labia majora, and the soft tissue was compressed with firm pressure against the pubic bone. The transducer was angled until the skull contour was as

clear as possible, which indicates that the ultrasound beam is perpendicular to the skull. HPD represents the remaining part of the birth canal through which the fetus has to pass. All ultrasound measurements were performed online in the labor room. A cineloop was used to assure that the shortest distance was measured. The birth attendants in charge of the delivery were blinded to the results of the ultrasound examination, and the ultrasound operators did not influence clinical management. The ultrasound examinations were performed by trained doctors and midwives.

The ultrasound devices used were a GE Voluson *i* (Stavanger, Trondheim, Lund, Bologna, Copenhagen) or GE Voluson S6 (Stavanger) (GE Medical Systems, Zipf, Austria). In London, a Samsung PT60A and a Samsung HM70 were used (Samsung Medison, Seoul, Republic of Korea). In Stavanger, Trondheim, Lund, London and Copenhagen, metal vacuum cups were preferred, whereas, in Bologna, Kiwi cups were used. Body mass index (BMI) was calculated from prepregnant weight and maternal height.

Cord blood was obtained by direct puncture of the umbilical artery, without cord clamping. Acid–base analysis was performed immediately after collecting the sample. The cut-off level of pH < 7.10 was used because this is known to be associated with adverse neonatal outcome^{17,18}.

The local ethics committees approved the study (reference numbers: REK 2012/1865 in Norway; 3348/2013 in Italy; REC reference 15/LO/1341 and IRAS project ID 169478 in UK; DNR 2012/808 in Sweden; and H-4-2014-038 in Denmark). All women gave written informed consent and the study was registered in Clinical Trials (identifier NCT01878591).

Statistical analysis

Cox regression analysis was used to calculate HRs as an estimate for relative risk of vaginal delivery over time in women undergoing vacuum extraction, and Δ HPD as a continuous variable was used as the test variable. HR > 1 indicates shorter survival i.e. duration of operative vaginal delivery with increasing Δ HPD. Pregnancies that underwent Cesarean section were censored at the time of the decision to perform the Cesarean section. We adjusted for prepregnancy BMI, maternal age, induction of labor, augmentation with oxytocin and use of epidural analgesia. Confounding effect was set at > 10% change in HR of the main test variable. Cox regression assumes proportional hazards, which was evaluated by log-minus-log plots.

The study population was divided according to Δ HPD quartile. Mean duration of vacuum extraction in the four quartile groups was estimated using Kaplan–Meier analysis. The associations between Δ HPD and delivery mode, 5-min Apgar score < 7 and umbilical artery pH < 7.10 were presented descriptively and compared using the chi-square test and Fisher's exact test. Data were analyzed using the statistical software package SPSS Statistics version 25.0 (IBM Corp., Armonk, NY, USA).

RESULTS

The original study population comprised 222 women. HPD at rest between contractions could be measured in all cases, and HPD during pushing was measured successfully in 204 cases. Figure 1 shows a flowchart of the study population. Forty-six women had spontaneous vaginal delivery, 143 had operative vaginal delivery (all started with vacuum extraction, but seven were converted to forceps) and 15 were delivered by Cesarean section. Table 1 shows the characteristics of the study population.

Duration of vacuum extraction was shorter with increasing Δ HPD, and the estimated mean duration of vacuum extraction was 10.0, 9.0, 8.8 and 7.5 min in pregnancies with HPD in the first to fourth quartiles, respectively. Results of the multivariable Cox regression analyses are presented in Table 2. The adjusted HR for vaginal delivery, using Δ HPD as continuous variable, was 1.04 (95% CI, 1.01–1.08). None of maternal age, BMI, use of epidural analgesia, induction of labor or augmentation with oxytocin had a confounding effect. While BMI influenced the HR for vaginal delivery (dependent variable) in the Cox regression analysis, it did not change the HR for Δ HPD (independent variable), indicating that BMI had no confounding effect on Δ HPD.

Mean HPD between contractions was 27 mm (range, 1–49 mm) and mean HPD during pushing was 20 mm (range, 0–42 mm); this difference was statistically significant ($P < 0.01$). Mean Δ HPD was 7 mm (range, –10 to 37 mm); 185 cases had a positive value, showing positive advancement of the fetal head during pushing, 13 cases had a negative value and six cases had a Δ HPD

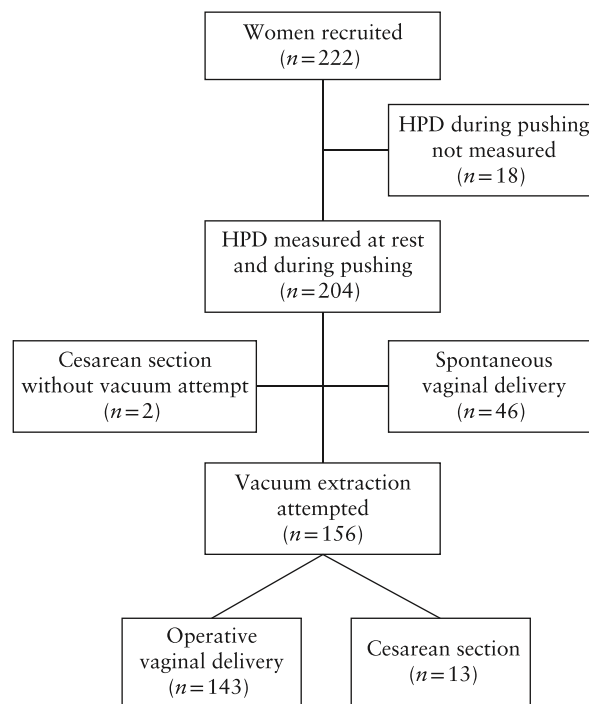


Figure 1 Flowchart summarizing inclusion and delivery outcome of study population of nulliparous women with prolonged second stage of labor. HPD, head–perineum distance.

Table 1 Characteristics of study population of 204 nulliparous women with prolonged second stage of labor

Characteristic	Value
Age (years)	30 (17–43)
Prepregnancy BMI	24 (18–39)
Gestational age (weeks)	40 (38–41)
Induction of labor	134 (66)
Epidural analgesia	162 (79)
Oxytocin augmentation	158 (78)
Birth weight (g)	3658 (2152–4930)
5-min Apgar score	10 (5–10)
Umbilical artery pH	7.24 (6.9–7.43)
Postpartum blood loss (mL)	400 (100–3400)
Third- or fourth-degree anal sphincter tear	14 (7)

Data are given as median (range) or *n* (%). BMI, body mass index.

Table 2 Cox regression analysis, showing hazard ratios (HR) for vaginal delivery in nulliparous women with slow progress in second stage of labor

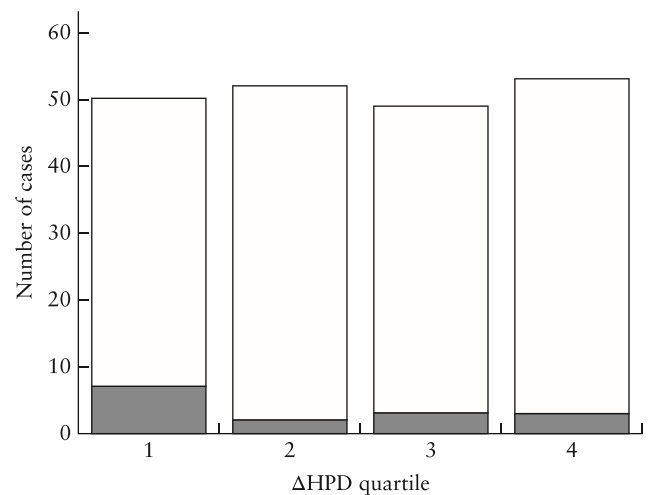
Variable	Unadjusted HR (95% CI)	Adjusted HR (95% CI)
Δ HPD*	1.04 (1.00–1.08)	1.04 (1.01–1.08)
Maternal age	0.99 (0.96–1.03)	0.99 (0.96–1.02)
Prepregnancy BMI	1.05 (1.00–1.09)	1.05 (1.01–1.10)
Epidural analgesia	0.69 (0.47–1.03)	0.76 (0.50–1.17)
Induction of labor	0.97 (0.70–1.36)	0.95 (0.65–1.14)
Oxytocin augmentation	0.75 (0.52–1.09)	0.71 (0.46–1.08)

*Change in head–perineum distance (Δ HPD) calculated as difference between HPD at rest between contractions and HPD on maximum contraction during active pushing. BMI, body mass index.

of 0 mm. We grouped pregnancies according to Δ HPD quartile and examined mode of delivery (Figure 2). Δ HPD was either negative or ≤ 2 mm in the lowest quartile. In this group, 7/50 (14%) women were delivered by Cesarean section, compared with 8/154 (5%) in pregnancies with Δ HPD > 2 mm ($P < 0.05$).

Two neonates had 5-min Apgar score < 7 . pH in the umbilical artery was analyzed in 169/204 (83%) cases. One neonate had pH < 7.0 (pH 6.90 and base excess 18) and pH < 7.10 occurred in eight cases. There was no significant association between umbilical artery pH < 7.10 or 5-min Apgar score < 7 and Δ HPD quartile.

Median duration of vacuum extraction was 8 min (range, 2–32 min). Median number of contractions during vacuum extraction was four (range, 0–14). Whether the vacuum cup detached was recorded in 150 cases; 116 had no detachments, 31 had one or two detachments and three cases had three or more detachments. Fetal position at delivery was occiput anterior in 92% and occiput posterior in 8% of cases. Dystocia was the indication for all conversions to Cesarean section. Information about the number of contractions during the extraction attempts was available in 12 of 15 pregnancies delivered by Cesarean section. Four of these cases had more than four contractions before Cesarean section was decided.

**Figure 2** Numbers of vaginal delivery (□) and Cesarean section (■) in nulliparous women with prolonged second stage of labor, according to difference between head–perineum distance (HPD) at rest between contractions and HPD on maximum contraction during active pushing (Δ HPD).

DISCUSSION

We found that a greater degree of head descent during active pushing was associated with shorter duration of operative delivery, and that increased frequency of Cesarean section was significantly associated with minimal or no fetal head descent. Δ HPD was not associated with umbilical cord pH or low 5-min Apgar score.

In 19 cases, Δ HPD had a negative value or was 0 mm. This may indicate that fetal head descent was obstructed or that the woman had an ineffective pushing technique. We believe that fetal head movement upwards in the birth canal during pushing can be explained by levator ani muscle coactivation instead of relaxation^{19,20}. The effect of coactivation on labor has been assessed recently^{21,22}. Youssef *et al.* and Kamel *et al.* examined nulliparous women at term before onset of labor and before induction of labor, respectively, and showed that women with coactivation had a significantly longer second stage of labor^{21,22}.

Fetal head descent is visible on the ultrasound screen during examination and visual biofeedback may be a future option to guide women to push more effectively. In a randomized controlled pilot study, 40 women randomized to either sonographic coaching or traditional coaching underwent a transperineal ultrasound at the beginning of the active phase of pushing²³. The sonographic coaching group observed the progress of the fetal head on the screen, while the other group did not. The sonographic coaching group had a significantly shorter second stage of labor²³. Gilboa *et al.* have shown that women who received visual biofeedback during labor had a more effective pushing technique and felt a stronger connection to the newborn after birth²⁴. The evidence level regarding pushing method is, however, low²⁵. There was no difference in maternal or neonatal outcome when comparing spontaneous and coached pushing or when

comparing delayed and immediate pushing^{25,26}. All of these studies investigated pushing at the beginning of the second stage. As we investigated pushing during prolonged second stage of labor, it is possible that women with minimal or no fetal head descent may benefit from coaching and receiving visual biofeedback by transperineal ultrasound.

Most failed operative vaginal deliveries which were converted to Cesarean section occurred in the group with no or minimal descent of the fetal head, but failed operative vaginal delivery also occurred in the other groups. In the fourth quartile, comprising pregnancies with the greatest Δ HPD values, there were three Cesarean sections, two of which had fetal occiput posterior position on ultrasound examination. Occiput posterior position is associated with a higher risk of emergency Cesarean section²⁷.

Fetal station can be measured with ultrasound using HPD⁸, angle of progression (AoP)⁷, progression distance²⁸, head–symphysis distance⁹, head direction¹ or intrapartum transperineal ultrasound (ITU) head station², and good correlation between methods has been found^{1,29,30}. Ghi *et al.* assessed progression of the fetal head using AoP from 3D volumes at the beginning of the second stage of labor and every 20 min thereafter. The results showed that women with a wide AoP had a higher incidence of spontaneous vaginal delivery³¹. Henrich *et al.* performed translabial ultrasound (another word for transperineal ultrasound³²) in women immediately before vacuum extraction¹. They assessed direction and descent of the fetal head during pushing. The head-up sign was a predictor for successful vacuum extraction in cases with protracted labor. In cases with no descent, vacuum extraction was either difficult or failed¹. This is in line with the results of the current study. Tutschek *et al.* recorded transperineal digital videos of the fetal head at rest, during contractions and during voluntary pushing. They found that, between ITU head station of -2 and $+2$, the average change in head direction was 10° during contraction, and between ITU head station of $+2$ and $+3$, there was an increased change of 18° . Time to delivery was shorter when the fetal head was below ITU head station of $+2$.

We found a significant association between Δ HPD and duration of operative delivery and failed vaginal delivery leading to Cesarean section. This is in accordance with a study in which AoP was measured in 20 women before vacuum extraction, in which it was found that a change in AoP of more than 15° predicted 73% of successful vacuum extractions³³.

Digital vaginal examination is subjective with poor reproducibility³. Position of the fetal head is determined more accurately with transabdominal ultrasound than by digital vaginal examination^{5,6}. Fetal head station can also be determined objectively using transperineal ultrasound^{8,10}. A significant advantage of ultrasound is the possibility to document the findings by adding an ultrasound image to the patient's chart. While ultrasound should not replace clinical examination, it

may add important information and may be helpful in decision-making in the labor room.

The strengths of the present study were the multicenter design, blinding of the ultrasound operators and the midwives and doctors in charge of the delivery, and inclusion of only nulliparous women with prolonged second stage of labor and no signs of fetal distress. A limitation is that only HPD was included as an ultrasound measurement in this study. AoP was measured at rest, but in only a few cases during pushing. It was difficult to measure both HPD and AoP during the same contraction and, therefore, it was not possible to calculate Δ AoP. Another limitation is that we do not have clinical evaluation of fetal head descent during pushing. Repeatability of HPD measurement was not assessed in the present study, but this has been examined previously³⁴. Additionally, umbilical cord pH was analyzed in 83% of cases as it was not measured routinely in all centers. Furthermore, we did not record if the ultrasound examination was performed by a doctor or a midwife.

In conclusion, this study shows that minimal or no fetal head descent measured using transperineal ultrasound during pushing was associated with longer duration of operative delivery and higher frequency of Cesarean section in nulliparous women with prolonged second stage of labor.

ACKNOWLEDGMENTS

We would like to thank Helen Barton for her work in recruitment for the study. We also thank Reuven Achiron for input into clinical experience of the 'yo-yo sign'.

B.H.K. is supported by The Liaison Committee for education, research and innovation in Central Norway. C.C.L. is supported by the National Institute for Health Research (NIHR) Biomedical Research Centre based at Imperial College Healthcare NHS Trust and Imperial College London. S.U. has been supported by the Helen Lawson British Medical Association Grant, Imperial Confidence in Concept grant and Imperial College Healthcare NHS Trust. The views expressed are those of the authors and not necessarily those of the NHS, the NIHR, the BMA or the Department of Health.

REFERENCES

1. Henrich W, Dudenhausen J, Fuchs I, Kamena A, Tutschek B. Intrapartum translabial ultrasound (ITU): sonographic landmarks and correlation with successful vacuum extraction. *Ultrasound Obstet Gynecol* 2006; 28: 753–760.
2. Tutschek B, Braun T, Chantraine F, Henrich W. A study of progress of labour using intrapartum translabial ultrasound, assessing head station, direction, and angle of descent. *BJOG* 2011; 118: 62–69.
3. Dupuis O, Silveira R, Zentner A, Dittmar A, Gaucherand P, Cucherat M, Redarce T, Rudigoz RC. Birth simulator: reliability of transvaginal assessment of fetal head station as defined by the American College of Obstetricians and Gynecologists classification. *Am J Obstet Gynecol* 2005; 192: 868–874.
4. Ghi T, Eggebo T, Lees C, Kalache K, Rozenberg P, Youssef A, Salomon LJ, Tutschek B. ISUOG Practice Guidelines: intrapartum ultrasound. *Ultrasound Obstet Gynecol* 2018; 52: 128–139.
5. Akmal S, Kametas N, Tsoi E, Hargreaves C, Nicolaidis KH. Comparison of transvaginal digital examination with intrapartum sonography to determine fetal head position before instrumental delivery. *Ultrasound Obstet Gynecol* 2003; 21: 437–440.

6. Ramphul M, Ooi PV, Burke G, Kennelly MM, Said SA, Montgomery AA, Murphy DJ. Instrumental delivery and ultrasound: a multicentre randomised controlled trial of ultrasound assessment of the fetal head position versus standard care as an approach to prevent morbidity at instrumental delivery. *BJOG* 2014; **121**: 1029–1038.
7. Barbera AF, Pombar X, Perugino G, Lezotte DC, Hobbins JC. A new method to assess fetal head descent in labor with transperineal ultrasound. *Ultrasound Obstet Gynecol* 2009; **33**: 313–319.
8. Eggebo TM, Gjessing LK, Heien C, Smedvig E, Okland I, Romundstad P, Salvesen KA. Prediction of labor and delivery by transperineal ultrasound in pregnancies with prelabor rupture of membranes at term. *Ultrasound Obstet Gynecol* 2006; **27**: 387–391.
9. Youssef A, Maroni E, Ragusa A, De Musso F, Salsi G, Iammarino MT, Paccapelo A, Rizzo N, Pilu G, Ghi T. Fetal head-symphysis distance: a simple and reliable ultrasound index of fetal head station in labor. *Ultrasound Obstet Gynecol* 2013; **41**: 419–424.
10. Ghi T, Farina A, Pedrazzi A, Rizzo N, Pelusi G, Pilu G. Diagnosis of station and rotation of the fetal head in the second stage of labor with intrapartum translabial ultrasound. *Ultrasound Obstet Gynecol* 2009; **33**: 331–336.
11. Usman S, Barton H, Wilhelm-Benartzi C, Lees CC. Ultrasound is better tolerated than vaginal examination in and before labour. *Aust N Z J Obstet Gynaecol* 2019; **59**: 362–366.
12. Chan YT, Ng KS, Yung WK, Lo TK, Lau WL, Leung WC. Is intrapartum translabial ultrasound examination painless? *J Matern Fetal Neonatal Med* 2016; **29**: 3276–3280.
13. Royal College of Obstetricians and Gynaecologists. Operative vaginal delivery. Green-top Guideline No 26. <https://www.rcog.org.uk/en/guidelines-research-services/guidelines/gtg26/>.
14. Wegner EK, Bernstein IM. Operative vaginal delivery. https://www.uptodate.com/contents/operative-vaginal-delivery?search=operative%20vaginal%20delivery&source=search_result&selectedTitle=1~81&usage_type=default&display_rank=1.
15. Kahrs BH, Usman S, Ghi T, Youssef A, Torkildsen EA, Lindtjorn E, Ostborg TB, Benediktsdottir S, Brooks L, Harmsen L, Romundstad PR, Salvesen KA, Lees CC, Eggebo TM. Sonographic prediction of outcome of vacuum deliveries: a multicenter, prospective cohort study. *Am J Obstet Gynecol* 2017; **217**: 69.e1–e10.
16. Kahrs BH, Usman S, Ghi T, Youssef A, Torkildsen EA, Lindtjorn E, Ostborg TB, Benediktsdottir S, Brooks L, Harmsen L, Salvesen KA, Lees CC, Eggebo TM. Fetal rotation during vacuum extractions for prolonged labor: a prospective cohort study. *Acta Obstet Gynecol Scand* 2019. DOI: 10.1111/aogs.13372.
17. Sabol BA, Caughey AB. Acidemia in neonates with a 5-minute Apgar score of 7 or greater – What are the outcomes? *Am J Obstet Gynecol* 2016; **215**: 486.e1–e6.
18. Knutzen L, Svirko E, Impey L. The significance of base deficit in acidemic term neonates. *Am J Obstet Gynecol* 2015; **213**: 373.e1–7.
19. Orno AK, Dietz HP. Levator co-activation is a significant confounder of pelvic organ descent on Valsalva maneuver. *Ultrasound Obstet Gynecol* 2007; **30**: 346–350.
20. Raimondo D, Youssef A, Mabrouk M, Del Forno S, Martelli V, Pilu G, Rizzo N, Zannoni L, Paradisi R, Seracchioli R. Pelvic floor muscle dysfunction on 3D/4D transperineal ultrasound in patients with deep infiltrating endometriosis: a pilot study. *Ultrasound Obstet Gynecol* 2017; **50**: 527–532.
21. Youssef A, Montaguti E, Dodaro MG, Kamel R, Rizzo N, Pilu G. Levator ani muscle co-activation at term is associated with a longer second stage of labor in nulliparous women. *Ultrasound Obstet Gynecol* 2019; **53**: 686–692.
22. Kamel R, Montaguti E, Nicolaidis KH, Soliman M, Dodaro MG, Negm S, Pilu G, Momtaz M, Youssef A. Contraction of the levator ani muscle during Valsalva maneuver (co-activation) is associated with a longer active second stage of labor in nulliparous women undergoing induction of labor. *Am J Obstet Gynecol* 2019; **220**: 189.e1–e8.
23. Bellussi F, Alcamisi L, Guizzardi G, Parma D, Pilu G. Traditionally vs sonographically coached pushing in second stage of labor: a pilot randomized controlled trial. *Ultrasound Obstet Gynecol* 2018; **52**: 87–90.
24. Gilboa Y, Frenkel TI, Schlesinger Y, Rousseau S, Hamiel D, Achiron R, Perlman S. Visual biofeedback using transperineal ultrasound in second stage of labor. *Ultrasound Obstet Gynecol* 2018; **52**: 91–96.
25. Lemos A, Amorim MM, Dornelas de Andrade A, de Souza AI, Cabral Filho JE, Correia JB. Pushing/bearing down methods for the second stage of labour. *Cochrane Database Syst Rev* 2015: CD009124.
26. Barasinski C, Lemery D, Vendittelli F. Do maternal pushing techniques during labour affect obstetric or neonatal outcomes? *Gynecol Obstet Fertil* 2016; **44**: 578–583.
27. Sizer AR, Nirmal DM. Occipitoposterior position: associated factors and obstetric outcome in nulliparas. *Obstet Gynecol* 2000; **96**: 749–752.
28. Dietz HP, Lanzarone V, Simpson JM. Predicting operative delivery. *Ultrasound Obstet Gynecol* 2006; **27**: 409–415.
29. Tutschek B, Torkildsen EA, Eggebo TM. Comparison between ultrasound parameters and clinical examination to assess fetal head station in labor. *Ultrasound Obstet Gynecol* 2013; **41**: 425–429.
30. Torkildsen EA, Salvesen KA, Eggebo TM. Agreement between two- and three-dimensional transperineal ultrasound methods in assessing fetal head descent in the first stage of labor. *Ultrasound Obstet Gynecol* 2012; **39**: 310–315.
31. Ghi T, Youssef A, Maroni E, Arcangeli T, De Musso F, Bellussi F, Nanni M, Giorgetta F, Morselli-Labate AM, Iammarino MT, Paccapelo A, Cariello L, Rizzo N, Pilu G. Intrapartum transperineal ultrasound assessment of fetal head progression in active second stage of labor and mode of delivery. *Ultrasound Obstet Gynecol* 2013; **41**: 430–435.
32. Salvesen KA. Ultrasound imaging of the pelvic floor: ‘What name shall be given to this Child?’ *Ultrasound Obstet Gynecol* 2006; **28**: 750–752.
33. Lau WL, Leung WC, Chin R. What is the best transperineal ultrasound parameter for predicting success of vacuum extraction? *Ultrasound Obstet Gynecol* 2009; **33**: 735; author reply 736.
34. Benediktsdottir S, Salvesen KA, Hjartardottir H, Eggebo TM. Reproducibility and acceptability of ultrasound measurements of head-perineum distance. *Acta Obstet Gynecol Scand* 2018; **97**: 97–103.

SUPPORTING INFORMATION ON THE INTERNET

The following supporting information may be found in the online version of this article:



Figure S1 Transperineal ultrasound images showing fetal head descent during active pushing.