

Detecting Awareness in the Vegetative State

Adrian M. Owen,^{1*} Martin R. Coleman,² Melanie Boly,³ Matthew H. Davis,¹ Steven Laureys,³ John D. Pickard²

The vegetative state is one of the least understood and most ethically troublesome conditions in modern medicine. The term describes a unique disorder in which patients who emerge from coma appear to be awake but show no signs of awareness. Although the diagnosis depends crucially on there being no reproducible evidence of purposeful behavior in response to external stimulation (1), recent functional neuroimaging studies have suggested that “islands” of preserved brain function may exist in a small percentage of patients who have been diagnosed as vegetative (2). On this basis, we hypothesized that this technique also may provide a means for detecting conscious awareness in patients who are assumed to be vegetative yet retain cognitive abilities that have evaded detection using standard clinical methods.

In July 2005, a 23-year-old woman sustained a severe traumatic brain injury as a result of a road traffic accident. Five months later, she remained unresponsive with preserved sleep-wake cycles. Clinical assessment by a multidisciplinary team concluded that she fulfilled all of the criteria for a diagnosis of vegetative state according to international guidelines (1) [Supporting Online Material (SOM) text].

We used functional magnetic resonance imaging (fMRI) to measure her neural responses during the presentation of spoken sentences (e.g., “There was milk and sugar in his coffee”), which were compared with responses to acoustically matched noise sequences (3). Speech-specific activity was observed bilaterally in the middle and superior temporal gyri, equivalent to that observed in healthy volunteers listening to the same stimuli (fig. S1). Furthermore, sentences that contained ambiguous words (italicized) (e.g., “The *creak* came

from a *beam* in the *ceiling*”) produced an additional significant response in a left inferior frontal region, similar to that observed for normal volunteers. This increased activity for ambiguous sentences reflects the operation of semantic processes that are critical for speech comprehension.

An appropriate neural response to the meaning of spoken sentences, although suggestive, is not unequivocal evidence that a person is consciously aware. For example, many studies of implicit learning and priming, as well as studies of learning during anesthesia and sleep, have demonstrated that aspects of human cognition, including speech perception and semantic processing, can go on in the absence of conscious awareness.

To address this question of conscious awareness, we conducted a second fMRI study during which the patient was given spoken instructions to perform two mental imagery tasks at specific points during the scan (3). One task involved imagining playing a game of tennis and the other involved imagining visiting all of the rooms of her house, starting from the front door. During the periods that she was asked to

imagine playing tennis, significant activity was observed in the supplementary motor area (Fig. 1). In contrast, when she was asked to imagine walking through her home, significant activity was observed in the parahippocampal gyrus, the posterior parietal cortex, and the lateral premotor cortex (Fig. 1). Her neural responses were indistinguishable from those observed in healthy volunteers (fig. S2) performing the same imagery tasks in the scanner (SOM text).

These results confirm that, despite fulfilling the clinical criteria for a diagnosis of vegetative state, this patient retained the ability to understand spoken commands and to respond to them through her brain activity, rather than through speech or movement. Moreover, her decision to cooperate with the authors by imagining particular tasks when asked to do so represents a clear act of intention, which confirmed beyond any doubt that she was consciously aware of herself and her surroundings. Of course, negative findings in such patients cannot be used as evidence for lack of awareness, because false negative findings in functional neuroimaging studies are common, even in healthy volunteers. However, in the case described here, the presence of reproducible and robust task-dependent responses to command without the need for any practice or training suggests a method by which some non-communicative patients, including those diagnosed as vegetative, minimally conscious, or locked in, may be able to use their residual cognitive capabilities to communicate their thoughts to those around them by modulating their own neural activity.

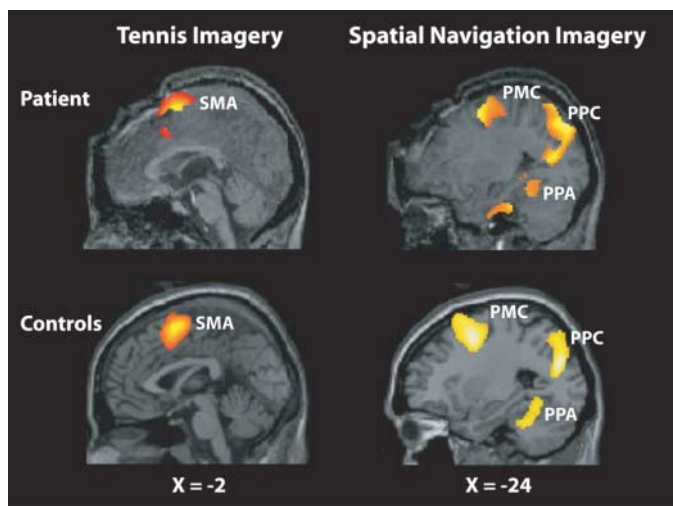


Fig. 1. We observed supplementary motor area (SMA) activity during tennis imagery in the patient and a group of 12 healthy volunteers (controls). We detected parahippocampal gyrus (PPA), posterior parietal-lobe (PPC), and lateral premotor cortex (PMC) activity while the patient and the same group of volunteers imagined moving around a house. All results are thresholded at $P < 0.05$ corrected for multiple comparisons. X values refer to distance in mm from the midline in stereotaxic space (SOM text).

References and Notes

- Royal College of Physicians, *The Vegetative State: Guidance on Diagnosis and Management* (Report of a Working Party, Royal College of Physicians, London, 2003).
- N. D. Schiff *et al.*, *Brain* **125**, 1210 (2002).
- Materials and methods are available as supporting material on *Science Online*.
- We thank D. Badwan, T. Bekinschtein, J. Rodd, J. Outtrim, D. Chatfield, D. Menon, I. Johnsrude, V. Lupson, R. Barker, J. Grahn, C. Frith, P. Maquet, the Cambridge Impaired Consciousness Research Group, and the staff of the Wellcome Trust Research Facility for their contributions. Funded by MRC program grant G9439390 ID 56833, the Smiths Charity, the Belgian Fonds National de la Recherche Scientifique, and the Mind Science Foundation.

Supporting Online Material

www.sciencemag.org/cgi/content/full/313/5792/1402/DC1

Materials and Methods

SOM Text

Figs. S1 and S2

References

19 May 2006; accepted 17 July 2006

10.1126/science.1130197

¹Medical Research Council Cognition and Brain Sciences Unit, Cambridge CB2 2EF, UK. ²Division of Academic Neurosurgery, Addenbrooke's Hospital and Wolfson Brain Imaging Centre, University of Cambridge, Cambridge CB2 2QQ, UK. ³Cyclotron Research Centre and Neurology Department, University of Liège, 4000 Liège, Belgium.

*To whom correspondence should be addressed. E-mail: adrian.owen@mrc-cbu.cam.ac.uk