

Detection of Oral Tumor based on Marker – Controlled Watershed Algorithm

K. Anuradha
Research Scholar, Karpagam University
Coimbatore

K.Sankaranarayanan
Phd, Dean, Electrical Sciences
Easa College of Engineering and Technology
Coimbatore

ABSTRACT

Oral cancer is a significant health problem throughout the world. It is very important to detect such types of cancer at an earlier stage than the later stage where the treatment becomes unsuccessful. Early detection helps surgeons to provide necessary therapeutic measures which also benefit the patients. In this paper, a technique is proposed to detect cancers present in mouth provided by an Orthopantomogram. A novel mathematical morphological watershed algorithm is proposed to preserve these edge details as well as prominent ones to identify tumors in dental radiographs. Applying watershed on images leads to oversegmentation even though it is preprocessed. To avoid this, Marker Controlled Watershed segmentation is used to segment tumors. The results obtained are quite good and were tested.

Keywords:

Orthopantomogram, Oversegmentation, Marker controlled watershed segmentation.

1. INTRODUCTION

Oral cancer is the 11th most common human neoplasm in the world as well as a complex disease arising in various organs, including tongue, buccal, hypopharynx, oropharynx, gum, palate, lips, and the floor of the mouth. Cancer of the oropharynx is a major cause of cancer-related death all over the world, exceeding the annual death rates for cervical cancer and malignant melanoma. Despite advances in surgery, radiation and chemotherapy, the mortality rate associated with oral cancer has no improvement in the last 40 years. Eventually, 50 percent of people who have oral cancer die as a result of the malignancy. Early evaluation of oral precancerous lesions can have a dramatic impact on oral cancer mortality rates [1]. Tumors that arise from odontogenic (tooth forming) tissues are referred to as Odontogenic tumors. Tumors are either benign or malignant. Malignant tumors are cancerous. Oral cancer can affect any area of the oral cavity including the lips, gum tissues, tongue, cheek lining and the hard and soft palate. This paper focuses on detecting oral cancers at an earlier stage. Oral cancers are every now and then located on the tongue, Magnetic Resonance (MR) images may become blurry because of moving artifacts induced by the moving tongue and jaw. So an efficient image processing algorithm is very much required to identify the suspicious region in the cancer area with high accuracy. Precancers and early stage oral cancers cannot be adequately identified by visual inspection alone and may be overlooked and neglected [1]. Orthopantomograms are the Dental Panoramic Radiographs which helps to identify problems with teeth, mouth and jaw. Dental radiographs are used for screening oral pathologies continuously and it is often a difficult task to detect early stage cancer tissues in a dental radiograph. Unlike other types of cancers, oral cancers are visibly seen with the naked eye, some cancers are located internally in the mouth,

making their detection difficult. And also, some non cancerous tissues are not harmful.

Over the years, Image Processing techniques have been successfully applied on dental radiographic images to extract useful information for biomedical applications.

The rest of the paper is organized as follows: Section 2 gives the related study of the literature survey. Section 3 and 4 gives a description about the methodology of the proposed work. Results and Conclusion are given in sections 5 and 6 respectively.

2. LITERATURE SURVEY

Oral cancer was not known before the advent of cigarette smoking. It was not even recognized as a serious disease until there was a major death rate. Many studies have been carried out that deal with Orthopantomogram image analysis. Different Techniques are presented in their papers.

Banumathi.A et.al [2] have proposed cyst detection and severity measurement of cysts using image processing techniques and neural network methods. The suspicious cyst regions are diagnosed using Radial Basis Function Network. The severity of the cysts is calculated using circularity values and the results show the part of the cysts extracted [2]. Woonggyu Jung et al [3] proposed a technique in oral cancer detection using Optical Coherence Tomography (OCT). For the imaging depth of 2-3 mm, OCT is suitable for oral mucosa. They also detected oral cancer in 3-D volume images of normal and precancerous lesions [3]. Ranjan Rashmi Paul et al [4] proposed a detection methodology to detect oral cancer using wavelet - neural networks. The wavelet coefficients of Transmission Electron Microscopy (TEM) images of collagen fibers from normal oral sub mucosa and Oral Sub mucous Fibrosis (OSF) tissues have been used in order to choose the feature vector which in, turn used to train the Artificial Neural Network. The trained network could classify the normal and precancerous stages after getting the image as an input [4]. Ghassan Hamarneh et al [5] have proposed the application of active contour models for the segmentation of oral lesions in medical color images acquired from the visual part of the light spectrum. The proposed work also classifies cancerous and non – cancerous lesions. The automatic segmentation algorithm simplifies the analysis of oral lesions and can be used in clinical practice to detect potentially cancerous lesions [5]. K. V. Kulhalli et al [6] have designed a computer aided diagnostic system using Image Processing and Artificial Neural Network (ANN). Features are extracted from the histopathological image which is used to train the ANN, to identify whether it is benign and malignant [6]. Tathagata Ray et al [7] compared Hybrid Segmentation Algorithm and Region Growing Algorithm to detect the constituent layers of histological OSF. The misclassification is compared with the algorithms. The

method presented provides an automatic means of segmenting histological layers [7].

3. METHODOLOGY

Image processing is one of the challenging and most growing research areas in the medical field. Here we present an approach that detects the tumor from the oral image. The block diagram of the proposed methodology and the input image is obtained and digitized are shown respectively in Figure 1 and Figure 2.

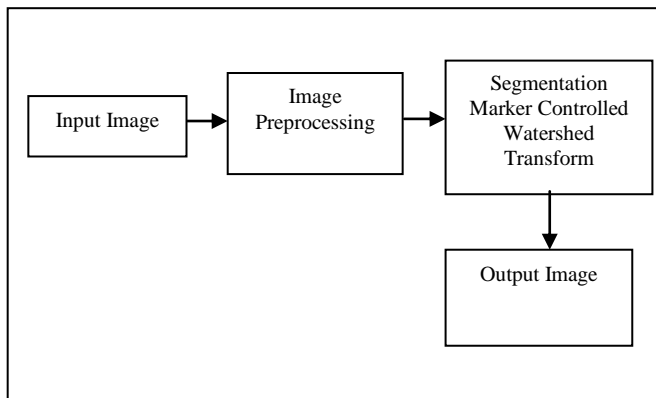


Figure 1. Block Diagram of the proposed methodology

Initially, an input image is taken and then enhanced using Linear Contrast Stretching. After enhancing the image, the image is filtered. Then, a segmentation algorithm is applied to segment the desired part of the image and detect the tumor, if found. To segment the image, Marker controlled watershed segmentation is applied. After segmentation of abnormal region using Marker – controlled watershed, a series of morphological operations have been applied.

3.1 Image Preprocessing

In the Image Preprocessing stage, Image enhancement is done to improve the interpretability or perception of information in images for human viewers, or to provide 'better' input for other automated image processing techniques. The input image (Figure 2) is preprocessed by increasing the gray levels in the image using linear contrast stretching.

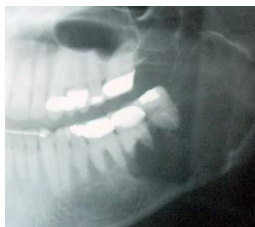

Figure 2. Input Image

Preprocessing of an image improves the appearance of an image and makes it easier for visual interpretation, understanding, and analysis. In this work, preprocessing is carried out by Linear contrast stretching of the input dental radiograph image. Since the histogram of dental radiographs is not covering the complete dynamic range, the contrast stretching method enhances the edges of the region of interest better. The enhanced image is shown in Figure. 3

3.2 Image Segmentation

Image segmentation is an essential process for most image analysis techniques. Segmentation subdivides an image into its constituent parts. Segmentation algorithms are based on one of the two properties of intensity values, namely discontinuity and similarity. First category is to partition an image based on abrupt changes in intensity, such as edges in an image, Second category are based on partitioning an image into regions that are similar according to a predefined criteria. Histogram, Thresholding approach falls under this category. As watershed transformation suffers from over segmentation, Marker controlled watershed segmentation is used in this work.

4. MARKER CONTROLLED WATERSHED ALGORITHM

The watershed transformation has been widely used in many fields of Image Processing, including medical image segmentation due to the number of advantages that it possesses: it is a simple, intuitive method, it is fast and can be parallelized and it produces a complete division of the image in separated regions even if the contrast is poor, thus avoiding the need for any kind of contour joining. Furthermore, several researchers have proposed techniques to embed the watershed transformation in a multiscale framework. The watershed transformation finds "catchment basins" and "watershed ridge lines" in an image by treating it as a surface where light pixels are high and dark pixels are low. The enhanced image (Figure. 3) is segmented by using the watershed segmentation first. The image shown in Figure 4 is the output after watershed segmentation. The strength of watershed segmentation is that it produces a unique solution for a particular image, and it can be easily adapted to any kind of digital grid and extended to n -dimensional images and graphs. However, the noise in the image results in oversegmentation. Lack of smoothness is the disadvantage for the watershed segmentation. It is not an efficient idea to treat the watershed segmentation as the final segmentation. So, a new approach is necessary to overcome these difficulties. The Marker – Controlled watershed segmentation solves all the problems faced by the previous segmentation algorithm. The Marker based watershed segmentation can segment unique boundaries from an image or stack of images, however it has no smoothing or generalization properties [8].

The principle of the immersion – based watershed algorithm by Soille et al [9] can be illustrated by imagining the gradient image of the (smoothed) original image as a relief, with the 'height' variable being the grey – value for each pixel position. Segmentation using the watershed transforms works well if the foreground objects and background locations are identified or marked.

The Algorithm steps for Marker – Controlled Watershed segmentation are as follows:

1. Compute a segmentation function. This is an image whose dark regions are the objects to be segmented.
2. Compute foreground Markers. These are connected blobs of pixels within each of the objects.
3. Compute background Markers. These are pixels that are not part of any object.
4. Modify the segmentation function so that it only has minima at the foreground and background Marker locations.

5. Compute the watershed transform of the modified segmentation function.

Marker – driven watershed segmentation extracts seeds indicating the presence of objects or background at specific image locations [10]. The Marker locations are then set to be regional minima within the topological surface. Every time the water reaches a minimum, which corresponds to a region in the original image, a catchment basin is ‘grown’. When two neighboring catchment basins eventually meet, a dam is created to avoid the water spilling from one basin into the other. When the water reaches the maximum grey- value, the edges of the union of all dams form the watershed segmentation [11]. The segmented image is shown in Figure 5.

5. RESULTS AND DISCUSSION

The proposed method of segmentation has been applied to the input image. The results of various phases are shown below:

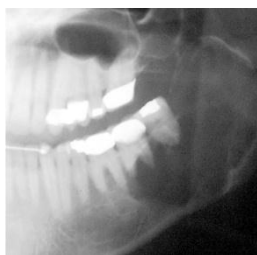
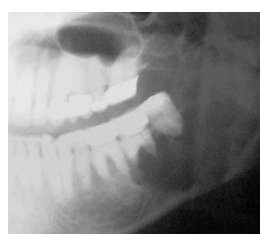
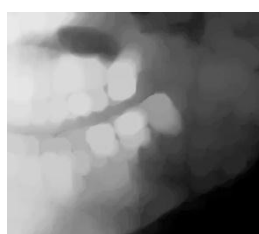
Figure 3. Enhanced Image

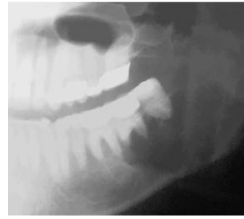Figure 4. Image after Watershed algorithm

The input image (Figure 2) is enhanced using linear contrast stretching which is shown in Figure 3. After preprocessing, watershed segmentation is applied to the image (Figure 3). The image after watershed segmentation is shown in Figure 4. Figure 4 leads to over segmentation. Due to that, Marker – controlled watershed segmentation is applied to the image shown in Figure 3. And the segmentation results are shown in Figure 5.



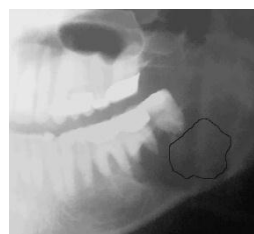(a)

(b)



(c)

(d)



(e)



(f)

Figure 5. (a), (b), (c), (d), (e) Marker – Controller watershed Segmentation results (f) shows tumor area

The output image (e) shows the tumor part with less blurring and noise.

Table. 1 shows the segmentation method assessment for Watershed segmentation and Marker controlled watershed transformation. From the results obtained, assessment is carried out through the metrics, Speed and Accuracy.

Speed is the Time taken to process the image. It can be calculated using:

$$\text{Average Speed} = \frac{100 - (\text{Initial Input Time} - \text{Final process Time})}{60} \text{ in seconds.}$$

Accuracy is calculated from:

$$\text{Accuracy} = \frac{\text{TN} + \text{TP}}{\text{TN} + \text{TP} + \text{FN} + \text{FP}}$$

where TN – Number of True Negative, which predicts Benign as Benign

FN – Number of False Negative, which predicts malignant as benign

TP – Number of True Positives, which predicts malignant as malignant

FP – Number of False Positives, which predicts benign as malignant.

Table 1. Comparison of algorithms

No. of cases: 10

Segmentation algorithm	Accuracy	Speed
Watershed segmentation	85.20%	91%
Marker controlled watershed segmentation	90.25%	92.55%

The comparison chart is shown in Figure 6.

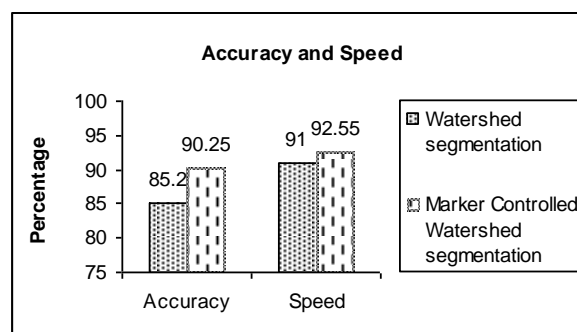


Figure 6. Comparison Chart

According to the experimental subjective assessment in the segmentation stage, Marker controlled watershed segmentation algorithm (with 90.25% Accuracy and 92.55% Speed) is better than Watershed segmentation (with 85.20% Accuracy and 91% Speed). So, Marker Controlled Watershed segmentation has achieved comparatively good results than Watershed algorithm.

6. CONCLUSION AND FUTURE WORK

In this proposed work, the dental X – ray image is captured and the series of operations to enhance the quality of the image and detection of tumor is performed. In this approach the quality of the image is enhanced using linear contrast stretching. After that watershed transformation is used to segment the image. Due to the problem of over segmentation, Marker controlled watershed transformation is used. After this the result image is compared with the source image to check the image quality and the tumor area.

The problem here is to differentiate benign and malignant tumors. The suspected malignant tumor cases have to undergo biopsy. The accuracy obtained is 90.25%. In future it is proposed to increase more number of cases to achieve 99% accuracy.

7. ACKNOWLEDGEMENT

Authors express their sincere thanks to Dr. T. P. Swamy, MDS, Anna Orthodontic Centre, Coimbatore and to the Management and Staff of Karpagam College of Engineering for their constant support and Motivation.

8. REFERENCES

- [1] James J. Sciubba, “Improving detection of precancerous and cancerous oral lesions”, American Dental Association, Vol. 130, October 1999, pp 1445 – 1457.
- [2] A. Banumathi, J. Praylin Mallika, S. Raju, V. Abhai Kumar, “Automated Diagnosis and Severity Measurement of cyst in dental X – ray images using Neural Network”, International Journal of Biomedical Soft Computing and Human Sciences, Vol.14, No.2, 2009, pp 103 – 107.
- [3] Woonggyu Jung, Jun Zhang, Junrae Chung, Petra Wilder – Smith, Matt Brenner, J. Stuart Nelson and Zhongping Chen, (2005) “Advances in Oral Cancer Detection using Optical Coherence Tomography”, IEEE Journal of Selected Topics in Quantum Electronics, Vol. 11, No.4.pp 811 – 817.
- [4] Ranjan Rashmi Paul, Anirban Mukherjee, Pranab K. Dutta, Swapna Banerjee, Mousumi, Pal, Jyotirmoy Chatterjee and Keya Chaudhuri, “A novel wavelet neural network based pathological stage detection technique for an oral precancerous condition” , Journal of Clinical Pathology, Vol.58, Issue.9, 2005, pp 932 – 938.
- [5] Ghassan Hamarneh, Artur Chodorowski, Tomas Gustavsson, “Active Contour models: Application to oral Lesion detection in color images”, IEEE Conference on Systems, Man, and Cybernetics.
- [6] K. V. Kulhalli, V.T.Patil, V.R.Udupi, “Image Processing Application for Computer Aided Diagnosis of Cancer”, Proceedings of the International Conference on Advances in Computing and Management, 2012, pp 297 – 301,
- [7] Tathagata Ray, D. Shivashankar Reddy, Anirban Mukerjee, Jyotimoy Chatterjee, Ranjan R. Paul, Pranab. K. Dutta, “Detection of constituent layers of histological oral sub – mucous fibrosis: Images using the Hybrid segmentation algorithm”, Journal of Oral Oncology, (2008), pp 1167 – 1171.
- [8] Rafael C. Gonzalez, Richard E. Woods, Steven L. Eddins, “Digital Image Processing using MATLAB”, Pearson Education, 2003.
- [9] Soille, L.V.P., “Watersheds in digital spaces: An efficient algorithm based on immersion simulations” IEEE Transactions on Pattern Analysis and Machine Intelligence, 1991. 13(6): p. 583–598.
- [10] H. S. Sheshadri, A. Kandasamy, “Detection of Breast cancer Tumor based Morphological Watershed Transformation” , International Journal on Graphics, Vision and Image Processing, Vol.5, Issue. 5, 2005.
- [11] Poonam Bhayan, Gagandeep Jindal, “A Segmented Morphological Approach to Detect Tumor in Lung Images”, International Journal of Computer Science and Technology, Vol. 2, Issue. 3, September 2011.