



6-2006

Diabetes Enhances Periodontal Bone Loss Through Enhanced Resorption and Diminished Bone Formation

Rongkun Liu

Harbinder S. Bal


Tesfahun Desta

Nanarao Krothapalli

Monaf Alyassi

See next page for additional authors

Follow this and additional works at: https://repository.upenn.edu/dental_papers

 Part of the [Bacterial Infections and Mycoses Commons](#), [Endocrinology, Diabetes, and Metabolism Commons](#), and the [Periodontics and Periodontology Commons](#)

Recommended Citation

Liu, R., Bal, H. S., Desta, T., Krothapalli, N., Alyassi, M., Luan, Q., & Graves, D. T. (2006). Diabetes Enhances Periodontal Bone Loss Through Enhanced Resorption and Diminished Bone Formation. *Journal of Dental Research*, 85 (6), 510-514. <http://dx.doi.org/10.1177/154405910608500606>

At the time of publication, author Dana Graves was affiliated with the Boston University School of Dental Medicine. Currently, he is a faculty member in the Penn Dental School at the University of Pennsylvania.

This paper is posted at ScholarlyCommons. https://repository.upenn.edu/dental_papers/20
For more information, please contact repository@pobox.upenn.edu.

Diabetes Enhances Periodontal Bone Loss Through Enhanced Resorption and Diminished Bone Formation

Abstract

Using a ligature-induced model in type-2 Zucker diabetic fatty (ZDF) rat and normoglycemic littermates, we investigated whether diabetes primarily affects periodontitis by enhancing bone loss or by limiting osseous repair. Diabetes increased the intensity and duration of the inflammatory infiltrate ($P < 0.05$). The formation of osteoclasts and percent eroded bone after 7 days of ligature placement was similar, while four days after removal of ligatures, the type 2 diabetic group had significantly higher osteoclast numbers and activity ($P < 0.05$). The amount of new bone formation following resorption was 2.4- to 2.9-fold higher in normoglycemic vs. diabetic rats ($P < 0.05$). Diabetes also increased apoptosis and decreased the number of bone-lining cells, osteoblasts, and periodontal ligament fibroblasts ($P < 0.05$). Thus, diabetes caused a more persistent inflammatory response, greater loss of attachment and more alveolar bone resorption, and impaired new bone formation. The latter may be affected by increased apoptosis of bone-lining and PDL cells.

Keywords

bone coupling, cell death, bacteria, gingiva, hyperglycemia, inflammation, infection, in vivo, periodontitis

Disciplines

Bacterial Infections and Mycoses | Endocrinology, Diabetes, and Metabolism | Periodontics and Periodontology

Comments

At the time of publication, author Dana Graves was affiliated with the Boston University School of Dental Medicine. Currently, he is a faculty member in the Penn Dental School at the University of Pennsylvania.

Author(s)

Rongkun Liu, Harbinder S. Bal, Tesfahun Desta, Nanarao Krothapalli, Monaf Alyassi, Qingxian Luan, and Dana T. Graves

Diabetes Enhances Periodontal Bone Loss through Enhanced Resorption and Diminished Bone Formation

R. Liu, H.S. Bal, T. Desta, N. Krothapalli, M. Alyassi, Q. Luan, and D.T. Graves*

Department of Periodontology and Oral Biology, Boston University School of Dental Medicine, 700 Albany Street, Rm. W-202D, Boston, MA 02118, USA

Abstract

Using a ligature-induced model in type-2 Zucker diabetic fatty (ZDF) rat and normoglycemic littermates, we investigated whether diabetes primarily affects periodontitis by enhancing bone loss or by limiting osseous repair. Diabetes increased the intensity and duration of the inflammatory infiltrate ($P < 0.05$). The formation of osteoclasts and percent eroded bone after 7 days of ligature placement was similar, while four days after removal of ligatures, the type 2 diabetic group had significantly higher osteoclast numbers and activity ($P < 0.05$). The amount of new bone formation following resorption was 2.4- to 2.9- fold higher in normoglycemic vs. diabetic rats ($P < 0.05$). Diabetes also increased apoptosis and decreased the number of bone-lining cells, osteoblasts, and periodontal ligament fibroblasts ($P < 0.05$). Thus, diabetes caused a more persistent inflammatory response, greater loss of attachment and more alveolar bone resorption, and impaired new bone formation. The latter may be affected by increased apoptosis of bone-lining and PDL cells.

Keywords

bone coupling; cell death; bacteria; gingiva; hyperglycemia; inflammation; infection; *in vivo*; periodontitis

INTRODUCTION

Periodontal disease is induced by bacterial plaque that stimulates a host response in the adjacent gingiva that leads to the destruction of connective tissue and bone (Socransky *et al.*, 1998; Graves and Cochran, 2003). The progression of periodontal disease may be affected by systemic conditions, such as diabetes (Løe, 1993). Type 2 diabetes significantly increases the risk for periodontal disease, with either attachment loss or bone loss as a criterion (Shlossman *et al.*, 1990; Emrich *et al.*, 1991; Tsai *et al.*, 2002). The severity of periodontal disease is also increased by type 2 diabetes (Collin *et al.*, 1998; Campus *et al.*, 2005). When diabetes types 1 and 2 are directly compared, both increase periodontal disease prevalence to a similar extent (Bacic *et al.*, 1988).

Since periodontal disease has been linked to the destructive effects of pro-inflammatory mediators (Williams *et al.*, 1985; Assuma *et al.*, 1998), diabetes may exert an effect on the periodontium through cytokine dysregulation. This is supported by studies in which poor glycemic control was significantly correlated with greater production of cytokines and higher cytokine levels in gingival fluid (Salvi *et al.*, 1997; Lalla *et al.*, 2000; Engebretson *et al.*, 2004). Furthermore, diabetic mice exhibit prolonged inflammation in response to *P. gingivalis*, which is due in part to TNF dysregulation (Naguib *et al.*, 2004). Increased

*corresponding author, dgraves@bu.edu.

inflammation could affect the net loss of bone by increasing bone loss, inhibiting repair of resorbed bone, or both.

To examine separately the impact of diabetes on periodontal bone loss and the formation of new bone following resorption, we carried out studies in a model where a ligature was placed around a molar tooth and the ensuing inflammation, loss of attachment, and bone were measured over a seven-day period (Bezerra *et al.*, 2002; Gaspersic *et al.*, 2003). This model was chosen since it mimics several features of human periodontitis, including the formation of an inflammatory infiltrate, loss of attachment, and loss of alveolar bone. Moreover, these features are dependent upon a bacteria-induced host response, as indicated by decreased loss of attachment and reduced bone resorption in rats treated with chlorhexidine, antibiotics, or prostaglandin inhibitors (Weiner *et al.*, 1979; Kenworthy and Baverel, 1981; Bezerra *et al.*, 2002). Interestingly, bone loss and inflammation are accelerated by the administration of IL-1 β or TNF- α (Koide *et al.*, 1995; Gaspersic *et al.*, 2003), which is consistent with results obtained in non-human primates, demonstrating that inhibition of these cytokines reduces alveolar bone loss (Assuma *et al.*, 1998; Delima *et al.*, 2002). By using the rat ligature model, where bone resorption and formation could be separately examined, we tested the hypothesis that type 2 diabetes would aggravate periodontal disease by both increasing bone loss as well as limiting reparative bone formation.

MATERIALS & METHODS

Induction of Periodontal Bone Loss

Eight-week-old male Zucker diabetic fatty (ZDF) and Zucker lean rats were purchased from Charles River Laboratories (Wilmington, MA, USA). ZDF rats become diabetic when they are 8 wks of age, and experiments were started at 12 wks. We induced experimental periodontitis by tying *P. gingivalis*-soaked silk ligatures around the maxillary second molars or mandibular first molars. For each animal, at least one quadrant had no ligated teeth. It has previously been shown that placement of the ligature facilitates bacteria-induced inflammation and tissue loss (Rovin *et al.*, 1966). To enhance reproducibility, we applied approximately 10 μ L of *P. gingivalis* (1×10^8 /mL) around the ligated tooth on days 2 and 4 after placement. In some animals, ligatures were removed, and the animals were killed 4 or 9 days later. The maxillary and mandibular jaws were fixed in 4% paraformaldehyde for 3 days at 4°C and decalcified in Immunocal (Decal Chemical Corporation, Tallman, NY, USA) at 4°C for 12 days. Sagittal paraffin sections were prepared at 5 microns, and the interproximal areas between the 1st and 2nd and the 2nd and 3rd maxillary molars, and between the 1st and 2nd mandibular molars were examined. All animal procedures were approved by the Institutional Animal Care and Use Committee, Boston University Medical Center.

Histomorphometric Analysis of Hematoxylin-/Eosin-stained Sections

The mid-interproximal region was examined in each specimen and was established by being sectioned to a level where the root canal systems in adjacent teeth were visible. Two randomly chosen sections of each interproximal area were examined, and the value for a given quadrant was calculated from these sections. The mean value for the quadrants was then established for a given animal, which was the unit of measurement. For most animals, 2 quadrants were examined. For each group, there were 5 to 7 animals. All data were analyzed by a blinded examiner who did not know the group to which an animal belonged. Approximately half of the sections were examined by a second individual to confirm the results. Inflammation was evaluated based on an inflammatory score of PMN/mononuclear cell infiltration: 0, no inflammatory cells; 1, slight inflammation (a few inflammatory cells close to the junctional epithelium); 2, moderate inflammation (several inflammatory cells scattered through the gingival connective tissue); and 3, severe inflammation (more than 1/3 of the cells in the

interproximal tissue were inflammatory cells). Attachment loss was measured by the distance between the cemento-enamel junction and the most coronal extent of connective tissue attachment to cementum. Bone area was assessed by the amount of bone coronal to a line 1 mm below the adjoining cemento-enamel junctions.

Histomorphometric Analysis of Tartrate-resistant Acid-phosphatase-stained (TRAP) Sections

Since rat molars undergo distal drift (Moss-Salentijn and Moss, 1977), there is constant resorptive activity on the proximal bone between the molars. Therefore, the analysis of TRAP-stained sections was restricted to the distal aspect of the interproximal bone. Osteoclasts were counted as previously described (He *et al.*, 2004), and we calculated the percent eroded bone surface by measuring the aggregate length of the lacunae and dividing that by the total bone length. New bone formation was quantified by the amount of matrix produced after the formation of a "reversal line", as described previously (Romano *et al.*, 1997).

Detection of Apoptotic Bone-lining Cells and Fibroblasts

Apoptotic cells adjacent to bone were detected by the TUNEL assay with a kit purchased from Trevigen (Gaithersburg, MD, USA). The total number of bone-lining cells was counted as the number adjacent to bone divided by bone length in hematoxylin-/eosin-stained sections. In addition, the number of osteoblastic cells was counted in areas of new bone formation, divided by the length of bone that contained osteoblastic cells. Osteoblastic cells were identified in hematoxylin-/eosin-stained sections as cuboidal cells adjacent to bone and were clearly distinguishable from other bone-lining cells. Fibroblastic apoptotic cells in the coronal third of the periodontal ligament space were also counted. The total number of PDL fibroblastic cells was counted in the same area in hematoxylin-/eosin-stained sections.

Statistical Analysis

Differences between diabetic and control groups were determined by Student's *t* test at the $P < 0.05$ level and between time points within a group by ANOVA with Scheffé's *post hoc* test.

RESULTS

Bone Loss and Repair

The placement of ligatures in normoglycemic and diabetic rats for 7 days, and the responses 4 and 9 days following ligature removal indicate that experimental periodontitis stimulates osteoclastogenesis, formation of Howship's lacunae, and reparative bone formation (Fig. 1A). When quantitative analysis was undertaken, a large and similar increase in the number of osteoclasts compared with baseline was noted for diabetic and control groups immediately after ligatures were removed (0 days) (Fig. 1B). Four days after removal of ligatures, the number was 4.6-fold higher in diabetics than in normoglycemics. By day 9, both groups returned to baseline. The pattern of eroded bone surface, a measure of osteoclast activity, was similar (Fig. 1C). Immediately after removal of ligatures, the percent eroded bone surface was similar in diabetic and normoglycemic groups. However, 4 days after removal of ligatures, the eroded bone surface in the diabetic group was 2.9-fold higher than in the normoglycemics ($P < 0.05$).

Histomorphometric analysis revealed that new bone formation increased significantly after the removal of ligatures, between day 0 and day 4 ($P < 0.05$), but did not increase significantly between day 4 and day 9 ($P > 0.05$) (Fig. 2A). However, new bone formation was 2.4- to 2.9-fold higher in the control group than in the diabetic group ($P < 0.05$). When total bone area above a line 1 mm apical to the cemento-enamel junction was measured, placement of ligatures

induced a large and similar decrease in both diabetic and normoglycemic rats (Fig. 2B). However, 4 days after removal of ligatures, the amount of bone was 2.6-fold higher in the normoglycemic compared with diabetic rats and continued to be significantly higher 9 days later.

The induction of experimental periodontitis stimulated the formation of an inflammatory infiltrate in both diabetic and normoglycemic rats (Table). However, after removal of ligatures, the infiltrate was significantly higher in the diabetic group ($P < 0.05$). Thus, the diabetic group was characterized by a higher level of inflammatory cell recruitment that was substantially more prolonged.

We performed the TUNEL assay to measure apoptosis of bone-lining cells (Fig. 2C). Experimental periodontitis significantly increased the number of apoptotic bone-lining cells in both diabetics and controls compared with baseline ($P < 0.05$), but at a much higher level, five-fold in the diabetics ($P < 0.05$). On day 4 after ligature removal, the number of apoptotic bone-lining cells was still high in the diabetic group but had returned to almost baseline levels in normoglycemic rats. Thus, diabetes increased the quantity and duration of apoptosis of bone-lining cells. We assessed the potential impact of apoptosis by measuring the number of these cells (Fig. 2D). At the time ligatures were removed and 4 days later, the period of peak bone formation, there were significantly fewer bone-lining cells in the diabetic group ($P < 0.05$). On day 9, both returned to baseline levels. In addition, the number of osteoblastic cells in areas of new bone formation was measured 4 days after ligature removal. The results indicated that the control group had significantly higher numbers of osteoblasts *per* mm bone length, 83.4 ± 3 , compared with the diabetic group, 66 ± 4 ($P < 0.05$).

Soft-tissue Destruction and Repair

Experimental periodontitis caused loss of attachment that was 1.7-fold higher in the diabetic compared with the normoglycemic rats ($P < 0.05$) (Fig. 3A), and was largely maintained after the removal of ligatures. When apoptosis of fibroblastic cells within the periodontal ligament space was measured, experimental periodontitis stimulated a 2.7-fold higher level in the diabetic than in the normoglycemic rats ($P < 0.05$) (Fig. 3B). The higher level in the diabetic group, but not in the normoglycemic group, was maintained 4 days later. By day 9, the level of apoptosis was low in both groups.

Fibroblast density was measured in the coronal third of the periodontal ligament space (Fig. 3C). When periodontitis was induced, there was a substantial decrease in PDL fibroblast density in both diabetic and control rats. However, 4 days after ligature removal, the density was almost 40% lower in the diabetic rats ($P < 0.05$). By day 9, when apoptosis was virtually non-existent, fibroblast density returned to normal levels in both diabetic and normoglycemic rats.

DISCUSSION

Experiments reported here indicate that experimental periodontitis stimulated osteoclast formation and activity and initial bone loss that were similar in normoglycemic and diabetic rats. The major difference between the 2 groups came after the removal of ligatures. The diabetic group maintained high levels of inflammation compared with the normoglycemic group. As a result, the diabetic rats continued to lose bone and had significantly impaired capacity to repair lost bone. However, there were no differences at baseline (no ligature) between the diabetic and normoglycemic control rats in any of the measurements that were made. Thus, there appear to be no developmental anomalies in the 12- to 14-week-old ZDF rats that significantly affect “baseline” measurements in the periodontium.

The finding that there was more persistent inflammation in the diabetic group is consistent with a more prolonged inflammatory response to *P. gingivalis* in diabetic mice (Naguib *et al.*, 2004; Graves *et al.*, 2005) and in a *P. gingivalis* gavage model of periodontitis (Lalla *et al.*, 2000). In the former, inhibition of TNF and, in the latter, blockage of advanced glycation end-products reduced the deleterious effect of diabetes. Thus, TNF dysregulation and advanced glycation end-products are two potential etiologic factors in the more persistent inflammatory responses of diabetics.

It is well-established that, in a healthy young adult, bone resorption is followed by an equivalent amount of bone formation, which is referred to as coupling (Parfitt, 1982). A novel use of the ligature model was to study osseous repair. The amount of new bone produced by diabetic rats was far less than that of their normal counterparts. The results would suggest that the diabetic group eventually produced enough bone to fill the lacunae and present a relatively smooth bone surface, while the normals produced bone beyond the lacunae to replace more of the lost bone. This was due to a reduced capacity to form bone, rather than to a shift in the time frame of new bone formation. The diminished osseous repair in diabetic rats may reflect a reduced production of matrix *per cell* or a decreased number of cells capable of producing matrix. The finding that diabetes significantly increased apoptosis of bone-lining cells raises the possibility that enhanced apoptosis may interfere with the repair of resorbed bone. Increased apoptosis of PDL cells could also affect the repair process, since it is thought to be a rich source of cells capable of differentiating into osteoblasts (Isaka *et al.*, 2001). That the high rate of apoptosis is functionally important is supported by the significantly decreased number of bone-lining and osteoblastic cells and decreased numbers of PDL cells in the diabetic rats following removal of ligatures. The higher rates of apoptosis could be due to the same mediators that have been implicated in prolonged inflammation, namely, cytokines such as TNF, or advanced glycation end-products (Hock *et al.*, 2001; Alikhani *et al.*, 2004, 2005). In addition, the higher rate of PDL cell apoptosis could potentially affect the loss of attachment, since the increased cell death and decreased cell density may make it more difficult for attachment levels to be maintained during bacterial invasion.

In summary, diabetic rats had a higher degree of inflammation and a more persistent inflammatory response following ligature-induced periodontal disease. This may result in more prolonged osteoclast formation and activity, greater loss of attachment due to increased production of matrix metalloproteinases (Ryan *et al.*, 1999), and diminished new bone formation. Diabetes-enhanced apoptosis of bone-lining and PDL cells may contribute to the latter.

Acknowledgements

We thank Brian Allen for technical assistance and Alicia Ruff for help in preparing this manuscript. This work was supported by NIDCR grant DE07559.

References

- Alikhani M, Alikhani Z, Graves DT. Apoptotic effects of LPS on fibroblasts are indirectly mediated through TNFR1. *J Dent Res* 2004;83:671–676. [PubMed: 15329370]
- Alikhani Z, Alikhani M, Boyd CM, Nagao K, Trackman PC, Graves DT. Advanced glycation end products enhance expression of pro-apoptotic genes and stimulate fibroblast apoptosis through cytoplasmic and mitochondrial pathways. *J Biol Chem* 2005;280:12087–12095. [PubMed: 15590648]
- Assuma R, Oates T, Cochran D, Amar S, Graves DT. IL-1 and TNF antagonists inhibit the inflammatory response and bone loss in experimental periodontitis. *J Immunol* 1998;160:403–409. [PubMed: 9551997]
- Bacic M, Plancak D, Granic M. CPITN assessment of periodontal disease in diabetic patients. *J Periodontol* 1988;59:816–822. [PubMed: 3225728]

- Bezerra MM, Brito GA, Ribeiro RA, Rocha FA. Low-dose doxycycline prevents inflammatory bone resorption in rats. *Braz J Med Biol Res* 2002;35:613–616. [PubMed: 12011948]
- Campus G, Salem A, Uzzau S, Baldoni E, Tonolo G. Diabetes and periodontal disease: a case-control study. *J Periodontol* 2005;76:418–425. [PubMed: 15857077]
- Collin HL, Uusitupa M, Niskanen L, Kontturi-Närhi V, Markkanen H, Koivisto AM, et al. Periodontal findings in elderly patients with non-insulin dependent diabetes mellitus. *J Periodontol* 1998;69:962–966. [PubMed: 9776023]
- Delima AJ, Karatzas S, Amar S, Graves DT. Inflammation and tissue loss caused by periodontal pathogens is reduced by interleukin-1 antagonists. *J Infect Dis* 2002;186:511–516. [PubMed: 12195378]
- Emrich LJ, Shlossman M, Genco RJ. Periodontal disease in non-insulin-dependent diabetes mellitus. *J Periodontol* 1991;62:123–131. [PubMed: 2027060]
- Engelbreton SP, Hey-Hadavi J, Ehrhardt FJ, Hsu D, Celenti RS, Grbic JT, et al. Gingival crevicular fluid levels of interleukin-1beta and glycemic control in patients with chronic periodontitis and type 2 diabetes. *J Periodontol* 2004;75:1203–1208. [PubMed: 15515334]
- Gaspersic R, Stiblar-Martincic D, Osredkar J, Skaleric U. Influence of subcutaneous administration of recombinant TNF-alpha on ligature-induced periodontitis in rats. *J Periodontol Res* 2003;38:198–203. [PubMed: 12608915]
- Graves DT, Cochran D. The contribution of interleukin-1 and tumor necrosis factor to periodontal tissue destruction. *J Periodontol* 2003;74:391–401. [PubMed: 12710761]
- Graves DT, Naguib G, Lu H, Leone C, Hsue H, Krall E. Inflammation is more persistent in type 1 diabetic mice. *J Dent Res* 2005;84:324–328. [PubMed: 15790737]
- He H, Liu R, Desta T, Leone C, Gerstenfeld LC, Graves DT. Diabetes causes decreased osteoclastogenesis, reduced bone formation, and enhanced apoptosis of osteoblastic cells in bacteria stimulated bone loss. *Endocrinology* 2004;145:447–452. [PubMed: 14525917]
- Hock JM, Krishnan V, Onyia JE, Bidwell JP, Milas J, Stanislaus D. Osteoblast apoptosis and bone turnover. *J Bone Miner Res* 2001;16:975–984. [PubMed: 11393794]
- Isaka J, Ohazama A, Kobayashi M, Nagashima C, Takiguchi T, Kawasaki H, et al. Participation of periodontal ligament cells with regeneration of alveolar bone. *J Periodontol* 2001;72:314–323. [PubMed: 11327058]
- Kenworthy R, Bayerel M. Studies of a periodontal tissue lesion in the rat, untreated or treated with chlorhexidine digluconate. *J Clin Periodontol* 1981;8:349–358. [PubMed: 6947996]
- Koide M, Suda S, Saitoh S, Ofuji Y, Suzuki T, Yoshie H, et al. *In vivo* administration of IL-1 beta accelerates silk ligature-induced alveolar bone resorption in rats. *J Oral Pathol Med* 1995;24:420–434. [PubMed: 8537916]
- Lalla E, Lamster IB, Feit M, Huang L, Spessot A, Qu W, et al. Blockade of RAGE suppresses periodontitis-associated bone loss in diabetic mice. *J Clin Invest* 2000;105:1117–1124. [PubMed: 10772656]
- Löe H. Periodontal disease. The sixth complication of diabetes mellitus. *Diabetes Care* 1993;16:329–334. [PubMed: 8422804]
- Moss-Salentijn L, Moss ML. Effects of occlusal attrition and continuous eruption on odontometry of rat molars. *Am J Phys Anthropol* 1977;47:403–407. [PubMed: 931019]
- Naguib G, Al-Mashat H, Desta T, Graves DT. Diabetes prolongs the inflammatory response to a bacterial stimulus through cytokine dysregulation. *J Invest Dermatol* 2004;123:87–92. [PubMed: 15191547]
- Parfitt AM. The coupling of bone formation to bone resorption: a critical analysis of the concept and of its relevance to the pathogenesis of osteoporosis. *Metab Bone Dis Relat Res* 1982;4:1–6. [PubMed: 7121250]
- Romano PR, Caton JG, Puzas JE. The reversal line may be a key modulator of osteoblast function: observations from an alveolar bone wound-healing model. *J Periodontol Res* 1997;32(1 Pt 2):143–147. [PubMed: 9085225]
- Rovin S, Costich ER, Gordon HA. The influence of bacteria and irritation in the initiation of periodontal disease in germfree and conventional rats. *J Periodontol Res* 1966;1:193–204. [PubMed: 4225530]
- Ryan ME, Ramamurthy NS, Sorsa T, Golub LM. MMP-mediated events in diabetes. *Ann NY Acad Sci* 1999;878:311–334. [PubMed: 10415738]

- Salvi GE, Collins JG, Yalda B, Arnold RR, Lang NP, Offenbacher S. Monocytic TNF alpha secretion patterns in IDDM patients with periodontal diseases. *J Clin Periodontol* 1997;24:8–16. [PubMed: 9049792]
- Shlossman M, Knowler WC, Pettitt DJ, Genco RJ. Type 2 diabetes mellitus and periodontal disease. *J Am Dent Assoc* 1990;121:532–536. [PubMed: 2212346]
- Socransky SS, Haffajee AD, Cugini MA, Smith C, Kent RJ Jr. Microbial complexes in subgingival plaque. *J Clin Periodontol* 1998;25:134–144. [PubMed: 9495612]
- Tsai C, Hayes C, Taylor GW. Glycemic control of type 2 diabetes and severe periodontal disease in the US adult population. *Community Dent Oral Epidemiol* 2002;30:182–192. [PubMed: 12000341]
- Weiner GS, DeMarco TJ, Bissada NF. Long term effect of systemic tetracycline administration on the severity of induced periodontitis in the rat. *J Periodontol* 1979;50:619–623. [PubMed: 294476]
- Williams RC, Jeffcoat MK, Kaplan ML, Goldhaber P, Johnson HG, Wechter WJ. Flurbiprofen: a potent inhibitor of alveolar bone resorption in beagles. *Science* 1985;227:640–642. [PubMed: 3969553]

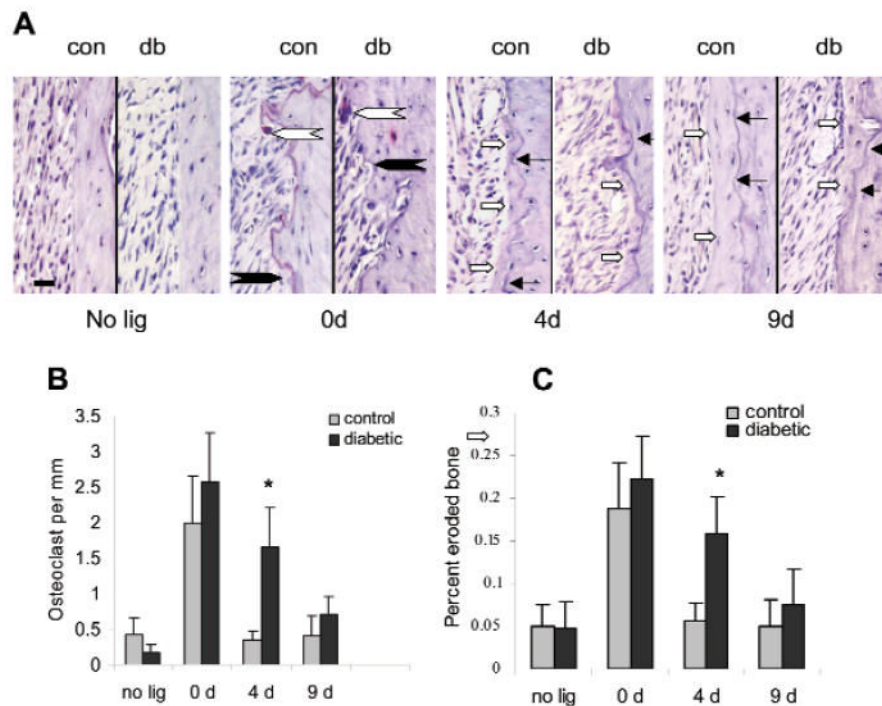


Figure 1.

Diabetes prolongs osteoclast formation and activity. Ligatures were placed around the molar teeth of ZDF type 2 diabetic and normoglycemic control rats and left in place for 7 days. Rats were killed prior to the placement of ligatures (no ligatures), immediately after removal (0 day), or 4 or 9 days later. Histologic TRAP-stained sections, original magnification 200x. Large open arrows indicate osteoclasts, large closed arrows indicate Howship's lacunae, small closed arrows point to a reversal line, and small open arrows point to the extent of new bone formation (A). Osteoclasts were counted (B), and the percent eroded bone surface (C) was measured in TRAP-stained sections. Each value in B and C is the mean of 5 to 7 rats \pm SE. *Significant difference between diabetics and normoglycemic control rats ($P < 0.05$). Bar in far left panel represents 0.05 mm.

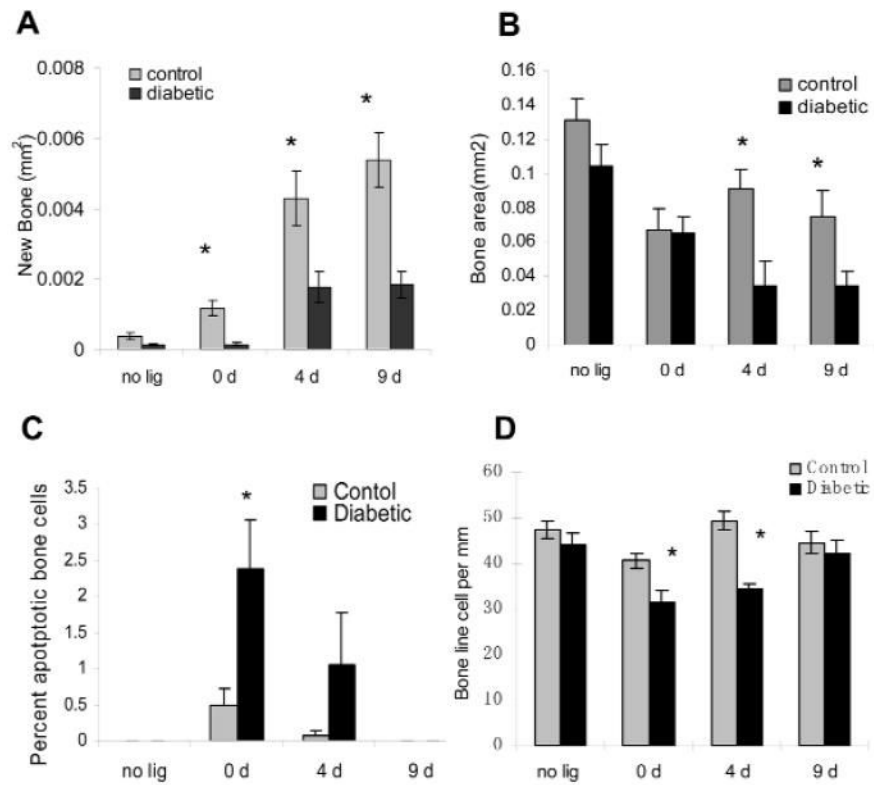


Figure 2.

Diabetes impaired new bone formation and increased osteoblastic apoptosis. The area of new bone formation (A) was measured in TRAP-stained sections as described in MATERIALS & METHODS. The area of alveolar bone between the cemento-enamel junction (CEJ) and a line 1 mm apical to the CEJ was measured in H&E-stained sections (B). Rats described in Fig. 1 were examined for the percent of apoptotic bone-lining cells by the TUNEL assay (C) and the number of bone-lining cells *per* mm bone length in H&E-stained sections (D). Each value is the mean of 5 to 7 rats \pm SE. *Significant difference between diabetics and normoglycemic control rats ($P < 0.05$).

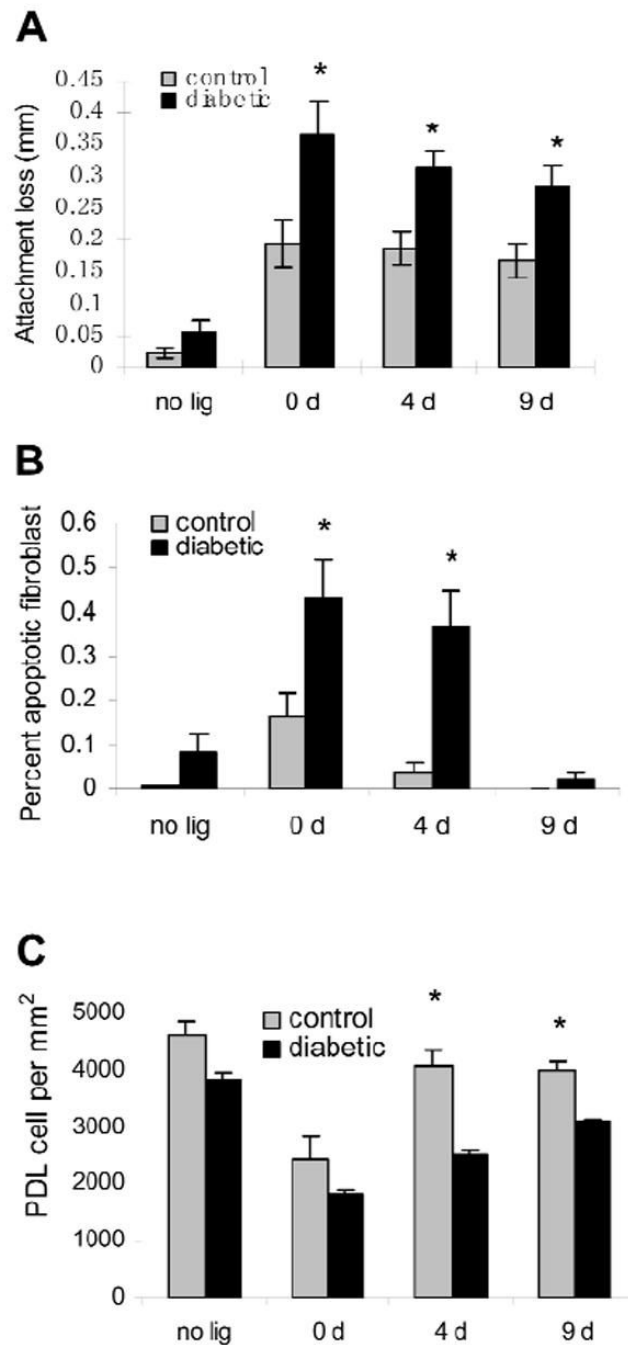


Figure 3.

Diabetes increases the loss of attachment, increases apoptosis of PDL fibroblasts, and decreases PDL fibroblast numbers. Rats described in Fig. 1 were examined for loss of attachment in H&E-stained sections (A) and for the number of fibroblasts in the coronal aspect of the PDL space (C). Apoptosis of PDL fibroblasts was determined by the TUNEL assay and expressed as the percent of apoptotic fibroblasts (B). Each value is the mean of 5 to 7 rats \pm SE. *Significant difference between diabetics and normoglycemic control rats ($P < 0.05$).

Table
The Formation of an Inflammatory Infiltrate is Prolonged by Type 2 Diabetes

	Control	Inflammatory Score Diabetic	P value
No lig	0.08	0.21	0.12
0 day	0.81	1.59	0.01
4 day	0.42	1.28	0.01
9 day	0.15	0.68	0.03

Experimental periodontitis was induced by the placement of ligatures as described in MATERIALS & METHODS for 7 days and removed in normoglycemic and type 2 diabetic rats. In some cases, rats had no ligatures placed or were killed 4 or 9 days following removal of ligatures. The interproximal gingiva between the 1st and 2nd and 2nd and 3rd molars was examined for the presence of inflammatory cells (PMNs and mononuclear cells) in H&E-stained sections, according to the following scale: 0 (no inflammation), 1 (slight), 2 (moderate), and 3 (severe), as described in MATERIALS & METHODS. Each value represents the mean score of 5 to 7 rats.