

# Diagnosing Fracture-Related Infection: Current Concepts and Recommendations

Geertje A. M. Govaert, MD, PhD,\* Richard Kuehl, MD,† Bridget L. Atkins, MD,‡ Andrej Trampuz, MD,§ Mario Morgenstern, MD,|| William T. Obrebsky, MD, MPH,¶ Michael H. J. Verhofstad, MD, PhD,\*\* Martin A. McNally, MD, FRCS(Orth),‡ and Willem-Jan Metsemakers, MD, PhD†† on behalf of the Fracture-Related Infection (FRI) Consensus Group

**Summary:** Fracture-related infection (FRI) is a severe complication after bone injury and can pose a serious diagnostic challenge. Overall, there is a limited amount of scientific evidence regarding diagnostic criteria for FRI. For this reason, the AO Foundation and the European Bone and Joint Infection Society proposed a consensus definition for FRI to standardize the diagnostic criteria and improve the quality of patient care and applicability of future studies regarding this condition. The aim of this article was to summarize the available evidence and provide recommendations for the diagnosis of FRI. For this purpose, the FRI consensus definition will be discussed together with a proposal for an update based on the available evidence relating to the diagnostic value of clinical parameters, serum inflammatory markers, imaging modalities, tissue and sonication fluid sampling, molecular biology techniques, and histopathological examination. Second, recommenda-

tions on microbiology specimen sampling and laboratory operating procedures relevant to FRI will be provided.

**Key Words:** fracture-related infection, diagnosis, diagnostic criteria, definition, clinical criteria, medical imaging, histopathology, microbiology, serum inflammatory markers, fracture, infection

**Level of Evidence:** Diagnostic Level V. See Instructions for Authors for a complete description of levels of evidence.

(*J Orthop Trauma* 2020;34:8–17)

## INTRODUCTION

Fracture-related infection (FRI) is a severe complication following bone injury and can pose a diagnostic challenge. There is a spectrum of clinical presentations of FRI and differentiating them from noninfected causes can be difficult. In the early postoperative period, classical clinical symptoms of infection, such as pain, redness, warmth, or swelling, overlap with features of normal fracture healing. Later, more subtle clinical presentations such as fracture nonunion or persistent pain can be attributable to both infective and noninfective conditions. The complexity and variety of FRI may have hindered the establishment of uniform diagnostic criteria. In addition, the lack of diagnostic guidance has led to uncertainty in the management and treatment of these patients.

These challenges highlight a need for standardized interdisciplinary diagnostic and treatment approaches. In contrast to periprosthetic joint infection (PJI), protocols tailored to infection in patients after musculoskeletal trauma are scarce. Therefore, many of the surgical and medical treatment concepts applied to FRI have been adopted from PJI treatment algorithms. Both conditions have a multistage process of diagnosis in common based on various diagnostic pillars. However, important differences exist between fractures and arthroplasties. Therefore, it is striking that there is little scientific evidence for the predictive value of diagnostic investigations specifically focusing on FRI.

The lack of a uniform definition for FRI may also have contributed to the scarcity of comparable data on diagnostic strategies. This shortcoming was confirmed by a recent systematic review, showing that only a minority of randomized controlled trials in fracture care use any kind of standardized definition of FRI.<sup>1</sup> The absence of a universally accepted definition of FRI is similar to the situation for PJI many years ago.<sup>2</sup> The development of uniform criteria for the

Accepted for publication August 9, 2019.

From the \*Department of Trauma Surgery, University Medical Center Utrecht, University of Utrecht, Utrecht, The Netherlands; †Department of Infectious Diseases and Hospital Epidemiology, University Hospital of Basel, Basel, Switzerland; ‡The Bone Infection Unit, Nuffield Orthopaedic Centre, Oxford University Hospitals, Oxford, United Kingdom; §Center for Musculoskeletal Surgery, Charité-Universitätsmedizin Berlin, corporate member of Freie Universität Berlin, Humboldt-Universität zu Berlin, and Berlin Institute of Health, Berlin, Germany; ||Department of Orthopaedic and Trauma Surgery, University Hospital Basel, Basel, Switzerland; ¶Department of Orthopaedic Surgery and Rehabilitation, Vanderbilt University Medical Center, Nashville, TN; \*\*Department of Trauma Surgery, Erasmus University Medical Centre, Rotterdam, The Netherlands; and ††Department of Trauma Surgery, University Hospitals Leuven, Leuven, Belgium.

The source of funding with respect to hosting the consensus meeting was the AO Foundation (AOTK system and AOTrauma). Open access publication was funded by the AO Foundation and the Orthopaedic Trauma Association, the Pro-Implant Foundation, and the European Bone and Joint Infection Society.

The authors report no conflict of interest.

G. A. M. Govaert and first authorship and W-J. Metsemakers last (senior) authorship.

Members of the FRI Consensus Group are listed in Acknowledgments section.

Reprints: Willem-Jan Metsemakers, MD, PhD, Department of Trauma Surgery, University Hospitals Leuven, Herestraat 49, 3000 Leuven, Belgium (e-mail: willem-jan.metsemakers@uzleuven.be).

Copyright © 2019 The Author(s). Published by Wolters Kluwer Health, Inc. This is an open-access article distributed under the terms of the Creative Commons Attribution-Non Commercial-No Derivatives License 4.0 (CCBY-NC-ND), where it is permissible to download and share the work provided it is properly cited. The work cannot be changed in any way or used commercially without permission from the journal.

DOI: 10.1097/BOT.0000000000001614

diagnosis of PJI has led to an improvement in the diagnostic process of PJI after hip and knee arthroplasty.<sup>3,4</sup> There is now growing awareness among orthopaedic and trauma surgeons that FRI is a unique entity and that a definition of FRI is required.<sup>5</sup> The need for a uniform definition for FRI is closely related to the need for a uniform diagnostic pathway. In 2015, a survey of practitioners involved in the care of patients with FRI showed that there was no consensus on the optimal diagnosis of infection.<sup>6</sup>

For these reasons, the AO Foundation and the European Bone and Joint Infection Society (EBJIS) recently proposed a consensus definition for FRI to standardize the diagnostic criteria and improve the quality of patient care and applicability of future studies regarding this condition.<sup>7</sup>

The aim of this article is to summarize the available evidence and to provide recommendations for the diagnosis of FRI. For this purpose, first the diagnostic criteria included in the recently published FRI consensus definition will be discussed together with a proposal for an update regarding nuclear imaging modalities and histopathological examination. This update is based on a second consensus meeting including not only the AO Foundation and the EBJIS but also the Orthopaedic Trauma Association and the PRO-Implant Foundation. Furthermore, recommendations on microbiology specimen sampling techniques and laboratory operating procedures relevant to FRI will be provided.

## DEFINITION

In 2018, the aforementioned consensus definition for FRI was published.<sup>7</sup> The development process was comparable to the one used for the new definition on PJI.<sup>8</sup> An international group of experts was involved, representing the AO Foundation and EBJIS as well as prominent orthopaedic trauma hospitals and academic centers with specific interest and clinical experience in FRI. Acknowledging the multidisciplinary nature of FRI, physicians from different specialties were included. After review of the literature and video conferences, a face-to-face consensus meeting was held and a final agreement on the definition of FRI was reached. It was accepted that some features of FRI can be regarded as definitive proof of infection and should be given more weight in the definition. Other less specific features may suggest an infection but may also be present in patients without infection. This resulted in a set of confirmatory criteria (infection definitely present) and suggestive criteria (infection possibly present). An updated diagnostic flowchart as proposed by the FRI consensus group will be provided at the end of this article.

## DIAGNOSTIC CRITERIA

The diagnosis of FRI is a multistage process based on various important diagnostic pillars. Authors of the consensus definition on FRI concluded that there is a scarcity of solid evidence on which such a definition could be based.<sup>7</sup> Thus, many of the included criteria were based on expert opinion. In the following sections, the diagnostic possibilities for patients

with FRI will be described and evaluated based on current evidence.

## Clinical Criteria

The clinical features used to define FRI were analyzed in 2 recent systematic reviews. In the first review, the authors identified definitions used in the scientific literature to describe infective complications after internal fixation of fractures.<sup>1</sup> The second review provided an overview of the available diagnostic criteria, classifications, treatment protocols, and patient-related outcome measurements for surgically treated FRI patients between 1990 and 2017.<sup>9</sup> Both reviews describe a large variety of clinical signs, with the only 2 undisputable definitive criteria being purulent drainage and wound dehiscence/breakdown. This corresponded to the conclusion of the consensus meeting on FRI: the presence of a fistula, sinus, or wound breakdown (with communication to the bone or implant) and/or purulent drainage from the wound or presence of pus during surgery are regarded as pathognomonic and are confirmatory clinical signs for the diagnosis of FRI.<sup>7</sup> To our knowledge, no studies have reported on the predictive value of systemic or local clinical signs of infection for FRI. However, it was accepted by the consensus group that the presence of FRI can be indicated by clinical signs comprising local redness, swelling, increased local temperature, fever ( $\geq 38.3^\circ\text{C}$ ), or persistent, increasing, or new-onset wound drainage beyond the first few days postoperatively. Therefore, these features were regarded as suggestive clinical signs for FRI. It is important to realize that these suggestive criteria are not pathognomonic and therefore should prompt the treating surgeon or physician to further investigate the possibility of an FRI.

## Serum Inflammatory Markers

The most commonly used serum inflammation markers in orthopaedic surgery are leukocyte count (LC), C-reactive protein (CRP), and erythrocyte sedimentation rate (ESR).

Leukocytes, and more specifically neutrophils, are the first innate immune cells that are rapidly recruited from the bloodstream to sites of infection and act as major phagocytes. The number of leukocytes and neutrophils can be measured in the blood, and therefore, they are frequently used as a surveillance tool for (postoperative) infection. Although an increase above normal parameters can be an indication of infection, their number will also increase in the presence of other causes of cell damage, such as trauma, surgery, sterile inflammation, systemic inflammatory diseases, and malignancies.<sup>10,11</sup> In spinal surgery, it is reported that maximum values of LC are seen on days 1 to 3 postoperatively and decline to normal values between days 4 and 6.<sup>12</sup>

Levels of CRP are known to increase in response to various stimuli, such as infection, tissue damage, acute coronary syndrome, and allergies.<sup>13</sup> The functions of CRP include recognizing microbial pathogens, activating the complement pathway, and leukocyte phagocytosis.<sup>14</sup> In fracture patients, CRP levels increase to a maximum on the second day and then return to normal after 2 weeks.<sup>15</sup>

Other acute phase proteins (particularly fibrinogen, haptoglobin, and ceruloplasmin) and immunoglobulins

(mainly IgM) cause a decrease in the negative surface charge of erythrocytes with subsequently increased agglutination and rouleaux formation (stacks of erythrocytes). Therefore, infection results in an increase in the relative weight of erythrocytes expressed by elevated ESR. Values of ESR peak at days 7–11 postoperatively following spinal instrumentation and decrease gradually until week 6.<sup>16</sup>

Elevation of the 3 inflammatory markers (LC, CRP, and ESR) may be seen in trauma patients due to a systemic inflammatory response, postoperative tissue damage, and surgical infections.<sup>11,17–21</sup> In a recent systematic review, the diagnostic value of the serum inflammatory markers CRP, LC, and ESR in suspected chronic/late-onset FRI was assessed.<sup>22</sup> Of a total of 8280 articles that were identified, only 6 were included. CRP appeared to be the most useful serum inflammatory marker with a sensitivity ranging between 60.0% and 100% and specificity between 34.3% and 85.7% (cutoff values varied between 5.0 and 10.0 mg/L). Meta-analysis of the pooled results showed limited diagnostic value of all 3 markers individually. For these reasons, the analyzed serum inflammatory markers (CRP, LC, and ESR) are insufficient to confirm or rule out the presence of chronic/late-onset FRI. Another issue that complicated the analysis of the available data was that different measuring devices, laboratory protocols, and/or thresholds were used.

Caution is warranted when interpreting the results of serum inflammatory markers in daily clinical practice, and they should be regarded only as suggestive criteria for FRI.<sup>7</sup> Future research, using a clear definition of FRI and standardized laboratory protocols, will require appreciation of the continuous values of serum inflammatory markers and assessment of their combined value in the diagnosis of FRI.

## Medical Imaging

There are 3 indications to request diagnostic imaging for FRI (1) to acquire more certainty regarding the presence or absence of FRI, (2) to visualize the anatomic details of the disease such as its extension, the presence of sequestra, cloacae, sinus tracts, and/or subcortical abscesses, for surgical planning, and (3) to establish the degree of fracture healing and implant stability. For these purposes, the clinician has a choice of several radiological and nuclear imaging techniques. Depending on local preference and availability, these techniques are most commonly conventional radiography, computed tomography (CT), magnetic imaging resonance (MRI), 3-phase bone scan (BS), fluorodeoxyglucose positron emission tomography (FDG-PET), and white blood cell (WBC) scintigraphy. The diagnostic performance of these imaging modalities has increased at an almost exponential rate in recent years, which makes it difficult to compare historical data with current practice. Only 1 study reviewed the recent literature (from 2000 to 2016) on imaging techniques, specifically for the diagnosis of FRI.<sup>23</sup>

Although no good quality study on the diagnostic value of conventional radiography in FRI exists, this modality is almost always requested first when an infectious complication related to a fracture is suspected.<sup>6</sup> It is easily available, cheap, quickly performed, and has a low radiation exposure. The radiograph provides baseline information regarding the

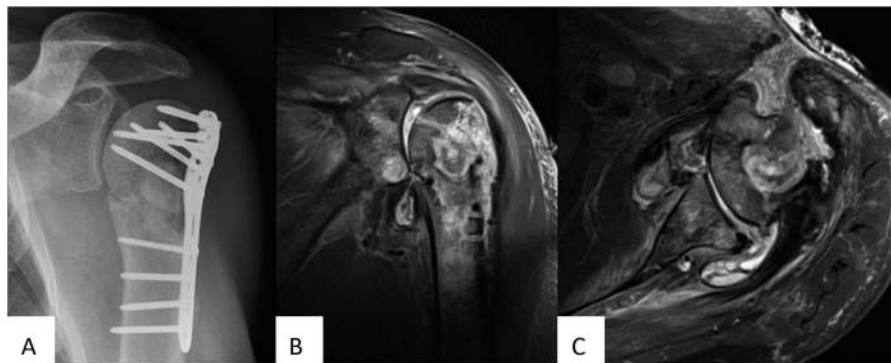
position of the fracture and the integrity and stability of any orthopaedic implant. A CT scan can be performed if more details are required and is better in revealing the presence of sequestra and bone cavities. However, its disadvantage is the radiation exposure and the low discriminatory capacity for FRI (sensitivity 47% and specificity 60%).<sup>23,24</sup> Universally accepted suggestive signs of infection on conventional radiography and CT scan are implant loosening, bone lysis, failure of progression of bone healing (nonunion), sequestration, and periosteal bone formation.<sup>7</sup>

MRI is very useful for the imaging of soft tissue pathology. It is also very sensitive for detecting morphologic bony changes, which makes it particularly useful in mapping specific surgical details, such as the extent of bone and soft tissue involvement and presence of sequestra, cloacae, sinus tracts, and/or subcortical abscesses. However, it can be difficult to distinguish between changes due to infection, inflammation, and normal tissue healing, and scattering from metal implants can obscure certain imaging details despite metal artifact reduction techniques. The sensitivity and specificity of MRI for the detection of FRI are reported to be between 82% and 100% and between 43% and 60%, respectively.<sup>23–25</sup>

Nuclear imaging of FRI mainly involves BS, WBC scintigraphy, and/or FDG-PET.<sup>6,26</sup> An important addition in recent times is the possibility of hybrid imaging (single photon emission CT [SPECT]/CT, PET/CT, PET/MRI), which allows for better anatomic details.<sup>27</sup> The sensitivity of BS is high (89%–100%), but its specificity is so low (0%–10%) that BS is not recommended in the workup of FRI.<sup>23,25,28,29</sup> The sensitivity and specificity of WBC scintigraphy + SPECT for diagnosing FRI is reported to be 79%–100% and 89%–97%, respectively.<sup>23,30–32</sup> A major advantage of WBC scintigraphy is that its accuracy is not influenced by recent surgery.<sup>32</sup> However, this technique is laborious and time consuming,<sup>30</sup> and it is less accurate in the axial skeleton.<sup>26,33</sup> FDG-PET is slightly less accurate compared with WBC scintigraphy but still suitable for diagnosing FRI. This technique is based on the consumption of glucose as an energy source by activated leukocytes, monocytes, lymphocytes, macrophages, and giant cells in infectious diseases. The major advantage of PET above SPECT is a higher spatial resolution and the fact that quantification possibilities are better with PET. Another advantage of FDG-PET is that it only requires one single scan in contrast to 2 imaging time points for WBC scintigraphy (respectively, 3–4 and 20–24 hours after reinjection of the labeled WBCs).<sup>26</sup> FDG-PET should however not be used for detecting FRI within 1 month after surgery.<sup>34</sup> The sensitivity and specificity of FDG-PET/CT for detecting FRI is between 65% and 94% and between 76% and 100%, respectively.<sup>23,34–38</sup> Figures 1–3 show examples of MRI, FDG-PET/CT, and WBC scintigraphy + SPECT/CT findings in FRI, respectively.

In conclusion, every option for medical imaging in FRI has both advantages and disadvantages, and currently, there is a lack of evidence to suggest that one technique is superior to another. Therefore, currently, radiological signs can only be regarded as a suggestive criterion for FRI.<sup>7</sup> Although nuclear imaging has a higher diagnostic accuracy, it is still not

**FIGURE 1.** Example of an x-ray (A) and T2-STIR MRI images (B coronal view, C sagittal view) performed in a patient with an infected proximal humerus fracture. The MRI demonstrated the extent of the infection with a skin defect, fluid/pus in the proximal humerus with surrounding edema, a sinus tract, and the involvement of the adjacent joint with possible involvement of the glenoid.



a conclusive test to establish the presence of FRI; therefore, it can also only be included in the FRI Consensus Definition as a suggestive criterion of FRI.

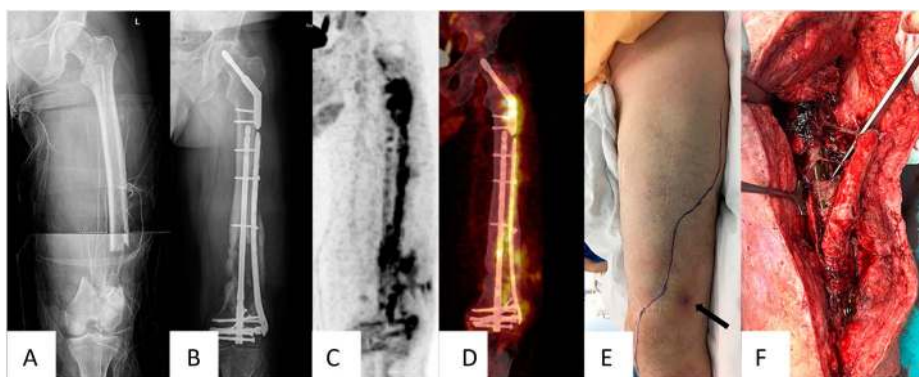
### Microbiology

The culture of distinct pathogens from at least 2 separate deep tissue/implant specimens is considered a confirmatory criterion of FRI.<sup>7</sup> In addition, the antibiotic susceptibility of the identified pathogens will guide the choice of antimicrobial treatment. Organisms causing chronic/late-onset infections around implants are often skin commensals and are therefore similar to those that can contaminate culture specimens during sampling or handling in the microbiology department. Additionally, organisms can be present in small numbers or may be in slow growth mode in a biofilm. Because false-positive or false-negative results can lead to erroneous treatment decisions, sampling and culturing techniques should be meticulous.

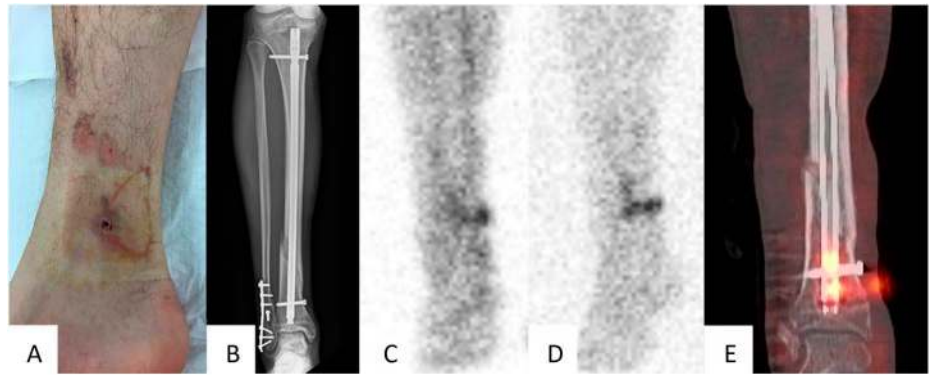
Surgical sampling protocols have been previously validated for PJI<sup>39</sup> and then applied to FRI.<sup>40,41</sup> All preoperative antibiotics should, where possible, be avoided for

a period of at least 2 weeks. Although small<sup>42,43</sup> and retrospective<sup>44</sup> PJI-related studies showed that a single dose of an antibiotic before skin incision makes no difference to the sensitivity of samples, there is a risk that growth of organisms in the laboratory could be inhibited in the presence of antibiotics.<sup>45,46</sup> It may therefore be more beneficial to administer antibiotics immediately *after* sampling in case of suspected infection. Preferably, 5 or more deep tissue or fluid samples should be collected,<sup>7,39,41,47,48</sup> ideally from the implant–bone interface. To avoid cross-contamination, it is recommended that manipulation of the target area during this procedure is minimized (“no-touch-technique”) and that separate, unused surgical instruments are used for each sample obtained. A simple sampling surgical instrument set can be assembled for this purpose.<sup>41</sup> Superficial, skin, or sinus tract samples should be avoided, as these will grow colonizing organisms with no predictive value for the causative pathogen of FRI.<sup>49</sup> Swabs should not be used due to their low yield compared with tissue cultures.<sup>50</sup> The application of this set of principles regarding tissue sampling techniques has shown to

**FIGURE 2.** A 57-year-old male patient sustained a combined left-sided neck-of-femur fracture, a patella fracture, and a Gustilo-Anderson type IIIB open intra-articular distal femur fracture with a segmental defect due to a motor vehicle accident (A: x-ray left femur, AP). The open reduction and internal fixation was complicated by a FRI for which an induced membrane (Masquelet) procedure was carried out combined with a 3-month antibiotic treatment. Despite the fact that the patient was full-weight bearing and pain free, 2.5 years later, a fistula developed at his distal lateral left thigh. An x-ray (AP) of the left femur (B) showed that the implants were intact, the neck-of-femur fracture was healed and that there was bone formation on the medial side of the femoral fracture and over the lateral plate. There was no consolidation of the femoral defect. Preoperative workup included an FDG-PET/CT to assess the extent of the FRI. This scan demonstrated that the complete femur and all implants were involved in the infection and also visualized the trajectory of the soft tissue fistula. C–F, 18F-FDG PET/CT: (C) coronal FDG-PET image, (D) coronal fused FDG-PET/CT image, (E) sagittal fused FDG-PET/CT image, (F) transaxial FDG-PET/CT image with evidence of soft tissue fistula. (E) Preoperative clinical image with fistula (black arrow). (F) Intraoperative clinical image: The bone overlying the lateral plate is removed, and the infection revealed. AP, Antero-posterior.



**FIGURE 3.** A fracture-related infection, caused by *Enterobacter cloacae*, in a 48-year-old man following intramedullary nailing of the tibia. A, The patient presented with a draining fistula at the level of one of the distal locking screws, 4 months after placement of an intramedullary tibial nail. B, AP x-ray of the right lower leg showing the intramedullary nail of the tibia and plate osteosynthesis of the fibula. C–D, Delayed (4 hours) and late (20 hours) static time decay corrected planar images (anterior view) of the lower leg, showing focally increased accumulation of WBCs at the level of the fistula extending toward the tibia. Note the increased tracer accumulation and increase in extension over time, indicating the presence of an infection. E, A fused SPECT-CT image of WBC scintigraphy (4 hours after tracer injection) showing focally increased accumulation of WBCs at the level of the fistula extending around the distal part of the nail and the distal locking screw.



significantly increase microbiological identification with more certainty of causative pathogens for FRI.<sup>41</sup>

Bone needle aspiration and closed bone needle biopsy, although important in other clinical infectious scenarios, do not appear to be useful in FRI. Bone needle aspiration has primarily been used in pediatric osteomyelitis<sup>51</sup> and vertebral osteomyelitis<sup>52</sup> but has not been studied in FRI. Image-guided closed bone needle biopsy has not been investigated specifically in FRI. Closed bone biopsy cultures in chronic osteomyelitis have been shown to have a poor yield.<sup>53–56</sup> Moreover, in FRI, surgical debridement is required for the collection of deep tissue samples. Therefore, the use of bone needle aspiration or closed bone needle biopsy is not advocated in FRI.

Blood cultures should be taken in case of fever (single oral temperature measurement of  $\geq 38.3^{\circ}\text{C}$  [ $101^{\circ}\text{F}$ ]). In cases of chronic/late-onset FRI, blood cultures exhibit a low yield rate, especially when compared with tissue cultures, because few of these FRI cases are associated with bacteremia.

Microbiology laboratory operating procedures for processing samples from FRI should be optimized. The relevant stages are as follows: (1) recognizing that these are deep implant-related samples and therefore processing each sample separately (no pooling of specimens), (2) considering methods to disrupt potential biofilm, (3) culturing using appropriate enrichment media (eg, blood culture bottles<sup>57</sup>) for sufficient duration, and (4) full identification and a broad antibiogram on each organism to facilitate differentiation of strains and to allow several options for antimicrobial treatment.

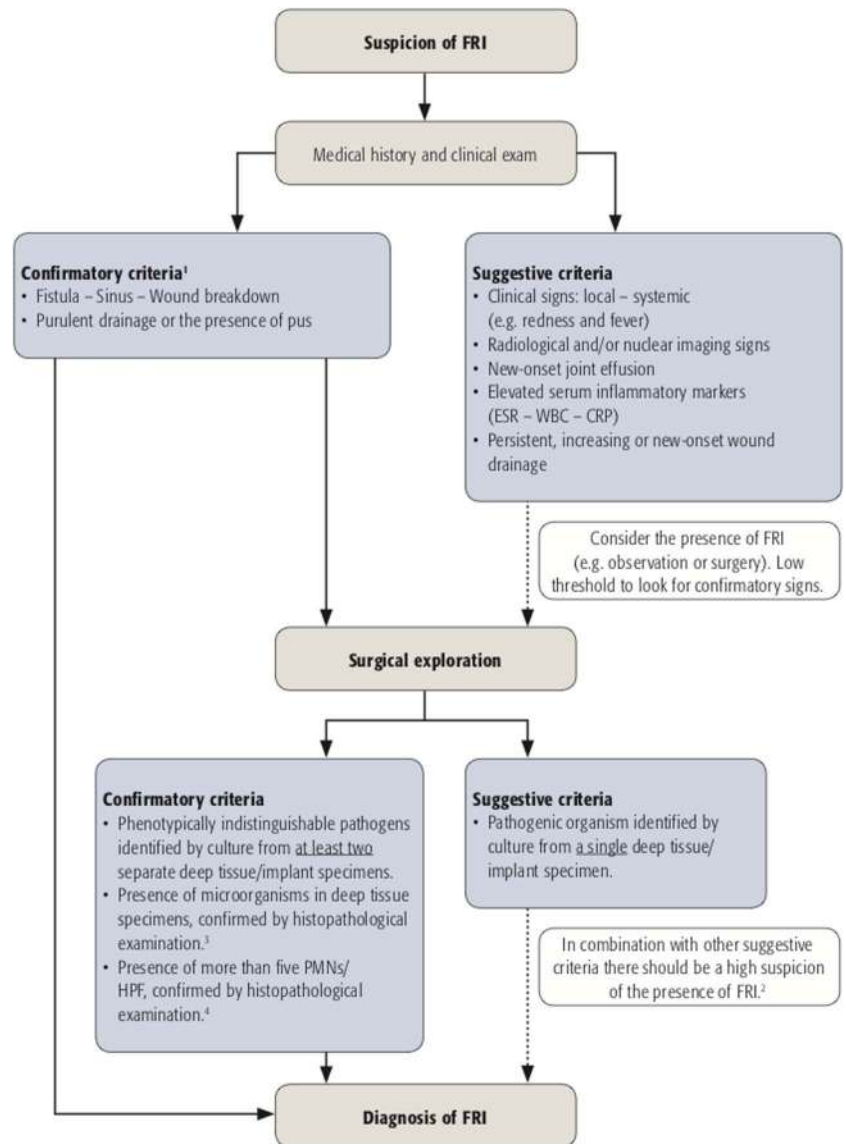
Methods to facilitate biofilm disruption of tissue samples include vortexing with sterile glass beads, possibly with a bead mill or vortexing alone.<sup>58,59</sup> As organisms can exist in slow growth mode and small numbers, enrichment broth cultures are essential.<sup>60</sup> In subacute or chronic infections, plate cultures are not necessary and have low sensitivity. Enrichment broths can be subcultured when cloudy or after a defined period (eg, five days). However, some organisms take longer to grow and require a later subculture.<sup>61</sup>

Using automated methods, cultures that contain pathogens are usually positive by day 3 and most are positive by day 5.<sup>62,63</sup> To culture the slower growing organisms, cultures should continue for 10–14 days, depending on the detection method. When cultures are positive, all isolates should be worked up with standard laboratory identification methods, and an extended antibiogram should be obtained.

Sonication of hard materials can be considered (eg, plates, intramedullary nails, cortical bone), but each component only represents one sample. A semiquantitative cutoff point for the number of colony-forming units helps to differentiate infection from contamination in PJI.<sup>64</sup> However, as fracture fixation components may not be removed until some time after start of the surgery and surgical sites can become contaminated, these results also need to be interpreted in context with other diagnostic findings.<sup>65</sup> In PJI, it is reported that sonication fluid culture is more sensitive than tissue culture when antimicrobial agents are discontinued within 14 days before surgery.<sup>64</sup> The available evidence on sonication fluid sampling and tissue tests (molecular diagnostics and histopathology) for the diagnosis of FRI was analyzed in a recent systematic review<sup>66</sup> and showed that for FRI, there is evidence that sonication fluid culture may be a useful adjunct to conventional tissue culture, but it is not superior. Overall, studies had variable “gold standard” definition criteria for comparison and poorly reported culture methods. The authors concluded that scientific evidence on the accuracy of sonication fluid culture for diagnosing FRI is scarce. A recent study on the performance of paired tissue and sonication cultures against a “gold-standard” of published clinical and composite clinical and microbiological definitions of infection found that tissue sampling is superior to sonication.<sup>47</sup>

In conclusion, a strict and clear protocol for tissue sampling and laboratory methods for FRI should be adhered to optimize diagnosis, management, and long-term outcome. Although sonication seems to be a useful adjunct to conventional tissue culture, its real added value in the diagnostic process of FRI still needs to be established.





**FIGURE 4.** Descriptive flow chart of the diagnostic criteria of FRI. Adapted from Metsemakers et al, *Injury* 2018.<sup>7</sup> Reprinted from Metsemakers WJ et al., Fracture-related infection: a consensus on definition from an international expert group. 2018 *Injury*:49/Issue 6, with permission from Elsevier. All permission requests for this image should be made to the copyright holder.

<sup>1</sup> In cases of purulent drainage or fistula/sinus/wound breakdown, the presence of pathogens identified by culture is not an absolute requirement (e.g. in the case of chronic antibiotic suppression).  
<sup>2</sup> If the positive culture is from sonication fluid, it is highly likely that FRI is present. This is especially true when virulent bacteria (i.e. *Staphylococcus aureus*) are present.  
<sup>3</sup> The presence of microorganisms is confirmed by using specific staining techniques for bacteria and fungi.  
<sup>4</sup> The presence of an average of more than five PMNs/HPF on histopathological examination should only be considered diagnostic of FRI in chronic/late-onset cases (e.g. fracture nonunion).  
 ESR: erythrocyte sedimentation rate, WBC: white blood cell count, CRP: C-reactive protein, PMN(s): polymorphonuclear neutrophil(s), HPF: high-power field.

### Molecular Biology

Polymerase chain reaction (PCR) is a technique that can be used to amplify bacterial DNA. In the past, the amplified PCR products were revealed by electrophoresis in an agarose gel (gel-based PCR). Over the past few years, most gel-based PCR assays have been replaced by real-time PCR. Real-time PCR has the advantage of speed and being less prone to cross contamination because it is performed in a closed system.<sup>67</sup> It is reported that molecular techniques performed on tissue,

synovial fluid, or sonication fluid can confer valuable additional information in PJI,<sup>68</sup> but in FRI, the evidence is less clear.<sup>69</sup> In the aforementioned systematic review, the diagnostic value of PCR techniques for FRI was studied.<sup>66</sup> Two studies were included.<sup>70,71</sup> The first study reported that 16S ribosomal RNA PCR of deep wound swabs is inferior to standard tissue cultures.<sup>70</sup> Unfortunately, this observation is of limited value because deep tissue swabs are not standard of care because they do not sufficiently represent the pathogens

**TABLE 1.** Key Recommendations

---

The diagnosis of FRI should always be considered in case of impaired fracture healing.
The presence of confirmatory signs of FRI should prompt the treating, multidisciplinary, medical team to proceed with developing a treatment strategy.
The presence of suggestive signs of FRI should prompt the treating, multidisciplinary, medical team to further investigate the probability of an FRI.
The only confirmatory clinical signs of FRI are the presence of a fistula, sinus, or wound breakdown and/or purulent drainage from the wound or presence of pus during surgery.
Caution when interpreting the results of serum inflammatory markers in FRI is warranted, as their predictive value is low.
The imaging modality of choice depends on the local availability of the technique and the questions to be answered.
Nuclear imaging (FDG-PET/CT or WBC scintigraphy + SPECT/CT) is more accurate than MRI for detecting FRI, but MRI is better in visualizing surgical relevant details. Therefore, apart from radiological signs, nuclear medicine signs should be included in the diagnostic pathway (definition) of FRI.
As evidence on histopathology is accumulating, it seems appropriate to include it in the diagnostic pathway (definition) of FRI for chronic/late-onset cases (eg, nonunion).

---

in the bone.<sup>50</sup> The other study focused on the validation of multiplex PCR on sonication fluid.<sup>71</sup> It was found that the performance of sonication fluid PCR for the diagnosis of FRI was comparable to tissue culture tests.

In conclusion, evidence for the diagnostic value of molecular techniques for FRI is scarce and based on small studies. Its benefit for diagnosing FRI has not yet been established and further research and improvement of diagnostic performance is warranted.

### Histopathology

In PJI, the presence of  $\geq 5$  polymorphonuclear neutrophils per high-power field (PMN/HPF) in 5 high-power fields observed from histopathologic analysis of periprosthetic tissue, at  $\times 400$  magnification, is considered to be an important intraoperative criterion for PJI.<sup>4</sup> In the FRI consensus definition, the presence of visible microorganisms in deep tissue specimens using specific staining techniques for bacteria and fungi is regarded a confirmatory sign of FRI.<sup>7</sup> The evidence on histopathological examination of tissue specimens for FRI has also been reviewed<sup>66</sup> and seems to be an underdeveloped area because only 3 studies could be included. Recently, however, a study on the value of quantitative histopathology for the diagnosis of chronic/late-onset FRI has been published.<sup>72</sup> In this study, a novel bimodal approach was used to confirm or exclude infection. The complete absence of PMNs had a very high correlation with aseptic nonunion (specificity 98%, positive predictive value 98%). On the other hand, the presence of  $> 5$  PMN/HPF was always associated with infection (specificity 100%; positive predictive value 100%). The combination of clinical signs,  $\geq 2$  microbiological cultures, and bimodal histopathological analysis (absent NPs vs.  $> 5$  PMNs/HPF) improved diagnostic accuracy in up to 96.8% of cases. The authors of this study recommend that these histopathological criteria can be considered diagnostic of infection in chronic/late-onset FRI (eg, fracture nonunion).

In conclusion, the histopathologically confirmation of the presence of microorganisms by specific staining techniques on deep tissue specimens is a confirmatory sign of FRI.<sup>7</sup> The value of histopathological criteria related to acute inflammatory cell infiltrates (absent PMNs vs.  $> 5$  PMNs/HPF) is now also established for chronic/late-onset cases (ie, fracture nonunion) and should therefore be included in the FRI consensus definition as a confirmatory criterion.

### CONCLUSIONS

In summary, there is limited scientific evidence regarding diagnostic criteria for FRI. Only a small number of studies are available concerning the diagnostic accuracy of serum inflammatory markers, imaging modalities, tissue and sonication fluid sampling, molecular biology, and histopathology for FRI. Validation studies on the value of clinical parameters for diagnosing this condition are nonexistent. This lack of scientific evidence precludes the development of a diagnostic pathway that is solely based on sound evidence. The recently published FRI consensus definition seems an adequate start and offers clinicians the opportunity to standardize clinical reports and improve the quality of published literature. It should also lead to a standardized clinical approach toward the diagnostic workup of patients with (suspected) FRI.

Apart from the established criteria, there is growing evidence that nuclear medicine imaging and histopathology should play a role in this diagnostic process. During a second consensus meeting in 2018—including not only experts from the AO Foundation and the EBJS but also from the Orthopaedic Trauma Association and the PRO-Implant foundation—it was therefore decided that these 2 criteria should be included in the FRI consensus definition. Figure 4 shows an update on the current diagnostic criteria. Key recommendations for the diagnosis of FRI are displayed in Table 1. Within the short period since publication, the consensus definition of FRI has already been applied in the design of 2 clinical studies.<sup>72,73</sup> The continued adoption and evaluation of this definition in further clinical studies will allow validation of the definition and improve the quality of comparative outcome studies in the future.

### ACKNOWLEDGMENTS

*The authors specifically thank the Anti-Infection Task Force (AOTK System; Claas Albers) and the Clinical Priority Program Bone Infection (AOTrauma; Philipp Buescher) for their support of the consensus meetings that were convened in 2016 (Davos, Switzerland) and 2018 (Zürich, Switzerland). Furthermore, the authors thank Jolien Onsea (Department of Trauma Surgery, University Hospitals Leuven) and Lois Wallach (AOTK System) for their assistance in preparing and proofreading this manuscript.*

*Members of the FRI Consensus Group: W.-J. Metsemakers, MD, PhD (chair): Department of Trauma Surgery, University Hospitals Leuven, Leuven, Belgium; W. T. Obremskey,*

MD, MPH (chair): Department of Orthopaedic Surgery and Rehabilitation, Vanderbilt University Medical Center, Nashville, TN; M. A. McNally, MD, FRCS(Orth) (Chair): The Bone Infection Unit, Nuffield Orthopaedic Centre, Oxford University Hospitals, Oxford, United Kingdom; Nick Athanasou, MD, PhD, MRCP, FRCPath: The Bone Infection Unit, Nuffield Orthopaedic Centre, Oxford University Hospitals, Oxford, United Kingdom; B. L. Atkins, MD, MBBS, MSc, FRCP, FRCPath: The Bone Infection Unit, Nuffield Orthopaedic Centre, Oxford University Hospitals, Oxford, United Kingdom; Olivier Borens, MD, PhD: Orthopedic Department of Septic Surgery, Orthopaedic-Trauma Unit, Department for the Musculoskeletal System, CHUV, Lausanne, Switzerland; Melissa Depytere, MD: Department of Laboratory Medicine, University Hospitals Leuven, Leuven, Belgium; Henrik Eckardt, MD: Department of Orthopaedic and Trauma Surgery, University Hospital Basel, Basel, Switzerland; Kenneth A. Egol, MD: Department of Orthopedic Surgery, NYU Langone Orthopedic Hospital, New York, NY; William Foster, MD: Department of Orthopaedic Surgery, Virginia Commonwealth University, Richmond, VA, USA; Austin T. Fragomen, MD: Hospital for Special Surgery, Limb Lengthening & Complex Reconstruction Service, New York, NY; G. A. M. Govaert, MD, PhD: Department of Trauma Surgery, University of Utrecht, University Medical Center Utrecht, Utrecht, the Netherlands; Sven Hungerer, MD: Department of Joint Surgery and Arthroplasty, Trauma Center Murnau, Murnau Germany and Paracelsus Medical University (PMU) Salzburg, Salzburg, Austria; Stephen L. Kates, MD: Department of Orthopaedic Surgery, Virginia Commonwealth University, Richmond, VA, USA; R. Kuehl, MD: Department of Infectious Diseases and Hospital Epidemiology, University Hospital of Basel, Basel, Switzerland; Leonard Marais, MD, PhD: Department of Orthopaedics, School of Clinical Medicine, University of KwaZulu-Natal, Durban, South Africa; Ian Mcfadyen, MD: Department of Orthopaedic Surgery, University Hospitals of North Midlands, Stoke-on-Trent, United Kingdom; M. Morgenstern: Department of Orthopaedic and Trauma Surgery, University Hospital Basel, Basel, Switzerland; T. Fintan Moriarty, PhD: AO Research Institute Davos, Davos, Switzerland; Peter Ochsner, MD: Medical University Basel, Basel, Switzerland; Alex Ramsden, MD: The Bone Infection Unit, Nuffield Orthopaedic Centre, Oxford University Hospitals, Oxford, United Kingdom; Michael Raschke, MD, PhD: Department of Trauma Surgery, University Hospital of Münster, Münster, Germany; R. Geoff Richards, PhD: AO Research Institute Davos, Davos, Switzerland; Carlos Sancineto, MD: Department of Orthopaedics, Hospital Italiano de Buenos Aires, Buenos Aires, Argentina; Charalampos Zalavras, MD, PhD: Department of Orthopaedic Surgery, Keck School of Medicine, University of Southern California, Los Angeles, CA; Eric Senneville, MD, PhD: Department of Infectious Diseases, Gustave Dron Hospital, University of Lille, Lille, France; Andrej Trampuz, MD: Center for Musculoskeletal Surgery, Charité-Universitätsmedizin Berlin, corporate member of Freie Universität Berlin,

Humboldt-Universität zu Berlin, and Berlin Institute of Health, Berlin, Germany; Michael H.J. Verhofstad, MD, PhD: Department of Trauma Surgery, Erasmus University Medical Centre, Rotterdam, the Netherlands; and Werner Zimmerli, MD: Interdisciplinary Unit for Orthopedic Infections, Kantonsspital Baselland, Switzerland.

## REFERENCES

1. Metsemakers WJ, Kortram K, Morgenstern M, et al. Definition of infection after fracture fixation: a systematic review of randomized controlled trials to evaluate current practice. *Injury*. 2018;49:497–504.
2. Metsemakers WJ, Moriarty TF, Morgenstern M, et al. Letter to the editor: new definition for periprosthetic joint infection: from the workgroup of the musculoskeletal infection Society. *Clin Orthop Relat Res*. 2016;474:2726–2727.
3. Parvizi J, Zmistowski B, Berbari EF, et al. New definition for periprosthetic joint infection: from the Workgroup of the Musculoskeletal Infection Society. *Clin Orthop Relat Res*. 2011;469:2992–2994.
4. Parvizi J, Tan TL, Goswami K, et al. The 2018 definition of periprosthetic hip and knee infection: an evidence-based and validated criteria. *J Arthroplasty*. 2018;33:1309–1314 e1302.
5. Morgenstern M, Moriarty TF, Kuehl R, et al. International survey among orthopaedic trauma surgeons: lack of a definition of fracture-related infection. *Injury*. 2018;49:491–496.
6. Govaert GAM, Glaudemans A, Ploegmakers JJW, et al. Diagnostic strategies for posttraumatic osteomyelitis: a survey amongst Dutch medical specialists demonstrates the need for a consensus protocol. *Eur J Trauma Emerg Surg*. 2018;44:417–426.
7. Metsemakers WJ, Morgenstern M, McNally MA, et al. Fracture-related infection: a consensus on definition from an international expert group. *Injury*. 2018;49:505–510.
8. Cats-Baril W, Gehrke T, Huff K, et al. International consensus on periprosthetic joint infection: description of the consensus process. *Clin Orthop Relat Res*. 2013;471:4065–4075.
9. Bezstarosti H, Van Lieshout EMM, Voskamp LW, et al. Insights into treatment and outcome of fracture-related infection: a systematic literature review. *Arch Orthop Trauma Surg*. 2019;139:61–72.
10. Nicolas-Avila JA, Adrover JM, Hidalgo A. Neutrophils in homeostasis, immunity, and cancer. *Immunity*. 2017;46:15–28.
11. Teng TS, Ji AL, Ji XY, et al. Neutrophils and immunity: from bactericidal action to being conquered. *J Immunol Res*. 2017;2017:9671604.
12. Kraft CN, Kruger T, Westhoff J, et al. CRP and leukocyte-count after lumbar spine surgery: fusion vs. nucleotomy. *Acta Orthop*. 2011;82:489–493.
13. Sproston NR, Ashworth JJ. Role of C-reactive protein at sites of inflammation and infection. *Front Immunol*. 2018;9:754.
14. Lu J, Marnell LL, Marjon KD, et al. Structural recognition and functional activation of FcγR by innate pentraxins. *Nature*. 2008;456:989–992.
15. Neumaier M, Scherer MA. C-reactive protein levels for early detection of postoperative infection after fracture surgery in 787 patients. *Acta Orthop*. 2008;79:428–432.
16. Kunakornsawat S, Tungsiripat R, Putthiwara D, et al. Postoperative kinetics of C-reactive protein and erythrocyte sediment rate in one-, two-, and multilevel posterior spinal decompressions and instrumentations. *Global Spine J*. 2017;7:448–451.
17. Brown KA, Brain SD, Pearson JD, et al. Neutrophils in development of multiple organ failure in sepsis. *Lancet*. 2006;368:157–169.
18. Chmielewski PP, Strzelec B. Elevated leukocyte count as a harbinger of systemic inflammation, disease progression, and poor prognosis: a review. *Folia Morphol (Warsz)*. 2018;77:171–178.
19. Ettinger M, Calliess T, Kielstein JT, et al. Circulating biomarkers for discrimination between aseptic joint failure, low-grade infection, and high-grade septic failure. *Clin Infect Dis*. 2015;61:332–341.
20. Fischer CL, Gill C, Forrester MG, et al. Quantitation of “acute-phase proteins” postoperatively: value in detection and monitoring of complications. *Am J Clin Pathol*. 1976;66:840–846.
21. Scherer MA, Neumaier M, von Gumpfenberg S. C-reactive protein in patients who had operative fracture treatment. *Clin Orthop Relat Res*. 2001:287–293.



22. van den Kieboom J, Bosch P, Plate DJJ, et al. Diagnostic accuracy of serum inflammatory markers in late fracture-related infection: a systematic review and meta-analysis. *Bone Joint J.* 2018;100B:1542–1550.
23. Govaert GA, FF IJ, McNally M, et al. Accuracy of diagnostic imaging modalities for peripheral post-traumatic osteomyelitis—a systematic review of the recent literature. *Eur J Nucl Med Mol Imaging.* 2017;44:1393–1407.
24. Goebel M, Rosa F, Tatsch K, et al. Diagnosis of chronic osteitis of the bones in the extremities: relative value of F-18 FDG-PET [in German]. *Unfallchirurg.* 2007;110:859–866.
25. Kaim A, Ledermann HP, Bongartz G, et al. Chronic post-traumatic osteomyelitis of the lower extremity: comparison of magnetic resonance imaging and combined bone scintigraphy/immunoscintigraphy with radiolabelled monoclonal antigranulocyte antibodies. *Skeletal Radiol.* 2000;29:378–386.
26. Govaert GA, Glaudemans AW. Nuclear medicine imaging of posttraumatic osteomyelitis. *Eur J Trauma Emerg Surg.* 2016;42:397–410.
27. Glaudemans AW, Prandini N, DI Girolamo M, et al. Hybrid imaging of musculoskeletal infections. *Q J Nucl Med Mol Imaging.* 2018;62:3–13.
28. Ballani NS, Al-Huda FA, Khan HA, et al. The value of quantitative uptake of (99m)Tc-MDP and (99m)Tc-HMPAO white blood cells in detecting osteomyelitis in violated peripheral bones. *J Nucl Med Technol.* 2007;35:91–95.
29. Meller J, Koster G, Liersch T, et al. Chronic bacterial osteomyelitis: prospective comparison of (18)F-FDG imaging with a dual-head coincidence camera and (111)In-labelled autologous leucocyte scintigraphy. *Eur J Nucl Med Mol Imaging.* 2002;29:53–60.
30. Glaudemans AW, de Vries EF, Vermeulen LE, et al. A large retrospective single-centre study to define the best image acquisition protocols and interpretation criteria for white blood cell scintigraphy with (9)(9m)Tc-HMPAO-labelled leucocytes in musculoskeletal infections. *Eur J Nucl Med Mol Imaging.* 2013;40:1760–1769.
31. Horger M, Eschmann SM, Pfannenber C, et al. The value of SPET/CT in chronic osteomyelitis. *Eur J Nucl Med Mol Imaging.* 2003;30:1665–1673.
32. Govaert GAM, Bosch P, FFA IJ, et al. High diagnostic accuracy of white blood cell scintigraphy for fracture related infections: results of a large retrospective single-center study. *Injury.* 2018;49:1085–1090.
33. Glaudemans AW, Galli F, Pacilio M, et al. Leukocyte and bacteria imaging in prosthetic joint infection. *Eur Cell Mater.* 2013;25:61–77.
34. Lemans JVC, Hobbelink MGG, FFA IJ, et al. The diagnostic accuracy of (18)F-FDG PET/CT in diagnosing fracture-related infections. *Eur J Nucl Med Mol Imaging.* 2019;46:999–1008.
35. Hartmann A, Eid K, Dora C, et al. Diagnostic value of 18F-FDG PET/CT in trauma patients with suspected chronic osteomyelitis. *Eur J Nucl Med Mol Imaging.* 2007;34:704–714.
36. Shemesh S, Kosashvili Y, Groshar D, et al. The value of 18-FDG PET/CT in the diagnosis and management of implant-related infections of the tibia: a case series. *Injury.* 2015;46:1377–1382.
37. van Vliet KE, de Jong VM, Termaat MF, et al. FDG-PET/CT for differentiating between aseptic and septic delayed union in the lower extremity. *Arch Orthop Trauma Surg.* 2018;138:189–194.
38. Wenter V, Muller JP, Albert NL, et al. The diagnostic value of [(18)F] FDG PET for the detection of chronic osteomyelitis and implant-associated infection. *Eur J Nucl Med Mol Imaging.* 2016;43:749–761.
39. Atkins BL, Athanasou N, Deeks JJ, et al. Prospective evaluation of criteria for microbiological diagnosis of prosthetic-joint infection at revision arthroplasty: the OSIRIS Collaborative Study Group. *J Clin Microbiol.* 1998;36:2932–2939.
40. McNally MA. Infection after fracture. In: Kates SL, Borens O, eds *Principles of Orthopedic Infection Management.* New York, NY: AO Trauma Thieme Verlag; 2016:139–165.
41. Hellebrekers P, Rentenaar RJ, McNally MA, et al. Getting it right first time: the importance of a structured tissue sampling protocol for diagnosing fracture-related infections. *Injury.* 2019 [epub ahead of print].
42. Perez-Prieto D, Portillo ME, Puig-Verdie L, et al. Preoperative antibiotic prophylaxis in prosthetic joint infections: not a concern for intraoperative cultures. *Diagn Microbiol Infect Dis.* 2016;86:442–445.
43. Bedencic K, Kavcic M, Faganeli N, et al. Does preoperative antimicrobial prophylaxis influence the diagnostic potential of periprosthetic tissues in hip or knee infections? *Clin Orthop Relat Res.* 2016;474:258–264.
44. Wouthuyzen-Bakker M, Tornero E, Claret G, et al. Withholding preoperative antibiotic prophylaxis in knee prosthesis revision: a retrospective analysis on culture results and risk of infection. *J Arthroplasty.* 2017;32:2829–2833.
45. Miller NS, Rogan D, Orr BL, et al. Comparison of BD Bactec Plus blood culture media to VersaTREK Redox blood culture media for detection of bacterial pathogens in simulated adult blood cultures containing therapeutic concentrations of antibiotics. *J Clin Microbiol.* 2011;49:1624–1627.
46. Grupper M, Nicolau DP, Aslanzadeh J, et al. Effects of clinically meaningful concentrations of antipseudomonal beta-lactams on time to detection and organism growth in blood culture bottles. *J Clin Microbiol.* 2017;55:3502–3512.
47. Dudareva M, Barrett L, Figtree M, et al. Sonication versus tissue sampling for diagnosis of prosthetic joint and other orthopaedic device-related infections. *J Clin Microbiol.* 2018;56.
48. Dudareva M, Barrett L, Morgenstern M, et al. An evidence base for tissue sampling and culture interpretation in fracture-related infection. *Orthop Proc.* 2018;100B:15.
49. Mackowiak PA, Jones SR, Smith JW. Diagnostic value of sinus-tract cultures in chronic osteomyelitis. *JAMA.* 1978;239:2772–2775.
50. Aggarwal VK, Higuera C, Deimengian G, et al. Swab cultures are not as effective as tissue cultures for diagnosis of periprosthetic joint infection. *Clin Orthop Relat Res.* 2013;471:3196–3203.
51. Schlung JE, Bastrom TP, Roocroft JH, et al. Femoral neck aspiration aids in the diagnosis of osteomyelitis in children with septic hip. *J Pediatr Orthop.* 2018;38:532–536.
52. Pupaibool J, Vasoo S, Erwin PJ, et al. The utility of image-guided percutaneous needle aspiration biopsy for the diagnosis of spontaneous vertebral osteomyelitis: a systematic review and meta-analysis. *Spine J.* 2015;15:122–131.
53. Beroukhi G, Shah R, Bucknor MD. Factors predicting positive culture in CT-guided bone biopsy performed for suspected osteomyelitis. *AJR Am J Roentgenol.* 2019;212:620–624.
54. Hoang D, Fisher S, Oz OK, et al. Percutaneous CT guided bone biopsy for suspected osteomyelitis: diagnostic yield and impact on patient's treatment change and recovery. *Eur J Radiol.* 2019;114:85–91.
55. Said N, Chalian M, Fox MG, et al. Percutaneous image-guided bone biopsy of osteomyelitis in the foot and pelvis has a low impact on guiding antibiotics management: a retrospective analysis of 60 bone biopsies. *Skeletal Radiol.* 2019;48:1385–1391.
56. Wu JS, Gorbachova T, Morrison WB, et al. Imaging-guided bone biopsy for osteomyelitis: are there factors associated with positive or negative cultures? *AJR Am J Roentgenol.* 2007;188:1529–1534.
57. Peel TN, Dylla BL, Hughes JG, et al. Improved diagnosis of prosthetic joint infection by culturing periprosthetic tissue specimens in blood culture bottles. *MBio.* 2016;7:e01776–e01715.
58. Roux AL, Sivadon-Tardy V, Bauer T, et al. Diagnosis of prosthetic joint infection by beadmill processing of a periprosthetic specimen. *Clin Microbiol Infect.* 2011;17:447–450.
59. Suren C, Harrasser N, Pohl F, et al. Prospective analysis of a sterile, semi-automated tissue biopsy homogenization method in the diagnosis of prosthetic joint infections. *In Vivo.* 2017;31:937–942.
60. Hughes HC, Newnham R, Athanasou N, et al. Microbiological diagnosis of prosthetic joint infections: a prospective evaluation of four bacterial culture media in the routine laboratory. *Clin Microbiol Infect.* 2011;17:1528–1530.
61. Schafer P, Fink B, Sandow D, et al. Prolonged bacterial culture to identify late periprosthetic joint infection: a promising strategy. *Clin Infect Dis.* 2008;47:1403–1409.
62. Minassian AM, Newnham R, Kalimeris E, et al. Use of an automated blood culture system (BD BACTEC) for diagnosis of prosthetic joint infections: easy and fast. *BMC Infect Dis.* 2014;14:233.
63. Patel R. MALDI-TOF MS for the diagnosis of infectious diseases. *Clin Chem.* 2015;61:100–111.
64. Trampuz A, Piper KE, Jacobson MJ, et al. Sonication of removed hip and knee prostheses for diagnosis of infection. *N Engl J Med.* 2007;357:654–663.
65. Jonsson EO, Johannesdottir H, Robertsson O, et al. Bacterial contamination of the wound during primary total hip and knee replacement: median 13 years of follow-up of 90 replacements. *Acta Orthop.* 2014;85:159–164.

66. Onsea J, Depypere M, Govaert G, et al. Accuracy of tissue and sonication fluid sampling for the diagnosis of fracture-related infection: a systematic review and critical appraisal. *J Bone Joint Infect*. 2018;3:173–181.
67. Hartley JC, Harris KA. Molecular techniques for diagnosing prosthetic joint infections. *J Antimicrob Chemother*. 2014;69(suppl 1):i21–i24.
68. Morgenstern C, Cabric S, Perka C, et al. Synovial fluid multiplex PCR is superior to culture for detection of low-virulent pathogens causing periprosthetic joint infection. *Diagn Microbiol Infect Dis*. 2018;90:115–119.
69. Morgenstern M, Kuhl R, Eckardt H, et al. Diagnostic challenges and future perspectives in fracture-related infection. *Injury*. 2018;49(suppl 1):S83–S90.
70. Omar M, Suero EM, Lioudakis E, et al. Diagnostic performance of swab PCR as an alternative to tissue culture methods for diagnosing infections associated with fracture fixation devices. *Injury*. 2016;47:1421–1426.
71. Renz N, Cabric S, Morgenstern C, et al. Value of PCR in sonication fluid for the diagnosis of orthopedic hardware-associated infections: has the molecular era arrived? *Injury*. 2018;49:806–811.
72. Morgenstern M, Athanasou NA, Ferguson JY, et al. The value of quantitative histology in the diagnosis of fracture-related infection. *Bone Joint J*. 2018;100B:966–972.
73. Govaert GAM, Hobbelen MGG, Reininga IHF, et al. The accuracy of diagnostic imaging techniques in patients with a suspected fracture-related infection (IFI) trial: study protocol for a prospective multicenter cohort study. *BMJ Open*. 2019;9:e027772.