

Diagnosis and Treatment of Coats' Disease: A Review of the Literature

Samim Ghorbanian^a Adil Jaulim^a Irini P. Chatziralli^b

^aBarts and the London School of Medicine and Dentistry, Queen Mary University of London, and

^bDepartment of Ophthalmology, Barts and the London NHS Trust, London, UK

Key Words

Coats' disease · Treatment · Diagnosis · Review

Abstract

Coats' disease is an idiopathic, ophthalmic condition characterized by retinal telangiectasis, intraretinal and subretinal exudation, which can lead to retinal detachment. It is mostly unilateral, progressive and affects mainly males during childhood, although adult cases have also been described. In this review, we make an update of the literature about Coats' disease, emphasizing on diagnosis and treatment, including the most recent treatment modalities, i.e. anti-vascular endothelial growth factor agents.

Copyright © 2012 S. Karger AG, Basel

Introduction

Coats' disease is an idiopathic, ophthalmic condition caused by a defect in the development of retinal vasculature, characterized by retinal telangiectasis, haemorrhage, intraretinal and subretinal exudation [1–3]. It was first described in 1908 by George Coats, a Scottish medical student, as a unilateral condition with retinal exudation and telangiectasis in male children. Four years later, Leber defined a similar condition albeit more severe, in which there were multiple retinal aneurysms, as well as

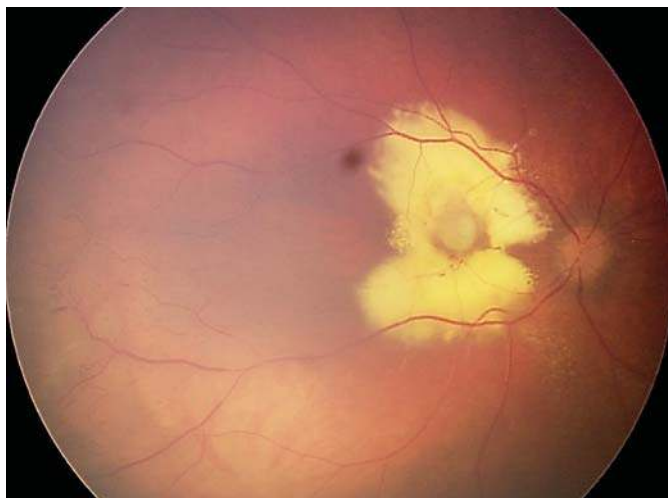
retinal detachment rather than telangiectasis [2]. For the first half of the 20th century, these clinical entities were considered as separate conditions. It was Reese who noted the overlapping between the two conditions and made the clarification that Leber miliary aneurysms were simply a progression of Coats' disease [2]. Subsequently, Shields et al. [2] defined Coats' disease as '*Idiopathic retinal teleangiectasia associated with intraretinal exudation and frequent exudative retinal detachment without signs of appreciable retinal or vitreal traction*'.

In this review, our purpose is to make an update of the literature about Coats' disease, emphasizing on diagnosis and treatment. Eligible papers were identified using a comprehensive literature search of PubMed, using the term 'Coats' disease'. Additional papers were also selected from reference lists of papers identified by the electronic database search.

Pathogenesis and Classification

Coats' disease is a mostly unilateral, progressive condition affecting mainly males during childhood, with the average age of diagnosis being between 8 and 16 years,

S.G. and A.J. share the first authorship.



Color version available online

Fig. 1. Colour fundus photo of a 2-year-old male patient presenting with Coats' disease at the age of 13 months. In the figure, exudates and telangiectasis are present as well as dilation of retinal vessels, confirming Coats' disease ('light-bulb').

although several cases have also been reported in adults [4–11]. It is often described as 'light bulb telangiectasia' due to the large amounts of yellow exudates accompanying the condition [5].

There are two pathological processes which are evident in Coats' disease. The first consists of a breakdown of the blood-retinal barrier at the endothelial level, which causes plasma leakage into the vessel wall and thickening of parts of the vessel wall, becoming necrotic and disorganized and producing what Egbert et al. [12] have described as a 'sausage-like' shape of the vessel. The second concerns the presence of abnormal pericytes and endothelial cells in retinal blood vessels, which subsequently degenerate, causing abnormal retinal vasculature and formation of aneurysms, as well as closure of vessels, leading to ischaemia [13]. Noticeably, Jones et al. [1] describe the process as being similar to that of diabetic retinopathy. The loss of endothelial cells and pericytes from the capillaries and the dilated telangiectatic arterioles causes leakage of a lipid-rich exudate into the retina, which can lead to changes in the retina, including thickening, cyst formation or retinal detachment [13, 14].

There are several studies assuming that the condition is idiopathic without a familial link [1, 2, 15] whereas others suggest that there may be a genetic cause [16–18]. Specifically, it is hypothesized that Coats' disease could be a consequence of a mutation in the NDP gene, which results in a deficiency of norrin, a protein thought to be

Table 1. Classification of Coats' disease [22]

Stage	Findings
1	Retinal telangiectasia only
2	Telangiectasia and exudation
3a	Exudative subtotal retinal detachment
3b	Exudative total retinal detachment
4	Total retinal detachment and glaucoma
5	Advanced end-stage disease

important for normal retinal vasculogenesis [16–18]. Of note, Black et al. [17] reported a case of a mother with unilateral Coats' disease, who gave birth to a son with Norrie disease, in which both had mutations in the NDP gene. Additionally, Coats' retinopathy has been associated with a variety of exudative retinopathies, as well as several conditions, including familial renal-retinal dystrophy (Senior-Loken syndrome), Turner's syndrome and autosomal dominant fascioscapulohumeral muscular dystrophy (Hallermann-Streiff syndrome) [1, 2, 19–21].

Shields et al. [22] proposed the most recent classification system, depicted in table 1. Patients can present with a range of signs, with the most common being decreased visual acuity, strabismus and leukocoria [2, 3]. Other signs that can be present in patients with Coats' disease are pain, heterochromia of the iris and nystagmus [22]. Importantly, although the extent of symptoms is variable, Coats' disease is mainly a progressive condition, which can be asymptomatic in early stages and diagnosed during routine ophthalmologic examination [22].

Diagnosis

On examination, ophthalmoscopy can demonstrate a variety of findings, depending on the stage of the disease. Retinal telangiectasia and aneurysmal dilation of the retinal vasculature may be accompanied by sheathing of the vasculature [22]. The majority of these vessels have been noted to be at the temporal and inferior quadrants and the majority of aneurysms are fusiform rather than saccular [22]. At the initial stages, there may only be vascular abnormalities, but as the disease progresses, exudation of fluid produces subretinal deposits, which can be seen on funduscopy as 'light bulb' (fig. 1) [2]. Advanced macular disease can be associated with macular fibrosis and formation of subfoveal nodules as well as macular holes [23]. The vitreous commonly remains clear, until areas of vit-

reous condensation cause retinal detachment and vitreous haemorrhage [23]. Clinically, the vision may remain unaffected, whilst the vascular abnormalities are in the periphery, but can be affected as the exudates move towards the macula. This can also cause macular oedema or retinal detachment, either at the area of telangiectasia or total retinal detachment [24].

The variability of symptoms in Coats' disease means that the clinical presentation can be similar to several other ophthalmic conditions. In the differential diagnosis, the most important lesion to be ruled out is retinoblastoma. It is considered to be the most common primary intra-ocular malignancy in children, and as it could be fatal when left untreated, significant attention should be paid to its diagnosis [23, 25, 26]. On the other hand, Coats' disease misdiagnosed as retinoblastoma has also been reported to be the most common cause of wrongful enucleation [2]. Furthermore, of considerable importance is the exclusion of retinopathy of prematurity, which can be treated and not affect the vision [23, 27]. Additionally, we should take into account familial exudative vitreoretinopathy, haemangioblastoma von Hippel, pars planitis, incontinentia pigmenti, which are more often bilateral, as well as ocular toxocariasis and persistent fetal vasculature, which tend to be unilateral [23].

There are various diagnostic modalities to confirm the clinical suspicion of Coats' disease, as well as to disregard the variety of differentials. Although it is possible to reach a diagnosis from clinical examination alone, in the majority of cases, some form of ancillary testing is needed, including fluorescein angiography, ultrasound, computerized tomography (CT) and magnetic resonance imaging (MRI) [28].

Fluorescein angiography plays a pivotal role in both diagnosis and assessment of disease progression, allowing clear visualization of the vascular changes which may be taking place. Telangiectasias cause early hyperfluorescence and exudation causes hypofluorescence. Moreover, in larger blood vessels, the aneurysms will be clearly visible, characteristically described as 'light bulb' dilations [1, 2].

Ultrasonography can also be a useful diagnostic tool, as demonstrated by Atta and Watson [29], who showed that findings on ultrasound can correlate with histology. The typical features of Coats' disease on ultrasound were subretinal opacities due to cholesterosis present from the exudates, as well as retinal detachment which is able to be visualized as a linear echo [1, 29]. It can also be used to disregard retinoblastoma, as it allows visualization of the intra-ocular space [2].

CT can be similarly useful to rule out retinoblastoma. Patients with retinoblastoma can present with solid tumours and calcifications, visualized with CT, whereas in Coats' disease the scan would be clear of these lesions [30, 31]. However, it should be noted that CT may not be useful in distinguishing cases of retinoblastoma without calcification, which Potter et al. [31] showed to be true in up to 46% of retinoblastomas. Furthermore, Eisenberg et al. [30] and Senft et al. [32] presented cases of Coats' disease, where there has been intraocular bone formation alongside the vascular and exudative retinopathy, showing a calcification in both CT and ultrasound. Moreover, in advanced Coats' disease, Edward et al. [28] reported that in up to 20% of cases, a submacular nodule may be formed and calcified. In advanced cases, CT can also show the lipid exudate as a hyperdense area within the orbit, as well as a present retinal detachment [28, 33].

MRI is extremely useful in the diagnosis of advanced Coats' disease, but may have lesser utility during the initial stages; MRI is superior to CT, in ruling out retinoblastoma as the difference between subretinal exudation and a solid mass is clearer on MRI [34]. Specifically, the exudate in Coats' disease is hyperintense on both T₁-weighted and T₂-weighted MRI images, whereas in retinoblastoma, T₁-weighted image will show a hyperintense mass, but T₂-weighted image shows a hypointense mass [30, 32]. Eisenberg et al. [30] also utilized magnetic resonance spectroscopy, which can provide biochemical information non-invasively from various body tissues. Moreover, the use of gadolinium contrast may also aid in the differential diagnosis of retinoblastoma as it enhances the solid tumours not seen in Coats' disease [1].

In the majority of cases, invasive diagnostic modalities, such as fine-needle aspiration (FNA), are not recommended; however, FNA can be used to confirm the diagnosis when non-invasive modalities are not diagnostic. Interestingly enough, Shields et al. [26] point out that FNA is contra-indicated if there is a total retinal detachment or if there is a strong clinical suspicion of retinoblastoma.

Treatment

There are several treatment modalities for Coats' disease, depending on its stage; they are briefly summarized in table 2. The overall aim of treatment in mild disease is ablation of the abnormal retinal vasculature, preservation of vision and prevention of disease progressing to retinal detachment. For years, the main treatment op-

Table 2. Treatment modalities according to stage of the disease

Stage	Treatment
Mild disease (1, 2)	Laser photocoagulation/cryotherapy
Mild disease (1, 2) without progression	Observation – no treatment
Advanced disease (3, 4)	Vitreoretinal surgery
Advanced end-stage disease (5) with painful eye	Enucleation
Advanced end-stage disease (5) with comfortable eye	Observation – no treatment
Adjuvant therapy	Intravitreal triamcinolone
Adjuvant therapy	Anti-VEGF agents

tions have been laser photocoagulation and cryotherapy, especially for mild or moderate stages of the disease [10, 35–53]. In more advanced disease, where there are extensive telangiectasias, retinal detachment and widespread exudation, laser photocoagulation and cryotherapy can still be used, although vitreoretinal surgery may be more effective and in severe cases enucleation may be necessary or simply observation depending upon the pain [22, 52–57].

Evaluation of treatment modalities in Coat's disease remains problematic due to the low incidence of Coat's disease and the great variation in severity upon presentation. Most published work consists of case reports or very small case series. Recently, a population-based study of Coat's disease was conducted by the British Ophthalmic Surveillance Unit. The study involved ophthalmologists completing a baseline questionnaire on how they managed cases of Coat's disease and a follow-up questionnaire 6 months thereafter. In 92% of cases, laser photocoagulation was used as primary treatment and cryotherapy as second line. However, the study concluded that despite the main aim to avoid enucleation, treatment via laser photocoagulation remained doubtful [36].

Laser photocoagulation is utilized to cauterize retinal vasculature and can be used in mild disease with limited exudation, corresponding to stages 1, 2 and 3a according to Shields' classification [10, 22, 35–49]. Argon lasers are most commonly used and often up to five sessions may be required for adequate regression [22]. In a review of 17 patients, the majority with stage 2 or 3, treated aggressively with laser photocoagulation, Scheffler et al. [46] showed excellent or moderate visual acuity in 53% of their patients, in comparison to Shields et al. [22], who used a variety of treatment modalities and produced better than poor results in 46% (stage 2) and 25% (stage 3). Although it is generally accepted that laser is only effective when the retina is attached, Scheffler et al. [46] also

showed that in 6 patients with advanced disease and sub-total retinal detachment, they were able to preserve some vision in 2. Until now, laser photocoagulation is thought to be the best option for early stages of Coats' disease [36]. If thick exudation is present, laser treatment may not be particularly useful, as it may not be able to reach the vessels, and cryotherapy is preferred [23].

Cryotherapy is used in Coat's disease especially in patients presenting with exudative disease and retinal detachment, which corresponds to stages 1–3b of Shields' classification. When laser photocoagulation is not possible, even being the treatment of choice for mild Coat's disease, cryotherapy is utilized and believed to be more effective than laser in more advanced cases. Interestingly enough, it is used as primary treatment in up to 42% of patients [22, 50–53]. Like laser photocoagulation, it may require multiple sessions, although if excessive it may conversely lead to an increase in subretinal exudation and an increase in retinal detachment [22]. Therefore, it is advisable to use it for only up to two quadrants at a time, with a month gap between treatments [22]. It is also worth mentioning that Budning et al. [35] did not demonstrate a benefit in outcome by combining laser photocoagulation and cryotherapy.

Laser photocoagulation and cryotherapy are not recommended in cases of total retinal detachment. In severe forms of Coats' disease, there is a variety of treatment options, with vitreo-retinal surgery playing a great role in late-stage Coats' disease [52–57]. Enucleation may be also necessary in some cases of Coats' disease and is carried out in approximately 16% of patients with confirmed Coat's disease, complicated with neovascular glaucoma, pain, nausea and vomiting [22].

Recently, intravitreal triamcinolone has been found to be effective in the treatment of Coats' disease as an adjuvant therapy [6–8, 51, 58, 59]. Specifically, Othman et al. [58] demonstrated an improvement in visual acuity, as

Table 3. Anti-VEGF in the treatment of Coats' disease

Author	Study type	Participants	Stage of disease	Treatment	Outcomes
Sun (2007) [60]	case report	1 (2 years old)	4	pegaptanib sodium	resolution of exudates and retinal detachment (80%)
Cakir (2008) [59]	case report	1 (14 years old)	3	bevacizumab 1.25 mg triamcinolone acetonide 2 mg	improvement in VA (from 20/400 to 20/125) resolution of subfoveal serous detachment and exudative detachment no recurrence at 6-month follow-up
Venkatesh (2008) [61]	case series	2 (14 and 16 years old)	2	bevacizumab 1.25 mg laser photocoagulation 6 weeks later	stabilization or improvement in VA decrease of macular oedema and exudates no recurrence at 12-month follow-up
Alvarez-Rivera (2008) [62]	case report	1 (10 years old)	2	bevacizumab 2.5 mg	slight improvement in VA decrease of subretinal fluid and exudates
Jun (2008) [7]	case report	1 (47 years old)	2	bevacizumab 1.25 mg triamcinolone 4 mg laser photocoagulation	improvement in VA (from 0.02 to 0.04) reduced leakage increase of macular oedema
Entezari (2009) [63]	case report	1 (13 years old)	2	bevacizumab 1.25 mg × 3	significant improvement in VA (from counting fingers to 20/20) regression of abnormal vessels no recurrence at 12-month follow-up
Stergiou (2009) [47]	case report	1 (17 years old)	2	bevacizumab 1.25 mg triamcinolone 2 mg laser photocoagulation	improvement in VA (from 20/1,000 to 20/60) decrease of exudates no recurrence at the end of follow-up
Kaul (2010) [64]	case series	3 (16, 7 and 2 years old)	2-3	pegaptanib 0.3 mg (1 case stage 2) bevacizumab 1.25 mg laser photocoagulation (2 cases stage 3)	stabilization/improvement in VA decrease of macular oedema and of teleangiectatic vessels reattachment of retina no recurrence at 6-month follow-up
Cackett (2010) [48]	case report	1 (15 years old)	2	bevacizumab 1.25 mg laser photocoagulation	improvement in VA (from 6/60 to 6/45) reduction of subretinal fluid and exudation
Diago (2010) [65]	case report	1 (18 years old)	2	ranibizumab × 3 laser photocoagulation	improvement in VA (from counting fingers to 20/60) decrease of macular oedema no recurrence at 12-month follow-up
Lin (2010) [66]	case series	3 (10 years old, 6 months and 12 years old)	2b-3b	bevacizumab 2.5 mg laser photocoagulation	improvement in VA resolution of exudation no recurrence at 12-month follow-up
He (2010) [67]	case report	1 (7 years old)	2b	bevacizumab 1.25 mg	improvement in VA (from 20/400 to 20/100) decrease of macular oedema
Böhm (2011) [8]	case report	1 (26 years old)	2	bevacizumab 1.25 mg × 3 triamcinolone 2 mg	significant improvement in VA (from 0.3 to 1.2) significant decrease in central retinal thickness no recurrence at 87-week follow-up
Goel (2011) [9]	case series	3 (45, 40 and 42 years old)	2	bevacizumab 1.25 mg laser photocoagulation 3 weeks later	improvement in VA reduction of exudation and macular oedema no recurrence at 9-month follow-up
Kim (2011) [10]	case report	1 (68 years old)	2	bevacizumab 1.25 mg PDT	stabilization in VA regression of abnormal vessels no recurrence at 9-month follow-up
Wang (2011) [11]	case series	3 (adults)	2	bevacizumab 2.5 mg laser photocoagulation	improvement in VA decrease of macular oedema and of vascular dilation
Zhao (2011) [68]	case report	1 (3 years old)	3b	bevacizumab 1.25 mg × 3	improvement in VA (from NPL to 20/125) decrease of subretinal exudates and of dilated vessels resolution of retinal detachment
Ramasubramanian (2011) [69]	case series	8 (mean age: 88 months)	2-3b	bevacizumab 1.25 mg (8 cases) cryotherapy (8 cases) laser photocoagulation (4 cases) triamcinolone (1 case)	reduction of exudates/fluid development of vitreoretinal fibrosis (4 cases) retinal detachment (4 cases)

VA = Visual acuity; NPL = no perception of light.

well as absorption of subretinal fluid and macular exudates in 15 consecutive patients having been treated with intravitreal triamcinolone in combination with other treatment modalities, such as laser photocoagulation and/or cryotherapy. This is in line with other reports, also suggesting an improvement in visual acuity, a decrease in central retinal thickness, resolution of exudates and no recurrence at an average 6-month follow-up, in patients treated with intravitreal triamcinolone as additional therapy [6, 8, 51, 59]. Nevertheless, a very common complication is a possible development of cataract and it could restrict its use [69].

The most recent development in the treatment of Coats' disease has been the use of anti-vascular endothelial growth factor (anti-VEGF) agents. The results of intravitreal injections of anti-VEGF agents have been reported in few case reports and small case series and have been variable, as is depicted in table 3 [7–11, 47, 48, 59–69]. Kaul et al. [64] recommend it as a future adjunctive treatment alongside traditional therapies, in accordance with the majority of other authors, as it seems to reduce macular oedema and exudates, improve or even stabilize visual acuity and enhance the regression of dilated abnormal vessels [7–11, 47, 48, 59–63, 65–69]. On the contrary, Ramasubramanian et al. [69] suggested that bevacizumab should be used with caution, as vitreoretinal fibrosis and, potentially, traction retinal detachment were

found in patients treated with bevacizumab in addition to standard therapy, but not in patients receiving only standard measures. It is also very important to mention that anti-VEGF agents can be used only if the diagnosis of Coats' disease is confirmed and retinoblastoma excluded as it is known that intraocular injections can cause seeding of extraocular tissue in some cases of retinoblastoma [70].

In conclusion, Coats' disease is an idiopathic, progressive ocular entity, with retinal telangiectasis and exudates, which can cause retinal detachment. Its diagnosis can be challenging and retinoblastoma is the most important lesion that should be ruled out in the differential diagnosis. There are several treatment modalities, especially laser photocoagulation and cryotherapy for mild to moderate stages of the disease as well as vitrectomy for advanced stages. Today, anti-VEGF agents are used as adjuvant therapy to other treatment options, but clinical trials or case series with a large number of patients are limited due to the low incidence of the disease.

Acknowledgement

We would like to thank Dr. Maria Tsimpida (Paediatric Ophthalmology Fellow at Barts and the London NHS Trust) for kindly providing us with the figure 1 from her database, to support our review.

References

- Jones JH, Kroll AJ, Lou PL, Ryan EA: Coats' disease. *Int Ophthalmol Clin* 2001;41:189–198.
- Shields JA, Shields CL, Honavar SG, Demirci H: Clinical variations and complications of Coats disease in 150 cases: the 2000 Sanford Gifford Memorial Lecture. *Am J Ophthalmol* 2001;131:561–571.
- Shienbaum G, Tasman WS: Coats disease: a lifetime disease. *Retina* 2006;26:422–424.
- Andonegui J, Aranguren M, Berástegui L: Coats disease of adult onset. *Arch Soc Esp Oftalmol* 2008;83:117–120.
- Adam RS, Kertes PJ, Lam WC: Observations on the management of Coats' disease: less is more. *Br J Ophthalmol* 2007;91:303–306.
- Jarin RR, Teoh SC, Lim TH: Resolution of severe macular oedema in adult Coats' syndrome with high-dose intravitreal triamcinolone acetonide. *Eye* 2006;20:163–165.
- Jun JH, Kim YC, Kim KS: Resolution of severe macular edema in adult Coats' disease with intravitreal triamcinolone and bevacizumab injection. *Korean J Ophthalmol* 2008;22:190–193.
- Böhm MR, Uhlig CE: Use of intravitreal triamcinolone and bevacizumab in Coats' disease with central macular edema. *Graefes Arch Clin Exp Ophthalmol* 2011;249:1099–1101.
- Goel N, Kumar V, Seth A, Raina UK, Ghosh B: Role of intravitreal bevacizumab in adult onset Coats' disease. *Int Ophthalmol* 2011;31:183–190.
- Kim J, Park KH, Woo SJ: Combined photodynamic therapy and intravitreal bevacizumab injection for the treatment of adult Coats' disease: a case report. *Korean J Ophthalmol* 2010;24:374–376.
- Wang KY, Cheng CK: A combination of intravitreal bevacizumab injection with tunable argon yellow laser photocoagulation as a treatment for adult-onset Coats' disease. *J Ocul Pharmacol Ther* 2011;27:525–530.
- Egbert PR, Chan CC, Winter FC: Flat preparations of the retinal vessels in Coats' disease. *J Pediatr Ophthalmol* 1976;13:336–339.
- Fernandes BF, Odashiro AN, Maloney S, Zajdenweber ME, Lopes AG, Burnier MN Jr: Clinical-histopathological correlation in a case of Coats' disease. *Diagn Pathol* 2006;1:24.
- Steidl SM, Hirose T, Sang D, Hartnett ME: Difficulties in excluding the diagnosis of retinoblastoma in cases of advanced Coats' disease: a clinicopathologic report. *Ophthalmologica* 1996;210:336–340.
- Robitaille JM, Zheng B, Wallace K, Beis MJ, Tatlidil C, Yang J, Sheidow TG, Siebert L, Levin AV, Lam WC, Arthur BW, Lyons CJ, Jaakkola E, Tsilou E, Williams CA, Weaver RG Jr, Shields CL, Guernsey DL: The role of Frizzled-4 mutations in familial exudative vitreoretinopathy and Coats disease. *Br J Ophthalmol* 2011;95:574–579.
- Berger W, van de Pol D, Bächner D, Oerlemans F, Winkens H, Hameister H, Wieringa B, Hendriks W, Ropers HH: An animal model for Norrie disease (ND): gene targeting of the mouse ND gene. *Hum Mol Genet* 1996;5:51–59.

- 17 Black GC, Perveen R, Bonshek R, Cahill M, Clayton-Smith J, Lloyd IC, McLeod D: Coats' disease of the retina (unilateral retinal telangiectasis) caused by somatic mutation in the NDP gene: a role for norrin in retinal angiogenesis. *Hum Mol Genet* 1999;8:2031-2035.
- 18 Dickinson JL, Sale MM, Passmore A, FitzGerald LM, Wheatley CM, Burdon KP, Craig JE, Tengtrisor S, Carden SM, Maclean H, Mackey DA: Mutations in the NDP gene: contribution to Norrie disease, familial exudative vitreoretinopathy and retinopathy of prematurity. *Clin Experiment Ophthalmol* 2006;34:682-688.
- 19 Schuman JS, Lieberman KV, Friedman AH, Berger M, Schoeneman MJ: Senior-Loken syndrome (familial renal-retinal dystrophy) and Coats' disease. *Am J Ophthalmol* 1985;100:822-827.
- 20 Beby F, Roche O, Burillon C, Denis P: Coats' disease and bilateral cataract in a child with Turner syndrome: a case report. *Graefes Arch Clin Exp Ophthalmol* 2005;243:1291-1293.
- 21 Newell SW, Hall BD, Anderson CW, Lim ES: Hallermann-Streiff syndrome with Coats disease. *J Pediatr Ophthalmol Strabismus* 1994;31:123-125.
- 22 Shields JA, Shields CL, Honavar SG, Demirci H, Cater J: Classification and management of Coats disease: the 2000 Proctor Lecture. *Am J Ophthalmol* 2001;131:572-583.
- 23 Reichstein DA, Recchia FM: Coats disease and exudative retinopathy. *Int Ophthalmol Clin* 2011;51:93-112.
- 24 Hsu J, Forbes B, Maguire AM: Total exudative retinal detachment in coats disease: biochemical analysis of the subretinal exudate. *Retina* 2006;26:831-833.
- 25 Shields CL, Uysal Y, Benevides R, Eagle RC Jr, Malloy B, Shields JA: Retinoblastoma in an eye with features of Coats' disease. *J Pediatr Ophthalmol Strabismus* 2006;43:313-315.
- 26 Shields CL, Ghassemi F, Tuncer S, Thangappan A, Shields JA: Clinical spectrum of diffuse infiltrating retinoblastoma in 34 consecutive eyes. *Ophthalmology* 2008;115:2253-2258.
- 27 Early Treatment for Retinopathy of Prematurity Cooperative Group, Good WV, Hardy RJ, Dobson V, Palmer EA, Phelps DL, Tung B, Redford M: Final visual acuity results in the early treatment for retinopathy of prematurity study. *Arch Ophthalmol* 2010;128:663-671.
- 28 Edward DP, Mafee MF, Garcia-Valenzuela E, Weiss RA: Coats' disease and persistent hyperplastic primary vitreous. Role of MR imaging and CT. *Radiol Clin North Am* 1998;36:1119-1131, x.
- 29 Atta HR, Watson NJ: Echographic diagnosis of advanced Coats' disease. *Eye* 1992;6:80-85.
- 30 Eisenberg L, Castillo M, Kwock L, Mukherji SK, Wallace DK: Proton MR spectroscopy in Coats disease. *AJNR Am J Neuroradiol* 1997;18:727-729.
- 31 Potter PD, Shields CL, Shields JA, Flanders AE: The role of magnetic resonance imaging in children with intraocular tumors and simulating lesions. *Ophthalmology* 1996;103:1774-1183.
- 32 Senft SH, Hidayat AA, Cavender JC: Atypical presentation of Coats disease. *Retina* 1994;14:36-38.
- 33 Lai WW, Edward DP, Weiss RA, Mafee MF, Tso MO: Magnetic resonance imaging findings in a case of advanced Coats' disease. *Ophthalmic Surg Lasers* 1996;27:234-238.
- 34 Mafee MF, Goldberg MF, Cohen SB, Gotsis ED, Safran M, Chekuri L, Raofi B: Magnetic resonance imaging versus computed tomography of leukocoric eyes and use of in vitro proton magnetic resonance spectroscopy of retinoblastoma. *Ophthalmology* 1989;96:965-976.
- 35 Budning AS, Heon E, Gallie BL: Visual prognosis of Coats' disease. *J AAPOS* 1998;2:356-359.
- 36 Mulvihill A, Morris B: A population-based study of Coats disease in the United Kingdom. II. Investigation, treatment, and outcomes. *Eye* 2010;24:1802-1807.
- 37 Spitznas M, Joussen F, Wessing A: Treatment of Coats' disease with photocoagulation. *Albrecht von Graefes Arch Klin Exp Ophthalmol* 1976;199:31-37.
- 38 Haut J, Van Effenterre G, Marre JM, Dureuil J, Moulin F: Treatment of Coats' disease with argon laser photocoagulation. *Bull Soc Ophthalmol Fr* 1979;79:463-465.
- 39 Ridley ME, Shields JA, Brown GC, Tasman W: Coats' disease. Evaluation of management. *Ophthalmology* 1982;89:1381-1387.
- 40 Tarkkanen A, Laatikainen L: Coat's disease: clinical, angiographic, histopathological findings and clinical management. *Br J Ophthalmol* 1983;67:766-776.
- 41 Sneed SR, Blodi CF, Pulido JS: Treatment of Coats' disease with the binocular indirect argon laser photocoagulator. *Arch Ophthalmol* 1989;107:789-790.
- 42 Kiratli H, Eldem B: Management of moderate to advanced Coats' disease. *Ophthalmologica* 1998;212:19-22.
- 43 Nucci P, Bandello F, Serafino M, Wilson ME: Selective photocoagulation in Coats' disease: ten-year follow-up. *Eur J Ophthalmol* 2002;12:501-505.
- 44 Couvillion SS, Margolis R, Mavrofjides E, Hess D, Murray TG: Laser treatment of Coats' disease. *J Pediatr Ophthalmol Strabismus* 2005;42:367-368.
- 45 Mrejen S, Metge F, Denion E, Dureau P, Edelson C, Caputo G: Management of retinal detachment in Coats disease. Study of 15 cases. *Retina* 2008;28:26-32.
- 46 Scheffler AC, Berrocal AM, Murray TG: Advanced Coats' disease. Management with repetitive aggressive laser ablation therapy. *Retina* 2008;28:38-41.
- 47 Stergiou PK, Symeonidis C, Dimitrakos SA: Coats' disease: treatment with intravitreal bevacizumab and laser photocoagulation. *Acta Ophthalmol* 2009;87:687-688.
- 48 Cackett P, Wong D, Cheung CM: Combined intravitreal bevacizumab and argon laser treatment for Coats' disease. *Acta Ophthalmol* 2010;88:48-49.
- 49 Shapiro MJ, Chow CC, Karth PA, Kiernan DF, Blair MP: Effects of green diode laser in the treatment of pediatric Coats disease. *Am J Ophthalmol* 2011;151:725-731.
- 50 Haut J, Zeghal M, Limon S: Cryotherapy of Eales' disease and Coats' disease. *Bull Soc Ophthalmol Fr* 1970;70:182-184.
- 51 Bergstrom CS, Hubbard GB 3rd: Combination intravitreal triamcinolone injection and cryotherapy for exudative retinal detachments in severe Coats disease. *Retina* 2008;28:33-37.
- 52 Silodor SW, Augsburger JJ, Shields JA, Tasman W: Natural history and management of advanced Coats' disease. *Ophthalmic Surg* 1988;19:89-93.
- 53 Theodossiadis GP: Some clinical, fluorescein-angiographic, and therapeutic-aspects of Coats' disease. *J Pediatr Ophthalmol Strabismus* 1979;16:257-262.
- 54 Haik BG: Advanced Coats' disease. *Trans Am Ophthalmol Soc* 1991;89:371-376.
- 55 Ozdamar Y, Berker N, Batman C, Zilelioglu O: Vitreoretinal surgery in advanced Coats disease. *Retinal Cases Brief Rep* 2009;3:57-59.
- 56 Kranias G, Krebs TP: Advanced Coats' disease successfully managed with vitreo-retinal surgery. *Eye* 2002;16:500-501.
- 57 Yamashita T, Kawamura H, Kojo N, Ohji M: A case of Coats' disease with visual recovery from no light perception vision after vitrectomy. *Jpn J Ophthalmol* 2011;55:78-80.
- 58 Othman IS, Moussa M, Bouhaimed M: Management of lipid exudates in Coats disease by adjuvant intravitreal triamcinolone: effects and complications. *Br J Ophthalmol* 2010;94:606-610.
- 59 Cakir M, Cekiç O, Yilmaz OF: Combined intravitreal bevacizumab and triamcinolone injection in a child with Coats disease. *J AAPOS* 2008;12:309-311.
- 60 Sun Y, Jain A, Moshfeghi DM: Elevated vascular endothelial growth factor levels in Coats disease: rapid response to pegaptanib sodium. *Graefes Arch Clin Exp Ophthalmol* 2007;245:1387-1388.
- 61 Venkatesh P, Mandal S, Garg S: Management of Coats disease with bevacizumab in 2 patients. *Can J Ophthalmol* 2008;43:245-246.

- 62 Alvarez-Rivera LG, Abraham-Marín ML, Flores-Orta HJ, Mayorquín-Ruiz M, Cortés-Luna CF: Coat's disease treated with bevacizumab (Avastin). *Arch Soc Esp Oftalmol* 2008;83:329–331.
- 63 Entezari M, Ramezani A, Safavizadeh L, Bassirnia N: Resolution of macular edema in Coats' disease with intravitreal bevacizumab. *Indian J Ophthalmol* 2010;58:80–82.
- 64 Kaul S, Uparkar M, Mody K, Walinjkar J, Kothari M, Natarajan S: Intravitreal anti-vascular endothelial growth factor agents as an adjunct in the management of Coats' disease in children. *Indian J Ophthalmol* 2010;58:76–78.
- 65 Diago T, Valls B, Pulido JS: Coats' disease associated with muscular dystrophy treated with ranibizumab. *Eye* 2010;24:1295–1296.
- 66 Lin CJ, Hwang JF, Chen YT, Chen SN: The effect of intravitreal bevacizumab in the treatment of Coats disease in children. *Retina* 2010;30:617–622.
- 67 He YG, Wang H, Zhao B, Lee J, Bahl D, McCluskey J: Elevated vascular endothelial growth factor level in Coats' disease and possible therapeutic role of bevacizumab. *Graefes Arch Clin Exp Ophthalmol* 2010;248:1519–1521.
- 68 Zhao T, Wang K, Ma Y, Jiang YR: Resolution of total retinal detachment in Coats' disease with intravitreal injection of bevacizumab. *Graefes Arch Clin Exp Ophthalmol* 2011;249:1745–1746.
- 69 Ramasubramanian A, Shields CL: Bevacizumab for Coats' disease with exudative retinal detachment and risk of vitreoretinal traction. *Br J Ophthalmol* 2011. Epub ahead of print.
- 70 Wells JR, Hubbard GB 3rd: The effect of intravitreal bevacizumab in the treatment of Coats disease in children. *Retina* 2011;31:427–428.