

## REVIEWS

## Diagnostic Point-of-Care Ultrasound for Hospitalists

Nilam J. Soni, MD<sup>1</sup>\*, Brian P. Lucas, MD, MS<sup>2</sup>

<sup>1</sup>Department of Medicine, University of Texas Health Science Center, San Antonio, Texas; <sup>2</sup>Medicine Service, VA Medical Center, White River Junction, Vermont.

We review the literature on diagnostic point-of-care ultrasound applications most relevant to hospital medicine and highlight gaps in the evidence base. Diagnostic point-of-care applications most relevant to hospitalists include cardiac ultrasound for left ventricular systolic function, pericardial effusion, and severe mitral regurgitation; lung ultrasound for pneumonia, pleural effusion, pneumothorax, and pulmonary edema; abdominal ultrasound for ascites, aortic aneurysm, and hydronephrosis; and venous ultrasound for central venous volume assess-

ment and lower extremity deep venous thrombosis. Hospitalists and other frontline providers, as well as physician trainees at various levels of training, have moderate to excellent diagnostic accuracy after brief training programs for most of these applications. Despite the evidence supporting the diagnostic accuracy of point-of-care ultrasound, experimental evidence supporting its clinical use by hospitalists is limited to cardiac ultrasound. *Journal of Hospital Medicine* 2015;10:120-124. © 2014 Society of Hospital Medicine.

Similar to the physical exam, diagnostic point-of-care ultrasound exams are performed at the bedside in real time by hospitalists who are seeking a diagnosis. In contrast, referral ultrasound exams involve multiple providers and several steps. Typically, an ultrasound technologist acquires images, a radiologist or cardiologist interprets the images, a report is prepared, and results are sent to the referring hospitalist (Figure 1). Another important difference is that although referral ultrasound exams are usually comprehensive evaluations of entire organs or anatomic spaces, often without specific diagnoses in mind, point-of-care ultrasound exams are aimed at making specific diagnoses for well-defined clinical scenarios.<sup>1</sup>

The American Medical Association has reassured providers that “ultrasound imaging is within the scope of practice of appropriately trained physicians.”<sup>2</sup> A growing body of literature demonstrates that point-of-care ultrasound is increasingly used by hospitalists for more than just bedside procedures. Incited by ongoing miniaturization of ultrasound devices, hospitalists are beginning to use point-of-care ultrasound for diagnosis, treatment, monitoring, and screening of patients (Figure 2). Our aim was to review the current literature for point-of-care ultrasound applications most relevant to hospitalists and highlight gaps in the current literature.

## ABDOMEN

## Ascites

Ultrasound is the gold standard for diagnosing ascites and can detect as little as 100 mL of ascitic fluid.<sup>3</sup> When ascites is not immediately evident, hospitalists can apply the principles of the FAST (Focused Assessment with Sonography in Trauma) examination to detect small amounts of ascites by evaluating the most dependent areas of the abdominopelvic cavity, the hepatorenal, left subdiaphragmatic, and rectovesicular or rectouterine spaces.<sup>1</sup> When ascites is identified and paracentesis is indicated, ultrasound guidance for site selection reduces bleeding complications.<sup>4</sup>

## Aortic Aneurysm

Novice providers with limited ultrasound training can accurately screen patients for abdominal aortic aneurysm (AAA). Multiple studies from emergency departments have shown that point-of-care ultrasound can be used to accurately detect AAA, and a recent meta-analysis of 7 high-quality studies demonstrated a sensitivity of 99% (95% confidence interval [CI]: 96%-100%) and a specificity of 98% (95% CI: 97%-99%).<sup>5</sup> Hospitalists could use ultrasound to rapidly detect AAA in patients with acute abdominal pain, monitor the size in patients with known AAA, and possibly screen high-risk patients.<sup>6</sup>

## Hydronephrosis

Once detected, relief of post-renal obstruction usually results in rapid reversal of acute kidney injury. Although diagnostic accuracy studies of detection of hydronephrosis have yet to be conducted with hospitalists, studies of other frontline providers with limited training in renal ultrasonography have revealed sensitivities of 72% to 87% and specificities of 73% to 82% in patients with renal colic.<sup>7,8</sup>

\*Address for correspondence and reprint requests: Nilam J. Soni, MD, 7703 Floyd Curl Drive, MC 7982, San Antonio, TX 78229; Telephone: 210-567-4815; Fax: 210-358-0647; E-mail: sonin@uthscsa.edu

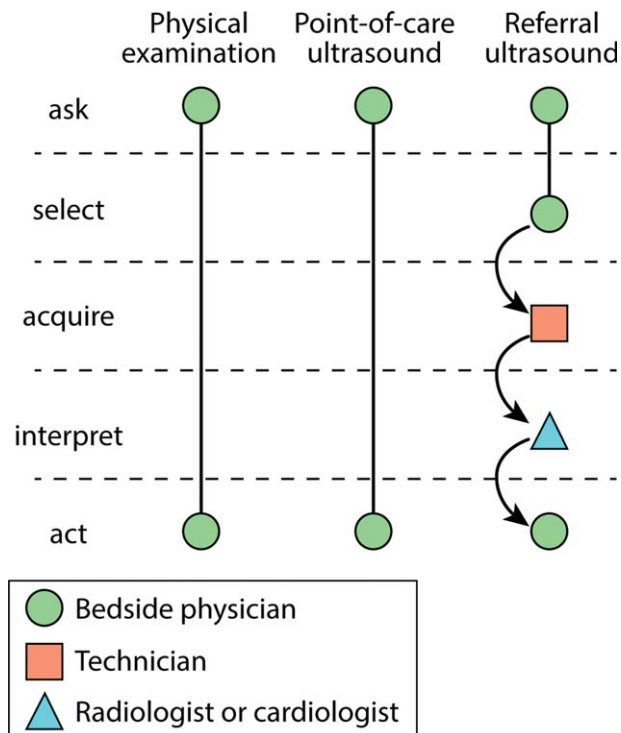
Additional Supporting Information may be found in the online version of this article.

Received: July 19, 2014; Revised: October 21, 2014;

Accepted: October 28, 2014

2014 Society of Hospital Medicine DOI 10.1002/jhm.2285

Published online in Wiley Online Library (Wileyonlinelibrary.com).

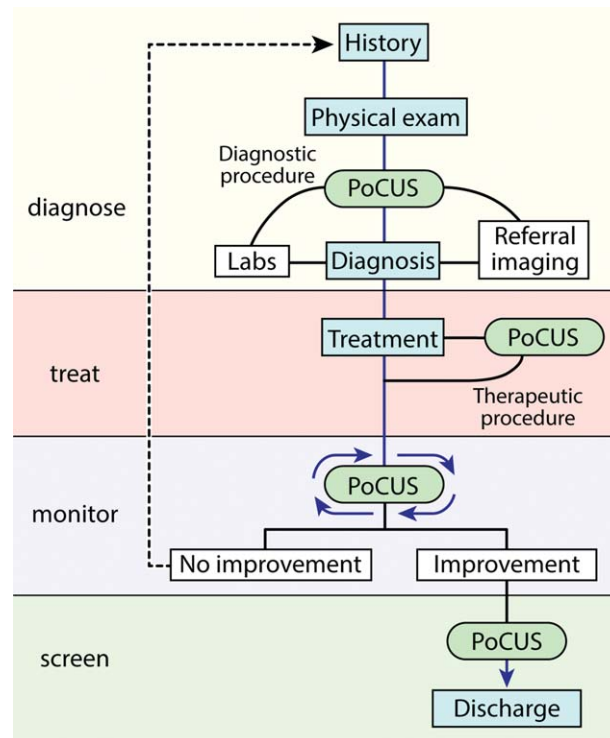


**FIG. 1.** Comparison of physical examination and point-of-care and referral ultrasound examinations. The circles, squares, and triangles represent different healthcare providers. The dotted lines separate 5 stages of bedside providers' clinical decision making. The curved arrows represent transfer of information—most commonly through written reports—from 1 provider to another.

## HEART

Studies of point-of-care cardiac ultrasound have focused most on detection of left ventricular systolic dysfunction. Yet studies among hospitalists have yielded high diagnostic accuracy for an array of abnormalities.<sup>9–11</sup> Lucas et al. evaluated the diagnostic accuracy of 9 hospitalists for 5 cardiac abnormalities including left ventricular systolic dysfunction after a 27-hour, structured training program. Positive and negative likelihood ratios for point-of-care cardiac ultrasound increased and decreased, respectively, the prior odds by 5-fold or more for left ventricular systolic dysfunction, severe mitral regurgitation, and moderate or large pericardial effusion. Likelihood ratios changed the prior odds by 2-fold or more for moderate or severe left atrial enlargement, and moderate or severe left ventricle hypertrophy.<sup>9</sup> Martin et al. found that after a brief training program, hospitalists' image acquisition and interpretation skills were respectively below echocardiography technicians' and senior cardiology fellows' skills.<sup>10</sup> Yet in a follow-up study, they found that bedside diagnosis of left ventricle systolic dysfunction, cardiomegaly, and pericardial effusion improved when point-of-care cardiac ultrasound supplemented hospitalists' physical examination.<sup>11</sup>

In 1 of the few experimental studies of the impact of point-of-care ultrasound on clinical care, Lucas



**FIG. 2.** Point-of-care ultrasound in hospitalized patients. After gathering a medical history and performing a physical examination, a focused bedside ultrasound exam can facilitate making a diagnosis or guiding further workup. Diagnostic or therapeutic bedside procedures are performed with ultrasound guidance to reduce complications. Serial point-of-care ultrasound exams are performed to monitor disease processes and treatment effects. Screening to detect asymptomatic, potentially treatable conditions can be undertaken with point-of-care ultrasound. Abbreviations: PoCUS, point-of-care ultrasound.

et al. randomized general medicine patients who were referred by hospitalists for standard echocardiography to care guided by point-of-care cardiac ultrasound versus care guided by the referral echocardiography (usual care). Point-of-care cardiac ultrasound changed hospitalists' management for 37% of patients, and a post hoc subgroup analysis of heart failure patients demonstrated a statistically significant 15% reduction in length of stay.<sup>12</sup>

## LUNGS

### Pneumonia

Normally aerated lung parenchyma generates A-lines, horizontal hyperechoic lines that are artifacts due to repeated reflections, or reverberations, between the highly reflective pleura and transducer.<sup>1</sup> These normal A-lines disappear with pneumonia due to accumulation of interstitial fluid and cellular exudate in consolidated alveoli. A meta-analysis of 9 studies of lung ultrasound to diagnose pneumonia reported pooled sensitivity of 97% (95% CI: 93%-99%) with specificity of 94% (95% CI: 85%-98%).<sup>13</sup>

### Pleural Effusion

Half of patients with community-acquired pneumonia have a pleural effusion, yet chest x-ray often cannot

differentiate pneumonia from pleural effusion, especially along the lower lung fields. Ultrasound can accurately differentiate consolidated lung from pleural effusion and is more sensitive than a chest x-ray for detecting small pleural fluid volumes (100% vs 71%).<sup>14</sup> Serial monitoring of size and character of a pleural effusion can distinguish free flowing from loculated pleural effusions. Drainage of pleural effusions with ultrasound guidance is associated with a lower rate of postprocedure pneumothorax and lower total hospital costs.<sup>15</sup>

### Pneumothorax

Lung ultrasound can accurately and rapidly detect pneumothorax after lung and pleural procedures, including thoracentesis, bronchoscopy, and transthoracic biopsy.<sup>2</sup> Multiple studies have demonstrated that lung ultrasound is superior to chest x-ray. Three recent meta-analyses reported near-perfect specificity for both ultrasound and x-ray. But the sensitivity of ultrasound (79%–95%) was far better than that of x-ray (40%–52%) to detect pneumothorax.<sup>16,17</sup>

The hallmark ultrasound findings of pneumothorax include absence of lung sliding, absence of B-lines, and a stratified pattern using M-mode ultrasonography (“stratosphere sign”). Both lung sliding and B-lines rule out pneumothorax with a negative predictive value of 100%.<sup>18</sup> Absence of either finding, however, does not rule in pneumothorax with similar strength. Absent lung sliding is seen in other conditions, such as pleurodesis, mainstem intubation, and massive atelectasis; absent B-lines are most suggestive of the normal lung (see below).<sup>1</sup>

### Pulmonary Edema

The classic ultrasound finding of acute pulmonary edema is bilateral anterior B-lines. In contrast to horizontal A-lines, B-lines are vertical, laser-like reverberations that originate from the pleura and are due to interlobular septal edema. A linear correlation has been shown between the quantity of B-lines and radiographic lung water score ( $r = 0.78$ ;  $P < 0.01$ ).<sup>19</sup> Yet B-lines are not specific for high pulmonary capillary wedge pressure because interstitial edema can be caused by a variety of etiologies. Nonetheless, visualization of multiple B-lines in a single intercostal space corresponds with a sensitivity of 86% to 100% and specificity of 92% to 98% for either high- or low-pressure pulmonary edema.<sup>20,21</sup>

## VEINS

### Central Venous Volume

The physiologic relationship between central venous volume and central venous pressure (CVP) is complex. Initially, there is upward stepwise progression to the “stressed volume” threshold, and then the relationship becomes curvilinear with the steepness of the slope

dependent on the stiffness or tone of the central veins.<sup>22</sup>

The complexity of this relationship may explain the variable diagnostic accuracy of inferior vena cava (IVC) measurements to determine CVP, with measurements best reflecting CVP at extreme values. An IVC maximal diameter  $>2.0$  cm predicted CVP  $>10$  mm Hg (sensitivity 82% and specificity 84%) and pulmonary capillary wedge pressure  $>16$  mm Hg (sensitivity 75% and specificity 83%) in 1 study.<sup>23</sup> Adding measurement of the collapsibility of the IVC with respiration may improve diagnostic accuracy, particularly with intermediate ranges of CVP and is recommended by current echocardiography guidelines.<sup>24</sup>

Nonetheless, in patients with acute dyspnea, a dilated, noncollapsing IVC may differentiate acute decompensated heart failure (ADHF) from primary pulmonary disease.<sup>25,26</sup> IVC measurements may guide fluid removal in hemodialysis and heart failure patients.<sup>27,28</sup> In 2 studies of patients hospitalized with ADHF, lack of improvement of IVC collapsibility index at the time of discharge was associated with higher rates of readmission.<sup>29,30</sup> A follow-up study comparing diuresis guided by IVC collapsibility to usual care in patients hospitalized with ADHF showed a reduction in hospital readmission rates (4% vs 30%,  $P = 0.03$ ) without an increase in hospital length of stay or renal dysfunction.<sup>31</sup> Patients with small, collapsed IVCs can be administered intravenous fluids safely, particularly in the setting of hypovolemic or septic shock, and the response to this fluid resuscitation can be assessed by serially measuring the change in IVC diameter.<sup>32</sup>

### Thromboembolism

Multiple studies have shown that point-of-care ultrasound can accurately diagnose deep venous thrombosis (DVT) with a pooled sensitivity of 96% and specificity of 96% based on a recent meta-analysis of 19 studies.<sup>33</sup> In symptomatic patients with a lung ultrasound pattern showing A-lines, positive and negative predictive values of DVT in predicting pulmonary embolism (PE) were 94% and 98%, respectively.<sup>34</sup> A diagnostic accuracy study to diagnose PE using lung ultrasound to detect pleural- or subpleural-based lesions yielded a sensitivity of 90%, specificity of 60%, positive predictive value of 80%, and negative predictive value of 78%.<sup>35</sup> In a study of 96 patients with suspected PE who underwent computed tomography pulmonary angiogram (CTPA), a focused ultrasound exam of the heart, lungs, and lower extremity veins was able to detect DVT (2.1%) or an alternative diagnosis (56.2%) in the majority of these patients, potentially obviating the need for CTPA in 58.4% of patients.<sup>36</sup> In addition, point-of-care cardiac ultrasound may reveal direct findings, such as free-floating thrombus in the pulmonary artery, or indirect findings, such as right ventricular dilation and systolic

dysfunction, septal bowing, McConnell's sign, or IVC dilation.<sup>1</sup> Cardiac abnormalities are more specific (88%–94%) than sensitive (31%–77%), and absence of cardiac abnormalities rules out massive PE, justifying withholding thrombolytic medications in most patients.<sup>37</sup>

## RESEARCH GAPS

Most point-of-care ultrasound research has focused on diagnostic accuracy. Yet the training required for hospitalists to attain diagnostic competency remains controversial.<sup>38</sup> Evidence from cardiac point-of-care ultrasound training suggests that the number of supervised studies is a key determinate in competency.<sup>39</sup> For example, training programs based on 30 supervised studies<sup>11,15,40</sup> outperformed those based on only 5 supervised studies.<sup>11</sup> Nevertheless, the real value of point-of-care ultrasound will be in leading hospitalists to more appropriate treatment decisions that result in better outcomes for patients.<sup>41</sup> We believe that there are 4 important clinical areas where future research ought to focus.

First, can point-of-care ultrasound guide hospitalists' decision making during cardiac arrest? Current advanced cardiac life support (ACLS) guidelines recommend ruling out potentially reversible causes of cardiac arrest, including tension pneumothorax, cardiac tamponade, and massive pulmonary embolism, but traditional physical examination techniques are impractical to perform during cardiopulmonary resuscitation. Point-of-care ultrasound may be able to detect these conditions and facilitate emergent interventions, such as pericardiocentesis or needle decompression.<sup>1</sup> Identifying the absence of cardiac contractility is importantly associated with a significantly low likelihood of return of spontaneous circulation.<sup>1,42</sup> Whether or not point-of-care ultrasound should be added to either "crash carts" or ACLS guideline recommendations will depend on further evidence demonstrating its value.

Second, should hospitalists seize the opportunity to screen inpatients for abdominal aortic aneurysm and asymptomatic left ventricular systolic dysfunction? Although such screening has been successfully carried out,<sup>6,43</sup> widespread screening applications have been slow to develop. Ultrasound waves, themselves, impart no harm, but further research is needed to weigh the benefits of early detection against the harms of false-positive findings.

Third, how can hospitalists best utilize bedside ultrasound to perform serial examinations of patients? Unlike referral ultrasound examinations that take single "snapshots" of patients at 1 point in time, point-of-care ultrasound allows hospitalists to iteratively monitor patients. Promising and needed applications include serial examinations of the IVC as a surrogate for central venous volume<sup>44</sup> during both fluid resuscitation and removal, left ventricular contraction in

response to inotrope initiation, and resolution or worsening of a pneumothorax or pneumonia.

Fourth, how should hospitalists integrate point-of-care ultrasound into their workflow for common conditions? Recognized protocols most relevant to hospital medicine include RUSH (Rapid Ultrasound for Shock and Hypotension),<sup>45</sup> FALLS (Fluid Administration Limited by Lung Sonography),<sup>46</sup> BLUE (Bedside Lung Ultrasound in Emergency),<sup>34</sup> CLUE (Cardiovascular Limited Ultrasound Exam),<sup>47</sup> and intensive care unit-sound.<sup>48</sup> Several small single-institution studies have demonstrated that bedside ultrasound may benefit clinical decision making by differentiating cardiac versus pulmonary causes of acute dyspnea.<sup>49,50</sup> However, large, validating, multicenter trials are needed. In addition, outcomes that better reflect both the patients' and payers' perspectives ought to be considered. For example, how are doctor-patient relationships affected? Is shared decision making and patient (or physician) satisfaction improved? How are resources utilized and healthcare costs affected?

## CONCLUSIONS

Hospitalists are striving to provide high-quality, cost-effective healthcare, and point-of-care ultrasound may contribute to achieving these goals by expediting diagnoses and decreasing costly ancillary testing that utilizes ionizing radiation. Hospitalists are uniquely poised to advance the field by studying how point-of-care ultrasound is best incorporated into patient care algorithms.

Disclosure: Nothing to report.

## References

1. Soni NJ, Arntfield R, Kory P. *Point-of-Care Ultrasound*. 1st ed. Philadelphia, PA: Saunders; 2014.
2. American Medical Association. House of Delegates. H-230.960 Privileging for ultrasound imaging. Policy finder website. Available at: <https://ssl3.ama-assn.org/apps/ecommm/PolicyFinderForm.pl?site=www.ama-assn.org&uri=%2fresources%2fhtml%2fPolicyFinder%2fpolicyfiles%2fHnE%2fH-230.960.HTM>. Accessed October 2, 2014.
3. Goldberg BB, Goodman GA, Clearfield HR. Evaluation of ascites by ultrasound. *Radiology*. 1970;96(1):15–22.
4. Mercaldi CJ, Lanes SF. Ultrasound guidance decreases complications and improves the cost of care among patients undergoing thoracentesis and paracentesis. *Chest*. 2013;143(2):532–538.
5. Rubano E, Mehta N, Caputo W, Paladino L, Sinert R. Systematic review: emergency department bedside ultrasonography for diagnosing suspected abdominal aortic aneurysm. *Acad Emerg Med*. 2013;20(2):128–138.
6. Dijos M, Puchoux Y, Lafitte M, et al. Fast track echo of abdominal aortic aneurysm using a real pocket-ultrasound device at bedside. *Echocardiography*. 2012;29(3):285–290.
7. Rosen CL, Brown DF, Sagarin MJ, Chang Y, McCabe CJ, Wolfe RE. Ultrasonography by emergency physicians in patients with suspected ureteral colic. *J Emerg Med*. 1998;16(6):865–870.
8. Gaspari RJ, Horst K. Emergency ultrasound and urinalysis in the evaluation of flank pain. *Acad Emerg Med*. 2005;12(12):1180–1184.
9. Lucas BP, Candotti C, Margeta B, et al. Diagnostic accuracy of hospitalist-performed hand-carried ultrasound echocardiography after a brief training program. *J Hosp Med*. 2009;4(6):340–349.
10. Martin LD, Howell EE, Ziegelstein RC, Martire C, Shapiro EP, Hellmann DB. Hospitalist performance of cardiac hand-carried ultrasound after focused training. *Am J Med*. 2007;120(11):1000–1004.
11. Martin LD, Howell EE, Ziegelstein RC, et al. Hand-carried ultrasound performed by hospitalists: does it improve the cardiac physical examination? *Am J Med*. 2009;122(11):35–41.



12. Lucas BP, Candotti C, Margeta B, et al. Hand-carried echocardiography by hospitalists: a randomized trial. *Am J Med.* 2011;124(8):766–774.
13. Hu QJ, Shen YC, Jia LQ, et al. Diagnostic performance of lung ultrasound in the diagnosis of pneumonia: a bivariate meta-analysis. *Int J Clin Exp Med.* 2014;7(1):115–121.
14. Reissig A, Gramegna A, Aliberti S. The role of lung ultrasound in the diagnosis and follow-up of community-acquired pneumonia. *Eur J Intern Med.* 2012;23(5):391–397.
15. Patel PA, Ernst FR, Gunnarsson CL. Ultrasonography guidance reduces complications and costs associated with thoracentesis procedures. *J Clin Ultrasound.* 2012;40(3):135–141.
16. Ding W, Shen Y, Yang J, He X, Zhang M. Diagnosis of pneumothorax by radiography and ultrasonography: a meta-analysis. *Chest.* 2011;140(4):859–866.
17. Alrajab S, Youssef AM, Akkus NI, Caldito G. Pleural ultrasonography versus chest radiography for the diagnosis of pneumothorax: review of the literature and meta-analysis. *Crit Care.* 2013;17(5):R208.
18. Lichtenstein D, Meziere G, Biderman P, Gepner A. The comet-tail artifact: an ultrasound sign ruling out pneumothorax. *Intensive Care Med.* 1999;25(4):383–388.
19. Picano E, Frassi F, Agricola E, Gligorova S, Gargani L, Mottola G. Ultrasound lung comets: a clinically useful sign of extravascular lung water. *J Am Soc Echocardiogr.* 2006;19(3):356–363.
20. Lichtenstein D, Meziere G. A lung ultrasound sign allowing bedside distinction between pulmonary edema and COPD: the comet-tail artifact. *Intensive Care Med.* 1998;24(12):1331–1334.
21. Volpicelli G, Mussa A, Garofalo G, et al. Bedside lung ultrasound in the assessment of alveolar-interstitial syndrome. *Am J Emerg Med.* 2006;24(6):689–696.
22. Rothe CF. Reflex control of veins and vascular capacitance. *Physiol Rev.* 1983;63(4):1281–1342.
23. Blair JE, Brennan JM, Goonewardena SN, Shah D, Vasaiwala S, Spencer KT. Usefulness of hand-carried ultrasound to predict elevated left ventricular filling pressure. *Am J Cardiol.* 2009;103(2):246–247.
24. Beigel R, Cercce B, Luo H, Siegel RJ. Noninvasive evaluation of right atrial pressure. *J Am Soc Echocardiogr.* 2013;26(9):1033–1042.
25. Miller JB, Sen A, Strote SR, et al. Inferior vena cava assessment in the bedside diagnosis of acute heart failure. *Am J Emerg Med.* 2012;30(5):778–783.
26. Blehar DJ, Dickman E, Gaspari R. Identification of congestive heart failure via respiratory variation of inferior vena cava diameter. *Am J Emerg Med.* 2009;27(1):71–75.
27. Goonewardena SN, Spencer KT. Handcarried echocardiography to assess hemodynamics in acute decompensated heart failure. *Curr Heart Fail Rep.* 2010;7(4):219–227.
28. Guiotto G, Masarone M, Paladino F, et al. Inferior vena cava collapsibility to guide fluid removal in slow continuous ultrafiltration: a pilot study. *Intensive Care Med.* 2010;36(4):692–696.
29. Carbone F, Bovio M, Rosa GM, et al. Inferior vena cava parameters predict readmission in ischemic heart failure. *Eur J Clin Invest.* 2014;44(4):341–349.
30. Goonewardena SN, Gemignani A, Ronan A, et al. Comparison of hand-carried ultrasound assessment of the inferior vena cava and N-terminal pro-brain natriuretic peptide for predicting readmission after hospitalization for acute decompensated heart failure. *JACC Cardiovasc Imaging.* 2008;1(5):595–601.
31. Laffin L, Patel AR, Saha N, et al. Inferior vena cava measurement by focused cardiac ultrasound in acute decompensated heart failure prevents hospital readmissions. *J Am Coll Cardiol.* 2014;63(12 suppl):A542.
32. Zhang Z, Xu X, Ye S, Xu L. Ultrasonographic measurement of the respiratory variation in the inferior vena cava diameter is predictive of fluid responsiveness in critically ill patients: systematic review and meta-analysis. *Ultrasound Med Biol.* 2014;40(5):845–853.
33. Pomero F, Dentali F, Borretta V, et al. Accuracy of emergency physician-performed ultrasonography in the diagnosis of deep-vein thrombosis: a systematic review and meta-analysis. *Thromb Haemost.* 2013;109(1):137–145.
34. Lichtenstein DA, Meziere GA. Relevance of lung ultrasound in the diagnosis of acute respiratory failure: the BLUE protocol. *Chest.* 2008;134(1):117–125.
35. Comert SS, Caglayan B, Akturk U, et al. The role of thoracic ultrasonography in the diagnosis of pulmonary embolism. *Ann Thorac Med.* 2013;8(2):99–104.
36. Koenig S, Chandra S, Alaverdian A, Dibello C, Mayo PH, Narasimhan M. Ultrasound assessment of pulmonary embolism in patients receiving computerized tomography pulmonary angiography. *Chest.* 2014;145(4):818–823.
37. Mookadam F, Jiamsripong P, Goel R, Warsame TA, Emani UR, Khandheria BK. Critical appraisal on the utility of echocardiography in the management of acute pulmonary embolism. *Cardiol Rev.* 2010;18(1):29–37.
38. Gesensway D. Making the case for portable ultrasound. *Today's Hospitalist.* 2012;10:32–36.
39. Spencer KT, Kimura BJ, Korcarz CE, Pellikka PA, Rahko PS, Siegel RJ. Focused cardiac ultrasound: recommendations from the American Society of Echocardiography. *J Am Soc Echocardiogr.* 2013;26(6):567–581.
40. Hellmann DB, Whiting-O'Keefe Q, Shapiro EP, Martin LD, Martire C, Ziegelstein RC. The rate at which residents learn to use hand-held echocardiography at the bedside. *Am J Med.* 2005;118(9):1010–1018.
41. Redberg RF, Walsch J. Pay now, benefits may follow—the case of cardiac computed tomographic angiography. *N Engl J Med.* 2008;359:2309–2311.
42. Blyth L, Atkinson P, Gadd K, Lang E. Bedside focused echocardiography as predictor of survival in cardiac arrest patients: a systematic review. *Acad Emerg Med.* 2012;19(10):1119–1126.
43. Martin LD, Mathews S, Ziegelstein RC, et al. Prevalence of asymptomatic left ventricular systolic dysfunction in at-risk medical inpatients. *Am J Med.* 2013;126(1):68–73.
44. Low D, Vlasschaert M, Novak K, Chee A, Ma IWY. An argument for using additional bedside tools, such as bedside ultrasound, for volume status assessment in hospitalized medical patients: a needs assessment survey. *J Hosp Med.* 2014;9:727–730.
45. Perera P, Mailhot T, Riley D, Mandavia D. The RUSH exam: Rapid Ultrasound in Shock in the evaluation of the critically ill. *Emerg Med Clin North Am.* 2010;28(1):29–56, vii.
46. Lichtenstein D. FALLS-protocol: lung ultrasound in hemodynamic assessment of shock. *Heart Lung Vessel.* 2013;5(3):142–147.
47. Kimura BJ, Yogo N, O'Connell CW, Phan JN, Showalter BK, Wolfson T. Cardiopulmonary limited ultrasound examination for “quick-look” bedside application. *Am J Cardiol.* 2011;108(4):586–590.
48. Manno E, Navarra M, Faccio L, et al. Deep impact of ultrasound in the intensive care unit: the “ICU-sound” protocol. *Anesthesiology.* 2012;117(4):801–809.
49. Cibinel GA, Casoli G, Elia F, et al. Diagnostic accuracy and reproducibility of pleural and lung ultrasound in discriminating cardiogenic causes of acute dyspnea in the emergency department. *Intern Emerg Med.* 2012;7(1):65–70.
50. Anderson KL, Jenq KY, Fields JM, Panebianco NL, Dean AJ. Diagnosing heart failure among acutely dyspneic patients with cardiac, inferior vena cava, and lung ultrasonography. *Am J Emerg Med.* 2013;31(8):1208–1214.