

DIAGNOSTIC RADIOLOGY OF PET AND WILD BIRDS: A REVIEW*
II. INDICATIONS OF RADIOLOGICAL EXAMINATION
AND RADIOGRAPHS OF PATHOLOGICAL LESIONS

A. BEREGI^{1**}, V. MOLNÁR¹, F. FELKAI¹, F. BÍRÓ¹ and ZS. SZENTGÁLI²

¹Outpatient Clinic, Department and Clinic of Internal Medicine and ²Department and Clinic of Surgery and Ophthalmology, University of Veterinary Science, H-1400 Budapest, P.O. Box 2, Hungary

(Received January 19, 1999; accepted June 24, 1999)

The second part of the review dealing with the diagnostic radiology of pet and wild birds discusses the indications of radiological examination, the interpretation of radiographs taken of pathological lesions, and the differential diagnosis of such lesions. Radiology has paramount importance in the diagnosis of diseases affecting the skeletal, digestive, respiratory, urogenital and cardiovascular systems. Certain diseases (shortage of grits, ovarian cysts) cannot be recognised without radiography. Other conditions (e.g. Macaw Wasting Disease, renal tumours, egg retention) require this complementary diagnostic method for confirmation of a suspicion based upon the clinical signs. Radiographic examination is also indicated for follow-up of the surgical management of bone fractures and for facilitating the implantation of transponders aimed at individual identification of the birds.

Key words: Pet birds, wild birds, radiology, diagnosis, indications, pathological lesions

Radiology as a complementary method has an important role in the diagnosis of pet bird diseases and in determining the indications of surgery. Radiographs may provide information on the status of organ systems and on the aetiology of pathological lesions.

Table 1 summarises the commonest indications of radiography, broken down by organ system.

Skeletal system and joints

Radiology has played an important role for the longest time as a complementary diagnostic method used for examining the skeletal system, first of all the limbs and joints, and for monitoring the healing of bone fractures (Cooper

* All illustrations are the authors' own photographs

** E-mail: aberegi@ns.univet.hu; Fax: +36 (1) 322-7416

and Kreel, 1976; McMillan, 1988; Paul-Murphy et al., 1990; Kostka and Krautwald-Junghanns, 1991; Kostka et al., 1991; Rübél et al., 1991; Krautwald et al., 1992).

Table 1

Indications of taking radiographs

Organ system	Radiological indications
Skeletal system	<ul style="list-style-type: none"> • traumas, fractures, luxations • follow-up of surgical interventions and the healing process • rachitis, osteomalacia of adult birds • bone tumours and deformations • foreign body (lead shots, bullets in wild birds)
Digestive system	<ul style="list-style-type: none"> • oesophageal stenosis and obstruction, dilatation and inflammation of the crop • obstruction and dilatation of the glandular stomach • atrophy of the muscular stomach, shortage of grits • lead poisoning, foreign body • gaseous distension of the intestines, enteritis • intestinal obstruction • hepatomegaly, hepatic cirrhosis, hepatic tumours
Respiratory system	<ul style="list-style-type: none"> • stenosis of the upper airways • mycoses (primarily aspergillosis) of the lungs and air sacs • pneumonia • airsacculitis
Urogenital system	<ul style="list-style-type: none"> • suspicion of renal tumour, renal enlargement, nephritis • gout • ovarian and testicular tumours, ovarian cysts • egg peritonitis, concrement, anomalies of egg formation • egg retention
Cardiovascular system	<ul style="list-style-type: none"> • cardiomegaly • sclerosis of the aorta

In the case of luxations (Fig. 1) and fractures (Fig. 2), a radiograph is also taken of the unaffected limb to facilitate preparation for surgery. Repeated radiological examination is needed after the intervention (Bush, 1978; Redig, 1978; Kummerfeld, 1987; Holz, 1992; Beynon et al., 1996; Baumgartner and Isenbügel, 1998; Dorrestein and Kummerfeld, 1998; Kummerfeld, 1998*a*; Kummerfeld, 1998*b*). Radiographs of wild birds often show the presence of lead shots or bullets (Hooimeijer and Zwart, 1987; Isenbügel and Rübél, 1987; Averbek et al., 1990; Heidenreich, 1996).

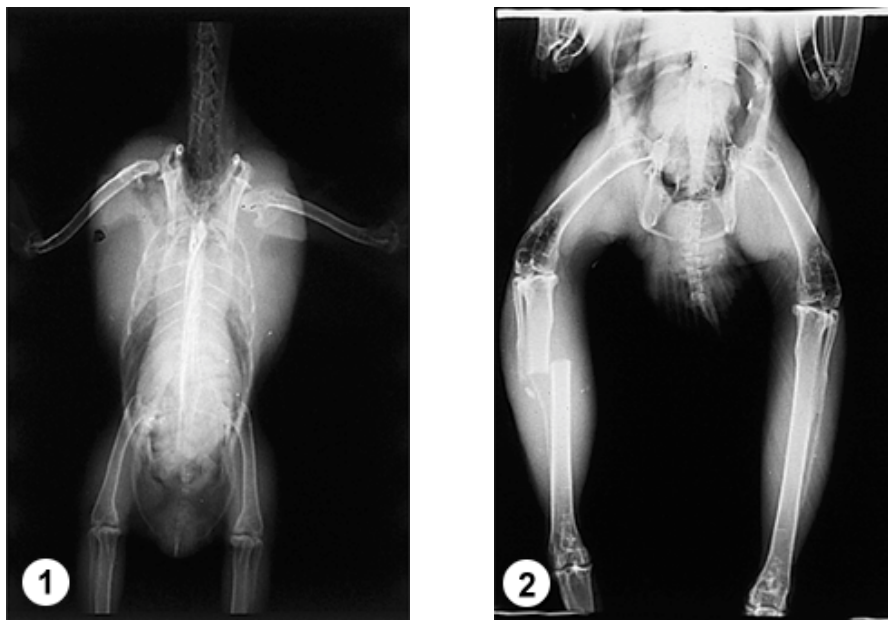


Fig. 1. Luxation of the right shoulder joint. Woodcock (*Scolopax rusticola*). Ventrodorsalis view

Fig. 2. Simple fracture of the right tibia and fibula. Pigeon hawk (*Accipiter gentilis*). Ventrodorsal view

Disturbances of bone metabolism are easy to interpret on the basis of radiographs, since rachitis (Fig. 3) and osteomalacia are characterised by a decrease in bone mass. Radiographs taken of birds suffering from tuberculosis show pronounced osteolysis (McMillan, 1988; Krautwald-Junghanns et al., 1991; Rübél et al., 1991; Korbél and Kösters, 1998; Kummerfeld, 1998a; Rübél and Isenbügel, 1998). In hypervitaminosis D and hypercalcaemia, calcic deposits can be observed in the bones, with the occasional presence of metastatic calcification in the kidney, lungs and glandular stomach (Schoemaker et al., 1997). Cortical periosteal exostoses accompanied by osteolytic processes are suggestive of hyperparathyroidism (Krautwald et al., 1987; Rübél and Isenbügel, 1998). Radiology is often indispensable in the diagnosis of bone tumours (Fig. 4).

Arthritis can be recognised on radiographs through inflammation of the surrounding tissues and the weaker shadow of the bone ends. Periarticular exostosis is a concomitant of chronic arthritis (Cooper and Kreel, 1976; Kösters and Jakoby, 1987; Kummerfeld, 1998a).

In frequently brooding female birds, increased oestrogen level due to ovarian cysts may lead to osteomyelosclerosis, which appears as hyperostosis on the radiograph (McMillan, 1988; Rübél et al., 1991; Baumgartner and Isenbügel, 1998; Krautwald et al., 1992).

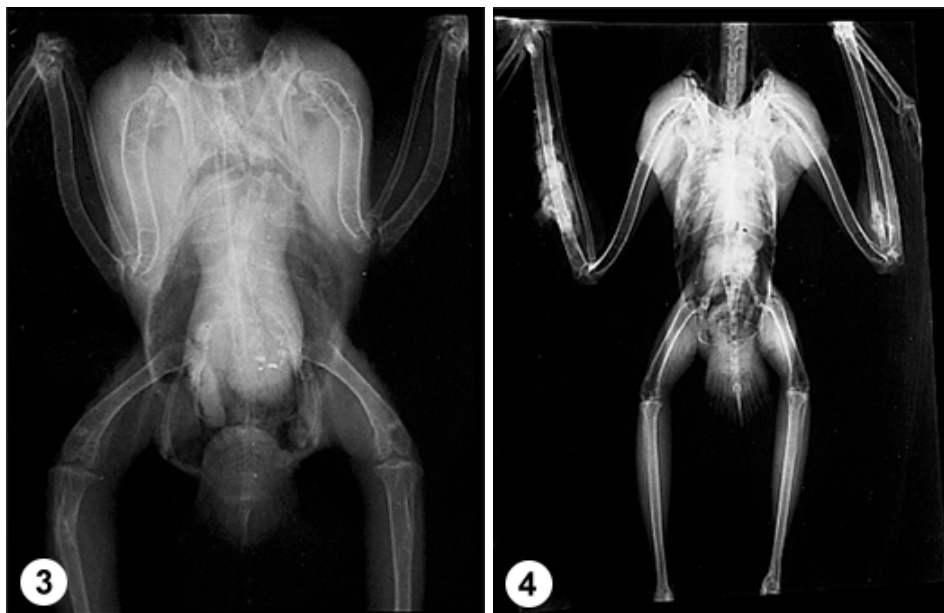

Fig. 3. Rachitis. African grey parrot (*Psittacus erythacus*). Ventrodorsal view
 Fig. 4. Osteosarcoma. Montagu's harrier (*Circus pygargus*). Ventrodorsal view

On radiographs taken of diurnal raptors and owls, the bones of the prey animal are occasionally well discernible in the stomach. If possible, such birds should be radiographed after one-day fasting (Hooimeijer and Zwart, 1987; Isenbügel and Rübel, 1987).

Digestive organs

Pathological conditions of the oesophagus are usually more easily detectable on radiographs taken in latero-lateral (LL) view. Oesophageal obstruction and stenosis is indicated by passage disturbances and accumulation of air. Advanced stages of hypovitaminosis A are characterised by epithelial metaplasia, which is seen as thickening of the oesophageal mucosa (and enlargement of the kidney) on the radiographs (Krautwald and Schildger, 1986; Krautwald et al., 1987; Rübel et al., 1991).

Dilatation of the crop, which occurs primarily in old budgerigars, is often accompanied by inflammatory processes (McMillan, 1988). On radiographs of birds with inflammation of the crop, the wall of the crop is thickened and gives a stronger shadow. Obstruction of the crop is a rare condition which occurs first of all in birds of prey (Fig. 5).

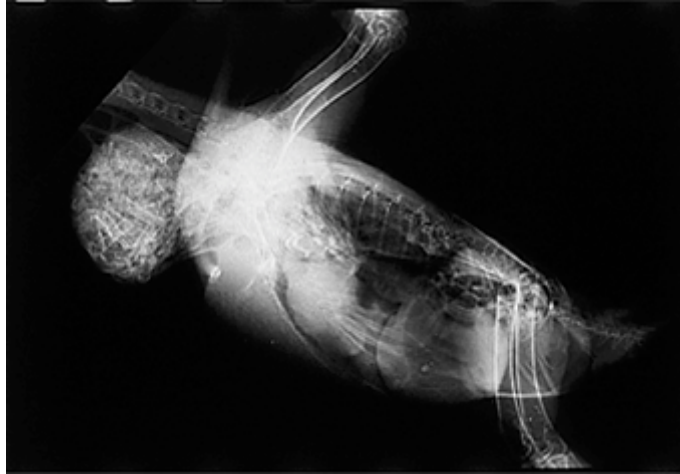

Fig. 5. Crop obstruction. Metal shadow of a leg ring of a prey animal (pigeon) stuck in the oesophagus, dorsal to the base of the heart. Peregrine falcon (*Falco peregrinus*). Latero-lateral view

In the case of macaw wasting disease of unknown aetiology ('neuropathic gastric dilatation of macaws') the glandular stomach is dilated and thin walled, while the muscular stomach is atrophic and often filled with grits (Krautwald et al., 1987; Rübél et al., 1991; Beynon et al., 1996; Gough et al., 1996). Contrast radiography can be used for evaluation of the lesions to confirm the diagnosis (Fig. 6).

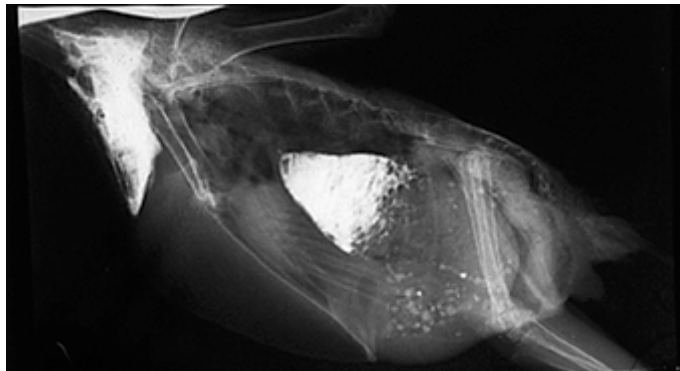

Fig. 6. Dilatation of the glandular stomach, one hour after the administration of contrast agent. African grey parrot (*Psittacus erythacus*). Latero-lateral view

Of those pathological changes of the muscular stomach (ventriculus) which can be studied by radiological methods, poisoning with lead and other heavy metals is of great importance in parrots pecking at the painted wire-netting

of their cages (Fig. 7). Foreign bodies taken up by the oral route may occur almost anywhere in the digestive tract; however, due to the anatomical conditions, foreign bodies most often get stuck in the muscular stomach (Hooimeijer and Zwart, 1987; Kösters and Jakoby, 1987; Kummerfeld, 1987; Kummerfeld and Erhorn, 1991; Rübel et al., 1991; Beynon et al., 1996; Korbel and Kösters, 1998; Rübel and Isenbügel, 1998). The muscular stomach of birds affected with atrophy of the stomach wall does not contain grits. In contrast, in some cases there is an excessive amount of grit in the ventriculus (Krautwald et al., 1992). Dislocation of the muscular stomach is brought about by the enlargement or diminution of some other abdominal organ. The direction of dislocation is suggestive of the organ that caused it (McMillan, 1988; McMillan, 1996).

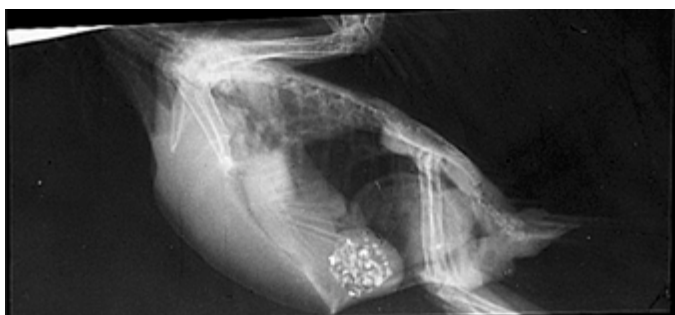

Fig. 7. Lead poisoning. Alexandrine parakeet (*Psittacula eupatria*). Latero-lateral view

The different portions of the intestinal tract cannot be distinguished on plain radiographs. In enteritis, the intestinal loops cast a larger and denser radiographic shadow (Fig. 8). In meteorism, the produced gas makes the intestines well discernible (Rübel, 1983; McMillan, 1988; Rübel et al., 1991; Beynon et al., 1996). For the diagnosis of ileus contrast radiographs are needed (Dorrestein and Kummerfeld, 1998). In severe parasitic infection the initial portion of the intestine, especially the loops of the duodenum are enlarged (Krautwald et al., 1987; Rübel et al., 1991; Krautwald et al., 1992).

In birds with fibrotic or cirrhotic degeneration of the liver, the radiographic shadow of the liver is more pronounced and slightly enlarged (Fig. 9) or diminished (Rübel et al., 1991; Kummerfeld, 1998a).

Contrast radiography performed in birds with paralysis of the pelvic limb may shed light on disturbances in the innervation of the gastrointestinal tract; namely, cloacal paralysis due to a spinal cord injury may result in the accumulation of faeces (Ungerechts, 1989).

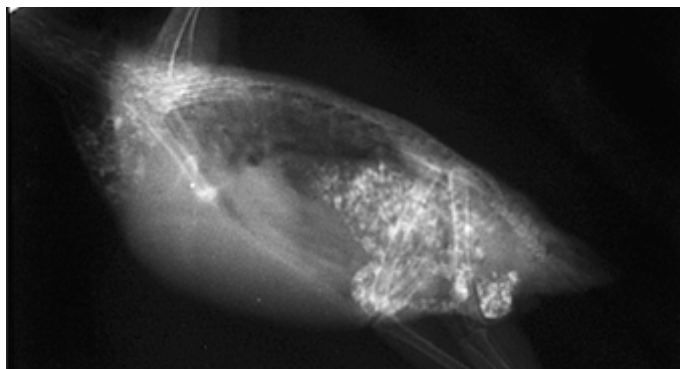


Fig. 8. Enteritis. Cockatiel (*Nymphicus hollandicus*). Latero-lateral view

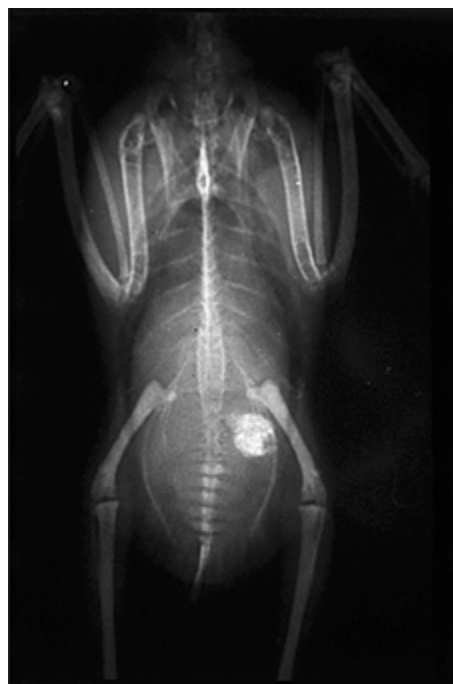


Fig. 9. Hepatomegaly. Alexandrine parakeet (*Psittacula eupatria*). Ventrodorsal view

Respiratory system

Of lesions of the upper airways, tracheal injuries can be evaluated in the same manner as in mammals. Stenosis of the trachea and syrinx, usually caused by fungal infections, can be diagnosed by the accumulation of air in the lower

airways, especially in the abdominal air sacs, which gives a negative contrast in the caudal part of the coelomic cavity (Krautwald et al., 1987; Krautwald-Junghanns, 1992).

Intensification of the pulmonary shadow is often attributable to bacterial infections (McMillan, 1988; Rübél et al., 1991). Radiographs of birds with tuberculosis show the presence of multiple focus-like spots in the lungs (Rübél, 1983; Isenbügel and Rübél, 1987; Krautwald-Junghanns et al., 1991; Krautwald et al., 1992).

Pulmonary granulomas due to mycoses appear as asymmetric foci in the pulmonary tissue (Rübél and Isenbügel, 1998). Mycoses can be easily diagnosed in ventrodorsal radiographs (the thoracic and abdominal air sacs cast an asymmetric shadow), while in latero-lateral view (cavern formation at the borders of air sacs) they can be detected only when the disease is well advanced (Hooimeijer and Zwart, 1987; McMillan, 1988; McMillan and Petrak, 1989; Rübél et al., 1991; Krautwald et al., 1992; Krautwald-Junghanns, 1992; Korbel et al., 1993; Beynon et al., 1996; McMillan, 1997; Dorrestein and Kummerfeld, 1998).

Enlargement of the air sacs is often attributable to the greater stress preceding radiography, e.g. flying (cervical air sac) or to the already mentioned upper airway stenosis (abdominal air sac) (James et al., 1976; Rübél and Isenbügel, 1998).

Air sac rupture, which is usually of traumatic origin, mostly affects the interclavicular air sac. In such a case, the size and location of the subcutaneous emphysema and the injuries and foreign bodies present in the area may provide a clue to the eliciting factor (Krautwald et al., 1987; Krautwald-Junghanns et al., 1993).

Urogenital system

The radiological diagnosis of nephritis is difficult or ambiguous. The clinical features are much more important in the diagnosis of that condition. In acute nephritis a markedly enlarged kidney is seen on the radiograph, while chronic nephritis is characterised by crystalline deposits (Rübél et al., 1991; Krautwald et al., 1992; Dorrestein and Kummerfeld, 1998).

Similar crystal formation is seen on radiographs of birds with elevated blood uric acid content (Fig. 10). In advanced stages of uricosis occasionally the enlargement of joints and intensification of their radiographic shadow can also be observed (Isenbügel and Rübél, 1987; Kummerfeld, 1987; McMillan, 1988; Beynon et al., 1996; Baumgartner and Isenbügel, 1998; Korbel and Kösters, 1998; Kummerfeld, 1998*a*).

Pronounced nephromegaly is suggestive of neoplastic disease (Fig. 11). Abnormal location of the abdominal organs, especially that of the ventriculus,

facilitates the diagnosis (Krautwald et al., 1987; Beynon et al., 1996; Heidenreich, 1996; McMillan, 1996; Baumgartner and Isenbügel, 1998).

In the mating season, the ovaries and the testes can be seen cranial to the kidneys and dorsal to the liver. These organs show enormous hyperplasia in the reproductive season (McMillan, 1988; Rübel et al., 1991).

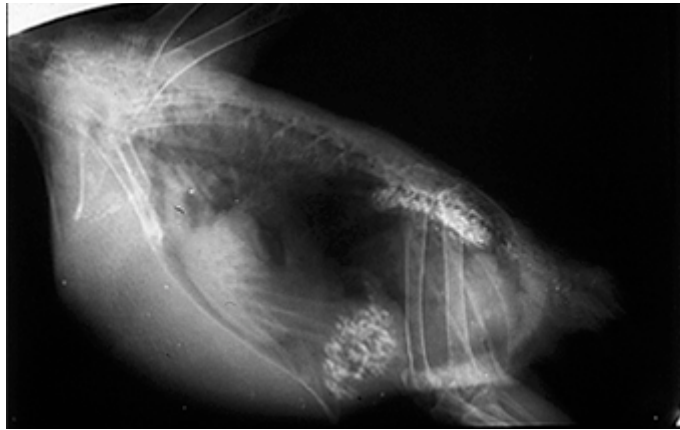


Fig. 10. Visceral gout. African grey parrot (*Psittacus erythacus*). Latero-lateral view

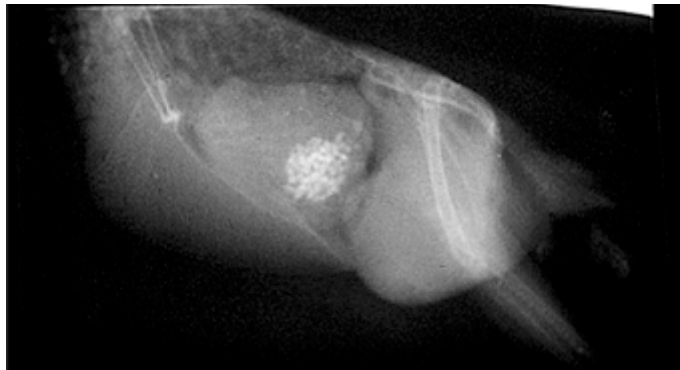

Fig. 11. Renal tumour. Budgerigar (*Melopsittacus undulatus*). Latero-lateral view

The most common radiologically detectable abnormalities of the genital organs include obstruction of the oviduct, egg retention, and salpingitis. Oviductal obstruction may be caused by egg components, concretions consisting of different materials (Fig. 12) or hyperplasia of the mucous membrane (Hooimeijer and Zwart, 1987; Kösters and Jakoby, 1987; Kummerfeld, 1987; McMillan, 1988; Rübel et al., 1991; Beynon et al., 1996; Korbel and Kösters, 1998; Kummerfeld, 1998a; Kummerfeld, 1998b).

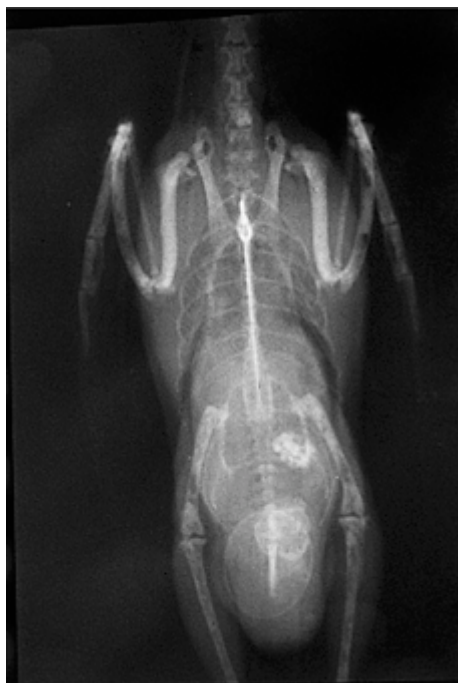


Fig. 12. Retained egg, concrement, osteomyeloclerosis. Budgerigar (*Melopsittacus undulatus*).
Ventrodorsal view

Cardiovascular system

Radiological examination of the cardiovascular system of pet birds is mostly done by the analysis of plain radiographs. Cardiomegaly is the most important abnormality that can be detected (Rosenthal and Stamoulis, 1993).

Atherosclerosis is most often seen in old and obese parrots. On the radiograph, the sclerotic aorta can be followed down to the kidneys (Rübel et al., 1991; Beynon et al., 1996; Rübel and Isenbügel, 1998).

In birds suffering from visceral gout, uric acid deposited in the pericardium may cause increased density of the cardiac silhouette (Isenbügel and Rübel, 1987; McMillan, 1988; Baumgartner and Isenbügel, 1998).

According to Ungerechts (1989), contrast radiography of the heart (angiocardiology) in parrots is justified if the cause of paroxysmal circulatory and central nervous system disturbances cannot be determined by other diagnostic methods. This method is rarely used because it is difficult to carry out.

Radiological examination also facilitates the diagnosis of the following diseases and lesions that cannot be assigned to any of the organ systems listed above: ascites (Fig. 13), abdominal hernia, peritonitis, splenomegaly, and splenic

tumour (Krautwald et al., 1987; McMillan, 1988; Pugh and Bishop, 1991; Rübél et al., 1991; Krautwald et al., 1992; Dorrestein and Kummerfeld, 1998).

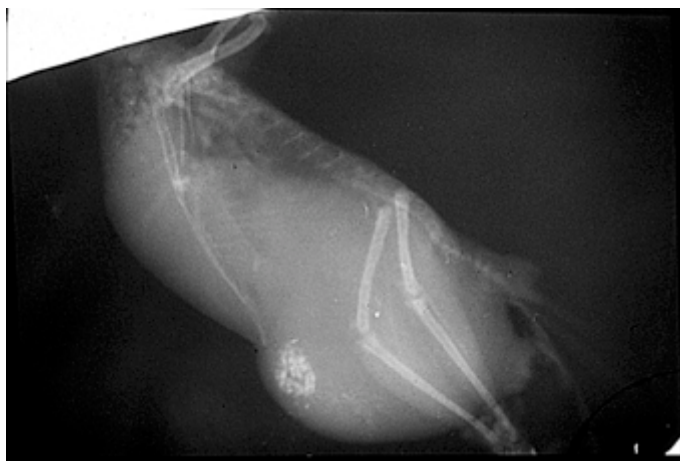


Fig. 13. Ascites. Budgerigar (*Melopsittacus undulatus*). Latero-lateral view

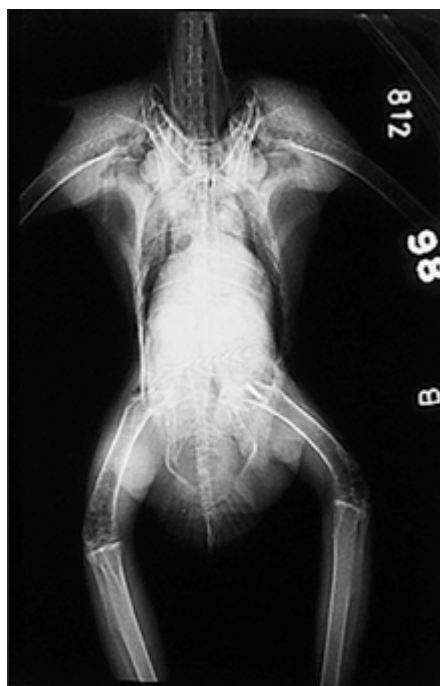

Fig. 14. Transponder implanted into the head of the femur to allow individual identification. Common buzzard (*Buteo buteo*). Ventrodorsal view

The individual identification of parrots and raptors of high value is rendered possible by the implantation of microchips under the skin, into the breast muscles or femur (Fig. 14) or, less frequently, to some other site. Such implanted microchips are radiographically detectable (Rübel et al., 1991; Heidenreich, 1996).

Acknowledgements

The authors thank Dr János Déri (Pusztadoktor Kft., Hortobágy), Mrs Józsefné Kampó (Department and Clinic of Surgery and Ophthalmology, University of Veterinary Science, Budapest) and Miss Éva Orbán (Central Library of the University of Veterinary Science, Budapest) for their help rendered in the compilation of this paper.

References

- Averbeck, C., Kempken, E., Petermann, S., Pruter, J., Vauk, G. and Visse, C. (1990): Radiological studies of lead shot pellets in tissues of various species of birds found dead in Northern Germany (in German). *Zeitschrift für Jagdwissenschaft* **36**, 30–42.
- Baumgartner, R. and Isenbügel, E. (1998): Budgerigars. In: Gabrisch, K. and Zwart, P. (eds) *Diseases of Companion Animals* (in German). Schlütersche, Hannover. pp. 429–486.
- Beynon, P. H., Forbes, N. A. and Lawton, M. P. C. (1996): *Manual of Psittacine Birds*. British Small Animal Veterinary Association, Gloucestershire.
- Bush, M. (1978): Special medicine: birds. Laparoscopy and surgery. In: Fowler, E. M. (ed.) *Zoo and Wild Animal Medicine*. W. B. Saunders Company, Philadelphia. pp. 253–262.
- Cooper, J. E. and Kreef, L. (1976): Radiological examination of birds: report of small series. *J. Small Anim. Pract.* **17**, 799–808.
- Degernes, L. A. (1994): Abdominal mass due to chronic salpingitis in an African Grey parrot (*Psittacus erithacus*). *Vet. Radiol. Ultrasound* **35**, 24–28.
- Dorresteijn, G. M. and Kummerfeld, N. (1998): Songbirds. In: Gabrisch, K. and Zwart, P. (eds) *Diseases of Companion Animals* (in German). Schlütersche, Hannover. pp. 327–395.
- Gough, R. E., Drury, S. E., Harcourt-Brown, N. H. and Higgins, R. J. (1996): Virus-like particles associated with macaw wasting disease. *Vet. Rec.* **139**, 24.
- Heidenreich, M. (1996): *Raptors. Diseases, Husbandry, Breeding*. Blackwell Wissenschaft, Berlin–Wien.
- Holz, P. (1992): Luxation of the stifle joint in a Major Mitchell cockatoo. *Vet. Rec.* **130**, 34.
- Hooimeijer, J. and Zwart, P. (1987): Owls. In: Gabrisch, K. and Zwart, P. (eds) *Diseases of Wild Animals. Exotic and Native Animals Seen in a Veterinary Practice* (in German). Schlütersche, Hannover. pp. 253–274.
- Isenbügel, E. and Rübel, A. (1987): Raptors. In: Gabrisch, K. and Zwart, P. (eds) *Diseases of Wild Animals. Exotic and Native Animals Seen in a Veterinary Practice* (in German). Schlütersche, Hannover. pp. 191–252.
- James, A. E., Hutchins, G., Bush, M., Natarajan, T. K. and Burns, B. (1976): How birds breathe: correlation of radiographic with anatomical and pathological studies. *J. Am. Vet. Radiol. Soc.* **17**, 77–86.
- Korbel, R., Bauer, J. and Gedek, B. (1993): Pathological-anatomical and mycotoxicological examination of aspergillosis in birds (in German). *Tierärztl. Praxis* **21**, 134–139.

- Korbel, R. and Kösters, J. (1998): Mynah birds. In: Gabrisch, K. and Zwart, P. (eds) Diseases of Companion Animals (in German). Schlütersche, Hannover. pp. 397–428.
- Kösters, J. and Jakoby, J. R. (1987): Ducks and geese. In: Gabrisch, K. and Zwart, P. (eds) Diseases of Wild Animals. Exotic and Native Animals Seen in a Veterinary Practice (in German). Schlütersche, Hannover. pp. 363–399.
- Kostka, V. and Krautwald-Junghanns, M. E. (1991): Radiological diagnosis of bone diseases in avian patients (in German). *Prakt. Tierarzt* **72**, 97–99.
- Kostka, V., Krautwald-Junghanns, M. E. and Tellhelm, B. (1991): Radiology of the avian skull. *J. Vet. Med.* **38**, 175–186.
- Krautwald, M. E. and Schildger, B. (1986): Oesophageal obstruction due to foreign body in a peacock (in German). *Tierärztl. Praxis* **14**, 491–494.
- Krautwald, M. E., Schildger, B. and Stamer, H. (1987): Radiological diagnosis of internal diseases in avian patients (in German). *Prakt. Tierarzt* **68**, 57–60.
- Krautwald, M. E., Tellhelm, B., Hummel, G., Kostka, V. and Kaleta, E. F. (1992): Atlas of Radiographic Anatomy and Diagnosis of Cage Birds. Paul Parey, Edinburgh.
- Krautwald-Junghanns, M. E. (1992): Respiratory diseases of cage birds. Advances in diagnosis and therapy (in German). *Prakt. Tierarzt* **73**, 970–976.
- Krautwald-Junghanns, M. E., Kostka, V. and Pieper, K. (1991): Radiological alteration in tuberculosis in pet birds and birds of prey (in German). *Tierärztl. Praxis* **19**, 156–162.
- Krautwald-Junghanns, M. E., Schumacher, F. and Tellhelm, B. (1993): Evaluation of the lower respiratory tract in psittacines using radiology and computed tomography. *Vet. Radiol. Ultrasound* **34**, 382–390.
- Kummerfeld, N. (1987): Storks and cranes. In: Gabrisch, K. and Zwart, P. (eds) Diseases of Wild Animals. Exotic and Native Animals Seen in a Veterinary Practice (in German). Schlütersche, Hannover. pp. 275–318.
- Kummerfeld, N. (1998a): Pigeons. In: Gabrisch, K. and Zwart, P. (eds) Diseases of Companion Animals (in German). Schlütersche, Hannover. pp. 569–624.
- Kummerfeld, N. (1998b): Gallinaceous birds. In: Gabrisch, K. and Zwart, P. (eds) Diseases of Companion Animals (in German). Schlütersche, Hannover. pp. 625–662.
- Kummerfeld, N. and Erhorn, I. (1991): Clinical and radiological diagnosis of foreign bodies in companion birds (in German). *Dtsch. tierärztl. Wschr.* **98**, 156–158.
- McMillan, M. C. (1988): Radiology. In: Petrak, M. L. (ed.) *Diagnosis of Diseases in Pet Birds, Radiology, Surgery* (in German). Ferdinand Enke, Stuttgart.
- McMillan, M. C. (1996): Radiographic diagnosis of avian abdominal disorders (in Italian). *Veterinaria Cremona* **10**, 77–97.
- McMillan, M. C. (1997): Radiology of avian respiratory diseases (in Italian). *Veterinaria Cremona* **11**, 81–87.
- McMillan, M. C. and Petrak, M. L. (1989): Retrospective study of aspergillosis in pet birds. *J. Assoc. Avian Vet.* **3**, 211–215.
- Paul-Murphy, J., Koblik, P. D., Stein, G. and Penninck, D. (1990): Psittacine skull radiography. Anatomy, radiographic technic and patient application. *Vet. Radiol.* **31**, 125–131.
- Pugh, C. R. and Bishop, C. R. (1991): Radiographic diagnosis. Fibrinoid splenitis in a cockatoo. *Vet. Radiol.* **32**, 257–258.
- Redig, P. T. (1978): Special medicine: birds. Raptors (Falconiformes and Strigiformes). A clinical review of orthopedic techniques used in the rehabilitation of raptors. In: Fowler, E. M. (ed.) *Zoo and Wild Animal Medicine*. W. B. Saunders Company, Philadelphia. pp. 388–401.
- Rosenthal, K. and Stamoulis, M. (1993): Diagnosis of congestive heart failure in an Indian mynah bird (*Gracula religiosa*). *J. Am. Assoc. Avian Vet.* **7**, 27–30.

- Rübel, A. (1983): Radiological studies in parrots. Technique and typical findings in internal diseases. In: Ippen, R. and Schröder, H. D. (eds) Diseases of Animals in Zoological Gardens. Proceedings 25th Symposium of the Diseases of Animals in Zoological Gardens, Wien, May 11–15, 1983 (in German). Akademie, Berlin. pp. 45–48.
- Rübel, A. and Isenbügel, E. (1998): Parrots. In: Gabrisch, K. and Zwart, P. (eds) Diseases of Companion Animals (in German). Schlütersche, Hannover. pp. 487–568.
- Rübel, A. G., Isenbügel, E. and Wolvekamp, P. (1991): Atlas of Diagnostic Radiology of Exotic Pets. Schlütersche, Hannover.
- Schoemaker, N. J., Lumeij, J. T. and Beynen, A. C. (1997): Polyuria and polydipsia due to vitamin and mineral over supplementation of the diet of a salmon crested cockatoo (*Cacatua moluccensis*) and a blue and gold macaw (*Ara ararauna*). Avian Pathol. **26**, 201–209.
- Ungerechts, N. (1989): Radiography with contrast media for diagnosing internal diseases of budgerigars (in German). Dissertation, Ludwig-Maximilians-Universität, München.