

## Differential In Situ Cytokine Gene Expression in Acute versus Chronic Atopic Dermatitis

Qutayba Hamid,\* Mark Boguniewicz,<sup>‡§</sup> and Donald Y. M. Leung<sup>‡§</sup>

\*Meakins-Christie Laboratories and Department of Pathology, McGill University, Montreal, Quebec, Canada H2X 2P2, <sup>‡</sup>Department of Pediatrics, The National Jewish Center for Immunology and Respiratory Medicine, Denver, Colorado 80206, and <sup>§</sup>Department of Pediatrics, University of Colorado Health Sciences Center, Denver, Colorado 80262

### Abstract

The mechanisms involved in the initiation and maintenance of skin inflammation in atopic dermatitis (AD) are poorly understood. Recent data suggest that the pattern of cytokines expressed locally plays a critical role in modulating the nature of tissue inflammation. In this study, we used in situ hybridization to investigate the expression of interleukin 4 (IL-4), IL-5, and interferon-gamma (IFN- $\gamma$ ) messenger RNA (mRNA) in skin biopsies from acute and chronic skin lesions of patients with AD. As compared with normal control skin or uninvolved skin of patients with AD, acute and chronic skin lesions had significantly greater numbers of cells that were positive for mRNA, IL-4 ( $P < 0.01$ ), and IL-5 ( $P < 0.01$ ), but not for IFN- $\gamma$  mRNA expressing cells. However, as compared with acute AD skin lesions, chronic AD skin lesions had significantly fewer IL-4 mRNA-expressing cells ( $P < 0.01$ ), but significantly greater IL-5 mRNA ( $P < 0.01$ ). T cells constituted the majority of IL-5-expressing cells in acute and chronic AD lesions. Chronic lesions also expressed significantly greater numbers of activated EG2+ eosinophils than acute lesions ( $P < 0.01$ ). These data indicate that although acute and chronic AD lesions are associated with increased activation of IL-4 and IL-5 genes, initiation of acute skin inflammation in AD is associated with a predominance of IL-4 expression whereas maintenance of chronic inflammation is predominantly associated with increased IL-5 expression and eosinophil infiltration. (*J. Clin. Invest.* 1994. 94:870–876.) Key words: atopic dermatitis • inflammation • cytokines • eosinophils • T cells

### Introduction

Atopic dermatitis (AD)<sup>1</sup> is a chronic skin disease affecting up to 10% of children and is the major cause of occupation-related

disability caused by skin disease. It is associated with intense pruritus, increased serum IgE levels, and peripheral blood eosinophilia (1, 2). The actual events that result in this inflammatory skin condition are poorly understood. However, it is thought that genetic susceptibility, environmental trigger factors such as allergens, and altered immune responses contribute to its pathogenesis (3). Acute and chronic skin lesions in AD are characterized by the infiltration of activated T cells and monocyte-macrophages (4, 5). Although eosinophils are not prevalent by routine histology, chronic AD is associated with extensive dermal deposition of eosinophil-granule major basic protein (6). In this regard, serum levels of sIL2R and eosinophil cationic protein have been reported to correlate with severity of skin disease (7, 8). Favorable clinical responses of AD patients to cyclosporin A also implicate immune activation as an important mechanism in the pathogenesis of AD (9, 10).

Identification of the immunologic elements that play a role in initiating and maintaining skin inflammation in AD is critical for the development of new approaches to treat this common and often debilitating skin disease. Studies of T cell clones support the concept that activation of a subpopulation of helper cells leads to the release of cytokines important in the pathogenesis of allergic diseases. In mice, two types of CD4+ T cell clones have been described on the basis of their cytokine gene transcription and secretion (11). T helper type 1 (Th1) cells express mRNA and secrete IL-2 and interferon-gamma (IFN- $\gamma$ ) but not IL-4 or IL-5. In contrast, Th2 cells elaborate IL-4 and IL-5 but not IFN- $\gamma$ . Both subpopulations of T cells produce IL-3, GM-CSF, and TNF- $\alpha$ . IL-4 acts as an IgE isotype-specific switch factor (reviewed in reference 12), promotes mast cell growth (13), and induces the expression of vascular cell adhesion molecule (VCAM-1), an adhesion molecule involved in the migration of mononuclear cells and eosinophils into sites of tissue inflammation (14). IL-5 promotes the differentiation, vascular endothelial adhesion and survival of eosinophils as well as enhances histamine release from basophils (reviewed in reference 15). In contrast, IFN- $\gamma$  inhibits IgE synthesis as well as the proliferation of IL-4 and IL-5-producing Th2 lymphocytes (16, 17). The lack of IFN- $\gamma$  production, as well as the concomitant activation of IL-4 and IL-5, is thought to play a critical role in the pathogenesis of AD and asthma (17–19).

Address correspondence to Donald Y. M. Leung, M.D., Ph.D., Department of Pediatrics, National Jewish Center for Immunology and Respiratory Medicine, 1400 Jackson Street, Denver, CO 80206.

Received for publication 11 January 1994 and in revised form 7 April 1994.

*J. Clin. Invest.*

© The American Society for Clinical Investigation, Inc.

0021-9738/94/08/0870/07 \$2.00

Volume 94, August 1994, 870–876

1. Abbreviations used in this paper: AD, atopic dermatitis; CLA, cutaneous lymphocyte antigen; DTH, delayed type hypersensitivity; LPR, late phase reactions; MBP, eosinophil major basic protein; Th1, T helper type 1; VCAM, vascular cell adhesion molecule.

To date, there have been no studies directly examining cytokine expression in AD skin lesions. Since the pattern of local cytokine expression may play a critical role in the nature of the inflammatory response in AD, the current study used *in situ* hybridization to determine the cytokine mRNA, particularly of IL-4, IL-5, and IFN- $\gamma$ , in acute and chronic skin lesions as well as uninvolved skin of AD patients. Furthermore, since eosinophils play an important role in allergic inflammation, the numbers of EG2+ cells in the different AD skin lesions were also examined.

## Methods

**Skin biopsy specimens.** As indicated in Table I, a total of 19 punch skin biopsy specimens were obtained from 12 patients meeting the diagnostic criteria for AD (1, 2): 7 biopsies from acute, erythematous AD lesions of less than 3 d onset, 7 biopsies from chronic lichenified AD lesions of greater than 2 wk duration, and 5 biopsies from uninvolved skin. The clinical severity of each skin lesion was graded on the following bases: Acute skin lesions were assessed by averaging the degree of erythema, papulation, and excoriation. Chronic skin lesions were assessed by averaging the degree of scaling/dryness and lichenification. Each parameter was measured on a half-point incremental scale from 0–3 (1 = mild, 2 = moderate, and 3 = severe). Skin biopsies were fixed immediately in freshly prepared 4% paraformaldehyde for 2 h, then washed twice (1 h each) with 15% sucrose in 0.1 M phosphate-buffered saline (PBS) pH 7.4. Tissues were blocked with ornithine carbamyl transferase and kept at  $-80^{\circ}\text{C}$  until used.

The AD patients' ages ranged from 19 to 49 yr old (median age = 28 yr); 6 were male and 6 were female. All patients had a history of AD dating back to early infancy and had associated respiratory allergy (allergic rhinitis and/or asthma). Serum IgE levels ranged from 269 to 10,700 IU/ml (median IgE level = 5,300). None of these patients had other skin conditions and none had previously received oral steroids. Topical steroids were withheld for at least 2 wk before biopsies were performed. Control specimens of normal skin were also obtained from 7 healthy individuals (ages 24–33 yr). Informed consent was obtained from all subjects prior to performing these studies.

***In situ* hybridization.** *In situ* hybridization was performed as we have previously described (19–22). In brief, riboprobes, both antisense (complementary to mRNA) and sense (having an identical sequence to mRNA) were prepared from cDNA for IL-4, interferon-gamma (IFN- $\gamma$ ) and IL-5 as described (22). cDNA were inserted into different pGEM vectors and linearized with appropriate enzymes before transcription. Transcription was performed in the presence of  $^{35}\text{S}$ -UTP and the appropriate T7 or SP6 RNA polymerases. For *in situ* hybridization, cryostat sections were permeabilized with Triton X-100 and proteinase K (1  $\mu\text{g}/\text{ml}$ ) in 0.1 M Tris containing 50 mM EDTA for 20 min at  $37^{\circ}\text{C}$ . To prevent nonspecific binding of  $^{35}\text{S}$ -labeled RNA probes, the preparations were incubated with 10 mM *N*-ethyl maleimide and 10 mM iodoacetamide for 30 min at  $37^{\circ}\text{C}$  and then in 0.5% acetic anhydride and 0.1 M triethanolamine for 10 min at  $37^{\circ}\text{C}$  (21). Prehybridization was carried out with 50% formamide and  $2\times$  standard saline citrate (SSC) for 15 min at  $40^{\circ}\text{C}$ . For hybridization, antisense or sense probes ( $10^6$  cpm/section) diluted in hybridization buffer were used (23). Dithiothreitol (100 mM) was included in the hybridization mixture to ensure blocking of any further nonspecific binding of the  $^{35}\text{S}$ -labeled probes. Posthybridization washing was performed in decreasing concentrations of SSC at  $45^{\circ}\text{C}$ . Unhybridized single-strand RNAs were removed by RNase A (20  $\mu\text{g}/\text{ml}$ ). After dehydration, the sections were immersed in NBT<sub>2</sub> emulsion and exposed for 10 d. The autoradiographs were developed in Kodak D-19, fixed and counterstained with hematoxylin.

Slides were coded and positive cells counted blindly using  $\times 100$  magnification with an eyepiece graticule. The results were expressed as mean number of positive cells/field. The number of fields/section

counted were two to six depending on the size of the biopsy and the pattern of alignment of the grid covering an intact area of epithelial and subepithelial tissue. The within observer coefficient of variation for repeated measures was less than 5%.

For the negative controls, skin biopsies were hybridized using sense probes for the relevant cytokines. In addition, sections were treated with RNase-A solution before the prehybridization step with antisense probes. Specific hybridization was recognized as dense deposits of silver grains in the photographic emulsion overlaying the tissue sections. Cells were identified as dense, discrete, well circumscribed areas of silver grains. When hybridizing cells were in close proximity, their numbers were determined by visualizing the individual nuclei using dark field illumination. Positive cells were only observed with an antisense probe; preparations treated with sense probes or pretreated with RNase were negative with only baseline background signals.

**Immunohistology and cytokine mRNA localization.** Cryostat sections (6  $\mu\text{m}$ ) were freshly cut from skin biopsies, mounted on slides coated with 0.1% poly-L-lysine (Sigma Chemical Co., St. Louis, MO) and air-dried for 2 h at room temperature. The alkaline phosphatase anti-alkaline phosphatase (APAAP) technique was used to detect EG2 and BMK-13 immunoreactivity. Monoclonal antibody (mAb) EG2 recognizes the cleaved and secreted form of eosinophil cationic protein, and hence, identifies activated eosinophils within tissues (24). Mab BMK-13, a kind gift from Dr. R. Moqbel (National Heart and Lung Institute, London) was raised against eosinophil major basic protein (MBP) and thus recognizes all eosinophils (25). The APAAP technique was used to enumerate activated and total eosinophils as previously described (20). EG2 antibody and BMK-13 were both used at a 1:30 dilution. As described in a previous publication (20), an irrelevant IgG isotype control was used as a negative control.

In selected experiments, cell localization of cytokine mRNA was performed using double immunostaining and *in situ* hybridization with digoxigenin labeled-IL-5 RNA probes and monoclonal antibodies to CD3 (T cells) and BMK-13 (total eosinophils). We previously described the details of this method in reference 26.

**Quantification and statistical analysis.** For both immunohistology and *in situ* hybridization slides were counted "blind" using an eyepiece graticule. For each biopsy at least two sections were immunostained or hybridized from which two to six fields were counted depending on the size of the biopsy and the pattern of alignment of the grid covering an intact area of epithelial and subepithelial tissue. Results were expressed as positive cells per field ( $0.202\text{ mm}^2$ ). The within observer coefficient of variation was  $< 5\%$ .

Statistical comparison of immunohistology counts and *in situ* hybridization results was performed with the Mann-Whitney U test with Minitab PC software (Minitab Project, University Park, PA).

## Results

Skin biopsies were obtained from a total of 19 donors: 12 with AD and 7 normal controls (Table I). From the 12 AD patients, skin biopsies were obtained from 7 acute erythematous lesions, 7 chronic lichenified plaques, and 5 uninvolved areas. The 5 biopsies of each type of lesion were derived from different donors. However, as shown in Table I, four biopsies of acute lesions and four chronic lichenified lesions were derived from the same donor. Biopsies of uninvolved areas were obtained from five donors, three of whom also provided biopsies from either acute or chronic lesions.

In agreement with previous reports (3–5), the histologic appearance of sections from involved skin of patients with AD depended on whether the biopsy specimen was taken from an acute lesion or a chronic lichenified plaque. In general, acute erythematous lesions demonstrated varying degrees of epidermal hyperplasia with focal intercellular edema (spongiosis) and

Table 1. Source and Clinical Severity of AD Skin Biopsies

AD patient	Acute lesion*	Chronic lesion	Uninvolved skin
1	Leg (2)	Arm (3)	Abdomen
2	Arm (2)	Thigh (3)	Thigh
3	Arm (2)	Arm (2)	—
4	Arm (3)	—	—
5	Thigh (3)	Arm (2)	Thigh
6	—	Arm (3)	—
7	—	Arm (3)	—
8	—	—	Arm
9	—	—	Arm
10	Thigh (3)	—	—
11	Arm (3)	—	—
12	—	Arm (2)	—

\* The skin disease severity for each acute vs chronic skin lesion was graded on a scale from 0–3 in parentheses as described in Methods.

an epidermal infiltrate. Perivascular infiltrates were also observed around the superficial capillary venous and superficial venous plexuses of the papillary and upper reticular dermis. In contrast, chronic lichenified lesions were characterized by acanthosis, with minimal epidermal infiltration.

All biopsies of acute AD skin lesions showed positive hybridization signals for IL-4 and IL-5 mRNA (Fig. 1). In contrast, normal skin had virtually no cells giving hybridizations for IL-4 mRNA or IL-5 mRNA. When acute AD skin lesions were compared with normal control skin, acute AD skin lesions had significantly greater numbers of cells expressing mRNA for IL-4 ( $P < 0.01$ ) and IL-5 ( $P < 0.05$ ). In contrast, only very few cells positive for IFN- $\gamma$  mRNA were detected in either the acute AD or normal control skin biopsies.

In general, the cytokine mRNA-positive cells in acute AD skin lesions were located among the inflammatory infiltrate in the epidermis and at the upper part of the dermis. An example of the strong signals obtained for IL-4 mRNA, as compared to IFN- $\gamma$  mRNA, in the acute AD lesions is shown in Fig. 2. The absence of hybridization signals with the respective sense probes and/or RNase pretreatment provides support for the specificity of the hybridization reaction. Of note, silver grains in the epidermis of Fig. 2 C represent nonspecific background rather than specific binding of the probe and are present in both sense and anti-sense preparations and post-RNase treatment.

Uninvolved AD skin also contained significantly greater numbers of cells expressing mRNA for IL-4 ( $P < 0.05$ ) than found in normal control skin. This is not surprising since increased numbers of perivascular infiltrating T cells (as compared to normal skin) have been reported even in the uninvolved skin of patients with AD (4, 5). However, uninvolved AD skin, as compared with acute lesions, had significantly fewer numbers of cells expressing IL-4 mRNA ( $P < 0.01$ ). Furthermore, no significant hybridization was detected for IL-5 mRNA or IFN- $\gamma$  mRNA in uninvolved skin.

As compared with normal skin or uninvolved AD skin, chronic AD skin lesions were found to have significantly greater numbers of cells expressing mRNA for IL-4 ( $P < 0.01$ ) and IL-5 ( $P < 0.01$ ), but not for IFN- $\gamma$  mRNA expressing cells.

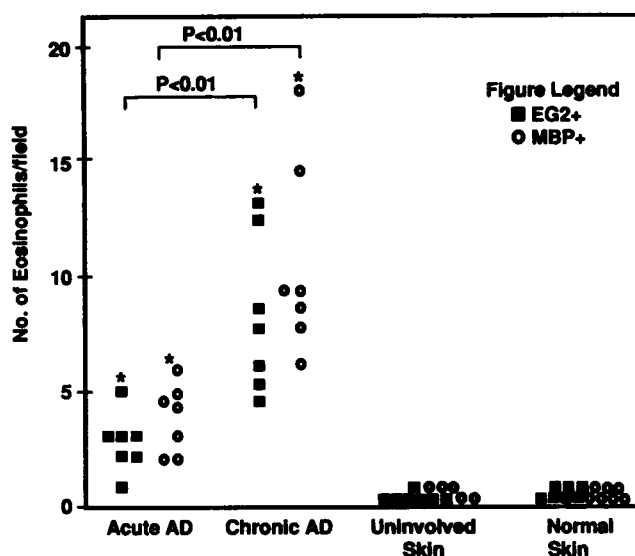
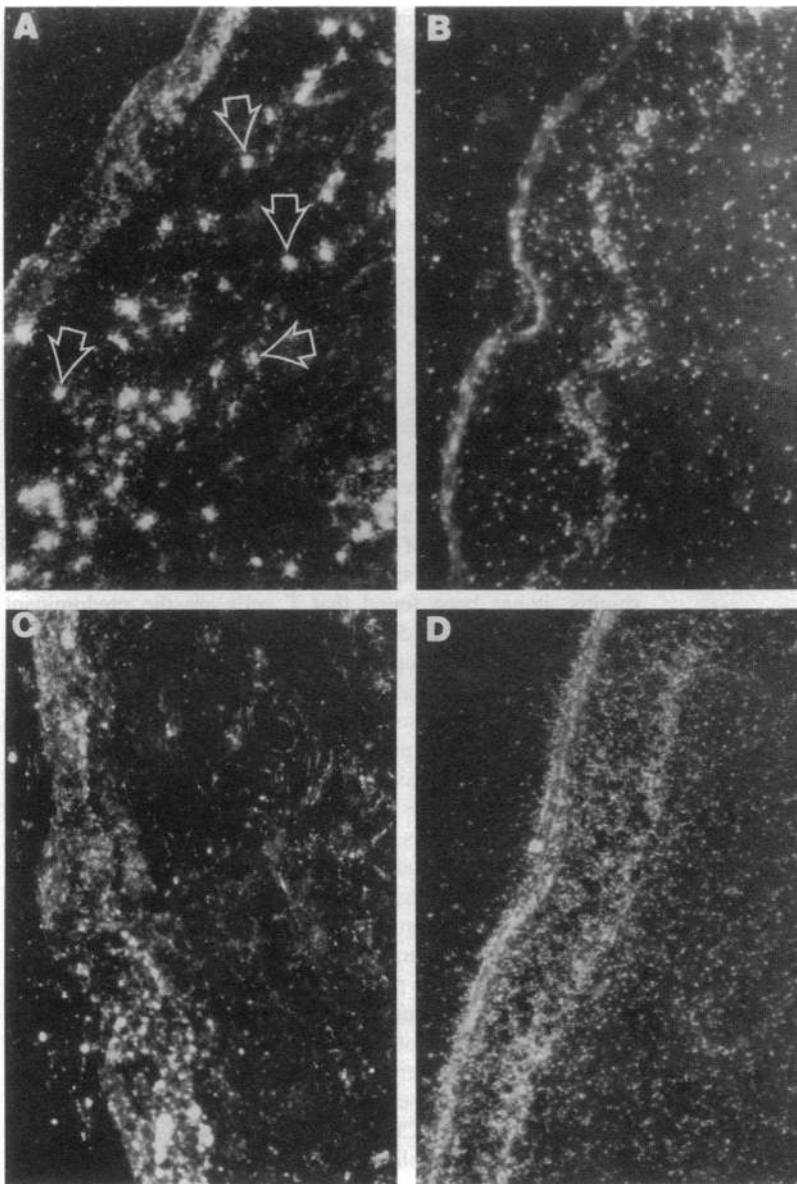


Figure 1. In situ hybridization of AD skin lesions and normal skin, by using riboprobes for IL-4, IL-5, and IFN- $\gamma$ . Comparisons were made between acute and chronic skin lesions by using the Mann-Whitney U test. The standard error represents the variability in the mean count of individual patients. \* $P$  value  $< 0.05$  or \*\* $P$  value  $< 0.01$ , respectively, as compared to the same cytokine mRNA in normal skin.

However, as compared with acute AD skin lesions, chronic AD skin lesions had significantly fewer IL-4 mRNA-expressing cells ( $P < 0.01$ ). In contrast, significantly greater numbers of IL-5 mRNA(+) cells ( $P < 0.01$ ) was found in chronic AD skin lesions as compared to acute AD lesions.

Eosinophil major basic protein has been demonstrated to be deposited in chronic AD skin lesions (6). Furthermore, IL-5 has been found to play a critical role in the differentiation and survival of eosinophils (15). To study the potential functional role of increased IL-5 expression in chronic AD we assessed the numbers of EG2+ cells as a measure of activated eosinophils, and MBP+ cells as a measure of total eosinophils in chronic vs acute AD skin lesions. No EG2+ cells were found in either uninvolved skin or normal control skin biopsies. However, as shown in Fig. 3, chronic AD lesions expressed significantly greater numbers of EG2+ and MBP+ eosinophils than acute lesions ( $P < 0.01$ ). Furthermore, there was no significant difference in the numbers of EG2+ and MBP+ eosinophils in each biopsy. These data suggest that the increase in EG2+ cells seen in chronic AD is the result of enhanced eosinophil recruitment as well as enhanced eosinophil activation.

To determine whether the increased IL-5 expression in chronic AD lesions was derived from T cells or eosinophils, we carried out double immunostaining and in situ hybridization on three acute and three chronic AD lesions. As shown in Table II, in the acute AD lesions, there is a mean of 92% T cells and 2% eosinophils in the IL-5 mRNA expressing cell population. In contrast, in chronic AD lesions, a mean of 86% T cells and 12% eosinophils are present in the IL-5 mRNA expressing population. Thus, T cells are the predominant cell expressing IL-5 in both acute and chronic AD skin lesions. However, there is an increase in IL-5 expressing eosinophils during the transition from acute to chronic AD skin lesions.



**Figure 2.** Darkfield illumination of autoradiographs of skin biopsies from an acute AD skin lesion hybridized with IL-4 cRNA probe (A), IFN- $\gamma$ -cRNA probe (B), IL-4 sense RNA probe (C), and RNase treatment done before application of the IL-4 riboprobe (D).  $\times 300$ .

## Discussion

Previous studies by our group (5), as well as others (27) have established that acute AD skin lesions, and to a lesser extent, uninvolved areas are associated with increased numbers of infiltrating CD3+, CD4+ activated T cells, compared with normal control skin. This is also a feature of antigen-induced, e.g., tuberculin, delayed type hypersensitivity (DTH) skin reactions. Therefore, it has been suggested that acute AD is a specialized form of DTH reaction. However, the observation that keratinocytes in the AD skin lesion do not express HLA-DR suggests that it is not a typical DTH reaction (28). In this regard, keratinocytes in DTH reactions express HLA-DR presumably due to the local production of IFN- $\gamma$  by infiltrating T cells (21).

By using the technique of in situ hybridization, we recently demonstrated that the classical DTH (tuberculin) reaction in human skin is associated with the preferential infiltration of IFN- $\gamma$ -expressing Th1 cells (21). Skin lesions from patients

with chronic psoriasis have also been reported to exhibit infiltration of Th1, but not Th2, cells (29). In contrast, allergen-induced cutaneous late phase reactions (LPR) (20) and asthmatic airways (19) are associated with mRNA expression for the cytokine gene cluster IL-3, IL-4, IL-5, and GM-CSF, i.e., Th2 cell infiltration. Similar studies have not been carried out previously in AD. Although mite-specific Th<sub>2</sub> cells have been cloned from skin lesions of a few patients with AD- and IgE-specific antibody to dust mites (30, 31), these clones are likely to have represented only a small proportion of the T cell infiltrate in the AD lesion. Furthermore, since they were grown in the presence of mite allergen and IL-4, such T cell clones may have been selected by the culture conditions. Of note, these studies also did not define the nature of the skin lesion from which such clones were derived and therefore did not address the possibility that different patterns of cytokine production might accompany acute vs chronic skin lesions.

This study demonstrates that acute and chronic AD skin

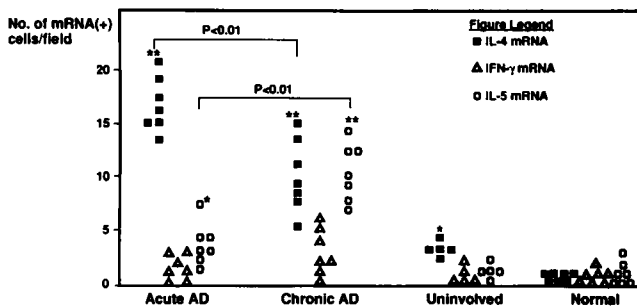


Figure 3. Comparison of the density of EG2+ eosinophils by immunocytochemistry in acute AD lesions, chronic AD lesions, uninvolved AD skin, and normal skin. Results are expressed as positive cells per high power field (0.202 mm<sup>2</sup>). The difference in EG2+ eosinophil numbers between acute and chronic skin lesions are statistically significant ( $P < 0.01$ ). Comparisons were made between acute vs chronic skin lesions by using the Mann Whitney U test. \* $P < 0.01$  as compared with the same eosinophil marker in normal skin.

lesions are associated with increased numbers of cells expressing mRNA for IL-4 and IL-5, but not IFN- $\gamma$ . However, the initiation of acute skin inflammation in AD is associated with a predominance of IL-4 expression. In contrast, the maintenance of chronic inflammation is associated with decreased numbers of IL-4 mRNA (+) cells, increased numbers of IL-5 mRNA (+) cells, and eosinophil infiltration. The mechanism by which IL-4 participates in the acute phase of allergic inflammation remains to be elucidated. In support of a critical role for IL-4 in the induction of skin inflammation in AD, Müller et al. (32) have recently demonstrated that murine Th2 cells are just as effective in inducing skin inflammation as Th1 cells. However, the mediation of skin inflammation by Th2 cells is IL-4, but not IFN- $\gamma$  dependent. One important action of IL-4 which may trigger the influx of inflammatory cells likely involves the induction of VCAM-1, an adhesion molecule involved in the migration of mononuclear cells and eosinophils into the sites of tissue inflammation (14). Indeed, recent studies have demonstrated that vascular endothelial cells in AD lesions do express VCAM-1 (33).

Table II. Cell Source of IL-5 Expression in Atopic Dermatitis Skin Lesions\*

AD skin lesion	Percent IL-5 mRNA (+) cells expressing:	
	CD3 surface antigen	Major basic protein
Acute AD-1	93	3
Acute AD-2	90	2
Acute AD-3	92	0
Chronic AD-1	86	12
Chronic AD-2	88	10
Chronic AD-3	84	13

\* In these experiments, skin biopsies of acute vs chronic AD lesions were subjected to in situ hybridization and double-immunostaining using digoxigenin-labeled IL-5 RNA probes and monoclonal antibodies to CD3 (T cells) and BMK-13 (total eosinophils), respectively. The predominant source of IL-5 expression localized to T cells.

The observation that IL-5 expression rises in chronic AD skin lesions is of interest because IL-5 promotes the differentiation, vascular endothelial adhesion, and survival of eosinophils as well as enhances histamine release from basophils (reviewed in reference 15). In this regard, our current finding of increased numbers of EG2+ cells in chronic AD skin lesions is consistent with previous reports by other investigators that such lesions are associated with increased eosinophil major basic protein (6). The secretion of transforming growth factor  $\beta$  by eosinophils and the deposition of eosinophil-derived cationic proteins may contribute to the dermal fibrosis and chronic mast cell degranulation that contributes to the evolution of lichenified AD plaques (34–37).

Aside from T cells, recent studies indicate that mast cells and eosinophils can also be a source of IL-4 and IL-5 (15, 38). The observation that T cell clones from AD skin lesions produce IL-4 and IL-5, however, are consistent with the concept that infiltrating T cells are a critical source of these cytokines. Furthermore, in studies of bronchoalveolar lavage fluid obtained from asthmatic airways, as well as nasal biopsies from allergic rhinitis, it has been found that T cells are the predominant source of IL-4 and IL-5 (19, 26).

Using double immunostaining and in situ hybridization, this study also indicates that in acute and chronic AD skin lesions, T cells are the major source of IL-5. However, it is of interest that the rise in IL-5 expression during the transition from acute to chronic AD was accompanied by a rise in IL-5 expression in activated eosinophils. These data indicate that IL-5 secretion in chronic AD lesions may support eosinophil survival and differentiation via autocrine and paracrine pathways. Although our data in Fig. 1 suggest an increase in the percentage of cytokine positive inflammatory cells in chronic AD, future studies are needed to confirm this by double staining with CD45.

These observations raise the interesting issue of what immunologic mechanisms may control the local infiltration of Th2 cells into the airways of asthmatics vs the skin of patients with AD. In this regard, recent studies have demonstrated that T cells migrating to the skin express the homing receptor cutaneous lymphocyte antigen (CLA) (39). In contrast, T cells isolated from the bronchoalveolar lavage fluid of asthmatics have only a low level of CLA expression which is no greater than that seen in peripheral blood (40). Thus, the propensity of a given individual to develop AD as opposed to asthma may depend on differences in the tissue migratory behavior of their memory T cells. This concept is supported by the observations that chronic AD skin lesions express E-selectin, the ligand for CLA, whereas asthmatic airways only express minimal levels of E-selectin (41).

Memory/effector T cells preferentially express homing receptors that return them to the same lymphatic beds in which they were first activated (42). CLA is preferentially activated in lymphoid beds that drain the skin (39). Therefore, the immune system remembers not only that it has previously encountered a particular antigen, but also the regional lymph node in which that antigen was encountered and directs lymphocyte homing accordingly. This model would suggest that patients with asthma and AD have in common the genetic predisposition to stimulate Th2 cells and IgE responses to specific allergens. However, allergen sensitization of an individual via their bronchial-associated lymphoid tissue will predispose to asthma, whereas sensitization via the skin-associated lymphoid tissue

system will predispose to AD. Further studies are obviously needed to confirm this hypothesis.

The mechanisms determining the selection of the Th2 phenotype in allergic diseases are of considerable importance. In both mice and humans, the genetic predisposition of the host as well as the nature of the antigen plays a role in the selection of cytokine patterns. It is now also well established that the local cytokine milieu plays a critical role in selecting the subgroup of T cells that predominates in an inflammatory response. IL-4 favors the development of Th2 cells whereas IFN- $\gamma$  favors the development of Th1 cells (16, 43). Thus, the lack of IFN- $\gamma$  production, coupled with the local secretion of IL-4, may contribute to the cytokine pattern observed in the acute AD skin lesion.

In summary, our current data indicate that the initiation of acute AD is associated with the local infiltration of IL-4 and IL-5 expressing Th2 cells. These data may explain the elevated IgE levels and increased numbers of eosinophils associated with this disease. The finding that chronic AD skin lesions are associated with a predominance of IL-5 expression and increased infiltration of eosinophils is a new and somewhat surprising finding. However, previous studies have demonstrated that T cells infiltrating into the AD skin lesion bear the CD45RO memory phenotype, suggesting previous encounter with antigen (44). The studies by Gundel et al. (45), in primates, demonstrating that repeated antigen inhalation results in a prolonged airway eosinophilia and airway hyperresponsiveness is consistent with the possibility that chronic AD lesions that express increased eosinophil infiltration are the result of repeated antigen exposure and IL-5 secretion. Thus, our current study provides a new direction in studying mechanisms that contribute to the pathogenesis of chronic allergic inflammation. Furthermore, our data suggest that future studies into the pathogenesis of AD and development of new strategies in the treatment of this common skin disease should take into account the changing patterns of local cytokine expression in acute vs chronic lesions.

## Acknowledgments

The authors wish to thank Dannette Martin, Noemi Sebastiao, and Anne Trumble for their technical assistance and Maureen Plourd-Sandoval for manuscript preparation.

This work was supported in part by National Institutes of Health grants AR-41256, HL-37260, RR-00051, and HL-36577 and the J. T. Costello Memorial Research Fund.

## References

1. Hanifin, J. M., and G. Rajka. 1980. Diagnostic features of atopic dermatitis. *Acta Dermatol Venereol (Stockh.)* 92:44-47.
2. Leung, D. Y. M., A. R. Rhodes, R. S. Geha, L. Schneider, and J. Ring. 1993. Atopic dermatitis. In *Dermatology in General Medicine*. T. B. Fitzpatrick, A. Z. Elsen, K. Wolff, I. M. Freeberg, and K. F. Austen, editors. McGraw-Hill, New York. pp. 1543-1564.
3. Leung, D. Y. 1992. Immunopathology of atopic dermatitis. *Springer Semin. Immunopathol.* 13:427-440.
4. Mihm, M. C., N. A. Soter, H. F. Dvorak, and K. F. Austen. 1976. The structure of normal skin and the morphology of atopic eczema. *J. Invest. Dermatol.* 67:305-312.
5. Leung, D. Y. M., A. K. Bhan, E. E. Schneeberger, and R. S. Geha. 1983. Characterization of the mononuclear cell infiltrate in atopic dermatitis using monoclonal antibodies. *J. Allergy Clin. Immunol.* 71:47-56.
6. Leiferman, K. M., S. J. Ackerman, H. A. Sampson, H. S. Haugen, P. Y. Venecie, and G. J. Gleich. 1985. Dermal deposition of eosinophil granule major

- basic protein in atopic dermatitis: comparison with onchocerciasis. *N. Engl. J. Med.* 313:282-285.
7. Colver, G. B., J. A. Symons, and G. W. Duff. 1989. Soluble IL-2 receptor in atopic eczema. *Br. Med. J.* 298:1426-1428.
8. Czech, W., J. Krutmann, E. Schopf, and A. Kapp. 1992. Serum eosinophil cationic protein (ECP) is a sensitive measure for disease activity in atopic dermatitis. *Br. J. Dermatol.* 126:351-355.
9. Van Joost, T., M. M. A. Kozel, B. Tank, R. Troost, and E. P. Prens. 1992. Cyclosporin in atopic dermatitis. Modulation in the expression of immunologic markers in lesional skin. *J. Am. Acad. Dermatol.* 27:922-928.
10. Sowden, J. M., J. Berth-Jones, J. S. Ross, R. J. Motley, R. Marks, A. Y. Finlay, M. S. Salek, R. A. C. Graham-Brown, B. R. Allen, and R. D. R. Camp. 1991. Double-blind, controlled, crossover study of cyclosporin in adults with severe refractory atopic dermatitis. *Lancet.* 338:137-140.
11. Mosmann, T. R., H. Cherwinski, M. W. Bond, M. H. Giedlin, and R. Coffman. 1986. Two types of murine helper T cell clones. I. Definition according to profiles of lymphokine activities and secretory proteins. *J. Immunol.* 136:2348-2357.
12. Geha, R. S. 1992. Regulation of IgE synthesis in humans. *J. Allergy Clin. Immunol.* 90:143-150.
13. Saito, H., K. Hatake, A. M. Dvorak, K. M. Leiferman, A. D. Donnenberg, N. Arai, K. Ishizaka, and T. Ishizaka. 1988. Selective differentiation and proliferation of hematopoietic cells induced by recombinant human interleukins. *Proc. Natl. Acad. Sci. USA.* 85:2288-2292.
14. Schleimer, R. P., S. A. Sterbinsky, J. Kaiser, C. A. Bickel, A. Klunk, K. Tomioka, W. Newman, F. W. Luscinskas, M. A. Gimbrone Jr, B. W. McIntyre, and B. S. Bochner. 1992. Interleukin-4 induces adherence of human eosinophils and basophils but not neutrophils to endothelium: association with expression of VCAM-1. *J. Immunol.* 148:1086-1092.
15. Weller, P. F. 1992. Role of eosinophils in allergy. *Curr. Opin. Immunol.* 4:782-787.
16. Gajewski, T., and F. Fitch. 1988. Anti-proliferative effect of IFN- $\gamma$  in immune regulation. I. IFN- $\gamma$  inhibits the proliferation of T<sub>H2</sub> but not T<sub>H1</sub> murine helper T lymphocyte clones. *J. Immunol.* 140:4245-4252.
17. Jujo, K., H. Renz, J. Abe, E. W. Gelfand, and D. Y. M. Leung. 1992. Decreased gamma interferon and increased interleukin-4 production promote IgE synthesis in atopic dermatitis. *J. Allergy Clin. Immunol.* 90:323-330.
18. Renz, H., K. Jujo, K. L. Bradley, J. Domenico, E. W. Gelfand, and D. Y. M. Leung. 1992. Enhanced IL-4 production and IL-4 receptor expression in atopic dermatitis and IL-4 receptor expression in atopic dermatitis and their modulation by interferon-gamma. *J. Invest. Dermatol.* 99:403-408.
19. Robinson, D. S., Q. Hamid, S. Ying, A. Tsicopoulos, J. Barkans, A. M. Bentley, C. Corrigan, S. R. Durham, and A. B. Kay. 1992. Predominant T<sub>H2</sub>-like bronchoalveolar T-lymphocyte population in atopic asthma. *N. Engl. J. Med.* 326:298-304.
20. Kay, A. M., S. Ying, V. Varney, M. Gaga, S. R. Durham, R. Moqbel, A. J. Wardlaw, and Q. Hamid. 1991. Messenger RNA expression of cytokine gene cluster, interleukin 3 (IL-3), IL-5, and granulocyte/macrophage colony-stimulating factor, in allergen-induced late-phase cutaneous reactions in atopic subjects. *J. Exp. Med.* 173:775-778.
21. Tsicopoulos, A., Q. Hamid, V. Varney, S. Ying, R. Moqbel, S. R. Durham, and A. B. Kay. 1992. Preferential messenger RNA expression of Th1-type cells (IFN- $\gamma$ +, IL-2+) in classical delayed-type (tuberculin) hypersensitivity reactions in human skin. *J. Immunol.* 148:2058-2061.
22. Hamid, Q., J. Wharton, G. Terenghi, C. Hassal, J. Aimi, K. Taylor, H. Nakazato, J. Dixon, G. Burnstock, and J. M. Poak. 1987. Localization of natriuretic peptic mRNA and immunoreactivity in rat heart and human arterial appendage. *Proc. Natl. Acad. Sci. USA.* 84:6760-6764.
23. Brady, M. A., and M. Finlan. 1990. Radioactive labels: autoradiography and choice of emulsions. In *In Situ Hybridization: Principles and Practice*. J. M. Polak and J. McGee, editors. Oxford University Press, Oxford, pp. 31-59.
24. Tai, P.-C., C. J. F. Spry, C. Peterson, P. Venge, and I. Olssen. 1984. Monoclonal antibodies distinguish storage and secreted forms of eosinophil cationic protein. *Nature (Lond.)* 309:182-184.
25. Moqbel, R., J. Barkans, B. Bradley, S. Durham, and A. B. Kay. 1993. Application of monoclonal antibodies against major basic protein (BMK-13) for quantifying eosinophils in bronchial biopsies from atopic asthma. *Clin. Exp. Allergy.* 22:265-273.
26. Ying, S., S. R. Durham, J. Barkans, K. Masuyama, M. Jacobson, S. O. Rak, R. Lowhagen, R. Moqbel, A. B. Kay, and Q. A. Hamid. 1993. T cells are the principal source of IL-5 mRNA in allergen-induced rhinitis. *Am. J. Respir. Cell Mol. Biol.* 9:356-360.
27. Willemze, R., C. B. de Graff-Reitsma, J. Cnossen, W. A. van Vloten, and C. V. L. M. Meijer. 1983. Characterization of T cell subpopulations in skin and peripheral blood of patients with cutaneous T cell lymphomas and benign inflammatory dermatoses. *J. Invest. Dermatol.* 80:60-66.
28. Barker, J. N. S. N., and D. M. MacDonald. 1987. Epidermal class II

- human lymphocyte antigen expression in atopic dermatitis: A comparison with experimental allergic contact dermatitis. *J. Am. Acad. Dermatol.* 16:1175-1179.
29. Schlaak, J. F., M. Buslau, W. Jochum, E. Hermann, M. Girndt, H. Gallati, J.-H. Meyer zum Buschenfelde, and B. Fleischer. 1994. T cells involved in psoriasis vulgaris belong to the Th1 subset. *J. Invest. Dermatol.* 102:145-149.
30. Van der Heijden, F., E. A. Wierenga, J. D. Bos, and J. L. Kapsenberg. 1991. High frequency of IL-4 producing CD4<sup>+</sup> allergen-specific T lymphocytes in atopic dermatitis lesional skin. *J. Invest. Dermatol.* 97:389-394.
31. Van Reijssen, F. C., C. A. Bruijnzeel-Koomen, F. S. Kalthoff, E. Maggi, S. Romagnani, J. K. Westland, and G. C. Mudde. 1992. Skin-derived aeroallergen-specific T-cell clones of the Th<sub>2</sub> phenotype in patients with atopic dermatitis. *J. Allergy Clin. Immunol.* 90:184-193.
32. Müller, K. M., F. Jaunin, I. Masouye, J.-H. Saurat, and C. Hauser. 1993. Th2 cells mediate IL-4 dependent local tissue inflammation. *J. Immunol.* 150:5576-5584.
33. Groves, R. W., M. H. Allen, D. O. Haskard, and D. M. MacDonald. 1991. Endothelial leukocyte adhesion molecule-1 in acute and chronic eczema. In *Immunological and Pharmacological Aspects of Atopic and Contact Eczema*. J. M. Czernielewski, editor. Karger, Basel. 85-88.
34. Leiferman, K. M. 1989. Eosinophils in atopic dermatitis. *Allergy (CPH)*. 44:20-26.
35. Raghov, R., P. Irish, and A. H. Kang. 1989. Coordinate regulation of transforming growth factor  $\beta$  gene expression and cell proliferation in hamster lungs undergoing bleomycin-induced pulmonary fibrosis. *J. Clin. Invest.* 84:1836-1842.
36. Wong, D. T. W., A. Elovic, K. Matossian, N. Nagura, M. Y. Chou, J. R. Gordon, T. H. Rand, S. J. Galli, and P. J. Weller. 1991. Eosinophils from patients with blood eosinophilia express transforming growth factor- $\beta$ <sub>1</sub>. *Blood*. 78:2702-2707.
37. Shah, M., D. M. Foreman, and M. W. J. Ferguson. 1992. Control of scarring in adult wounds by neutralising antibody to transforming growth factor  $\beta$ . *Lancet*. 339:213-214.
38. Plaut, M., J. H. Pierce, C. J. Watson, J. Hanley-Hyde, R. P. Nordan, and W. E. Paul. 1989. Mast cell lines produce lymphokines in response to cross-linkage of Fc $\epsilon$ RI to calcium ionophores. *Nature (Lond.)*. 229:64-67.
39. Berg, E. L., T. Yoshin, L. S. Rott, M. K. Robinson, R. A. Warnock, T. K. Kishimoto, L. J. Picker, and E. C. Butcher. 1991. The cutaneous lymphocyte antigen is a skin lymphocyte homing receptor for the vascular lectin endothelial cell-leukocyte adhesion molecule 1. *J. Exp. Med.* 174:1461-1466.
40. Picker, L. J., R. J. Martin, A. E. Trumble, L. Newman, P. A. Collins, P. R. Bergstresser, and D. Y. M. Leung. 1994. Control of lymphocyte recirculation in man: Differential expression of homing-associated adhesion molecules by memory/effector T cells in pulmonary vs cutaneous effector sites. *Eur. J. Immunol.* (In press).
41. Montefort, S., W. R. Roche, P. H. Howart, R. Djukanovic, C. Gratziau, M. Carroll, L. Smith, K. M. Britten, D. Haskard, T. H. Lee, and S. T. Holgate. 1992. Intercellular adhesion molecule-1 (ICAM-1) and endothelial leucocyte adhesion molecule-1 (ELAM-1) expression in the bronchial mucosa of normal and asthmatic subjects. *Eur. Respir. J.* 5:815-823.
42. Picker, L. J., and E. C. Butcher. 1992. Physiological and molecular mechanisms of lymphocyte homing. *Annu. Rev. Immunol.* 10:561-591.
43. Swain, S. L., A. D. Weinberg, M. English, and G. Huston. 1990. IL-4 directs the development of Th2-like helper effectors. *J. Immunol.* 144:4110-4120.
44. Bos, J. D., C. Hagenaars, P. K. Das, S. R. Kreis, W. J. Boorn, and M. L. Kapsenberg. 1989. Predominance of memory T cells (CD4<sup>+</sup>, CDw29<sup>+</sup>) over naive T cells (CD45<sup>+</sup>, CD45R<sup>+</sup>) in both normal and diseased human skin. *Arch. Dermatol. Res.* 281:24-30.
45. Gundel, R. H., E. Gerritsen, G. J. Gleich, and C. D. Wegner. 1990. Repeated antigen inhalation results in a prolonged airway eosinophilia and airway hyperresponsiveness in primates. *J. Appl. Physiol.* 68:779-786.