

24. B. Morales, S. Y. Choi, A. Kirkwood, *J. Neurosci.* **22**, 8084 (2002).
 25. G. D. Mower, *Brain Res. Dev. Brain Res.* **58**, 151 (1991).
 26. T. K. Hensch et al., *Science* **282**, 1504 (1998).
 27. Z. J. Huang et al., *Cell* **98**, 739 (1999).
 28. N. Mataga, Y. Mizuguchi, T. K. Hensch, *Neuron* **44**, 1031 (2004).
 29. E. J. Bradbury et al., *Nature* **416**, 636 (2002).
 30. T. Pizzorusso et al., *Science* **298**, 1248 (2002).
 31. M. Fagiolini, T. K. Hensch, *Nature* **404**, 183 (2000).
 32. M. Fagiolini et al., *Science* **303**, 1681 (2004).
 33. S. Taha, J. L. Hanover, A. J. Silva, M. P. Stryker, *Neuron* **36**, 483 (2002).
 34. M. Simonen et al., *Neuron* **38**, 201 (2003).
 35. B. Zheng et al., *Neuron* **38**, 213 (2003).
 36. J. DeFelipe, E. G. Jones, *J. Neurosci.* **5**, 3246 (1985).
 37. P. Somogyi, I. Soltesz, *Neuroscience* **19**, 1051 (1986).
 38. A. Rebsam, I. Seif, P. Gaspar, *J. Neurosci.* **25**, 706 (2005).
 39. We thank N. Tian for providing dark-reared mice. This work was supported by grants from NIH to S.M.S. and A.W.M. and from the McKnight Founda-

tion to S.M.S. S.M.S. is a member of the Kavli Institute of Neuroscience at Yale.

Supporting Online Material
www.sciencemag.org/cgi/content/full/309/5744/2222/DC1
 Materials and Methods
 Figs. S1 to S3
 References

3 May 2005; accepted 26 August 2005
 10.1126/science.1114362

Direct Evidence for a Parietal-Frontal Pathway Subservicing Spatial Awareness in Humans

Michel Thiebaut de Schotten,¹ Marika Urbanski,¹ Hugues Duffau,²
 Emmanuelle Volle,^{1,3} Richard Lévy,^{1,4} Bruno Dubois,^{1,4}
 Paolo Bartolomeo^{1,4*}

Intraoperative electrical stimulation, which temporarily inactivates restricted regions during brain surgery, can map cognitive functions in humans with spatiotemporal resolution unmatched by other methods. Using this technique, we found that stimulation of the right inferior parietal lobule or the caudal superior temporal gyrus, but not of its rostral portion, determined rightward deviations on line bisection. However, the strongest shifts occurred with subcortical stimulation. Fiber tracking identified the stimulated site as a section of the superior occipitofrontal fasciculus, a poorly known parietal-frontal pathway. These findings suggest that parietal-frontal communication is necessary for the symmetrical processing of the visual scene.

Left unilateral neglect is a neurological condition resulting from right hemisphere damage (1, 2). Neglect patients ignore left-sided events in everyday life (3) and have a poor functional outcome. They typically bisect horizontal lines to the right of the true center (2, 4), perhaps because they perceive the left half of the line as being shorter or less salient than the right half (5, 6). The study of unilateral neglect is important if we are to understand the mechanisms of spatial cognition, but its anatomical correlates are controversial. Most studies implicate the inferior parietal lobule (IPL) (7, 8), consistent with the known role of posterior parietal cortex in spatial attention (9, 10) and perceptual salience (11). Others implicate the rostral superior temporal gyrus (rSTG) (12), suggesting a segregation of spatial awareness in the ventral cortical visual stream (13, 14). The underlying subcortical association circuits have received less attention (15).

We used intraoperative direct electrical stimulation (16) to study line bisection performance. During brain surgery for tumor resection, it is common clinical practice to awaken patients in order to assess the functional role of

restricted brain regions (the brain has no receptors for pain), so that the surgeon can maximize the extent of the exeresis without provoking cognitive impairment. Patients perform cognitive tasks, such as counting or figure naming, while the surgeon temporarily inactivates restricted regions (~5 mm) around the tumor by means of electrical stimuli (16). If the patient stops talking or produces incorrect responses, the surgeon avoids removing the stimulated region.

CAL, a 27-year-old woman, and SB, a 28-year-old man, both left-handed, underwent surgical resection of a low-grade glioma (WHO II). In CAL, the glioma was centered on the caudal part of the right temporal lobe (17). CAL showed a rightward deviation upon stimulation of two cortical sites: the supramarginal gyrus (SMG, the rostral subdivision of the IPL) and the caudal portion of the superior temporal gyrus (cSTG) (Fig. 1) (table S2). There was no deviation during stimulation of the rSTG or of the frontal eye field.

In SB, the glioma was centered on the right inferior parietal lobule (17). SB showed a rightward deviation remarkably identical in amplitude to that shown by CAL (Fig. 2) (table S2) upon stimulation of the SMG. SB also deviated rightward during cSTG stimulation, again consistent with CAL's performance. Stimulation of other neighboring areas ("control 1" in Fig. 2B) did not determine pathological shifts. During tumor resection, subcortical regions on the floor of the surgical cavity were stimulated.

SB showed a large rightward deviation upon stimulation of the restricted region labeled as 42 in Fig. 2A, but not of neighboring cortical or subcortical areas ("control 2" in Fig. 2B). Stimulation of region 42 was repeated after additional excavation of the surgical cavity, causing even greater deviations ("O-FF 2" in Fig. 2B). Again, stimulation of neighboring subcortical sites had no effect on line bisection performance. Still further extension of the resection into the depth of the angular gyrus caused SB to deviate rightward even during stimulation of neighboring regions, or in the absence of any stimulation ("control 3" in Fig. 2B). As a consequence, the neurosurgeon decided to stop the exeresis at this level. Five days after surgery, SB accurately bisected 20-cm lines ("day +5" in Fig. 2B) and showed no signs of neglect (table S1).

Using diffusion tensor magnetic resonance tractography (18) on postoperative magnetic resonance imaging (MRI) scans and diffusion tensor imaging (DTI) scans, we were able to precisely map the course of long association fibers in the white matter of this patient (19). The region labeled as 42 in Fig. 2A, whose inactivation had produced the maximal rightward shifts on line bisection, corresponded exactly to a portion of the superior occipitofrontal fasciculus (18, 20) that connects the parietal to the frontal lobe (21) (Fig. 2, C and D) (figs. S1 and S2). The stimulated region was both distinct and remote from other corticocortical pathways, such as the optic radiations or the parietal-temporal connections.

Our findings demonstrate that the SMG, the cSTG, and a poorly known parietal-frontal pathway, the superior occipitofrontal fasciculus (18, 20), but not the rSTG, are critical to the symmetrical processing of the visual scene in humans (22). These results provide evidence relevant to the debate about the lesional correlates of neglect, based until now on the relatively imprecise lesion-overlapping method in stroke patients, and support the proposal that damage to the temporal-parietal junction (7, 8, 23) and the underlying white matter (15) is a crucial antecedent of left neglect. As a consequence, there is no need to postulate a segregation of spatial awareness, specific to humans, in the rostral part of the right STG (14).

We observed the maximal deviation upon inactivation of the superior occipitofrontal fasciculus in the depth of the IPL. This result specifies the precise anatomical locus of the parietal-frontal pathway in which neglect

¹INSERM Unit 610, ²Department of Neurosurgery, ³Department of Neuroimaging, ⁴Department of Neurology, Assistance Publique-Hôpitaux de Paris, Hôpital de la Salpêtrière, 75013 Paris, France.

*To whom correspondence should be addressed.
 E-mail: paolo.bartolomeo@chups.jussieu.fr

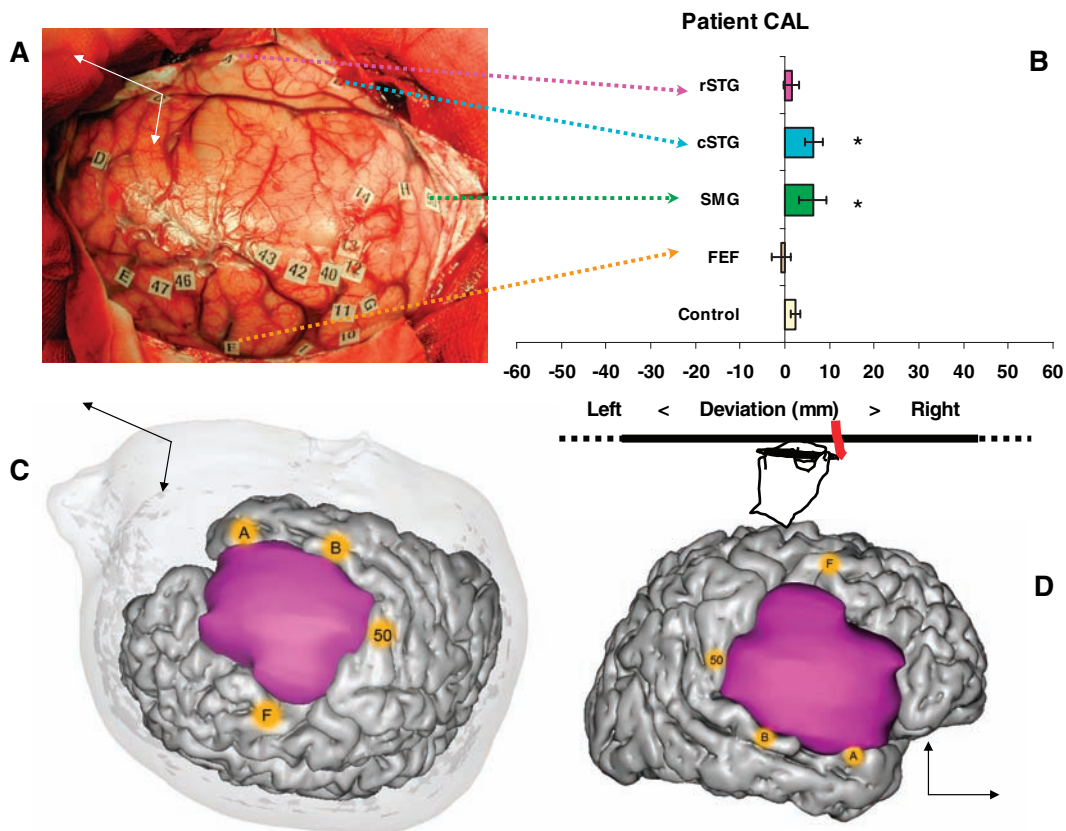


Fig. 1. Performance of patient CAL. (A) The surgical field. (B) Mean deviation (in millimeters) with 95% confidence intervals during stimulation of the rostral part of the superior temporal gyrus (rSTG, label A; $n = 4$), of the caudal part of the STG (cSTG, label B; $n = 2$), of the supramarginal gyrus (SMG, label 50; $n = 4$), of the frontal eye field (FEF, label F; $n = 5$), and of control neighboring regions (superior frontal gyrus, medial frontal gyrus, precentral gyrus, postcentral gyrus, and tumor, $n = 16$). * $P < 0.05$ (two-tailed) as compared to controls' performance (32). (C) Three-dimensional reconstruction of the tumor mass (in purple) and of the stimulated regions (in yellow). (D) Lateral view.

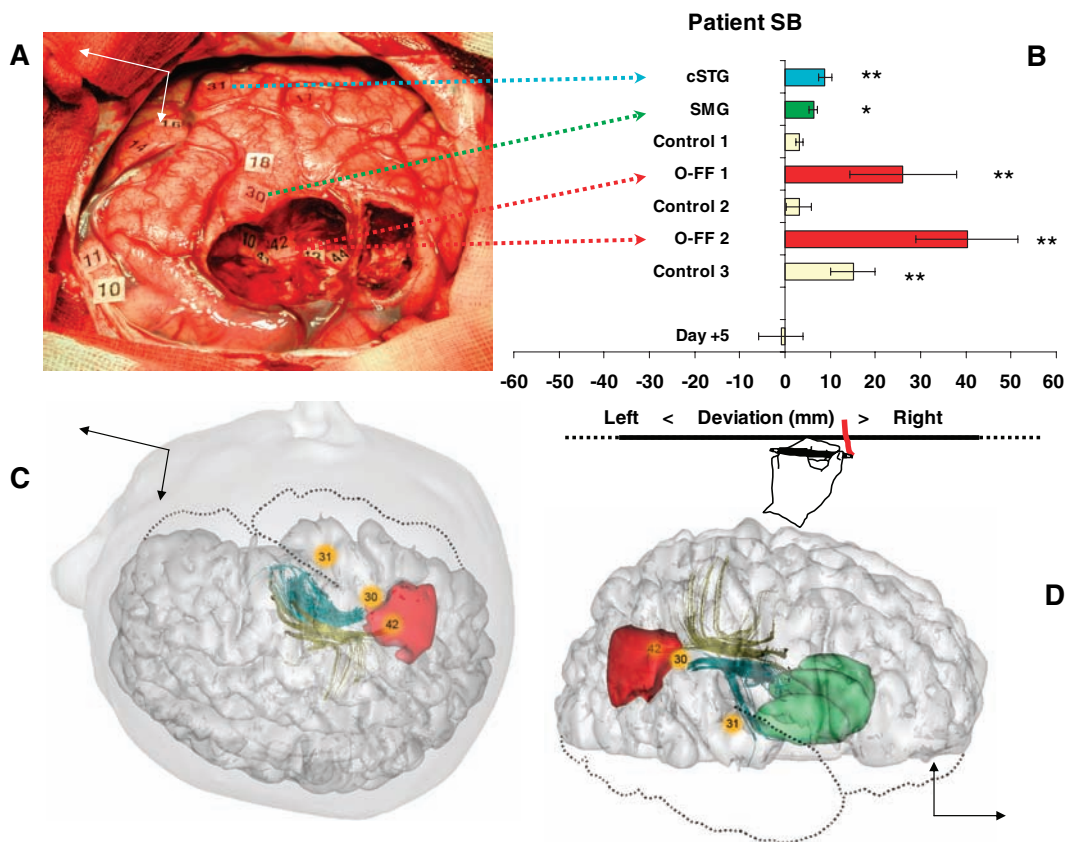


Fig. 2. Performance of patient SB. (A) The surgical field. (B) Mean deviation (in millimeters) with 95% confidence intervals during stimulation of the caudal part of the STG (cSTG, label 31; $n = 6$), of the supramarginal gyrus (SMG, label 30; $n = 4$), of the superior occipitofrontal fasciculus (label 42) during (O-FF 1; $n = 4$) and after tumor resection (O-FF 2, $n = 4$), and of control neighboring regions (postcentral gyrus, lateral occipital gyri, and tumor) before resection (control 1, $n = 27$), during resection (control 2, $n = 38$), and after resection (control 3, $n = 12$). Performance 5 days after surgery is also shown (day +5). * $P < 0.05$, ** $P < 0.01$ (both two-tailed) as compared to controls' performance (32). (C) Three-dimensional reconstruction of the surgical resection (in red) and of the stimulated regions (in yellow), showing their relationships with the superior occipitofrontal fasciculus (in yellow) and the superior longitudinal fasciculus (in blue) (18). The head of the caudate nucleus and the putamen are shown in green. (D) Lateral view.

patients' lesions overlap (15). Our findings are similar to those obtained in nonhuman primates. Monkeys showed persistent signs of neglect after unilateral section of the white matter between the fundus of the intraparietal sulcus and the lateral ventricle (24). The greater effect of subcortical inactivation, as compared to cortical inactivation, is consistent with the idea that symmetrical space processing requires the integrity of a parietal-frontal network (1, 15). Damage to restricted regions of the white matter can cause the dysfunction of large-scale neurocognitive networks. According to an influential model (1), signs of left neglect result from impairment of a right-hemisphere network, including prefrontal, parietal, and cingulate components. The parietal component of the network could be especially important for the perceptual salience of extrapersonal objects, whereas the frontal component might be implicated in the production of an appropriate response to behaviorally relevant stimuli (1), in the online retention of spatial information (1, 25), or in the focusing of attention on salient items through reciprocal connections to more posterior regions (20).

Models of line bisection postulate a competition between the relative salience of the two lateral segments (6). The bisection mark is drawn at the point of subjective equality between the two segments (5). Bisection-related tasks activate the IPL in humans (26). Transcranial magnetic stimulation over the right posterior parietal cortex, but not over the STG, was found to bias the comparison of the lengths of the component segments of pretransected lines in a direction coherent with rightward shifts in line bisection (27). In the monkey, regions adjacent to the intraparietal sulcus, such as the lateral intraparietal area, are related to visual perceptual salience (11) and can reinforce the stimulus attentional priority (10). Parietal inactivation may thus bias the perceptual decision by modulating the salience of the line segments (6).

The assessment of spatial cognition during intraoperative stimulation offers the double opportunity of preserving spatial processing functions during brain surgery and of pinpointing the neurocognitive systems devoted to spatial processing in humans. Spatial awareness is dependent not only on the cortical areas of the temporal-parietal junction, but also on a larger parietal-frontal network communicating via the superior occipitofrontal fasciculus.

References and Notes

1. M. M. Mesulam, *Philos. Trans. R. Soc. London Ser. B* **354**, 1325 (1999).
2. P. Azouvi et al., *J. Neurol. Neurosurg. Psychiatry* **73**, 160 (2002).
3. P. Bartolomeo, S. Chokron, *Neurosci. Biobehav. Rev.* **26**, 217 (2002).
4. T. Schenkenberg, D. C. Bradford, E. T. Ajax, *Neurology* **30**, 509 (1980).
5. J. C. Marshall, P. W. Halligan, *Cognit. Neuropsychol.* **7**, 107 (1990).
6. B. Anderson, *Brain* **119**, 841 (1996).
7. G. Vallar, *Neuroimage* **14**, S52 (2001).
8. D. J. Mort et al., *Brain* **126**, 1986 (2003).

9. M. Corbetta, G. L. Shulman, *Nat. Rev. Neurosci.* **3**, 201 (2002).
10. J. W. Bisley, M. E. Goldberg, *Science* **299**, 81 (2003).
11. J. P. Gottlieb, M. Kusunoki, M. E. Goldberg, *Nature* **391**, 481 (1998).
12. H. O. Karnath, M. Fruhmann Berger, W. Kuker, C. Rorden, *Cereb. Cortex* **14**, 1164 (2004).
13. A. D. Milner, M. A. Goodale, *The Visual Brain in Action* (Oxford Univ. Press, Oxford, 1995).
14. H. O. Karnath, *Nat. Rev. Neurosci.* **2**, 568 (2001).
15. F. Doricchi, F. Tomaiuolo, *Neuroreport* **14**, 2239 (2003).
16. H. Duffau et al., *Brain* **128**, 797 (2005).
17. CAL and SB attended clinical observation because of epileptic seizures. They showed no abnormality on preoperative neurological and neuropsychological examination, consistent with the slowly infiltrative character of low-grade gliomas, whose clinical presentation rarely includes signs of focal brain disease other than epilepsy. In particular, there were no signs of neglect on paper-and-pencil tests (table S1). Intraoperative electrical stimulation was well tolerated, and the patients reported no abnormal visual sensations. They bisected horizontal lines with their left, dominant hand during brain surgery (28). Eight healthy left-handed subjects (mean age, 31 years; SD, 5.3; range, 26 to 38) served as controls. They performed 30 line bisections each, with the same test material and in a body position similar to that of the patients. Our patients' baseline performance was well within the range of the controls' performance (mean \pm SD, 0.28 ± 2.39 mm) as well as that of 10 strongly left-handed normal individuals tested in another study (29) (mean \pm SD, -1.50 ± 3.66 mm). In an unselected population of 204 patients with right brain damage (2), 5 of the 10 patients with the strongest left-handedness deviated rightward on 20-cm lines as compared to controls (29), a frequency of impairment similar to that showed by right-handed patients (2).
18. M. Catani, R. J. Howard, S. Pajevic, D. K. Jones, *Neuroimage* **17**, 77 (2002).
19. The neurosurgeon stopped the resection after stimulation of the region labeled as 42 (Fig. 2A). As a consequence, region 42 corresponded to the deepest point on the floor of the rostral-superior part of the surgical cavity, and was thus easily identified on postoperative anatomical MRI scans. The white matter tract underlying region 42 was identified by overlapping the MRI scans with the DTI scans (fig. S1) (Fig. 2, C and D).
20. M. Petrides, D. N. Pandya, in *Principles of Frontal Lobe Function*, D. T. Stuss, R. T. Knight, Eds. (Oxford Univ. Press, Oxford, 2002), pp. 31–50.
21. The superior occipitofrontal fasciculus is a poorly known long association pathway. It terminates

rostrally in the lateral prefrontal cortex of the inferior and middle frontal gyri (18). Its caudal terminations are less known (18, 30), but despite its name, derived from early descriptions (31), the superior occipitofrontal fasciculus seems to terminate caudally in the superior parietal gyrus (18) and in the intraparietal sulcus [(30), p. 367].

22. We used line bisection because it is an easy task for patients to perform and allows repeated assessments in the time scale required by intraoperative testing. Bisection of centrally presented 20-cm lines correlates positively and significantly with cancellation tests and is a good predictor of clinical neglect as assessed by standardized scales (2, 28).
23. C. Rorden, M. Fruhmann Berger, H.-O. Karnath, *Cognit. Brain Res.*, published online 19 February 2005 (10.1016/j.cogbrainres.2004.10.022).
24. D. Gaffan, J. Hornak, *Brain* **120**, 1647 (1997).
25. M. Husain, C. Rorden, *Nat. Rev. Neurosci.* **4**, 26 (2003).
26. G. R. Fink, J. C. Marshall, P. H. Weiss, I. Toni, K. Zilles, *Neuropsychologia* **40**, 1119 (2002).
27. A. Ellison, I. Schindler, L. L. Pattison, A. D. Milner, *Brain* **127**, 2307 (2004).
28. See supporting data on Science Online.
29. M. Rousseaux et al., *Rev. Neurol. (Paris)* **157**, 1385 (2001).
30. R. Nieuwenhuys, J. Voogd, C. van Huijzen, *The Human Central Nervous System: A Synopsis and Atlas* (Springer-Verlag, New York, 1988).
31. M. J. Déjerine, *Anatomie des Centres Nerveux* (Rueff, Paris, 1895).
32. J. R. Crawford, P. H. Garthwaite, *Neuropsychologia* **40**, 1196 (2002).
33. We thank the patients for their cooperation; P. Gatignol for help with intraoperative testing; J. Chiras and the Department of Neuroradiology of the Salpêtrière Hospital for MRI acquisitions; S. Kinkingnehun, C. Delmaire, J. B. Pochon, L. Thivard, and the staff of BrainVISA software for technical support for image analysis; and P. Azouvi and the members of the Groupe d'Etude sur la Rééducation et l'Evaluation de la Négligence (GEREN) for permission to use data from GEREN studies (2, 29).

Supporting Online Material

www.sciencemag.org/cgi/content/full/309/5744/2226/DC1
 Materials and Methods
 SOM Text
 Tables S1 and S2
 Figs. S1 and S2
 References

17 June 2005; accepted 26 August 2005
 10.1126/science.1116251

Breakdown of Cortical Effective Connectivity During Sleep

Marcello Massimini,^{1,2} Fabio Ferrarelli,¹ Reto Huber,¹ Steve K. Esser,¹ Harpreet Singh,¹ Giulio Tononi^{1*}

When we fall asleep, consciousness fades yet the brain remains active. Why is this so? To investigate whether changes in cortical information transmission play a role, we used transcranial magnetic stimulation together with high-density electroencephalography and asked how the activation of one cortical area (the premotor area) is transmitted to the rest of the brain. During quiet wakefulness, an initial response (~15 milliseconds) at the stimulation site was followed by a sequence of waves that moved to connected cortical areas several centimeters away. During non-rapid eye movement sleep, the initial response was stronger but was rapidly extinguished and did not propagate beyond the stimulation site. Thus, the fading of consciousness during certain stages of sleep may be related to a breakdown in cortical effective connectivity.

When awakened early in the night from non-rapid eye movement (NREM) sleep, people often report little or no conscious experience

(1). It was first thought that this fading of consciousness was due to the brain shutting down. However, although brain metabolism is re-