

Direct Lymphography of the Breast

K. Kett, G. Varga, L. Lukács

1st Surgical Clinic and Roentgenological Clinic of the Medical University, Pécs

Lymphology 1 (1970), 3—12

The surgical treatment of breast cancer has been developed on the basis of the topographic anatomy of lymphatic vessels and regional lymph nodes. The axillary and infraclavicular lymph nodes of the breast as well as their afferent lymphatic vessels and the pectoral muscles are removed in continuity. Provided that the lymphatic anatomy of the patient is normal, the operation seems to be radical indeed: yet recurrences and late metastases are often observed (8).

In the diagnosis of regional lymph nodes palpation has remained the most common method of examination. However, axillary palpation is not suitable for the demonstration of the collateral lymphatic system developing as a result of blocked main lymphatic channels by tumour deposits. Examination of the axillary lymph nodes by palpation gives according to data in the literature (6, 9, 10) an incorrect diagnosis in about 30 per cent of cases. More accurate methods of examination with regard to diagnosis, prognosis, and therapy are needed to be chosen. With more accurate examinations patients who seem operable according to the classical methods of investigation, but who already have metastases outside the field of operation, can be selected. In order to come closer to the "correct diagnosis" we used direct lymphography of the breast in a group of patients with breast cancer. In recent related literature two authors had reported of similar investigations. *Lewis* (7) performed successful lymphangiadenography at two patients with benign tumour of the breast, while *Halsell* (5) studied the anatomy of mammary lymphatics by the method of lymphangiography, also in 7 benign cases.

Material

Direct lymphography of the breast was performed in 88 patients, of whom 56 had malignant and 32 had benign tumour, at 27 of our cases injection of the contrastmedium because of tumoural obstruction was not successful. In order to obtain some data about the lymphatic drainage of the last patients' breast too, our intervention was only confined to an investigation by Patent blue dye.

It seems but essential that such striking signs allow us to judge the extent and character of the alterations of the lymphatic drainage, in any case, i.e. malignancy can't be overlooked in actual practice.

Table summing-up efficiency of direct lymphography in the preoperative diagnosis of breast cancer metastases.

Number of cases	Affected lymph nodes	Verified by histological examination
10	normal filling	all nodes normal
2	a discreet filling defect in the Sorgius lymph node	2 × 1 nodes
7	Sorgius lymph node + some pectoral lymph nodes affected	all 7 cases had some positive nodes
10	Sorgius 10 pectoral glands 8 central group 4 interpect. nodes infraclav. nodes cases	All 10 cases**
27	no filling in the lymph nodes; indirect signs indicating an advanced lymphatic obstruction	All 27 cases**

** All metastatic lymph nodes are to be revealed if metastatic deposits are quite initial and do not result in secondary changes of the lymphatic drainage. In these cases the number of metastatic lymph nodes seen by lymphography and identified by histological examination has been the same. But when metastatic proceedings spread further to higher lymph node groups, or even the lymph flow is blocked by tumour cell deposits, it is impossible to see or count all lymph nodes.

Methods

0,2 ml of a mixture containing equal parts of 11 per cent "Patent blue violet" dye and of 1 per cent procaine will be injected intradermally into the region of the mammary areola (4). A few minutes following the injection of the dye blue streaks appear on the skin along the courses of the lymphatic vessels (5). An incision is made over one of the clearly visible lymphatic vessels, which is exposed. If no discolouration of the skin results, the incision has to be made at a venture. The collecting lymphatics running above the axilla are found under the superficial fascia hardly covered with any subcutaneous adipose tissue. After the removal of the adipose and the connective tissue, the vulnerable wall of the rather thin lymphatic vessel appears. This is followed by cannulation, which is rendered considerably difficult by the respiratory movements of the patient. A 20 gauge needle is inserted into the vessel and secured in place by a ligature. The needle is fixed to the skin by means of adhesive tape (Fig. 1). Thereafter, 2 ml of "Lipiodol Ultra Fluide" is injected with the aid of an injection-pump. The length needed for the injection amounts 25 to 35 minutes.

Then a roentgenogram is taken. During the roentgenography the patient is turned by 20 degrees to the left and then to the right in order to separate the hard shadow of the costal plica from that of the lymph nodes filled with contrast medium. Roentgenograms

are taken again after 24 hours as well as following the operation. The operative specimen is placed under a roentgen screen and the excised lymph nodes are identified with those seen on the lymphogram. The individual nodes are marked with metal clips, which is followed by histological examination of the whole material.

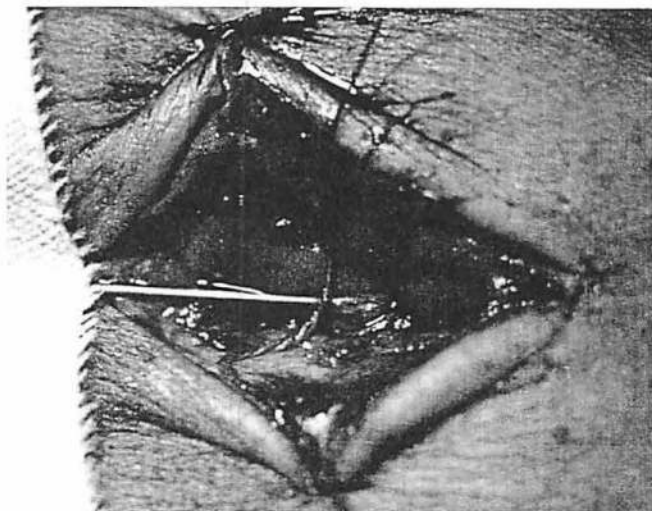


Fig. 1 Exposed and cannulated lymphatic in the outer-upper quadrant of the left breast.

Results

From the site of injection of the contrast medium to the node first visualised, generally the filling of only one lymphatic vessel can be observed. At the height of the fourth rib the vessel leads into an isolated lymph node which, owing to its position can be easily examined (fig. 2 a, 2 b). From this point the contrast medium passing through several lymph nodes and filling many lymphatic vessels, arrives at the collecting system around the axillary vein. Four types of lymphatic drainage to different lymph nodes were observed in benign cases.

1. By 16 examinations a direct connection was seen from the lymph nodes situated at the edge of the major pectoral muscle towards the axillary nodes, namely the collecting system around the axillary vein, further up to the central group and to the lymph nodes of the infraclavicular region.

2. At 15 patients lymphatic vessels became distinct from the pectoral nodes towards ipsilateral axilla. On the roentgenograms infraclavicular nodes were also visible, receiving afferent branches but only from the axillary region.

3. At one case the pectoral group showed an immediate connection with axillary and infraclavicular lymph nodes, besides supraclavicular nodes also appeared filling from the central group.

4. A single roentgenogram demonstrated two lymph nodes along the edge of the major pectoral muscle, from which an efferent branch started towards the infraclavicular region. The number of lymph nodes filled in the average examination was usually about fifteen, differences from the average were only rarely encountered. Three of the distinct nodes were the fewest and 39 the most.

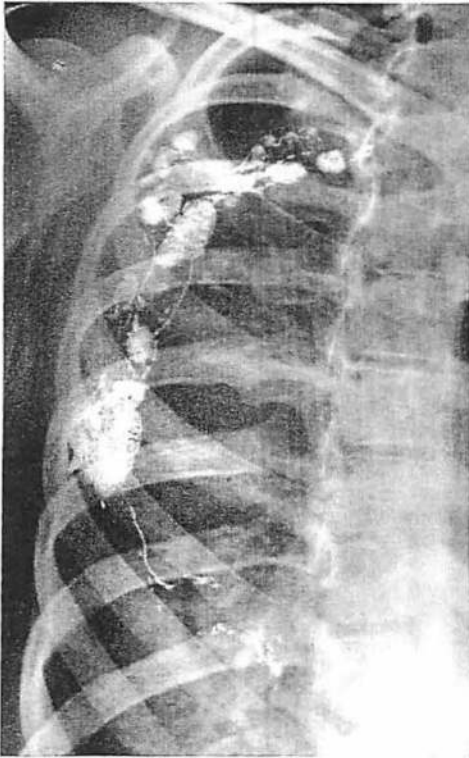


Fig. 2 a Lymphangiogram of the normal breast.

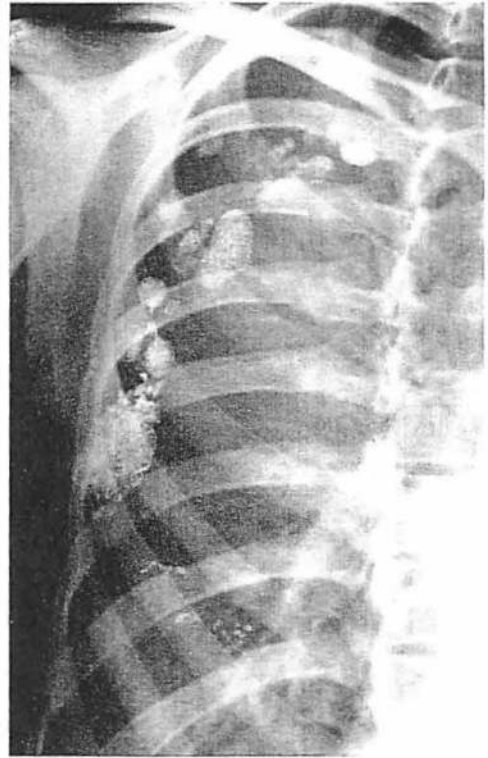

Fig. 2 b Lymphadenogram of the normal breast.

Pictures of benign alterations in the lymph nodes such as succeeding adipose degeneration after previous inflammatory states were only seldom seen in our cases. To separate them from real carcinoma metastases proved to be comparatively easy. Lymph nodes with adipose degeneration filled only along their round borders, never producing any obstacle in lymphatic circuit, while early carcinoma metastases result just in this field in peripheral deficiencies (fig. 3 a, 3 b). By growth of the tumoural tissue the most irregular lymph node shapes are to be encountered, such abnormalities are but every time followed by secondary changes of the lymphatic vessels.

Although cancer may also be accompanied by inflammatory changes without the signs of stagnation or irregular contours, the above-described alterations in the structure of lymph nodes suggest that the primary disease may be benign. These differential-

diagnostic data can be all the more valuable because the biopsy of inflamed carcinoma carries an increased danger of dissemination.

The first metastases can be seen generally in the lymph nodes situated at the edge of the major pectoral muscle, where they can be detected by lymphography at a relatively early stage (fig. 4 a, 4 b, 4 c, 4 d, 4 e). The smallest metastases we succeeded in

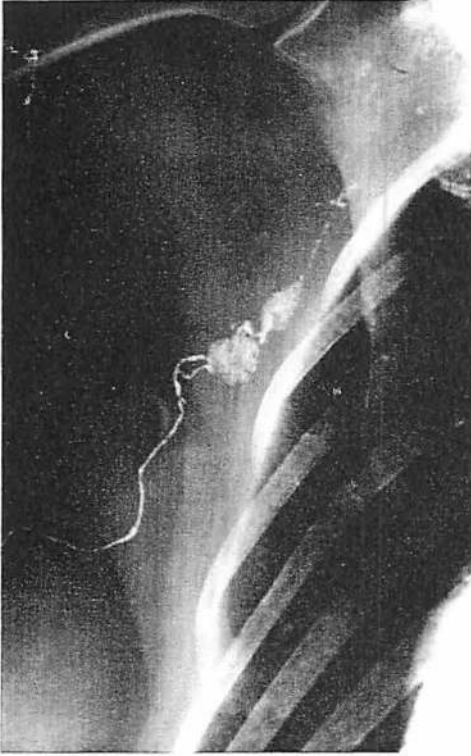

Fig. 3 a

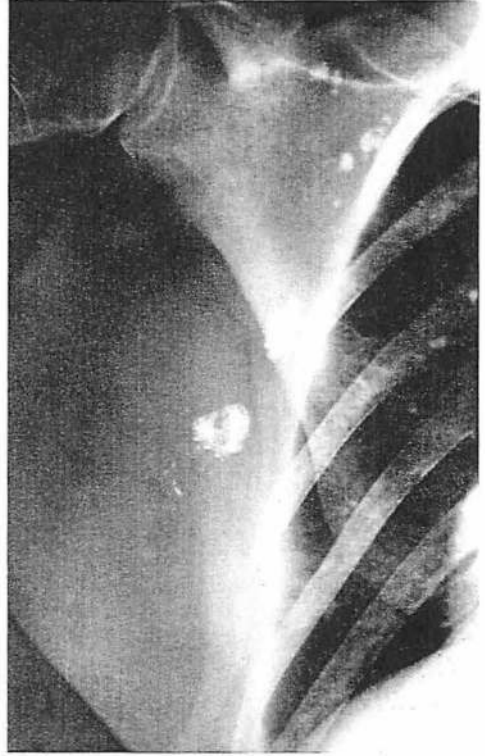


Fig. 3 b

Fig. 3 a Breast cancer with a solid metastasis in the Sorgius lymph node. Lymphangiogram. Lymphatic drainage is sound.

Fig. 3 b Lymphadenogram of the same patient. A small, round metastasis in the Sorgius lymph node.

demonstrating had a diameter of 2 to 3 mm. In advanced cases (fig. 5), when several lymph nodes have already been involved rough signs of stagnation are also observable. In such cases a lymphadenogram shows extravasation of contrast medium around the tortuous lymphatic vessels. The development of extravasations is due to an increased resistance counteracting the injection and to more permeable stagnating lymphatics. This statement is proved by the fact, that extravasations of the contrast medium in case of free lymphatic passage never have been observed.

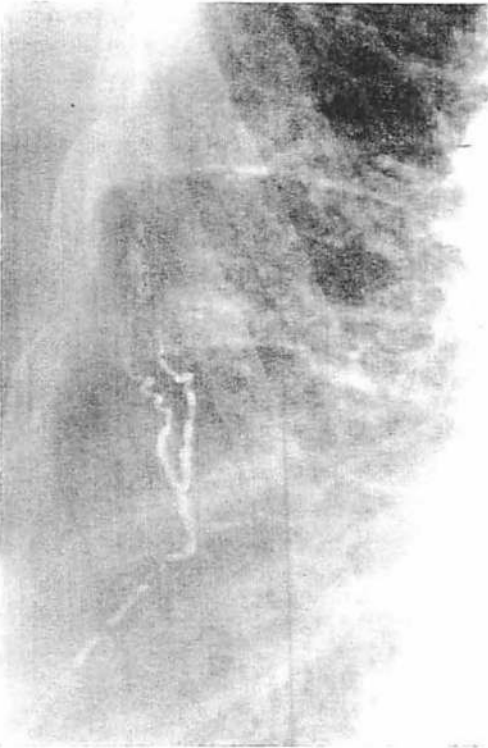


Fig. 4a

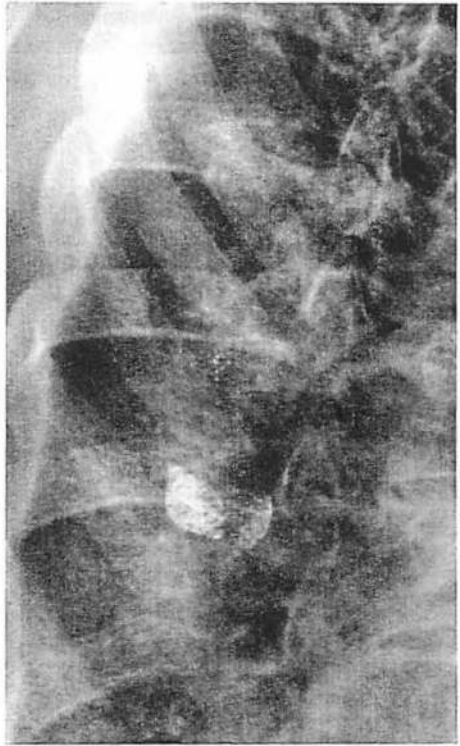


Fig. 4b

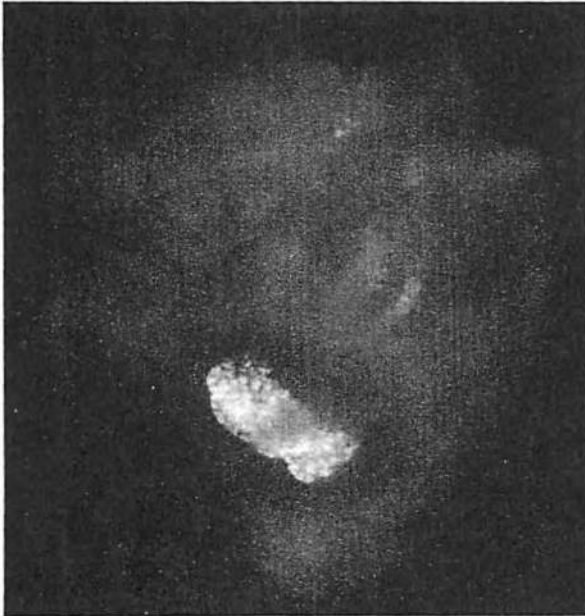

Fig. 4c

Fig. 4 a Breast cancer with a solid metastasis in the Sorgius lymph node; widened, tortuous lymphatics showing multiple ramification before entering the lymph node (corkdrawer shape).

Fig. 4 b Lymphadenogram of the same patient. A defect of uneven contours in the Sorgius lymph node points to the site of metastasis.

Fig. 4 c Operative specimen of the same patient. Roentgenogram; in the center of the Sorgius lymph node, there is a filling defect visible.

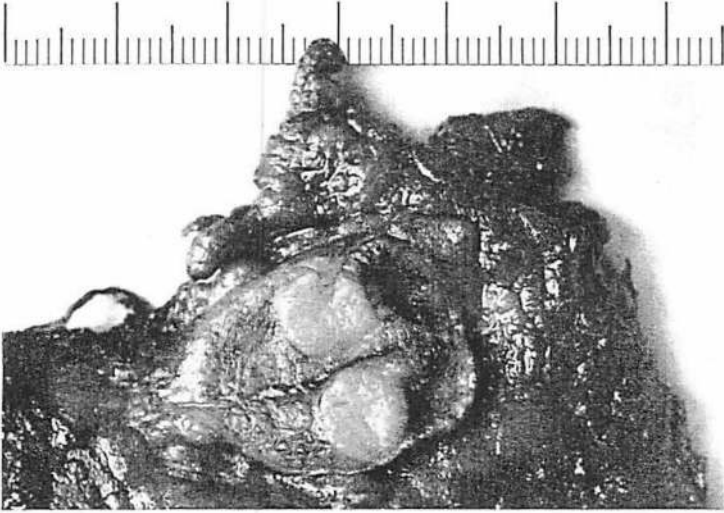

Fig. 4 d Sectioned operative specimen of the same patient; a round metastasis with a diameter of 6 mm. in the Sorgius lymph node.




Fig. 4 e Histological prepare, stained with silver nitrate, of the same lymph node.

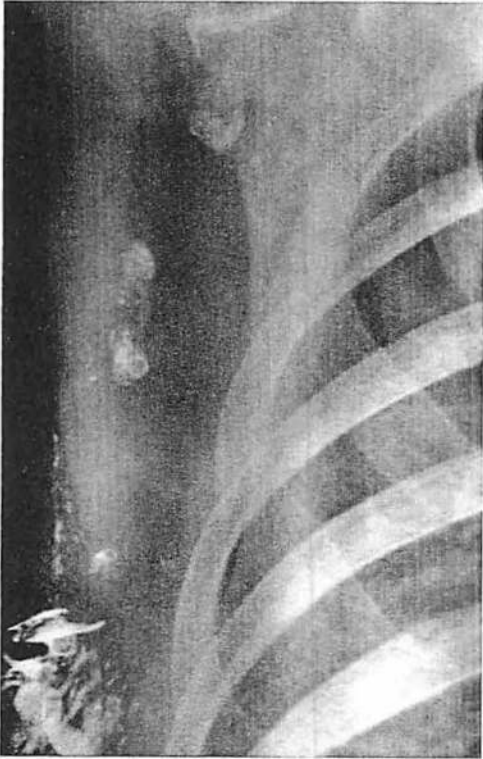


Fig. 5 Lymphadenogram of a patient with advanced breast cancer. Pectoral nodes are ill-shaped and filled only partially with contrast material (Histological proof: 4 lymph node metastases).

As a consequence of the high degree of stagnation collateral vessels develop toward other regions (2). These vessels can be seen in a roentgenogram only when they are enough to allow the passage of Lipiodol. In two cases we succeeded in filling up the lymph nodes along the internal mammary artery through the collateral branches (fig. 6a, fig. 6b).

The filling of parasternal lymph nodes was exclusively seen in pathological cases. Under normal conditions respectively in benign cases direct lymphography did not reveal neither parasternal nor presternal lymphatics. *Bobbio*, *Peracchia* and *Pellegrino* reported of presternal lymphatic connections between the two mammary regions after mastectomy. Pre- and parasternal way of lymph flow has been observed in the course of our investigations, too, predominantly in postmastectomy cases, but it has occurred also preoperatively, in patients with lymph node metastasis (1, 3). No contrast examination can be performed if metastases have completely blocked axillary lymphatic drainage. In such cases a dense network of blue lines

appears in the skin of the breast within 1 to 2 minutes after the injection of "Patent blue", which is caused by retrograde lymph flow (fig. 7).

Conclusions

Lymphography of the breast by means of cannulation of its own lymphatic vessels represents a rather difficult and time-consuming method of examination. However, after necessary practice and experience it can be performed with the same safety as lymphography of the upper or lower extremities. The data obtained by our method only apply to the lymphatic system of the affected breast in contrast to examinations made from the extremities where also the lymph nodes of other regions show contrast filling. The tumour cells have to pass through a chain of 3 to 4 lymph nodes in order to arrive at the collecting system around the axillary vein. Therefore it is easy to understand that metastases can be detected at a much earlier stage by examination from the breast than by that from the extremities.

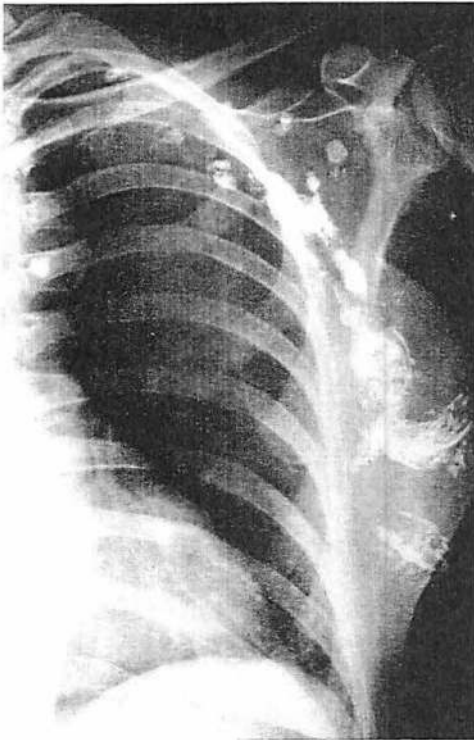

Fig. 6 a

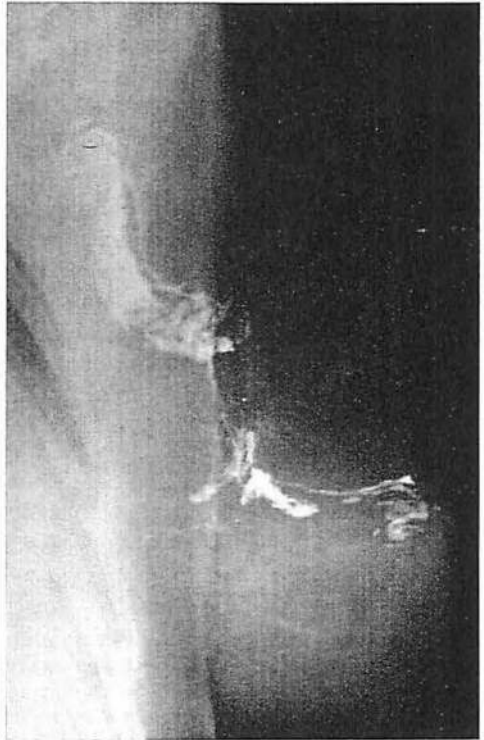

Fig. 6 b

Fig. 6 a Lymphadenogram of a patient with advanced breast cancer. There is a rich network of lymphatics round the Sorgius and pectoral lymph nodes (Histological proof: 7 lymph node metastases). Two homolateral parasternal nodes are also filled.

Fig. 6 b Lymphangiogram of the same patient made in an everted position. A perforating branch is also delineated, invisible in the former picture which connects extramammary lymph nodes with parasternal lymph nodes.

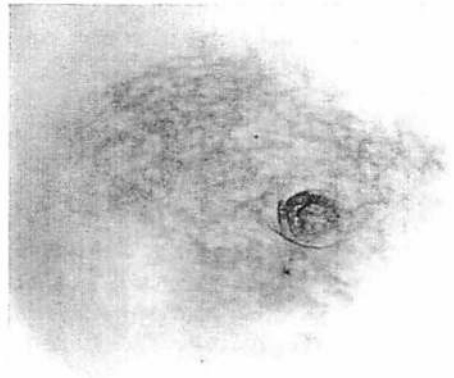


Fig. 7 Owing to the high degree of narrowing of the axillary lymphatic channels the Patent blue dye injected intradermally into the region of the mammary areola causes a dense reticular pattern to appear through the skin of the breast.

A diagnosis based on palpation of the axillary lymph nodes, which is correct in about 70 per cent, can be improved considerably by lymphography. This procedure can reveal small metastases not detectable by palpation. On the other hand, enlargement of a lymph node not infrequently turns out to be an inflammatory change. A lymphadenogram characteristic for inflammation may prove useful also in the diagnosis of the primary disease of the breast.

The stagnation of contrast medium in the lymphatic vessels is indicative of a lymph block which results in the development of collateral vessels. These vessels, circumventing the obstruction may establish a connection also with other regions, such as, for instance, the contralateral axilla or the parasternal lymph nodes. Accordingly stagnation is a very important prognostic sign, which may explain post-operative metastases also in the case of a negative palpatory finding in the axilla.

Net-like discolouration of the breast skin appearing shortly after the injection of the dye indicates severe damage to lymphatic drainage. According to our experiences this phenomenon must be regarded as a sign of inoperability, i.e. objection to radical operation.

Summary

The authors have evaluated the results of direct lymphography of the breast in 88 patients and point out that this procedure renders the diagnosis of regional lymph nodes in breast cancer considerably more accurate. The differing alterations in the lymph nodes which accompany benign and malignant disease can be easily distinguished on the basis of the structural characteristics of lymph nodes. Signs of stagnation call attention to the development of a collateral circulation and, through this, to the involvement of other regions in the process. The almost instantaneous spread of the vital dye in the skin after the injection is indicative of retrograde lymph flow and is a sign of the severity of the disease.

References

- 1 Bobbio, P., G. Peracchia, F. Pellegrino: Connessioni linfatiche presternali fra le regioni mammarie dei due lati. *Ateneo parmense* 33 (1962), 95-109
- 2 Gerota, D.: Nach welchen Richtungen kann sich der Brustkrebs weiter verbreiten? *Arch. klin. Chir.* 54 (1897), 280-288
- 3 Goffrini, P., P. Bobbio, G. Peracchia, F. Pellegrino: Valore della linfografia e della comparazione anatomico-linfografica nello studio delle metastasi ascellari del cancro della mammella. *Ateneo parmense* 33 (1962), 33-59
- 4 Grant, R. N., E. J. Tabak, F. E. Adair: The surgical significance of the subareolar lymph-plexus in cancer of the breast. *Surgery* 33 (1953), 71-78
- 5 Halsell, J. T., J. R. Smith, C. R. Bentlage, O. K. Park, J. W. Humphreys: Lymphatic drainage of the breast demonstrated by vital dye staining and radiography. *Ann. Surg.* 162 (1965), 221-226
- 6 Jones, H. W.: Carcinoma of the breast. *Amer. J. Surg.* 77 (1944), 696-704
- 7 Lewis, R. J., J. M. Beal: Mammalymphangio-adenography: direct radiologic visualization of the breast lymphatics. *Surg. Forum* 14 (1963), 112-114
- 8 Lewison, E. F.: Breast cancer and its diagnosis and treatment. Baltimore 1955
- 9 Marcial-Rojas, R. A.: The role of the surgical radiologist in the diagnosis, treatment and prognosis of cancer. *Amer. J. Surg.* 91 (1956), 719-724
- 10 Robinson, D. W.: Treatment of carcinoma of the breast. *Amer. J. Surg.* 75 (1948), 484-488

Karoly Kett, M. D., 1st Surgical Clinic, Pecs/Hungary, Ifjusag u. 31