

S. Seitsalo
D. Schlenzka
M. Poussa
K. Österman

Disc degeneration in young patients with isthmic spondylolisthesis treated operatively or conservatively: a long-term follow-up

Received: 12 February 1996
Revised: 17 March 1997
Accepted: 12 May 1997

Abstract The purpose of this long-term follow-up was (1) to investigate disc changes in the olisthetic segment in patients treated conservatively, (2) to compare disc changes above the slipped vertebra in conservatively treated patients with those in operatively treated patients, and (3) to establish possible relations of disc changes to the degree of the slip and to subjective back pain symptoms of the patients. The subjects were 227 patients with isthmic L5 olisthesis diagnosed under 20 years of age (mean 13.8 years) with a mean follow-up of 15.4 (range 5–30) years. Of these, 145 patients had been treated with segmental fusion and 82 had been treated conservatively. At follow-up, standing anteroposterior and lateral radiographs as well as flexion/extension views of the lumbar spine were taken. Disc degeneration was graded semiquantitatively: 0 = normal disc height, 1 = decrease of disc height < 50%, 2 = decrease \geq 50%, and 3 = obliteration of the disc. In the conservatively treated patients degeneration of the olisthetic disc was distributed by grade as follows: 0: $n = 38$, 1: $n = 24$, 2: $n = 14$, 3: $n = 6$. No motion at all was observed in the olisthetic segment in 40 patients (48%) with a mean slip of 30%, segmental motion of 4°–18° was found in 42 patients with a mean slip of 14%. There was a statistically signif-

icant association of the degree of slip to the severity of disc degeneration and non-mobility of the segment. Grade 1 degeneration of the L4/5 disc occurred in 25.6% of the conservatively treated patients and in 32% of 48 patients treated with L5-S1 fusion. This correlated with the severity of the slip, but not with pain symptoms or pathologic segmental mobility at the time of follow-up. Out of 84 patients with L4-S1 fusion, in 17% grade 1 degeneration of the L3/4 disc was observed, and 3 out of 13 patients (23%) with L3-S1 fusion had grade 1 degeneration of the disc above the fusion. The disc changes had no correlation with subjective pain symptoms. It is concluded that the natural course of isthmic spondylolisthesis is associated with disc degeneration and spontaneous stabilization of the olisthetic segment. Fusion operations do not significantly increase the rate of disc degeneration in the adjacent disc above the fusion after a mean post-operative follow-up of 13.8 years. No correlation between the number of degenerated discs or the degree of degeneration and subjective low back pain symptoms was found.

Key words Spondylolisthesis · Conservative treatment · Spinal fusion · Disc degeneration · Low back pain

S. Seitsalo
Jorvi Hospital, Espoo, Finland

D. Schlenzka · M. Poussa · K. Österman
Orton Orthopedic Hospital,
The Invalid Foundation, Helsinki, Finland

S. Seitsalo (✉)
Liinasaarenkuja 3-5 D 7,
FIN-02160 Espoo, Finland
Tel. +358-9-861815202;
Fax +358-9-8615900

Introduction

Low back pain symptoms in spondylolisthesis during childhood and adolescence are believed to be connected to the instability of the involved segment [6, 17, 18]. Degeneration of the disc below the slipped vertebra, which is almost regularly seen on MRI even in adolescence, may influence the development of the instability and pain symptoms [11, 12]. Whether the degeneration in this process is primary (causing the break of the isthmus) or secondary (due to the instability caused by the isthmus lysis), is under debate [12, 18]. In the literature, there is only scant information about the natural history of spondylolisthesis in the long term [6, 13]. Spontaneous stabilization of the unstable olisthetic segment is seen in the natural course of the condition [13].

Segmental spinal fusion is widely accepted as the method of choice for treatment of symptomatic cases not responding to conservative measures. Fusion operation, however, increases bending and shearing forces acting on the intervertebral disc above the fusion, leading to progressive degeneration [1, 4, 15]. Furthermore, there are a few reported cases with a development of spondylolysis in the vertebra above the fusion [1, 4, 15].

The aim of this study was, as a part of a more comprehensive examination, to analyze changes connected to the natural course of spondylolisthesis and in the mobility and degeneration of the lower lumbar discs during long-term follow-up of conservatively treated patients. Corresponding changes were examined in the segment(s) above the fusion in spondylolisthesis patients treated by spondylodesis.

Patients and methods

The original study group consisted of 257 patients diagnosed to have symptomatic isthmic spondylolisthesis of L5 at an age of less than 20 years at the Orthopedic Hospital of the Invalid Foundation in Helsinki. They were retrospectively followed up clinically and radiographically for 15.4 (range 6–30) years on average.

Eighty-two patients had received conservative treatment during the initial symptomatic phase of the disease. This treatment consisted of diminishing of physical activities, strengthening of abdominal and back muscles, and, in some cases, a soft brace. One hundred and seventy-five patients were treated by fusion in situ. Only 145 out of these 175 operated patients had solid fusion at follow-up and were included in the final examination group. Thirty patients with pseudoarthrosis were excluded. Out of the 145 patients with solid fusion, 87 had undergone posterior fusion and 55 posterolateral; anterior technique had been used in 3. In 48 patients the fusion operation was carried out between L5 and S1, in 84 between L4 and S1, and in 13 between L3 and S1.

The final study group consisted of 227 patients (113 females and 114 males), 82 treated conservatively and 145 with solid fusion. The mean age at the time of diagnosis was 13.8 (range 8–19) years. The operative treatment was performed at a mean age of 14.3 (range 10–19) years. The mean vertebral slip in the operatively treated group was 45.2% (range 10–100%) compared with 21.8% (range 10–67%) in the non-operative group. This difference was statistically significant ($P < 0.001$).

At follow-up examination the patients were asked (as part of a more extensive study) about the possible occurrence of actual back

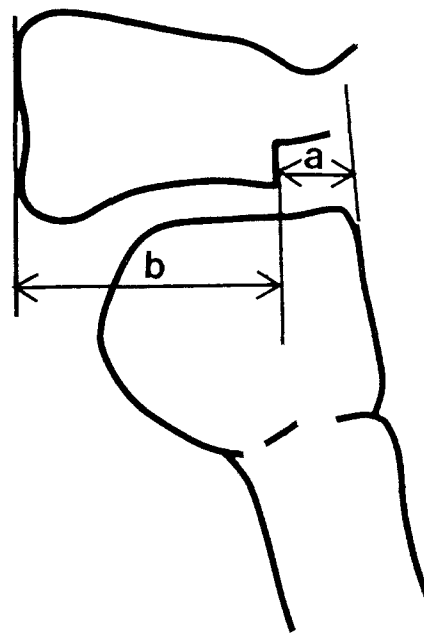


Fig. 1 The anterior slip measured as a percentage of the width of the spondylolisthetic vertebral body ($a/b \times 100$)

pain symptoms. The radiological examination consisted of standing anteroposterior and lateral projections and functional (extension/flexion) radiographs of the lumbar spine using a standardized method.

Degeneration of the three lower lumbar discs was calculated from standing lateral radiographs utilizing a semiquantitative method for assessment of disc height recommended by Andersson et al. [2] and Saraste [10]: grade 0 = normal, grade 1 = disc height decreased by less than 50%, grade 2 = disc height decreased by at least 50%, and grade 3 = disc space completely eliminated.

The degree of vertebral slip was measured from standing lateral radiographs and calculated as the percentage of the sagittal diameter of the slipped vertebral body according to Laurent and Einola [8] (Fig. 1).

The segmental motion was measured from lateral functional radiographs according to the method of Penning and Blickman [9]. For the extension study, the patient was standing and bending maximally backward against the X-ray table. For the flexion study, the patient was bending maximally forward with extended knees and leaning with their hands on a small stool. Segmental motion was determined by superimposing flexion and extension radiographs. Segmental flexion/extension motion of less than 3° was categorized as "non-mobile," motion of 3° or more as "mobile."

The level above the fusion was checked carefully for possible occurrence of secondary spondylolysis developed during the post-operative follow-up period. Disc degeneration and segmental motion were related to the degree of vertebral slip, to the occurrence of low back pain symptoms, and to the duration of follow-up. The Chi-square and Student's *t*-test were used as statistical methods.

Results

The results of the assessment of degeneration of the olisthetic disc in conservatively treated patients and their relations to segment mobility and pain symptoms are shown in Table 1. In 6 out of 82 conservatively treated patients

Table 1 Degeneration of the spondyloarthrotic disc (measured semiquantitatively) and its relation to the movement of the olisthetic segment in functional radiography in 82 patients treated conservatively. Analysis after 15 (range 5–30) years of follow-up. Correlation of the grade of degeneration to the occurrence of low back pain (LBP) symptoms is presented

Grade of disc degeneration	Olisthetic segment (L5-S1)		LBP symptoms
	Non-mobile (n = 40)	Mobile (n = 42)	
Grade 0 (n = 38)	1	37	5/38
Grade 1 (n = 24)	19	5	3/24
Grade 2 (n = 14)	14	0	2/14
Grade 3 (n = 6)	6	0	0/6 n.s.
Mean slip (%)	30.5	13.8	<i>P</i> < 0.001

Table 2 Grade of disc degeneration in the adjacent disc above the fusion in 145 operated patients according to fusion levels

Grade of disc degeneration	Fusion level(s)		
	L5-S1 (n = 48)	L4-S1 (n = 84)	L3-S1 (n = 13)
Grade 0	33	70	10
Grade 1	15 (31%)	14 (17%)	3 (23%)

Table 3 The condition (grade of degeneration) of the adjacent disc (L4/5) in 82 patients treated conservatively and 48 patients after L5-S1 fusion and its relation to the amount of vertebral slip and the occurrence of low back pain at follow-up

	Conservative treatment (n = 82)	L5-S1 fusion (n = 48)	<i>P</i>
No. of patients			
Grade 0	61	33	
Grade 1	21 (26%)	15 (31%)	n.s.
Slip (%)			
Grade 0	16.2 ± 8.4	19.2 ± 5.2	
Grade 1	32.4 ± 21.6 <i>P</i> = 0.03	48.1 ± 7.2 <i>P</i> = 0.01	n.s.
LBP (No. of patients)			
Grade 0	6/61	5/33	
Grade 1	4/21	4/15	
	n.s.	n.s.	n.s.

(7.3%) the olisthetic disc was found to be completely eliminated (grade 3) during the follow-up period. In 14 (17%) the decrease in the disc height was more than 50% (grade 2). In these 20 cases of grade 2 and 3 degeneration there was no measurable motion in the olisthetic segment on functional radiographs. Grade 1 degeneration of the olisthetic disc was noted in 24 patients (29%). Nineteen of those discs were immobile. Degeneration was positively correlated with non-mobility. Forty patients who had no motion in the olisthetic segment had a significantly higher mean slip than those 42 patients with normal segmental mobility.

At follow-up, 10 out of 82 conservatively treated patients reported low back pain. The occurrence of pain symptoms did not correlate with the grade of degeneration, nor with the segmental mobility.

The condition of the adjacent disc above the fusion at follow-up in operated patients is shown in Table 2. Disc space narrowing of less than 50% (grade 1 degeneration) was seen in 17–31% of the patients. The differences between the groups related to the number of fused segments were not significant. Neither the mobility of the segment nor occurrence of pain symptoms had any statistical correlation to the degeneration.

A comparison of the condition of the L4/5 disc in conservatively versus operatively treated patients is presented in Table 3. Grade 1 degeneration of the adjacent disc above the olisthetic segment was found in 26% and 31% respectively, the difference being not statistically significant. In both groups, disc degeneration was significantly related to more severe slip. Neither mode of treatment nor occurrence of disc degeneration had any statistical correlation to low back pain at follow-up.

Table 4 shows the results of the measurements of segmental flexion/extension motion in both treatment groups. For comparison, normal values published by Hayes et al. [5] are presented.

In all groups degeneration was related to a longer follow-up time. The differences, however, do not reach statistical significance. Bilateral spondylolysis in the vertebra above the fusion, not present at operation, was found in three patients. All three had a grade 1 disc degeneration at this level. Two of them had symptoms of low back pain at the time of follow-up.

Discussion

The natural history of L5 spondylolisthesis has been reported to be benign [6, 10, 13, 18]. The clinical long-term results of the conservatively treated patients described in the present study were reported earlier [13]. During the follow-up period, none of the patients whose treatment was initially planned to follow conservative lines was later operated on. Furthermore, those patients to whom operative treatment had been proposed, but who had not been operated on for various reasons, showed statistically comparable clinical and radiological end results as well as comparable subjective assessment with other patients treated conservatively [13]. After the symptomatic initial period in childhood or adolescence, the occurrence of later pain problems was rare [13].

In the present study, the semiquantitative assessment of disc degeneration expressed by loss of intervertebral disc height in standing plain radiographs was used. This was measured according to the recommendation of Andersson et al. [2] and Saraste [10], who reported minimal inter- and intraobserver errors when using this method. Osteo-

Table 4 Segmental range of lumbar flexion/extension motion (degrees) in conservatively and operatively treated patients

Segment	Conservative treatment (n = 82)	Operative treatment (fusion)			Normal ^a
		L5-S1 (n = 48)	L4-S1 (n = 84)	L3-S1 (n = 13)	
L2-3	10.4 ± 1.8 (5–15)	10.4 ± 2.6 (5–18)	10.7 ± 3.3 (6–20)	8.4 ± 5.1 (6–17)	9 (2–16)
L3-4	11.6 ± 3.5 (2–21)	11.1 ± 4.4 (0–21)	9.9 ± 6.3 (0–26)	–	10 (2–18)
L4-5	10.6 ± 5.2 (0–24)	10.3 ± 7.3 (0–23)	–	–	13 (2–20)
L5-S1	5.1 ± 6.3 (0–22)	–	–	–	14 (2–27)

^aAccording to Hayes et al. [5]

phyte formation indicating more advanced degeneration was not chosen as an assessment criterion. MR imaging is, of course, a more sensitive method, revealing degeneration at a very early stage. This technique, however, was not available routinely at the time of the present examination.

The radiological results in the present study support the opinion that the natural course of the spondylolisthesis disease at the L5 level is benign. The progressive degeneration of the olisthetic disc expressed as decrease in the disc height, associated with decrease in mobility, i.e., stabilization of the segment, is part of the natural process of this condition. This kind of spontaneous stabilization of the olisthetic disc occurs in the majority of these patients, leading in some cases to immobility. The spontaneous stabilization described here, associated with the degeneration of the olisthetic disc, is analogous to the widely accepted hypothesis of the natural history of “physiologic” degeneration of the lumbar spine described by Kirkaldy-Willis, including the phases of dysfunction, instability, and stabilization [7]. In spondylolisthesis, however, the progression of the disc degeneration seems to happen faster and at a younger age. The period of instability may, of course, involve progressive pain of such severity that operative stabilization may be needed.

Decreased disc height above the fusion level during the long-term follow-up was observed in 17–32% of patients. In the conservatively treated group, adjacent disc degeneration was seen in 26%. This degeneration, however, did not cause statistically more pain symptoms than were found in patients without disc narrowing in the segment above, regardless of whether the treatment had been conservative or operative. The highest incidence of adjacent disc degeneration occurred in patients with a short (L5-S1) fusion and a more severe slip (mean 48.1%). This may be due to the fact that severe slips are connected with loss of lumbosacral lordosis, forcing the segment above into compensatory increased lordosis. This could be one reason for premature degeneration of the adjacent disc, which has been shown to be quite common by using MRI

preoperatively in symptomatic slips in children and adolescents [11]. This may be seen as a reason to include the L4/L5 disc in the fusion. We, however, do not believe that this is justified in a young patient, because the clinical course of the degenerative process seems to be benign in the majority of cases. Furthermore, we have to acknowledge that we are looking at the problem from a purely mechanical point of view. One has, however, to bear in mind that genetic factors determining the quality of the disc tissue are of primary importance [3]. Therefore, it is impossible to decide on the basis of this investigation how much of the degeneration is due to the spondylolisthesis or the fusion, respectively, and how much is primary (genetically determined). Besides that, we know from earlier MRI studies that a certain number of discs showing signs of beginning (“physiologic?”) degeneration have been detected in normal healthy schoolchildren [12, 14]. There is, however, evidence that the incidence of premature disc degeneration in olisthetic children and adolescents is higher than in non-olisthetics of a comparable age [12].

The segmental flexion/extension range of motion in the lumbar segments above the olisthetic level was surprisingly uniform in operatively as well as conservatively treated patients, the mean values being very close to normal figures from the literature. The fusion operation does not seem to influence segmental motion in the remaining segments, at least after a mean follow-up of about 14 years. One explanation could be that posterior and posterolateral fusions, used in the vast majority of our cases, are mechanically not very rigid. This may protect the adjacent disc somewhat if compared with anterior or circumferential fusions, which are certainly much stiffer [16]. The patients, however, are still very young and it is possible that we will see changes developing during further follow-up.

In this material were also noted three patients with a development of spondylolysis in the vertebra above the fusion during follow-up. There are some earlier reports of similar cases in the literature [1, 4, 15]. The cases in the present series occurred after posterior spondylodesis, and

two of the patients also had pain symptoms. This possibility must be taken into consideration as an iatrogenic complication of fusion in the long term.

Conclusions

In conservatively treated young patients, the olisthetic disc undergoes progressive degeneration leading to loss of mobility and self-stabilization of the segment. The degree

of disc degeneration in the olisthetic segment is positively related to the amount of vertebral slip.

Disc degeneration in the adjacent segment above the fusion was seen in 17–31% of the operated patients. No significant differences could be established between the condition of the disc above the olisthetic segment in the operatively and that in the conservatively treated patients.

Low back pain symptoms were rare. There was no correlation between disc degeneration on radiographs and pain.

References

1. Anderson CE (1956) Spondyloschisis following spine fusion. *J Bone Joint Surg [Am]* 38:1142
2. Andersson GBJ, Schultz A, Nathan A, Irstam L (1981) Roentgenographic measurement of lumbar intervertebral disc height. *Spine* 6:154–158
3. Battié MC, Videman T, Gibbons LE, Fisher LD, Manninen H, Gill K (1995) Determinants of lumbar disc degeneration. *Spine* 20:2601–2612
4. Harris RI, Wiley JJ (1963) Acquired spondylolysis as a sequel to spine fusion. *J Bone Joint Surg [Am]* 45:1159
5. Hayes MA, Howard TC, Gruel CR, Kopta JA (1989) Roentgenographic evaluation of lumbar spine flexion-extension in asymptomatic individuals. *Spine* 14:327–331
6. Hensinger RN (1989) Current concepts review. Spondylolysis and spondylolisthesis in children and adolescents. *J Bone Joint Surg [Am]* 71:1098–1107
7. Kirkaldy-Willis WH (1983) The pathology and pathogenesis of low back pain. In: Kirkaldy-Willis WH (ed) *Managing low back pain*. Churchill Livingstone, New York/Edinburgh/London, pp 23–43
8. Laurent LE, Einola S (1961) Spondylolisthesis in children and adolescents. *Acta Orthop Scand* 31:45
9. Penning L, Blickman JR (1980) Instability in lumbar spondylolisthesis. A radiologic study of several concepts. *Am J Roentgenol* 134:293–301
10. Saraste H (1984) Spondylolysis and spondylolisthesis. Thesis, University of Stockholm, Stockholm
11. Schlenzka D, Poussa M, Seitsalo S, Österman K (1991) Intervertebral disc changes in adolescents with isthmic spondylolisthesis. *J Spinal Disord* 4:344–352
12. Schlenzka D, Seitsalo S, Poussa M, Österman K (1993) Premature disc degeneration: source of pain in isthmic spondylolisthesis in adolescents? *J Pediatr Orthop [B]* 1:153–157
13. Seitsalo S (1990) Operative and conservative treatment of moderate spondylolisthesis in young patients. *J Bone Joint Surg [Br]* 72:908–913
14. Tertti MO, Salminen JJ, Paajanen HEK, Terho PH, Kormano MJ (1991) Low-back pain and disc degeneration in children: a case-control MR imaging study. *Radiology* 180:503
15. Unander-Scharin L (1950) On low-back pain with special reference to the value of operative treatment with fusion. *Acta Orthop Scand [Suppl]* 5
16. White AA, Panjabi MM (1990) *Clinical biomechanics of the spine*, 2nd edn. Lippincott, Philadelphia, pp 561–565
17. Wiltse LL (1961) Spondylolisthesis in children. *Clin Orthop* 21:156–163
18. Zippel H (1980) *Wirbelgleiten in Lendenbereich*. Barth, Leipzig