

DISORDERS OF "SIMULTANEOUS PERCEPTION" IN A CASE OF BILATERAL OCCIPITO-PARIETAL BRAIN INJURY

BY

A. R. LURIA

University of Moscow and Academy of Pedagogical Sciences, Moscow

I. INTRODUCTION

IN reports of the optico-gnostic disorders arising from cerebral lesions, a restriction of the field of visual perception to single objects or their parts has been repeatedly described. It was mentioned in some of the earliest descriptions of visual agnosia (Wilbrandt, 1887; Lissauer, 1890) and subsequently analysed with particular thoroughness by Bálint (1909). In Bálint's case, the patient was said to have been able to see only one object at a time, irrespective of its size. Holmes later described very similar disorders in cases of bilateral posterior parietal gunshot wound (Holmes, 1919; Holmes and Horrax, 1919). Although placing the main emphasis upon loss of visual orientation, Holmes referred to a constriction of visual attention as an important element in the syndrome. In more recent years, Bálint's syndrome has been reinvestigated by Hécaen and Ajuriaguerra (1954), who likewise stress the defect of attention and the bilaterality of the responsible lesion.

Defects of visual synthesis of a somewhat less pronounced character have also been described in the literature (Gelb and Goldstein, 1920; Wolpert, 1924; Head, 1926; Paterson and Zangwill, 1944). In these cases, the lesion is commonly unilateral, orientation in space is usually preserved, and scanning movements of the eyes less obviously disturbed. But there may be gross incapacity to combine the elements of the perceptual display into a coherent and integrated whole. To this type of deficit the term "simultanagnosia" is commonly applied (Wolpert, 1924).

It is clear that the limited and fragmentary character of perception so often associated with occipito-parietal lesions cannot be wholly accounted for in terms of visual field defects. Restriction of visual perception to individual objects or their parts has been described in the absence of significant field defects; conversely, perception may be more or less adequate in spite of extensive scotomata. This is not, however, to say that the perceptual deficit does not call for physiological explanation;

indeed the need for such explanation has been repeatedly stressed in the recent literature and at least two theories of its origin (Bay, 1950; Denny-Brown, Meyer and Horenstein, 1952) have been put forward.

It is the author's belief that a proper explanation of the occipito-parietal syndromes will come about only through thorough investigation of the neurodynamical basis of agnostic states. Such an investigation should proceed from the principles of physiological analysis adumbrated in the modern Pavlovian theory of higher nervous activity.

In 1935, I. P. Pavlov devoted one of his "Wednesday colloquia" to the discussion of a case of brain injury briefly reported by Pierre Janet (1935, pp. 160-3). This was the case of a French officer who sustained a bilateral occipital gunshot wound and who subsequently presented a peculiar disturbance of vision. According to Janet, "visual comprehension became concentrated" and the patient lost the ability of orientation in space. He could not see a number of objects simultaneously and, in his own words, "felt lost in the surrounding world."

The physiological analysis of this phenomenon given by Pavlov is of exceptional interest. "The (occipital) region," he wrote, . . . is inhibited to such a considerable degree that it cannot endure two simultaneous stimulations The visual region of the brain has such a low tonus of excitation that it is able, influenced by the given stimulus, to concentrate its activity at one point only, while all other points remain as if they were non-existent. Hence the patient sees a distinct person, a distinct object, but he is unable simultaneously to perceive anything else, since the notion of space escapes him. Everything is confined to the point which is stimulated at the given moment. There are no traces whatever, and that is why the patient feels 'lost in the world' (Pavlov, 1955, p. 609).

Pavlov's attempt to consider physiologically the origin of central visual disorder opens up bright prospects. If we assume that, owing to the functional weakness of the visual cortex, each focus of excitation inhibits the remainder of the cortex by way of negative induction, a functional limitation of perception must inevitably result. This viewpoint makes it possible for us to comprehend "restriction of visual attention" in physiological terms and to approach the phenomena of "simultaneous agnosia" in a new way. For the deficit will then appear as a consequence of excessive cortical inhibition, leading to failure to synthesize excitation arising in the visual sphere under conditions of complex stimulation. One might also suggest that a patient whose perception is restricted to a single detail will be obliged to combine details in a *secondary way*, relying on his intact speech to attempt an interpretation of the total situation.

This hypothesis can be verified only through thorough investigation of appropriate clinical cases. It must be established first, that agnostic disorders of the kind described by Janet really are referable to want of

simultaneous perception: and secondly, that they really are determined by neurodynamic disturbance of the cortex and are subject to modification by factors which influence cortical tonus. We propose in the present paper to attempt to answer these questions by reference to a detailed analysis of a case of brain injury closely comparable to that of Janet to which reference was made by Pavlov.¹

II. CASE REPORT

V. . ., aged 21, an officer of the Polish Army, was wounded in the left occipito-parietal region in April, 1945. The bullet penetrated through the posterior and mesial parts of this area, crossing the mid-line and becoming embedded in the oral parts of the right occipital lobe. It may be assumed that the bullet passed either through the splenium of the corpus colosum or dorsally through the large longitudinal ligament and the white matter of both occipital lobes (fig. 1).

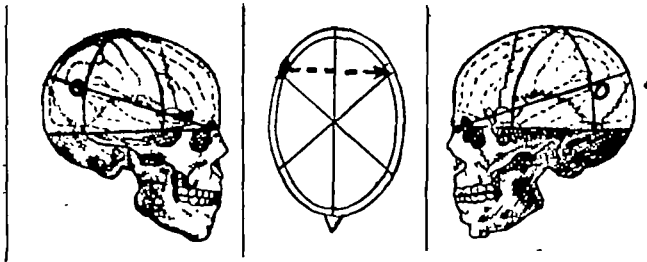


FIG. 1.—Patient V. . . Approximate locus and track of missile wound.

The patient at first presented a left-sided hemiplegia and motor aphasia. Vision was totally lost. Six months later, speech was fully recovered and some improvement of the hemiplegia was in evidence. Vision began to improve. The patient at this stage reported attacks of giddiness and nausea as well as photophobia and epiphora, i.e., symptoms which testify to an irritation of the corresponding parts of the brain.

Six months later, the patient underwent a trepanation of the right occipital lobe with a view to removal of the m.f.b. (this operation was however unsuccessful, the m.f.b. being removed at a later stage at the Institute of Neurosurgery in Moscow). After the operation the patient's vision again deteriorated, without further improvement. The attacks of vestibular giddiness were now accompanied by epileptic fits, which began with acute headaches and twitching of the right eyelid, and were associated with loss of consciousness. These attacks necessitated his readmission to the Burdenko Institute of Neurosurgery in Moscow, where he had already undergone treatment in December 1947 and in August–October 1950.

At this time the patient's behaviour was absolutely normal. He spoke Polish and Russian without difficulty: vocabulary and grammar were fully intact. He could

¹Phenomena essentially similar to those described here may also arise on a paroxysmal basis. I have had occasion to observe a boy of 14, who suffered from epileptic attacks accompanied by micropsia following an occipito-parietal injury at the age of 9. Before each fit the boy's field of visual perception was limited in such a way that he could see only *one* object at a time, e.g. a letter, a car, or a man, irrespective of its size. The analysis of paroxysmal visual defects of this type might be expected to throw valuable light on the functions of the visual cortex.

repeat 6 or 7 words or digits forwards. Understanding of speech was intact and the patient readily performed various abstract operations, experiencing difficulty only when it was necessary to appreciate spatial relationships directly based on visual analysis. He could easily carry out complex verbal instructions (e.g. Marie's test). Calculations were easily performed and the patient could grasp the logical system of rather complex arithmetical problems. Emotionally, he was absolutely normal, and tried hard to overcome his disabilities.

The patient's main complaint was of certain defects in his vision which he could not, however, clearly specify. He stated that he discerned objects around him with difficulty, that they flashed before his eyes and sometimes disappeared from his field of vision. This impression was particularly pronounced in reading: the words and lines flashed before his eyes and now one, now another, extraneous word suddenly intruded itself into the text. The same occurred in writing: the patient was unable to bring the letters into correlation with his lines or to follow visually what he was writing down: letters disappeared from the field of vision, overlapped with one another and did not coincide with the limits of the lines.

The patient also complained of occasional attacks of giddiness and of infrequent fits, with visual and kinesthetic auras, and accompanied by loss of consciousness.

On *neurological examination* (Dr. Podgornaya), the main findings were residual left-sided hemiparesis, most pronounced in the proximal parts of the limbs; increase of tendon reflexes, and some trophic changes in the left limbs. Sensory findings comprised diminution of sensitivity to temperature and pin prick in left limbs and left-sided astereognosis.

Neuro-ophthalmological examination (Dr. Pantieleva) revealed a slight pallor of the optic discs and some degree of concentric constriction of the visual fields (fig. 2). Visual acuity was normal. No abnormality of colour vision.

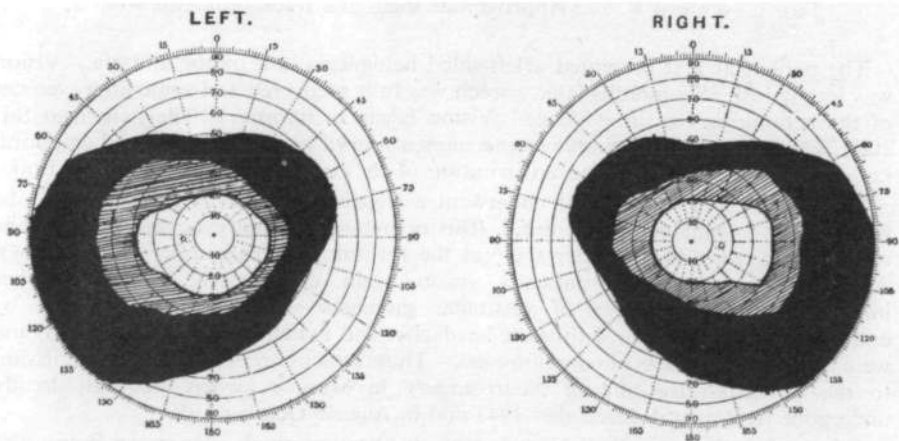


FIG. 2.—Visual fields of patient V. . . Stippled area: Movement perception only.

At *otological examination* (Professor Ageyeva-Maikova), auditory sensitivity was found to be intact but there was marked derangement of binaural hearing. The patient exhibited a slight spontaneous nystagmus.

Electroencephalographic studies (Dr. Novikova) gave evidence of a marked deceleration of the alpha rhythm in the occipital region, accompanied by slow delta waves. The latter were more pronounced on the right side and sometimes irradiated

over the whole cortex. The normal depression of the alpha rhythm to visual stimulation was reduced, particularly on the right side.

X-ray studies (Professor Kopylov) indicated phenomena of regional hydrocephalus, especially in the posterior portions of both ventricles. The posterior horn of the left lateral ventricle showed marked dilatation and the posterior and lower horns of the right lateral ventricle were obliterated, due to productive cicatricial changes. These findings testified to a residual inflammatory process in the occipital region.

This patient presents clear indications of a bilateral occipito-parietal lesion. There are obvious disturbances in optico-vestibular and visual functions, which the patient himself could not clearly specify. At the same time, speech remained intact and the personality was well preserved.

III. DEFECTS OF VISUAL PERCEPTION

The patient was able to perceive objects in an essentially normal manner. He could recognize geometrical figures (e.g. triangle, square), even when they were drawn in dotted lines. Substantial defects made their appearance only when *the visual field contained a number of separate elements*. Under these conditions the process of perception was greatly retarded. The patient moved his eyes from one object to another in a confused and inadequate manner. Thus it might take him 7 or 8 seconds to perceive a group of three small objects. Oculomotor scanning often appeared defective, leading to failure to fixate one or more of the objects present (those to his left being more frequently ignored).

These findings suggested that there was an appreciable derangement of *simultaneous visual synthesis*, which should also appear under conditions in which eye movements were excluded. A series of tachistoscopic experiments were therefore undertaken.

Tachistoscopic studies: Groups of 2, 3 and 4 single figures were repeatedly presented on cards of 2 × 3 cm. or 3 × 4 cm., each card being exposed such that the material fell fully within the intact portion of the visual field. Exposure times varied between 0.2 and 0.6 sec., and were occasionally raised to 0.8 sec. Illustrations of the displays used are given in fig. 3 (a-d) and 4 (a and b).

Experiment 1 (fig. 3a): Twenty-five presentations of this display were given. On only three of these (Trials 20, 23 and 24) were both forms correctly recognized. The circle alone was reported on ten occasions and the cross alone on three. In seven cases, one figure was correctly recognized and the subject also reported a second figure, which he was either unable to name or which he misidentified. In five cases, neither figure was perceived. It was noteworthy that, even when the patient was told that a cross was present in addition to a circle, he still failed to perceive the former figure.

Experiment 2 (fig. 3b): On eighteen presentations of this display, the circle alone was reported once and the square alone once. "A square and a dot" were reported on four occasions and "a circle and

a dot" on one. In the remaining cases either nothing was seen, or one or more "dots."

Experiment 3 (fig. 3c): Nine presentations were given. The star alone was reported on four occasions, and a star "with something else" on three. On one exposure, the patient reported "a star and a triangle or a circle. I could not make it out."

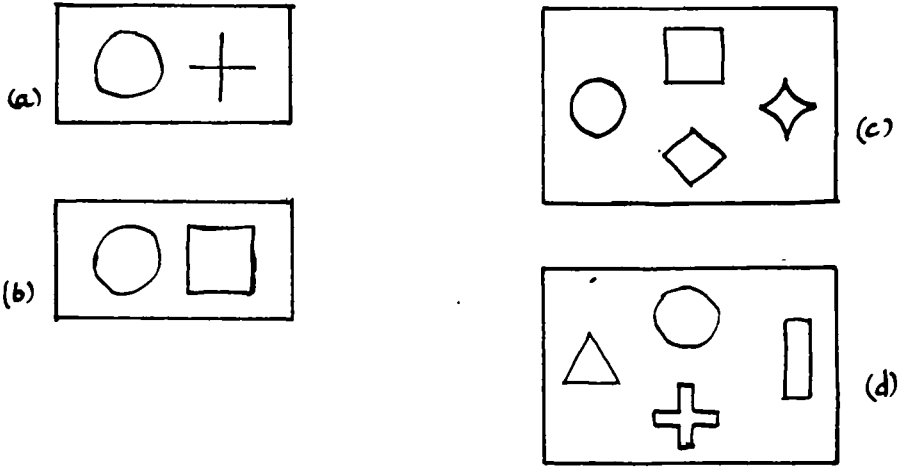


FIG. 3.—Experiments 1-4: Simultaneous exposure of simple forms.

Experiment 4 (fig. 3d): Ten presentations were given. A cross with or without "something else" was reported on six occasions. "A double rod" was reported three times.

Experiment 5 (fig. 4a): Seven presentations of this display were given. One triangle was perceived on the first and third exposures. On and after the fourth presentation, however, both triangles were noted.



FIG. 4.—Experiments 5-6: Simultaneous exposure of identical or related forms.

Experiment 6 (fig. 4b): Ten presentations were given. One circle was perceived on the first four trials. Thereafter, the patient consistently reported "two circles, resembling spectacles."

These results suggest first, that when two or more separate forms are exposed for brief intervals, only one is seen at a time; and secondly, that if the two forms are identical, or combined into a single structure, their perception is markedly facilitated.

It may therefore be postulated that the excitation evoked in the visual cortex was confined to a single focus. In some cases, this focus represented a single objective "element," in others, a configuration composed of several "elements," e.g. "spectacles." But if the several "elements" did not form a configuration, and thereby required for perception the synthesis of two isolated centres of excitation, the patient was in general unable to perceive them simultaneously. This was clearly brought out in the following experiments:

Experiment 7 (fig. 5a and b): A star-shaped figure consisting of two overlapping triangles (5a) was exposed for a short interval. The patient immediately perceived it as a star. If, however, one triangle was coloured red and the other blue (fig. 5b), *one or other triangle*

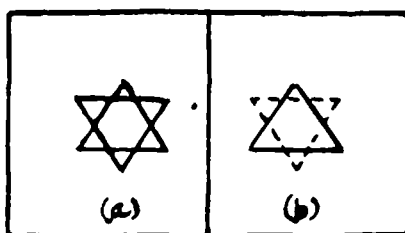


FIG. 5.—Experiment 7: Effects of colour on form perception.—: red - - -: blue.

alone was perceived and the star was never reported. In the same way, a very simple outline drawing of a human face was recognized if all components were drawn in the same colour, but never recognized if two different colours were employed. In general, the more complex the coloured material, the greater the recognition difficulty.

These results indicate that, owing to constriction of the perceptual field (in particular disregard of the left half), the patient is unable to perceive a number of visual items presented simultaneously. In such a patient, the visual cortex can "concentrate its activity at one point only, while other points remain as if they were non-existent." It is only where, in virtue of previous experience, several stimuli can be combined into a single configuration that the simultaneous perception of several elements becomes possible.

IV. OCULOMOTOR "ATAXIA"

The perceptual restriction to which we have called attention was associated with a second, and probably related, syndrome which has often been described in the literature. This consists of a derangement in oculomotor scanning and "ataxia of the gaze" (Bálint, 1909; Hécaen and Ajuriaguerra, 1954).

Although the patient was able to control movements of his right upper limb very adequately with eye closed, his movements lost all precision

when executed under the control of vision. It took him much time to locate and grasp an object placed upon the table; his movements were clumsy and he often missed the object altogether. It is characteristic that his "gaze" manifested the same helplessness as his arm.

This lack of proper oculomotor scanning was also apparent in reading and writing. In reading, extraneous words would intrude themselves into his field of vision; in writing, the patient proved unable properly to dispose the elements of the letters in space and to co-ordinate his writing with the lines (fig. 6a). If, however, he attempted to write with eyes closed (fig. 6b), performance was consistently improved.




FIG. 6.—Samples of writing: (A) Eyes open. (B) Eyes closed.

These findings suggest that the derangements in motor performance, both manual and oculomotor, would appear to originate on a predominantly visual basis. But it remains to be ascertained whether, and if so to what extent, they are connected with the postulated changes in the activity of the visual cortex to which attention has been drawn.

A series of experiments was carried out to determine the extent to which the defect in simultaneous visual conjunction is reflected in motor co-ordinations.

Experiment 8: The patient was first asked to touch with the tip of a pencil a *single* dot presented on a piece of paper. This he could do quite adequately. If, however, the examiner pointed to a given spot on the paper (without making any mark) and then asked the patient to point to the same spot, the task proved exceedingly difficult and quite extensive errors (2 or 3 cm. deviation) were recorded.

Still greater difficulties arose if the patient was required to co-ordinate his movements in accordance with the relationship between a number of visual elements; e.g. to place his pencil point on the centre of a circle or cross. Thus he would complain that one line of the cross would disappear while he was fixating the other. He also tended, when fixating the point of the pencil, to "lose" the design. For this reason, the patient tended to adopt special procedures to avoid having to perceive all the relevant elements simultaneously. Thus he might move his pencil along one of the lines of a cross, or view the cross from above and make a sudden jab with his pencil towards its centre.

Very similar difficulties likewise arose if the patient were required to outline a figure (fig. 7a and b) or to copy a design.




FIG. 7.—Attempts to outline simple figures.

It is plain that if there is but a *single* focus of excitation in the visual field, the act of visual fixation of the corresponding object remains relatively undisturbed. If, however, we deal only with the *trace* of such an excitation (as when the patient is required to indicate a spot touched a second or two previously by the examiner), the weakened visual cortex manifests a considerable defect in the concentration of nervous activity. The trace is extremely unstable and considerable error results. Finally, the patient's incapacity to perceive two elements simultaneously, and to co-ordinate fixation and manipulation in terms of a synthetic visual perception, evokes the phenomenon of "optic ataxia." This, to a considerable degree, represents the motor equivalent of the visual disorder.

V. VISUAL SYNTHESIS AND SPATIAL ORIENTATION

There is an apparent paradox in the fact that the patient can perceive a unified structure while being at the same time unable to appreciate a

complex of unrelated elements. This paradox is, however, resolved when we bear in mind that the patient's appreciation of a perceptual structure may be lost if he is required to focus attention upon its component elements.

Experiment 9: If the patient is presented with a pattern of six dots arranged to form a rectangle, he can easily perceive and name it. But if the patient be then instructed to *count* the component dots, he experiences very considerable difficulty. The new task destroys immediate awareness of the configuration; it is now the separate elements which become the object of analysis. Under these conditions, the patient becomes unable to see clearly any dot other than that which he is immediately fixating. This simple experiment helps us to comprehend the peculiarities of the act of reading in our patient, as well as of his perception of complete and complex situations.

A picture presenting a definite situation is perceived by the patient as a whole, though he does not always obtain the correct idea of its nature. When he attempts to analyse it, however, difficulties arise of the kind described in the above experiment. Concentration on any given detail results in the loss of its relationship to the remainder and the general perception of the picture becomes disintegrated.

Experiment 10: A picture of two men talking on a verandah was shown to the patient. He immediately said: "Here are some people." When asked to specify the number of people, he pointed first to the head of one of the men, saying "one," then to the arm of the other, saying "two." He then pointed to the head of the same man, saying "Here's a third." Repetition leads to no improvement in comprehension; indeed to further disintegration of the original global impression.

The same basic want of visual synthesis was also apparent in the patient's weakness in spatial orientation. Although orientation for left and right (with regard to his own body or to external objects) was preserved, orientation in space was markedly deranged. According to his own statement, he had been at first unable to orient himself in his native town. "I was really ashamed," he said, "Although the town was so familiar to me I was compelled constantly to ask the way. Once I addressed such a request to a passer-by in the street; on the way back I happened to address the same person with the same request. Naturally he was surprised and wondered whether I was drunk. I apologised and decided to find my way without assistance."

Experiment 11: This defect of orientation was investigated by A. Y. Kolodnaya. It was found that the patient was quite unable to draw routes or ground-plans. When trying to draw a scheme of his ward, he proved unable to represent the disposition of objects and was compelled to examine each individual object afresh to ascertain

its place in the ward. As a result, the simple task of drawing a scheme of the ward was fulfilled in the form of numerous separate observations and was in consequence extremely time-consuming. (On one occasion he took 40 minutes over the task, which involved turning the head or even the entire body 110 times.) It was also characteristic that the patient, when drawing the scheme with his back to the ward, represented it mirror-wise without appropriate transposition.

The principal defect underlying the loss of orientation thus appears to be a limitation of perception to one element and an inability to reflect the inter-connection of attributes in visual perception or imagination. This resulted in a syndrome close to that formerly described as "simultaneous agnosia."

VI. EFFECTS OF CAFFEINE ON VISUAL PERFORMANCE

Let us now attempt to approach this syndrome from the standpoint of Pavlovian neurodynamics.

If—as Pavlov assumed—a decline in tonus of the nervous processes in the affected visual cortex underlies this syndrome, it might be surmised that certain pharmacological agents, by affecting the general tonic state of the cortex, would produce alterations in the symptoms. The fact that only a relatively small part of the occipito-parietal area was wholly destroyed by the injury gave sufficient grounds to anticipate a positive result.

A series of experiments was carried out with injections of 10 per cent solution of caffeine (from 0.05 to 0.1 gramme). Control tests were carried out before and after the injections.

The experiments yielded distinctive results. The patient stated that all of a sudden everything appeared to him "in a brighter light" and he was able to accomplish in a new and direct way many tasks which normally gave him very considerable difficulty. These changes manifested themselves 15 to 20 minutes after the injection, and reached their maximum level in 30 to 35 minutes. Thereafter, they gradually declined, performance returning to the previous level after about one hour to one hour and a half.

(1) *Tachistoscopic perception of figures.*—Experiments of the kind described in Section II of this paper gave markedly different results 20 to 25 minutes after the injection of caffeine. In cases in which two simple figures were simultaneously exposed, perception of two figures was recorded in almost 50 per cent of exposures. A comparison of the findings with those obtained before and after the administration of caffeine is given in Table I. (In this Table, "incomplete" perception of the two figures refers to cases in which one figure alone was clearly perceived but the subject was aware that a second figure of some kind was also present.)

TABLE I.—SIMULTANEOUS PERCEPTION OF FIGURES BEFORE AND AFTER INJECTION OF CAFFEINE

Time of test	No. of combined exposures	Perception of one figure only	Perception of the figures	
			Complete	Incomplete
(1) Prior to administration of caffeine	30	25	0	5
(2) 25 min. after injection of caffeine	30	14	12	4
(3) 1 hour after injection of caffeine	30	20	2	6

(2) *Visual-motor co-ordination.*—Performance on simple tests of visual-motor co-ordination was much improved by injection of caffeine. It was found that the patient, 15 to 20 minutes after an injection, could place a dot accurately in the centre of a circle or bring his pencil-point accurately to the centre of a cross. Further, he was able to perform these tasks in a direct way, without resorting to his usual “round about” methods. The average time taken to execute these two tasks was markedly reduced.

(3) *Visual analysis of patterns.*—Similar results were obtained with tests of counting dots arranged to form simple and regular patterns. As a rule, the patient was quite unable to count five dots arranged in a simple pattern. But 20 minutes after the administration of caffeine he performed the task easily and quickly, the effect persisting for about an hour.

(4) *Plan-drawings.*—A striking improvement in the ability to draw plans or routes was likewise observed. The task was performed very much more quickly and the level of representation much improved. Head-turning was much reduced, e.g. from 110 to 8 turns. As in the earlier experiments, the best results were obtained 25 to 30 mins. after the administration of caffeine and the effects persisted for 1–2 hours.

These findings suggest that the occipito-parietal injury had been instrumental in reducing the tonus of excitation in the visual area of the cortex. Increasing the level of tonus by pharmacological means led to marked, if transient, improvement in visual and oculomotor capacity.

VII. SUMMARY AND CONCLUSIONS

A case is described in which marked derangements of visual perception and orientation occurred as *sequela* of a bilateral occipito-parietal brain-injury. It is argued that the key feature of the syndrome is the restriction of visual perception to a single object or configuration. This deficit can best be explained in terms of Pavlov's theory of cortical activity. According to this theory, there is a general functional weakness (or reduction in cortical tonus) of the affected portions of the brain. In

consequence, each focus of excitation within this area inhibits the remainder of the visual cortex by way of negative induction. If, therefore, a large number of stimuli are simultaneously presented, only very few are likely to elicit a perceptual response. The patient is in consequence likely to perceive only a restricted element or aspect of the total stimulus pattern.

It is probable that an explanation of this kind will cover many of the phenomena of visual agnosia described in the literature. In particular, "limitation of visual attention" (Holmes), "incapacity to combine details into a coherent whole" (Head) and "piecemeal perception" (Paterson and Zangwill) would appear as no more than psychological consequences of this basic neuro-physiological deficit.

At the same time, it appears unlikely that such an explanation, in its present form at least, will cover all aspects of agnosia, in particular those which appear to betray an ideational or conceptual origin, e.g. true topographical agnosia. The more adequate understanding of these syndromes in terms of changes at the neurophysiological level remains a task for future research.

REFERENCES

- BÁLINT, R. (1909) *M Schr. Psychiat. Neurol.*, **25**, 51.
 BAY, E. (1950) "Agnosie und Funktionswandel." Berlin.
 DENNY-BROWN, D., MEYER, J. S., and HORENSTEIN, S. (1952) *Brain*, **75**, 433.
 GELB, A., and GOLDSTEIN, K. (1920) "Psychologische Analysen hirnpathologischer Fälle." Leipzig.
 HEAD, H. (1926) "Aphasia and Kindred Disorders of Speech." Cambridge.
 HÉCAEN, H. and AJURIAGUERRA, J. DE (1954) *Brain*, **77**, 373.
 HOLMES, G. (1919) *Brit. med. J.*, **2**, 230.
 —, and HERRIX, G. (1919) *Arch. Neurol. Psychiat., Chicago*, **1**, 385.
 JANET, P. (1935) "Les débuts de l'intelligence." Paris.
 LISSAUER, H. (1890) *Arch. Psychiat. Nervenkr.*, **21**, 222.
 PATERSON, A., and ZANGWILL, O. L. (1944) *Brain*, **67**, 54.
 PAVLOV, I. P. (1955) "Selected Works." Moscow.
 WILBRANDT, M. (1887) "Die Seelenblindheit als Herderscheinung und ihre Beziehungen zur Alexie und Agraphie." Wiesbaden: Bergmann.
 WOLPERT, I. (1924) *Z. ges. Neurol. Psychiat.*, **93**, 397.