

Disseminated Leishmaniasis: A New and Emerging Form of Leishmaniasis Observed in Northeastern Brazil

Meredith L. Turetz,¹ Paulo R. Machado,³
 Albert I. Ko,^{1,4} Fábio Alves,⁵ Achiléa Bittencourt,³
 Roque P. Almeida,³ Niloufar Mobashery,^{1,2}
 Warren D. Johnson, Jr.,¹ and Edgar M. Carvalho³

¹*Division of International Medicine and Infectious Diseases, Weill Medical College, Cornell University, New York, New York;*
²*Department of Internal Medicine, University of Maryland, Baltimore;*
³*Serviço de Imunologia, Hospital Universitário Professor Edgard Santos, Universidade Federal da Bahia, and*
⁴*Centro de Pesquisas Gonçalo Moniz, Fundação Oswaldo Cruz, Salvador, Bahia,*
 and ⁵*Fundação Oswaldo Cruz, Rio de Janeiro, Brazil*

During the past decade, there has been an increase in the number of patients with disseminated leishmaniasis (DL), which is characterized by a large number of acneiform and papular skin lesions, with very few or no parasites in the skin tissue. The present report describes 42 cases of DL identified between 1992 and 1998 in an area where *Leishmania braziliensis* transmission is endemic; 8 of the patients were prospectively diagnosed. In a contrast to localized cutaneous leishmaniasis (LCL), acquisition of DL was associated with age >19 years ($P < .05$), male sex ($P < .05$), and agricultural occupation ($P < .001$). Patients with DL presented with 10–300 lesions that were a mixture of acneiform, papular, nodular, and ulcerated types. Twelve (29%) of 42 patients had mucosal involvement. Patients with DL had lower levels of interferon- γ ($P < .05$) and tumor necrosis factor- α ($P < .05$) production, compared with patients with LCL. DL is an emerging clinical distinct form of leishmaniasis associated with agricultural activities and host immunological response.

Disseminated leishmaniasis (DL) has been reported almost exclusively in northern and northeastern Brazil [1–3]. In Corte de Pedra, Bahia, Brazil, where leishmaniasis is endemic and where studies have been conducted for >35 years, DL is characterized by the appearance of multiple pleomorphic lesions in ≥ 2 noncontiguous areas of the body [1]. DL accounted for 0.2% of the total number of cases of cutaneous leishmaniasis (CL) in the early 1970s [4]. DL is distinct from classic CL, which is characterized, in most cases, by well-delimited ulcerated skin lesions with elevated borders. DL is also different from anergic diffuse cutaneous leishmaniasis (DCL) [5, 6]. We have noted elsewhere that the main differences between DCL and DL are the presence of multiple nonulcerative nodular lesions, a poor T cell response to leishmania antigen, and a high number of phagocytosed leishmania within macrophages found in DCL but not in DL [2]. DCL is rare disease entity, and no more than 1–2 cases are diagnosed in all of Brazil each year [7].

The reasons for the development of DL have not been established. Parasite, host, and environmental factors may favor the dissemination of the parasite through the body. Here, we describe an increase in the number of DL cases since the 1970s during ongoing ambulatory clinic-based surveillance in a region of northeastern Brazil where leishmaniasis is endemic. The patients analyzed in this case series allowed us to define demographic characteristics and identify high-risk population groups. In addition, clinical, parasitological, and immunological findings provide a preliminary characterization of this severe form of leishmaniasis.

Subjects and Methods

Epidemiological surveillance and data collection. Patients were identified at the Corte de Pedra Health Post, located in the southeastern region of the State of Bahia, Brazil. Ongoing clinical, epidemiological, and laboratory studies of CL and mucosal leishmaniasis have been performed in this area since 1975. The health post is the reference center for diagnosis and treatment of leishmaniasis for an area of ~ 7000 km² and a population of >500,000 people. At presentation to the health post, patients with suspicious cutaneous or mucosal lesions have a history taken and undergo physical examination and leishmanin skin test. The patient's medical record documents demographic and clinical data, including lesion size, location, and duration, as well as laboratory data and treatment. The lesions were marked and quantified according to body region. Ulcerated lesions were measured in their greatest diameter. Parasite isolation and histopathological studies are performed on a subgroup of patients for the purpose of diagnosis.

DL was identified according to a case definition of ≥ 10 mixed-

Received 29 May 2002; revised 19 August 2002; electronically published 19 November 2002.

This study was approved by the ethical committees of both Hospital Universitário Professor Edgard Santos and New York Presbyterian Hospital, and informed consent was obtained from all prospectively enrolled patients.

Financial support: National Institutes of Health (grants AI-30639 and TW 00919); Programa de Núcleos de Excelência, Brazil.

Reprints or correspondence: Dr. Edgar M. Carvalho, Serviço de Imunologia, Hospital Universitário Prof. Edgard Santos, Universidade Federal da Bahia, Rua João das Botas, s/n 40110-160, Salvador, Bahia, Brazil (edgar@ufba.br).

The Journal of Infectious Diseases 2002; 186:1829–34

© 2002 by the Infectious Diseases Society of America. All rights reserved.
 0022-1899/2002/18612-0018\$15.00

type lesions (e.g., acneiform, papular, nodular, and/or ulcerated), located in ≥ 2 body parts (head, trunk, arms, and legs). Laboratory-confirmed case patients were those with a positive skin test with leishmanial antigen or identification of *Leishmania* species in cultures or biopsy specimens. Localized cutaneous leishmaniasis (LCL) disease was defined as < 10 cutaneous lesions in any distribution or > 9 lesions localized to a single body part.

Patients with DL were identified retrospectively, between June 1992 and July 1998, through review of medical charts from all patients who received a diagnosis of leishmaniasis, and prospectively, from August through December 1998. A standardized entry form was used to extract the demographic, diagnostic, and clinical information from the records. Patients were excluded from the study if the number of lesions could not be ascertained ($n = 115$) or if disease was not diagnostically confirmed ($n = 8$).

Laboratory diagnosis. Leishmania skin test was performed as described elsewhere [8]. Induration of ≥ 5 mm was considered to be a positive result. Skin biopsies were performed with a 3-mm Baker's biopsy punch after local anesthesia with 2% lidocaine, and skin samples were fixed in buffered formol. A smear was defined as positive if parasites could be identified on the hematoxylin-eosin stained section. Lesion aspirates were performed and used to inoculate NNN blood agar overlaid with modified liver infusion tryptose broth [9]. Characterization of *Leishmania* species was done in paraffin-embedded tissue. In brief, the tissue block was cut in 6- μ m sections, deparaffinized in xylene, and washed with ethanol. Tissue DNA was isolated using a Qiamp kit (Qiagen). *Leishmania* minicircle DNA was amplified by polymerase chain reaction (PCR) using a pair of primers specific to the conserved region of the minicircle DNA (primer A, 5'-(G/C)(G/C)(C/G)CC(A/C)CTAT(A/T)TTACACCAACCCC-3' and primer B, 5'-GGGGTAGGGGCGTTCTGCGAA-3') and the following reaction conditions: 30 cycles of 94°C for 30 s, 50°C for 30 s, and 72°C for 30 s. After amplification, the DNA was transferred to nitrocellulose membrane and hybridized with a *Leishmania braziliensis*-specific probe labeled with 32 P- α -dCTP [10].

Treatment. All prospectively identified patients with DL were treated with pentavalent antimony (Sb^v; 20 mg/kg/day; Glucantime; Roche) for 20 days (for cutaneous lesions) or 30 days (for mucosal lesions). Patients were evaluated 60 days after they finished treatment, and all the patients who were not cured were retreated.

Determination of interferon (IFN)- γ , tumor necrosis factor (TNF)- α , interleukin (IL)-10, and IL-5. To evaluate the production of cytokines, peripheral blood mononuclear cells (PBMC) isolated in ficoll-hypaque gradient were adjusted to a concentration of 3×10^6 cells/mL in RPMI 1640 medium supplemented with 10% normal human AB serum and stimulated with 10 μ g/mL soluble leishmania antigen. After 72 h of incubation, supernatants were harvested, and a sandwich ELISA technique (Genzyme) was used to quantify the concentrations of IFN- γ , TNF- α , IL-10, and IL-5.

Statistical analysis. Epi-Info software (version 6.04; Centers for Disease Control and Prevention) was used to create a database and perform the data analyses. Categorical data were compared using the χ^2 test with Yates's correction or Fisher's exact test. Continuous data were compared using 1-way analysis of variance (ANOVA) or the Kruskal-Wallis test, except for analyses of cytokine data, which were compared using the Mann-Whitney *U* test. Results were considered to be significant if 2-tailed $P < .05$.

Results

Among 2206 patients with laboratory-confirmed cases of leishmaniasis identified between June 1992 and December 1998, 42 had clinical and diagnostic criteria for DL (34 retrospectively and 8 prospectively), and 2164 met the criteria for LCL (see Subjects and Methods). Of the 2164 patients with CL, 1483 (69%) had a single lesion, 678 (31%) had 2–9 lesions, and 3 (0.1%) had > 9 lesions confined to 1 body part. The overall prevalence of DL was 1.9% (42/2206 patients).

Demographics. Among the demographic characteristics evaluated, age > 19 years, male sex, and agricultural occupation were associated with an increased risk of DL (table 1). The mean (\pm SD) age of patients with DL was significantly greater than that of patients with CL (30 ± 16 vs. 25 ± 18 years, respectively; $P < .05$). Patients > 20 years old had an increased risk for acquiring DL (odds ratio [OR], 2.57; 95% confidence interval [CI], 1.25–5.70). Men comprised 79% of the patients with DL, compared with 62.2% of patients with CL ($P = .045$). Agriculture-related occupations were associated with increased risk for DL (OR, 3.59; 95% CI, 1.71–8.22), whereas students had a reduced risk for DL. During ambulatory clinic-based surveillance, seasonal variation of cases was not observed (data not shown). Furthermore, no municipalities or farm villages within municipalities were identified that had an increased risk for acquiring DL, compared with CL, which indicates a lack of geographical clustering of DL cases.

Clinical characteristics. The median number of lesions for the 42 patients with DL was 18 (range, 10–300 lesions), in contrast to a median of 1 lesion (range, 1–15 lesions) in patients with CL (table 2). Most patients with DL (23/42 [55%]) had widespread dissemination, with lesions identified in all body parts (legs, arms, trunk, and face) at the time of presentation. Seven (17%) and 4 (10%) patients had lesions distributed exclusively on the upper body (arms, trunk, and face) and legs

Table 1. Demographic characteristics of patients with disseminated leishmaniasis (DL) and other forms of cutaneous leishmaniasis (CL).

Characteristic	Patients with DL (n = 42)	Patients with CL (n = 2164)	OR (95% CI)	P
Age, years				
Mean \pm SD	30 \pm 16	25 \pm 18	—	—
≥ 20	31 (74)	1131 (52)	—	.013 ^a
< 20	11 (26)	1033 (48)	2.57 (1.25–5.70)	.009
Male sex	33 (79)	1347 (62)	2.22 (1.03–5.31)	.045
Occupation				
Agriculturist ^b	32 (76)	1020 (47)	3.59 (1.71–8.22)	$< .001$
Student ^c	5 (12)	643 (30)	0.32 (0.10–0.82)	.019

NOTE. Data are no. (%) of subjects, except where noted. Analysis of variance was used to determine significant differences between means. The χ^2 test was used to determine significant differences between proportions. CI, confidence interval; OR, odds ratio.

^a Determined by Kruskal-Wallis test.

^b All 32 agriculturists with DL were men.

^c Children < 5 years old were included in the student group because their risk of acquiring DL was thought to be similar to that of students.

and trunk, respectively. All patients with DL had lesions above the waistline, whereas 40% (870/2164) of the patients with LCL had lesions within this distribution ($P < .05$). Ulcerated lesions associated with DL were significantly larger than lesions associated with CL (mean diameter of largest lesion, 29.1 vs. 19.2 mm; $P = .002$). Patients with DL presented to the clinic later in the course of their illness than did patients with LCL (mean duration of lesions prior to outpatient evaluation, 9.0 vs. 7.2 weeks, $P = .002$). However, when analyses were limited to patients identified with duration of illness ≤ 9 weeks, the association between DL and increased lesion size remained significant ($P = .014$; table 2).

Twelve (28.6%) of the 42 patients with DL had concomitant mucosal involvement, compared with 25 (1.2%) of 2164 patients with CL. DL was strongly associated with mucosal disease (OR, 34.22; 95% CI, 14.18–78.28; $P < .001$). Patients with mucosal involvement in the 2 groups did not significantly differ regarding duration of cutaneous lesions or distribution of cutaneous lesions below or above the waist. In both groups, the nasal mucosa or septum was affected most frequently (67% for DL and 84% for CL; $P > .05$). All patients with DL with mucosal disease had head or neck involvement, compared with 11 (44%) of patients with CL with mucosal involvement ($P < .05$).

Prospectively identified patients. Eight patients with DL were prospectively identified; more complete information on clinical presentation and outcome were obtained from them. None of these patients had a history of previous leishmaniasis. They had 13–270 lesions and a mixture of lesion types (table 3). Two patients presented initially, during their first clinic visit, with <5 lesions and developed DL after initiation of pentavalent antimony treatment. Four patients recalled a prodrome of constitutional symptoms within the week before the appearance of the initial lesion ($n = 2$), during the dissemination phase of illness ($n = 1$), or during both periods ($n = 1$). During the prodromal phase, all patients had fever; 3 patients noted body aches, chills, and malaise; and 2 patients complained of headaches. No hepatosplenomegaly and no regional lymphadenopathy was detected by physical examination.

These patients recalled having a single, initial lesion prior to the onset of DL, which was distributed on the lower extremities

($n = 4$), trunk ($n = 2$), arms ($n = 1$) and face ($n = 1$). Patients reported that the initial lesion had been small and papular. However, by the time of the outpatient evaluation, the initial lesion became large (median diameter, 31.3 mm; range, 13–87.5 mm) and ulcerated. Appearance of multiple disseminated lesions followed 3 days to 8 weeks (mean, 2.6 ± 2.4 weeks) after identification of the initial lesion. Patients reported an abrupt onset of lesions during the dissemination phase, with a mixture of ulcerated, nodular, papular and acneiform lesions (figure 1). Two patients (25%) presented with mucosal involvement, 1 patient presented with nasal involvement only, and 1 presented with involvement of the labia, palate, pharynx, and nasal mucosa.

Patients were treated with Sb^v (20 mg/kg/day) for 20 or 30 days, depending on the absence or presence of mucosal involvement, respectively. None of these patients had previous antileishmanial therapy. Of the 8 patients, 4 were cured, defined as complete healing of all lesions and absence of new lesions, after 1 year of follow-up. Three of these patients received a single 20–30 day treatment course, whereas 1 patient required 3 courses. Of the 4 patients who were not cured, 3 demonstrated clinical response during retreatment but developed new lesions during the 1-year follow-up period. The majority of one patient's lesions healed, but this patient had several persisting ulcerated lesions.

Histopathological studies and parasite identification. The biopsy sections showed infiltration with plasma cells and granulomatous reaction. Amastigotes were identified in 5 histological sections of biopsy specimens: large numbers of parasites were found in 2 biopsy specimens of 10- and 60-day ulcers. PCR analysis of 7 specimens amplified *Leishmania* species DNA that was recognized by specific *L. braziliensis* probes.

Cytokine production. The cytokine secretion pattern of PBMC from 8 patients with DL was compared with those of 20 control patients with CL with single lesions (figure 2). Patients with DL produced both Th1 and Th2 cytokines. However, the mean (\pm SD) level of IFN- γ was significantly lower ($P < .05$) in patients with DL (1073 ± 433 pg/mL), compared with that in control patients with CL (2329 ± 1408 pg/mL). The TNF- α mean level in patients with DL (171 ± 301 pg/mL) was also significantly lower ($P = .01$), compared with that in

Table 2. Clinical characteristics of patients with disseminated leishmaniasis (DL) and classic cutaneous leishmaniasis (CL).

Characteristic	Patients with DL	Patients with CL	OR (95% CI)	P
Duration of lesion at presentation, mean weeks \pm SD (no. of patients)	9.0 \pm 7.6 (40)	7.2 \pm 17.8 (2125)	—	.002
No. of lesions, median (range) [no. of patients]	18 (10–300) [40]	1 (1–15) [2164]	—	<.001
Location of skin lesions, no. of patients with lesions/total no. of patients (%)				
Legs	33/42 (79)	1389/2029 (68)	1.86 (0.86–4.43)	.14
Arms	34/42 (81)	441/2029 (22)	15.91 (7.15–40.01)	<.001
Trunk	42/42 (100)	295/2029 (15)	—	<.001
Face	34/42 (81)	289/2029 (14)	26.51 (11.86–66.80)	<.001
Diameter of largest ulcerated lesion, mean mm \pm SD (no. of patients)	29.1 \pm 19.7 (31)	19.2 \pm 10.7 (2050)	—	.002
Diameter of lesions for illness of ≤ 9 weeks duration, mean mm \pm SD (no. of patients)	25.6 \pm 15.71 (24)	18.3 \pm 10 (1689)	—	.014
Diameter of lesions for illness of >9 weeks duration, mean mm \pm SD (no. of patients)	41.3 \pm 27.9 (7)	23.5 \pm 13 (328)	—	.058
Mucosal involvement, no. of patients/total no. of patients (%)	12/42 (28.6)	25/2164 (1.2)	25 (14.18–78.28)	<.001

NOTE. P values were determined by analysis of variance and Fisher's exact test. CI, confidence interval; OR, odds ratio.

Table 3. Clinical characteristics of prospectively identified patients with disseminated leishmaniasis.

Patient	Age, years	Prodrome ^a	Location of initial lesion	Weeks until dissemination ^b	Lesions			Mucosal involvement
					Total no.	Ulcerated, no. (%)	Papular, no. (%)	
1 ^c	71	No	Face	3	17	16 (94)	1 (6)	Yes
2	31	Yes	Trunk	2	185	6 (3)	179 (97)	No
3	43	Yes	Trunk	2	13	3 (23)	10 (77)	No
4	35	No	Leg	2	114	9 (8)	105 (92)	No
5	24	Yes	Leg	3	44	22 (50)	22 (50)	No
6 ^c	65	No	Leg	1	15	8 (53)	7 (47)	No
7	21	No	Leg	8	37	25 (68)	8 (22)	Yes
8	17	Yes	Arm	<1	270	6 (2.2)	264 (98)	No

NOTE. All patients were men.

^a Constitutional symptoms during the prodrome phase of illness included fever, chills, malaise, and body aches.

^b Period between recognition of initial lesion and the appearance of subsequent multiple, disseminated lesions.

^c Patients who developed disseminated disease after initiation of treatment with pentavalent antimony for the initial localized lesion.

control patients (751 ± 749 pg/mL). Although patients with DL produced more IL-5 (32 ± 35 pg/mL) and IL-10 (84 ± 80.8 pg/mL) than did control patients with CL (18 ± 26 pg/mL and 55 ± 56 pg/mL, respectively), these differences were not significant ($P > .05$).

Discussion

Our previous study performed in this area in northeastern Brazil, where tegumentary leishmaniasis is endemic, showed that DL was a rare disease form, responsible for 0.2% (2/958) of the cases of all CL identified from 1978 to 1984 [4]. In the present study, surveillance from 1992 to 1998 shows that DL now accounts for 1.9% (42/2206) of cases of CL, indicating that it has become an emerging form of leishmaniasis. This study provides epidemiological, clinical, and immunological data of patients with DL.

The presentation of multiple lesions (>10) of different mor-

phological types makes DL a unique clinical entity of leishmaniasis. Furthermore, >25% of patients with DL had concomitant mucosal disease, developing simultaneously with the disseminated skin manifestations. Classic mucosal leishmaniasis has been described to occur in ~3% of patients with a history of CL and typically presents months to years after the appearance of the initial cutaneous infection [4].

It is important to distinguish DL from CL with multiple lesions. Patients with the latter disease entity have ulcerated lesions that usually appear at different times during the course of illness. Although patients with DL present with an initial, isolated ulcer, they subsequently develop up to hundreds of lesions of mixed acneiform, nodular, papular, and ulcerated types within a period of several days. As noted in the introduction, there is a clear difference with respect to the clinical, histopathological, and immunological aspects between DL and DCL [2]. Furthermore, DL is distinct from the presentation of CL in human immunodeficiency virus (HIV)-infected patients [11, 12], which is com-

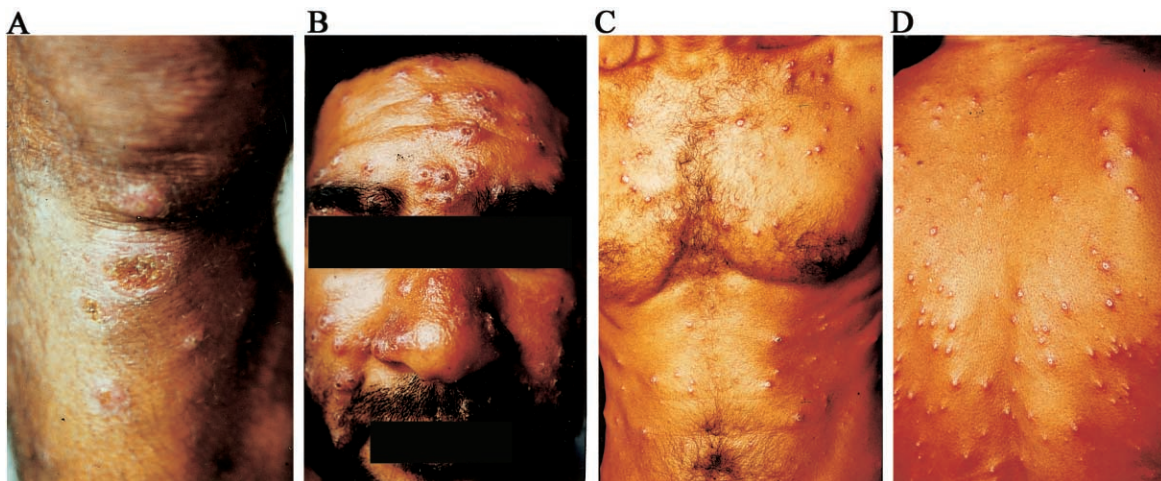


Figure 1. Multiple mixed type of lesions in a patient with disseminated leishmaniasis. *A*, An initial lesion (ulcerated) in the right leg surrounded by papular lesions. *B*, Exuberant papular lesions with central crust in the face. *C* and *D*, Anterior and posterior chest with acneiform lesions.

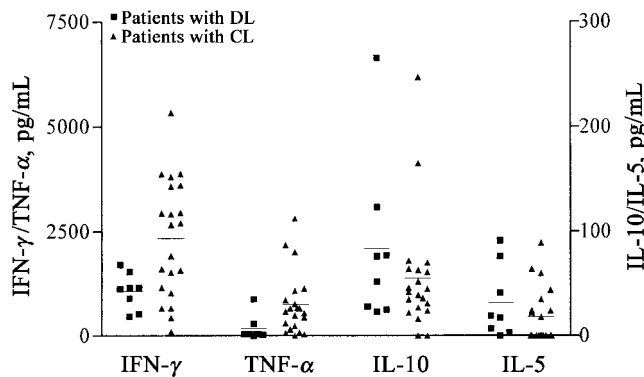


Figure 2. Cytokine levels in prospective patients with disseminated leishmaniasis (DL), compared with levels in patients with classic cutaneous leishmaniasis (CL) with single lesions. IL, interleukin; IFN, interferon; TNF, tumor necrosis factor.

monly associated with multiple lesions. HIV infection has not been reported in this area of endemicity, and all 8 prospectively-identified patients from our study had negative HIV tests results.

The rapid dissemination of lesions to all parts of the skin, as well as to the mucosa, and the frequent history of prodromal manifestations, such as fever, chills, and malaise, support the hypothesis that these manifestations are produced by spread of *Leishmania* species via the bloodstream. A combination of host, parasite and exposure factors may be responsible for this new emerging clinical disease form. PBMC of patients with DL produce lower levels of IFN- γ and TNF- α and increased levels of IL-10, compared with PBMC from control patients with CL. It has been well established that Th1 cytokines (IFN- γ , IL-2, and TNF- α) are responsible for protective responses to *Leishmania* species infection, whereas Th2 cytokines (IL-4, IL-5, and IL-10) promote disease exacerbation [13]. Together, these findings suggest that the type of host immune response may predispose progression to the DL disease form after infection. Adult males and agricultural workers have significantly greater risk for acquiring DL, suggesting that exposure to the parasite occurred during work in plantation fields and forested areas. Therefore, parasite-and/or vector-associated factors, in addition to host factors, may be possible determinants for the development of this atypical form of leishmaniasis. In addition, the link of DL to exposure to occupational products should be studied.

In the present study, *L. braziliensis*, the principal cause of classic CL in this region, was the etiologic agent for DL in 7 cases in which parasites were isolated and typed. Strain-specific differences may influence the development of dissemination after infection. Antigenic variation between strains has been proposed as a potential mechanism to explain the differing clinical features of leishmaniasis, as well as the T cell responses and cytokine profiles induced during infection [14, 15]. Future studies are needed to determine whether molecular and/or pheno-

typical typing methods can distinguish isolates that cause DL from those that cause classic CL.

Pentavalent antimony is the most widely used drug to treat CL. In this study, cure was defined as complete healing of lesions 60 days after the end of the therapy, without reactivation or the appearance of new lesion during 1 year of follow-up. More than 80% of patients with CL have successful responses and are cured with standard antimony treatment in this area where leishmaniasis is endemic [16]. In contrast, <40% of the prospectively identified patients with DL had their lesions cured with a single course of treatment. Because of the high frequency (>25%) of concomitant mucosal involvement, patients with DL should receive a thorough otolaryngology examination. Furthermore, the high rate of therapeutic failure strongly suggests that patients with DL should be treated for longer periods (30 days) of standard therapy and carefully monitored.

References

- Costa JM, Marsden PD, Llanos-Cuentas EA, et al. Disseminated cutaneous leishmaniasis in a field clinic in Bahia, Brazil: a report of eight cases. *J Trop Med Hyg* 1986;89:319–23.
- Carvalho EM, Barral A, Costa JM, Bittencourt A, Marsden P. Clinical and immunological aspects of disseminated cutaneous leishmaniasis. *Acta Tropica* 1994;56:315–25.
- Galvão CE, Silva AC, Saldanha AC, Silva CM, Costa MR, Costa JM. Disseminated cutaneous leishmaniasis due to *Leishmania Viannia braziliensis* in the state of Maranhão, Brazil. *Rev Soc Bras Med Trop* 1993;26:121–3.
- Jones TC, Johnson WD Jr, Barreto AC, et al. Epidemiology of American cutaneous leishmaniasis due to *Leishmania braziliensis braziliensis*. *J Infect Dis* 1987;156:73–83.
- Convit J, Pinardi ME, Rondon AJ. Diffuse cutaneous leishmaniasis: a disease due to an immunological defect of the host. *Trans R Soc Trop Med Hyg* 1972;66:603–10.
- Bittencourt AL, Barral A, Costa JM. Tegumentary leishmaniasis in childhood. *Pediatr Dermatol* 1996;13:455–63.
- Lainson R. The American leishmaniases: some observations on their ecology and epidemiology. *Trans R Soc Trop Med Hyg* 1983;77:569–96.
- Reed SG, Badaró R, Masur H, et al. Selection of a specific skin test antigen for American visceral leishmaniasis. *Am J Trop Med Hyg* 1986;35:79–85.
- Romero GAS, Sampaio RNR, Macedo VO, Marsden PD. Sensitivity of a vacuum aspiratory culture technique for diagnosis of localized cutaneous leishmaniasis in an endemic area of *Leishmania (Viannia) braziliensis* transmission. *Mem Inst Oswaldo Cruz* 1999;94:505–8.
- Fernandes O, Catanho MP, Segura I, et al. Minicircle variable region probes for characterization of *Leishmania (Viannia)* species. *J Parasitol* 1999;85:563–8.
- Machado ES, Braga MP, Da Cruz AM, et al. Disseminated American mucocutaneous leishmaniasis caused by *Leishmania b. braziliensis* in a patient with AIDS: a case report. *Mem Inst Oswaldo Cruz* 1992;87:487–92.
- Agostini C, Dorigoni N, Malfitano A, et al. Mediterranean leishmaniasis in HIV-infected patients: epidemiological, clinical and diagnostic features of 22 cases. *Infection* 1998;26:93–9.
- Heinzel FP, Sadick MD, Mutha SS, Locksley RM. Production of interferon- γ , interleukin-2, interleukin-4, and interleukin-10 by CD4⁺ lymphocytes in vivo during healing and progressive murine leishmaniasis. *Proc Natl Acad Sci USA* 1991;88:7011–5.

14. Akuffo H, Maasho K, Blostedt M, Højeberg B, Britton S, Bakhiet M. *Leishmania aethiopica* derived from diffuse leishmaniasis patients preferentially induce mRNA for interleukin-10 while those from localized leishmaniasis patients induce interferon- γ . *J Infect Dis* **1997**;175:737–41.
15. Almeida RP, Barral-Netto M, De Jesus AMR, De Freitas LAR, Carvalho EM, Barral A. Biological behavior of *Leishmania amazonensis* isolated from humans with cutaneous, mucosal, or visceral leishmaniasis in BALB/c mice. *Am J Trop Med Hyg* **1996**;54:178–84.
16. Correia D, Macêdo VO, Carvalho EM, et al. Estudo comparativo entre antimoniato de meglumina, isotianato de pentamidina e sulfato de aminosidine, no tratamento de lesões cutâneas primárias causadas por *Leishmania (viannia) braziliensis*. *Rev Soc Bras Med Trop* **1996**;29:447–53.