

## CASE REPORT

### DISSEMINATED TOXOPLASMOSIS IN AN IMMUNOCOMPETENT PATIENT FROM PERUVIAN AMAZON

Juan NUNURA(1), Tania VÁSQUEZ(2), Sergio ENDO(2), Daniela SALAZAR(2), Alejandrina RODRIGUEZ(2), Sonia PEREYRA(3) & HILDA SOLIS(4)

#### SUMMARY

We report a case of severe toxoplasmosis in an immunocompetent patient, characterized by pneumonia, retinochoroiditis, hepatitis and myositis. Diagnosis was confirmed by serology, *T. gondii* in thick blood smear and presence of bradyzoites in muscle biopsy. Treatment with pyrimethamine plus sulfadoxine was successful but visual acuity and hip extension were partially recovered. This is the first case report of severe toxoplasmosis in an immunocompetent patient from Peru.

**KEYWORDS:** Disseminated toxoplasmosis; Immunocompetent; Peru.

#### INTRODUCTION

Toxoplasmosis has decreased in the last decades due to a greater control of its transmission patterns<sup>37</sup>. However, it is still common in tropical regions like the Amazon. In India, 2% of the population is seropositive, whereas in Brazil seroprevalence ranges from 65.8% to 75%. By the 1980s, 84% of the people in the Peruvian Amazon were seropositive<sup>2,16,26,28</sup>.

*T. gondii* infection varies according to the patient's immune status. It is mostly asymptomatic among immunocompetent patients. Clinical manifestations such as pneumonia myocarditis, hepatitis and encephalitis are rarely reported. On the contrary, life threatening encephalitis, pneumonitis and multiorgan involvement is frequently developed in immunocompromised patients<sup>5,8,28</sup>.

#### CASE REPORT

Our patient is a previously healthy 37 year old male marine. He was on a military operation by the Putumayo River (Peruvian Amazon) for the last four months. He also cooked for the brigade, drank stream water, ate undercooked meat and had three cats. He specified that the brigade hunted mostly mammals (tapirs, peccaries) and ate fish. This patient was hospitalized in Iquitos because of pain in the right hip, with limping. He was prescribed pain relievers and rest. During the fifth day of hospitalization he developed fever, dyspnea and decreased visual acuity. He was referred to the Peruvian Navy Hospital (Lima, Peru). Clinical examination revealed tachypnea, mild jaundice, left palpebral ptosis, rales in the two lower thirds of the left hemithorax. There was no adenopathy. His white cell count was 20,900 cells/ $\mu$ L (granulocytes

83%, 4% rods, lymphocytes 10%), direct bilirubin 1.41 mg/dL, alanine aminotransferase (ALT) 168U/L, aspartate aminotransferase (AST) 335 U/L. Chest X ray showed a diffuse interstitial infiltrate. Chest computed tomography (CT) showed multiple nodular cavities and pleural effusion. (Fig. 1) Bronchoalveolar lavage (BAL) showed gram positive cocci but culture grew panresistant *Pseudomonas aeruginosa*. No other bacteria, fungi or acid fast bacilli were cultured either from sputum, BAL, thoracocentesis or blood samples. No bacteria were isolated with Ziehl Neelsen stain. The left fundoscopic examination revealed

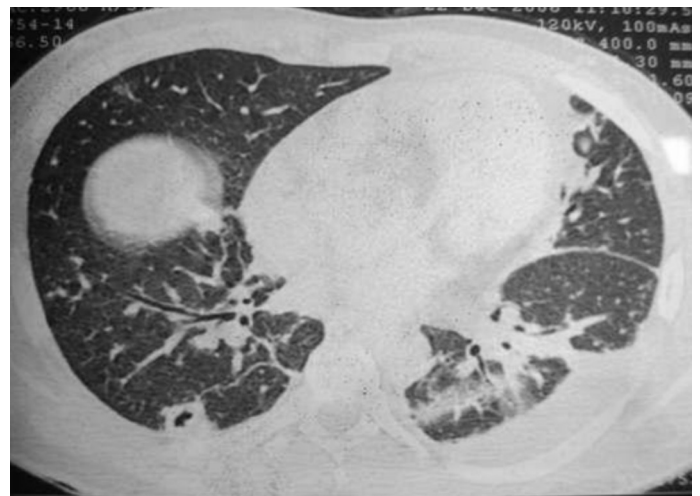


Fig. 1 - Chest CT scan: Nodular lesion and cavity in the right hemithorax and left pleural effusion.

(1) Dirección General de Epidemiología, Ministerio de Salud, Av. Salaverry s/n, Lima 11, Perú.

(2) Sociedad Científica de San Fernando, Escuela de Medicina Humana, Universidad Nacional Mayor de San Marcos, Av. Grau 755, Lima 01, Perú. E-mails: tanny\_82@hotmail.com, robarobado@hotmail.com, alexita21@hotmail.com, corina\_rf20@hotmail.com.

(3) Instituto Nacional de Salud del Niño, Departamento de Patología, Av. Brasil N° 600, Lima 05, Perú. E-mail: spereyra\_18@hotmail.com

(4) Instituto de Medicina Tropical, Universidad Nacional Mayor de San Marcos, Lima, Perú. E-mail: hildamarias3@hotmail.com

**Correspondence to:** Juan M. Nunura. E-mail: jnunura@dge.gob.pe

a foggy pattern in the medial inferior macula and retinal hemorrhage. This finding was identified as *Toxoplasma retinochoroiditis*. Repeated serological testing for rheumatoid factor, ANCA, HIV, leptospirosis, aspergillus, histoplasmosis, HTLV I - II, Cytomegalovirus, Epstein Barr Virus, Hepatitis B virus and thick blood smear for malaria were repeatedly negative. Treatment with Ceftriaxone, Clarithromycin plus Cothrimoxazol and Clindamycin were started but the former two were changed on the 5<sup>th</sup> day for Imipenem and Vancomycin. However his fever, dyspnea and dry cough persisted. On the 15<sup>th</sup> day of his hospital stay, *T. gondii* serology results were received: IgG 40.8 UI/mL; IgM 1.4 UI/mL (positive if: IgM  $\geq$  1.0 UI/mL; IgG  $\geq$  1.0 UI/mL). A thick blood smear showed tachyzoites of *T. gondii* (+++) (Fig 2). Sulfadoxine plus Pyrimethamine (Fansidar<sup>®</sup>) were started. Clindamycin and Cothrimoxazol were discontinued. Patient became afebrile on the second day of this treatment. Right hip MRI showed avascular necrosis and mild synovial effusion. Right hip biopsy showed *T. gondii* bradyzoites (Fig. 3, Fig. 4). Ig E levels were increased over six months (IgE: 2000 UI/mL). *T. gondii* PCR-based assay and IgM titers in blood samples were negative one year after treatment (Fig. 5). The patient only achieved partial recovery from his chorioretinitis and right hip disability.

## DISCUSSION

Consumption of stream water contaminated by oocysts and game

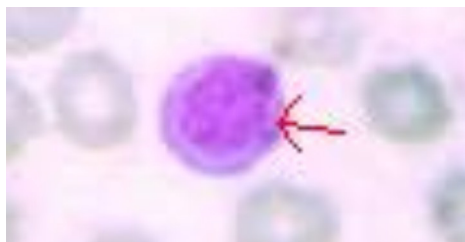

Fig. 2 - Tachyzoites are observed on thick blood smear. 100x

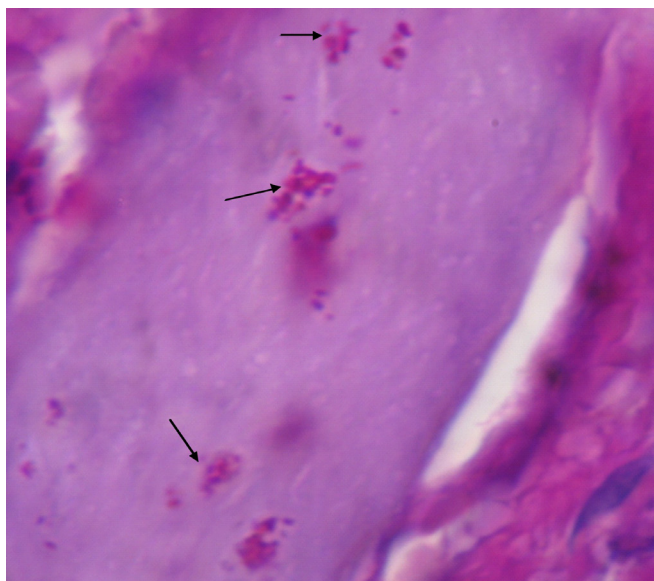


Fig. 3 - Right hip biopsy: hyaline degeneration of striated muscle fibers, absence of grooves and presence of multiple *T. gondii* cysts. (Arrows) PAS stain. 40x

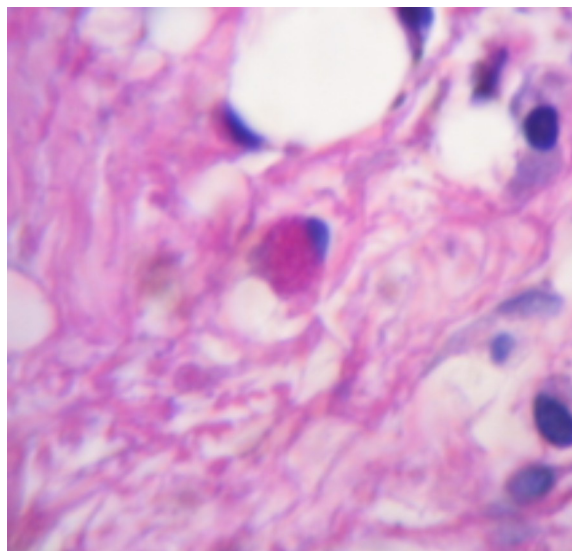


Fig. 4 - Right hip biopsy: increased volume of muscle fibers due to hyaline degeneration and edema. Cyst containing multiple bradyzoites is shown in the center of the picture. PAS stain, 100x

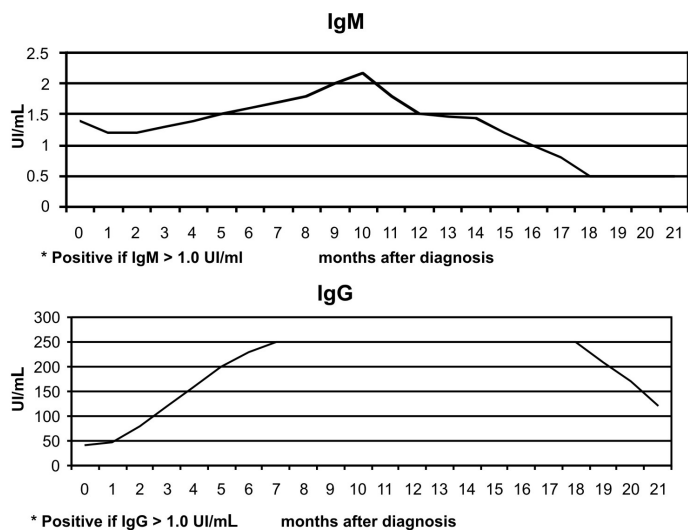


Fig. 5 - Serological follow-up: IgM and IgG in *T. gondii* reinfection.

meat are the most important risk factors contributing to the predominance of *T. gondii* wild cycle, especially in French Guyana<sup>6</sup>. Presence of felines or other infected animals are the main risk factors for food and water contamination<sup>35</sup>. Isolation of an atypical *T. gondii* strain in a wild jaguar supports the existence of a *T. gondii* wild cycle in the Amazon<sup>11</sup>. Waterborne outbreaks due to contamination with *T. gondii* oocysts have also been described<sup>1,4</sup>. Moreover, this type of transmission is associated with more severe clinical outcomes<sup>22</sup>.

On the other hand, people that participate in military operations do so under poor sanitary conditions and are exposed to biological factors in the new tropical environment<sup>10</sup>. Infection is the result of poor host adaptation to new strains. Thus, people who have been recently exposed to virgin forest are prone to developing the severe form of the disease.

However, our patient was the only case reported from that brigade. His main risk factor was cooking and manipulating game meat. Thus, he developed a wildlife cycle. Unfortunately, since he was in the jungle for a military operation and frequently exposed to risk factors, it is difficult for us to determine the incubation period.

*T. gondii* strains from South America have atypical genotypes and higher diversity compared to the ones formerly described in North America and Europe. These atypical strains have been associated with a worse clinical involvement and outcome in mice and humans<sup>7,25,32</sup>. Cases of severe toxoplasmosis in immunocompetent patients reported in French Guyana, Brazil and Surinam suggest that atypical strains of *T. gondii* might induce an increased pathogenicity<sup>5,24</sup>. Severe cases of toxoplasmosis have been previously reported in French Guyana, Surinam and Brazil<sup>5,11,24</sup>. Patients commonly develop a generalized infectious syndrome with visceral involvement such as mild hepatitis, jaundice, atypical pneumonia, enlarged lymph nodes and less frequently, myositis and chorioretinitis<sup>5,14</sup>. Our patient developed an atypical pneumonia with cavities and pleural effusion. However, interstitial pneumonia is the most frequent pulmonary manifestation<sup>5,9,24,34</sup>.

Even though *Pseudomonas aeruginosa* is a cause of necrotizing pneumonia, its isolation in this case is due to contamination. First, some reports describe hospital pseudo-outbreaks of *P. aeruginosa* pneumonia linked to the use of ventilators and other related instruments<sup>12,36</sup>. Second, sputum and blood culture results were negative on different occasions. Finally, despite panresistant *Pseudomonas* not having been related to an increased mortality<sup>18</sup> our patient showed clinical improvement only after his second day of first line antiprotozoal therapy.

Ocular toxoplasmosis is the most common cause of posterior uveitis in immunocompetent subjects. The lesions reported in our case are classified as severe and are mostly caused by *T. gondii* serotype I, which is less sensitive to therapy with Pyrimethamin *in vitro*<sup>3,20,33</sup>. Musculoskeletal involvement concomitant to *T. gondii* infection in immunocompetent patients is described as a proximal and symmetrical myositis<sup>29,31</sup>; in contrast to the focal and asymmetrical involvement (right thigh) reported hereby. Although trauma is a frequent cause of avascular necrosis, the antiangiogenic state triggered by *T. gondii* impairs healing and is an aggravating factor for this condition<sup>21,38</sup>. Slow and partial recovery from right hip articulation disability can also be explained by axonolysis, and an altered immune response<sup>38</sup>. Relapses have been reported even after receiving first line antiprotozoal treatment, because it does not eliminate bradyzoites and in other cases because of long corticosteroid therapy<sup>29</sup>.

Toxoplasmosis is very frequent in South America; indeed 84% of the inhabitants of the Peruvian Amazon are infected. Even though we do not have a baseline serology for our patient we treated his clinical scenario as if it were a reinfection by *T. gondii*. Our patient's IgM, IgG and IgE curves during his hospitalization support our diagnosis<sup>17,28</sup>. In 2006, DZITKO *et al.* describe slightly increased IgM and moderately increased IgG levels after inoculating a virulent strain to chronically infected mice<sup>15</sup>. In other words, as our patient was previously exposed, his IgM levels did not increase as much as his IgG levels. It is also known that *T. gondii* is an intracellular parasite that induces a humoral response. In this way, IgE plays a fundamental role in antibody-dependent cellular cytotoxicity (ADCC). IgE levels are increased during the first five months following infection. It has a high specificity (91.7%) for acute *T. gondii*

infection when measured with other markers of infection (IgG) and has the best association with clinical findings<sup>23,27</sup>.

Diagnosis of *T. gondii* re-infection in this case is based on *T. gondii* isolation on thick blood smear and hip biopsy, serology results, typical retinochoroiditis and effective antiprotozoal treatment in the absence of the most common causes of infectious syndrome with visceral involvement and immunodeficiency.

Hereby, this is the first time a severe case of disseminated toxoplasmosis in an immunocompetent adult from Peru is reported. Even though toxoplasmosis is not the most common cause of pneumonia in Peru, we recommend keeping it as a differential diagnosis in people coming from endemic areas like the Amazon, especially military recruits. Due to constant human migration to our tropical rainforest it is also important to identify risk population.

We hypothesize that *T. gondii* serotypes from the Peruvian Amazon could share the same atypical strains and disease patterns as the ones found in Brazil and French Guyana. We encourage further research on Amazonian *T. gondii* wild cycle, in this way we would improve knowledge of its distribution, disease patterns and prevention in the Amazon Basin.

## RESUMEN

### Toxoplasmosis diseminada en un paciente inmunocompetente procedente de la Amazonía peruana

Reportamos un caso de toxoplasmosis severa en un paciente inmunocompetente caracterizado por neumonía, retinocoroiditis, hepatitis y miositis. El diagnóstico fue confirmado por serología, el hallazgo de *T. gondii* en gota gruesa y la presencia de bradizoitos en biopsia muscular. El tratamiento con pirimetamina mas sulfadoxina fue exitoso pero solo hubo una parcial recuperación de la agudeza visual y de la capacidad de extensión de la cadera. Este es el primer reporte de un caso de toxoplasmosis severa en el Perú.

## ACKNOWLEDGMENTS

We would like to thank to the Infectious Diseases Department of the Peruvian Navy Hospital and also Dra. Hilda Solis and Dra. Pereyra for contributing with their experience in isolating *T. gondii* in thick blood smear and muscle biopsies, respectively.

Disclaimer: The authors disclosed no conflict of interest.

## REFERENCES

1. Bahia-Oliveira LM, Jones JL, Azevedo-Silva J, Alves CC, Oréfice F, Addiss DG. Highly endemic, waterborne toxoplasmosis in north Rio de Janeiro State, Brazil. *Emerg Infect Dis*. 2003;9:55-62.
2. Boia M, Carvalho-Costa F, Sodre F, Pinto G, Amendoeira M. Seroprevalence of *Toxoplasma gondii* infection among indian people living in Lauareté, São Gabriel da Cachoeira, Amazonas, Brazil. *Rev Inst Med Trop Sao Paulo*. 2008;50:17-20.
3. Bonfioli A, Orefice F. Toxoplasmosis. *Semin Ophthalmol*. 2005;20:129-41.
4. Bowie WR, King AS, Werker DH, Isaac-Renton JL, Bell A, Eng SB, *et al.* Outbreak of toxoplasmosis associated with municipal drinking water. The BC Toxoplasma Investigation Team. *Lancet*. 1997;350(9072):173-7.

5. Carme B, Bissuel D, Ajzenberg R, *et al.* - Severe acquired toxoplasmosis in immunocompetent adult patients in French Guiana. *J Clin Microbiol.* 2002;40:4037-44.
6. Carme B, Demar M, Ajzenberg D, Dardé ML. Severe acquired toxoplasmosis caused by wild cycle of *Toxoplasma gondii*, French Guiana. *Emerg Infect Dis.* 2009;15: 656-8.
7. Darde ML. *Toxoplasma gondii*, "new" genotypes and virulence. *Parasite.* 2008;15:366-71.
8. Darde M, Villena I, Pinon J, Beguinot, I. Severe acute disseminated toxoplasmosis. *Lancet.* 2004;364:579.
9. De Salvador-Guillouët F, Ajzenberg D, Chaillou-Opitz S, Saint-Paul MC, Dunais, B, Dellamonica P, *et al.* Severe pneumonia during primary infection with an atypical strain of *Toxoplasma gondii* in an immunocompetent young man. *J Infect.* 2006;53:e47-e50.
10. Debord T, Eono P, Rey JL, Roué R. Infectious hazards in military personnel in operations. *Med Mal Infect.* 1996;26(suppl 3):402-7.
11. Demar M, Ajzenberg D, Serrurier B, Dardé ML, Carme B. Atypical *Toxoplasma gondii* strain from a free-living jaguar (*Panthera onca*) in French Guiana. *Am J Trop Med Hyg.* 2008;78:195-7.
12. Diaz Granados CA, Jones MY, Kongphet-Tran T, White N, Shapiro M, Wang YF, *et al.* Outbreak of *Pseudomonas aeruginosa* infection associated with contamination of a flexible bronchoscope. *Infect Control Hosp Epidemiol.*, 2009;30:550-5.
13. Diaz-Suarez O, Estevez J. Seroepidemiology of toxoplasmosis in women of childbearing age from a marginal community of Maracaibo, Venezuela. *Rev Inst Med Trop Sao Paulo.* 2009;51:13-7.
14. Dogan N, Kabukcuoglu S, Vardareli E. Toxoplasmic hepatitis in an immunocompetent patient. *Türk Parazitol Dergisi.* 2007;31: 260-3.
15. Dzitko K, Staccek P, Gatkowska J, Dlugonska H. *Toxoplasma gondii*: serological recognition of reinfection. *Exp Parasitol.* 2006;112: 134-7
16. Ferreira MU, Hiramoto, RM.; Aureliano DP, da Silva Nunes M, da Silva NS, Malafrente RS, *et al.* A community-based survey of human toxoplasmosis in rural Amazonia: seroprevalence, seroconversion rate, and associated risk factors. *Am J Trop Med Hyg.* 2009;81:171-6.
17. Gross U, Holpert M, Goebel S. Impact of stage differentiation on diagnosis of toxoplasmosis. *Ann Ist Super Sanità.* 2004;40:65-70.
18. Hatchette T, Gupta R, Marrie T. *Pseudomonas aeruginosa* community-acquired pneumonia in previously healthy adults: case report and review of the literature. *Clin Infect Dis.* 2000;31:1349-56.
19. Hassene A, Vital A, Anghel A, Guez S. Acute acquired toxoplasmosis presenting as polyomyositis and chorioretinitis in immunocompetent patient. *Joint Bone Spine.* 2008;75:603-5.
20. Holland, G. Ocular toxoplasmosis: a global reassessment. Part II: Disease manifestation and management. *Am J Ophthalmol.* 2004;137:1-17.
21. Hunter C, Yu D, Gee M, Hgo CV, Sevignani C, Goldschmidt M, *et al.* Cutting edge: systemic inhibition of angiogenesis underlies resistance to tumors during acute toxoplasmosis. *J Immunol.* 2001;166:5878-81.
22. Jones JL, Dubey J.P. Waterborne toxoplasmosis: recent developments. *Exp Parasitol.* 2010;124:10-25.
23. Kodym P, Machala L, Roháčová H, Sirocka B, Maly M. Evaluation of a commercial IgE ELISA in comparison with IgA and IgM ELISAs, IgG avidity assay and complement fixation for the diagnosis of acute toxoplasmosis. *Clin Microbiol Infect.* 2007;13:40-7.
24. Leal F, Cavazzana C, Franco De Andrade H, Galisteo AJ Jr, de Mendonça JS, Kallas EG. *Toxoplasma gondii* pneumonia in immunocompetent subjects: case report and review. *Clin Infect Dis.*, 2007;44:e62-6.
25. Lehmann T, Marcet PL, Graham DH, Dahl ER, Dubey JP. Globalization and the population structure of *Toxoplasma gondii*. *Proc Natl Acad Sci USA.* 2006;103:11423-8.
26. Maguiña C, Gotuzzo E, Alvarez H, Carcelen A, Irrivaren J, Soto J, *et al.* Toxoplasmosis en Bartonellosis humana. *Rev Med Hered.* 1998;9:14-20.
27. Matowicka-Karna J, Dymicka-Piekarska V, Kemonan H. Does *Toxoplasma gondii* infection affect the levels of IgE and cytokines (IL-5, IL-6, IL-10, IL-12, and TNF-alpha)? *Clin Dev Immunol.* 2009;374696. Epub 2009 May 25.
28. Montoya J, Liesenfeld O. Toxoplasmosis. *Lancet.* 2004;363:1965-76.
29. Montoya J, Jordan R, Lingamneni S, Berry G, Remington J. Toxoplasmic myocarditis and polyomyositis in patients with acute acquired toxoplasmosis diagnosed during life. *Clin Infect Dis.* 1997;24:676-83.
30. Nancy FCC. Bacterial, fungal, parasitic, and viral myositis. *Clin Microbiol Rev.* 2008;21:473-94.
31. Paspalaki P, Mihailidou E, Bitsori M, Tsagkarani D, Mantzouranis E. Polyomyositis and myocarditis associated with acquired toxoplasmosis in an immunocompetent girl. *BMC Musculoskelet Disord.* 2001;2:8.
32. Pena HF, Gennari SM, Dubey JP, Su C. Population structure and mouse-virulence of *Toxoplasma gondii* in Brazil. *Int J Parasitol.*, 2008;38:561-9.
33. Pleyer U, Torun N, Liesenfeld O. Ocular toxoplasmosis. *Ophthalmologie.* 2007;104:603-15.
34. Pomeroy C, Filice GA. Pulmonary toxoplasmosis: a review. *Clin Infect Dis.* 1992;14:863-70.
35. Santos TR, Costa AJ, Toniollo GH, Luvizotto MC, Benetti AH, Santos RR, *et al.* Prevalence of anti-*Toxoplasma gondii* antibodies in dairy cattle, dogs, and humans from the Jauru micro-region, Mato Grosso State, Brazil. *Vet Parasitol.* 2009;161:324-6.
36. Srinivasan A, Wolfenden L, Song X, Mackie K, Hartsell TL, Jones HD, *et al.* An Outbreak of *Pseudomonas aeruginosa* infections associated with flexible bronchoscopes. *N Engl J Med.* 2003;348: 221-7.
37. Tenter A, Heckeroth A, Weiss L. *Toxoplasma gondii*: from animals to humans. *Int J Parasitol.*, 2000;30:1217-58.
38. Tonino P, Finol HJ, Marquez A. Skeletal muscle pathology in mice experimentally infected with *Toxoplasma gondii*. *J Submicrosc Cytol Pathol.* 1996;28:521-6.

Received: 30 July 2009

Accepted: 11 February 2010