

## **Distribution of T-cell subsets and immunoglobulin-containing cells in nasal-associated lymphoid tissue (NALT) of chickens**

**K. Ohshima and K. Hiramatsu**

Laboratory of Functional Anatomy, Faculty of Agriculture, Shinshu University, Ina, Japan

**Summary.** The present study demonstrated the localization of the T-cell subsets (CD4+ and CD8+) and immunoglobulin (Ig)-containing cells (IgA, IgM, and IgG) in the nasal mucosa and its accessory structures. These lymphoid structures may be compared with nasal-associated lymphoid tissue (NALT) of rats and mice. In the chicken NALT, T-cell subsets were more widely distributed than Ig-containing cells, especially in large lymphoid accumulations restricted to the respiratory mucosa in the nasal cavity and the nasolacrimal duct. These lymphoid accumulations in the mucosa of the nasal cavity and nasolacrimal duct consisted of widely distributed CD8+ cells and deeply aggregated CD4+ cells adjacent to large germinal centers. In these lymphoid accumulations, IgG-containing cells were more frequently observed than IgM- and IgA-containing cells. T-cell subsets, predominantly CD8+ cells were more widely distributed in the duct epithelium of the lateral nasal glands than Ig-containing cells. Moreover, numerous CD8+ cells and a few Ig-containing cells were found in the chicken salivary glands, especially around the orifice of their ducts into the oral cavity. Therefore, it seems likely that the chicken NALT plays an important part in the upper respiratory tract, with a close relationship to the paraocular immune system.

**Key words:** Nasal-associated lymphoid tissue (NALT), Immunoglobulin-containing cells, T-cell subsets, Immunohistochemistry, Chicken

### **Introduction**

The nasal mucosa lining the upper respiratory tract is the first site of contact with inhaled aeroantigens. According to Spit et al. (1989), it seems justified to consider the nasal lymphoid tissue as a general part of the mucosa-associated lymphoid tissue (MALT) system,

and to denote it as nasal-associated lymphoid tissue (NALT) in analogy with the gut- and bronchus-associated lymphoid tissue (GALT and BAL, respectively). However, the nature of local immune responses, and the role of NALT in these responses have rarely been studied, due to the absence of a suitable model (Kuper et al., 1992).

Recently, the structure and development of NALT in the rat (Hameleers et al., 1989; Spit et al., 1989; Kuper et al., 1990; van Poppel et al., 1993) and mouse (van der Ven and Sminia, 1993; Heritage et al., 1997) have been investigated by immunohistochemical or electron microscopic methods. Consequently, since it has been demonstrated that GALT, BAL and NALT differ in T/B-cell ratios (Kuper et al., 1990, 1992; Heritage et al., 1997), their function may differ in the defense mechanism of the mucosal sites; Peyer's patches (PP) may be the central tissue in the induction of secretory immunoglobulin (Ig) synthesis, while BAL and NALT appear to be more involved in cellular responses. Moreover, Kuper et al. (1992) reported that even within the respiratory tract there are some differences in the state of activation and in the number of B-cells between BAL and NALT of conventionally housed, untreated rats. They suggested that the more activated appearance and earlier development in NALT than BAL were probably due to its strategic position with respect to incoming air containing aeroantigens. Ichikawa et al. (1991) suggested that immunocompetent cells distributed in normal nasal mucosa of mice might locally develop or mobilize from systemic circulation according to antigenic stimuli.

In contrast to mammals, most avian species including chickens entirely lack lymph nodes, but have a system of lymphoid nodules normally associated with lymph vessels (King and McLelland, 1975). Accumulation of lymphoid tissue has been demonstrated in the oculo-nasal region in many avian species (Bang and Bang, 1968; Hodges, 1974; Aitken and Survasche, 1977; Rose, 1981). Plasma cells and lymphoid foci were common in paranasal tissues of chickens, but rare in those of other birds (Aitken and Survasche, 1977). Invasive lymphocyte populations consistently found in

---

**Offprint requests to:** Dr. Koji Ohshima, Laboratory of Functional Anatomy, Faculty of Agriculture, Shinshu University, Ina, Nagano-ken, 399-4598 Japan. Fax: 81-265-72-5259. e-mail: ohshima@gipmc.shinshu-u.ac.jp

the paraocular (Harderian glands and their ducts) and paranasal organs (nasolacrimal ducts, lateral nasal glands and their ducts) of healthy commercial stock chickens suggested that these tissue systems may be capable of local immune response to environmental stimuli (Bang and Bang, 1968).

The distributions of T- and B-lymphocytes in the chicken BALT (Fagerland and Arp, 1993a) are generally similar to those in mammalian BALT (Plesch et al., 1983). These observations suggested that the chicken BALT may also be mainly involved in cellular immune responses, but the functional nature of the T-cells in the respiratory mucosa is not yet clear.

Respiratory diseases in poultry are of major economic importance, and vaccination via an aerosol route would be a practical and economical method of protecting large flocks of chickens and turkeys (Fagerland and Arp, 1993a,b). However, immunohistochemical studies with respect to nasal lymphoid tissues have not yet been performed in chickens or other avian species.

The aim of the present study was to determine the structure and organization of the immunocompetent elements in the chicken NALT, especially with respect to T-cell subsets and Ig-containing cells, using immunohistochemical methods.

## Materials and methods

### *Chickens and tissue processing*

Eighteen adult male White Leghorn chickens from 25 weeks to 1-2 years of age were used in this study. They received food and water ad libitum and were clinically healthy.

Twelve birds anesthetized with thiopental sodium, were perfused with saline followed by periodate-lysine-paraformaldehyde (PLP) solution. The nasal tissues were dissected out with the surrounding tissues and immersed in the same fixative for at least 4 h at 4 °C. They were rinsed and dialyzed using 0.1M cacodylate buffer (pH 7.4) containing 10% to 20% sucrose for 24 h at 4 °C, embedded in Tissue-Tek OCT compound (Miles, USA) and frozen after decalcification for 3-5 weeks with 5% ethylenediaminetetra-acetic acid (EDTA) solution except for two tissue samples which were embedded and frozen without decalcification.

The other six birds were killed by decapitation, and the nasal tissues were removed with the surrounding tissues. They were immediately fixed with Bouin's fluid for 18-24 h at 4 °C, dehydrated through a graded ethanol series and embedded in paraffin after decalcification for 3-5 weeks with 5% EDTA solution.

### *Immunohistochemistry*

Cryostat sections (10-15 µm thick) and paraffin sections (8-10 µm thick) were cut serially in the frontal plane, and mounted on gelatin-coated slides. For

immunohistochemical analysis, they were incubated overnight at room temperature with one of the following primary antibodies, after pre-incubation with normal rabbit serum (1:20, Cedarlane Laboratories, USA) for 10 min. Cryostat sections; mouse anti-chicken monoclonal antibodies directed to CD4, and CD8 (1:500, Southern Biotechnology Associates, USA). Paraffin sections; goat anti-chicken polyclonal antibodies respectively directed to IgA, IgM or IgG (1:1000, Bethyl Laboratories, USA).

Following incubation with these antibodies, the cryostat sections were incubated with biotinylated rabbit anti-mouse Ig G<sub>1</sub> (1:500, Zymed Laboratories, USA) and the paraffin sections were incubated with biotinylated rabbit anti-goat IgG (1:1000, EY Laboratories, USA) for 20 min. Then, they were incubated with peroxidase-conjugated streptavidin (1:100, Zymed Laboratories) for 20 min. The normal serum, primary and secondary antibodies were diluted with 0.01M phosphate-buffered saline (PBS). The sections were washed with PBS three times for 5 min each time after each incubation step. Staining for peroxidase was performed using 0.05M Tris-HCl buffered (pH 7.6) containing 0.05% 3,3'-diaminobenzidine (DAB) and 0.006% H<sub>2</sub>O<sub>2</sub>. After immunohistochemical staining, the sections were slightly counterstained with hematoxylin, dehydrated, cleared and mounted.

Controls stained with normal serum instead of each respective primary antibody all gave negative results.

Also, some adjacent serial sections were stained using the periodic acid-Schiff (PAS) technique and counterstained with hematoxylin.

## Results

The nasal cavity was covered with three different types of epithelium, i.e. the vestibular, respiratory and olfactory epithelium (Figs. 1a-c, 2). The nasolacrimal ducts and the infra-orbital sinuses were situated in the ventro-lateral wall of the nasal cavity and covered with the respiratory epithelium (Fig. 1a,d). Also, lateral nasal glands were found in the ventro-lateral wall, opening into the nasal cavity (Fig. 1a,d), and medial and lateral palatine salivary glands were in close proximity to the nasal cavity, opening into the oral cavity (pharynx) (Fig. 1a,e). Lymphoid tissues were observed in the mucosa lining the nasal cavity and in its accessory structures in various amounts and with various distribution patterns as follows (summarized in Table 1).

### *Vestibular epithelium*

The vestibular region was situated at the entrance of the nasal cavity, which was lined with keratinized stratified squamous epithelium (Fig. 2). Within and under the vestibular epithelium, scarcely any cells showed positive immunoreactivity with the antibodies for chicken Ig and T-lymphocyte subsets, except for the rare appearance of CD8+ cells (Fig. 2).

### Respiratory epithelium

The majority of the surface of the nasal cavity was covered with the respiratory epithelium; a tall, ciliated pseudostratified columnar epithelium within and below which lay well-developed simple and compound alveolar mucous glands showing prominent PAS-positive reactivity (Fig. 1a,b). In the greater part of the respiratory mucosa, CD8+ cells were distributed in the basal portion of the respiratory epithelium and in the lamina propria just under the epithelium surrounding the mucous glands, whereas CD4+ cells were rarely scattered in the lamina propria (Fig. 3a,b). Occasionally, large lymphoid accumulations, consisting of numerous gathered CD4+ cells and scattered CD8+ cells, were observed in the lamina propria under the respiratory epithelium (Fig. 3a,b). They appeared to be variable in amount and distribution, and rarely had small germinal centers. These T-cells were small and round in shape with scant cytoplasm and immunoreactivity was detected only on their surface (Fig. 3c).

While, IgG-containing cells and IgM-containing cells were also observed in a similar distribution pattern to CD8+ cells in the general epithelium, IgA-containing cells were relatively few in number (Fig. 4a,b). In these lymphoid accumulations of the respiratory mucosa, IgG-containing cells were more frequently observed than those containing IgM or IgA (Fig. 4a,b). They were large and oval in shape with abundant cytoplasm showing strong immunoreactivity (Fig. 4c); especially strong staining was seen in the relatively abundant cytoplasm of IgM-containing cells.

### Olfactory epithelium

Part of the dorsal wall of the nasal cavity including the dorsal origin of the septum and the posterior turbinate was covered by a tall columnar, non-ciliated, pseudo-stratified epithelium, i.e. olfactory epithelium (Fig. 1a,c). The lamina propria of the olfactory mucosa consisted of collagenous connective tissue within which lay flask-shaped alveolar olfactory glands and olfactory nerves. A number of immunopositive cells for T cell subsets and three different types of Ig-containing cells

were scattered around the olfactory glands in the lamina propria and occasionally in the epithelium (Figs. 5, 6).

### Nasolacrimal duct

The general structure and distribution of T-cell subsets and Ig-containing cells in the wall of the nasolacrimal duct were similar to those in the nasal respiratory mucosa (Fig. 1a,d). However, the nasolacrimal duct mucosa included larger amounts of lymphoid accumulations and larger well-defined germinal centers than those in the respiratory mucosa (Figs. 7, 8). Although these lymphoid accumulations appeared not to have a fixed location, the largest was occasionally found around the orifice opening into the nasal cavity. In these lymphoid accumulations, CD8+ cells were distributed throughout the lamina propria (Fig. 7a), whereas CD4+ cells were in tightly packed clusters in deeper portions (Fig. 7b). Also, small groups of IgG-containing cells were superficially located in these accumulations, but IgA- and IgM-containing cells were infrequent (Fig. 8a,b). The surface of these lymphoid accumulations was extensively covered with non-ciliated squamous epithelium (Fig. 8b,c).

### Infra-orbital sinus

The overlying epithelium of the infra-orbital sinus consisted of low to medium ciliated cuboidal cells, with a few simple mucous glands (Figs. 1a, 8). The three different types of Ig-containing cells and CD 8+ cells were located within and just under the epithelium, in a row (Fig. 8a,b). CD 4+ cells were less numerous in the mucosa of the infra-orbital sinus. Scarcely any subepithelial lymphoid accumulation was observed.

### Lateral nasal glands

The lateral nasal glands were compound tubular structures without alveoli, the main ducts of which extended to the septum and opened into the nasal cavity (Fig. 1a,d). The height of the epithelium of the ducts increased in proportion to their caliber (Figs. 9, 10). Large numbers of T-cell subsets, predominantly CD8+ cells, were distributed in the basal region of the epithelium of various calibered ducts and in the interstitium among the ducts (Fig. 9). Rarely, CD4+ cells accumulated in the interstitium. The three types of Ig-containing cells were restricted to the main and secondary ducts and the interstitium, and were not seen in the tertiary duct with the smallest caliber (Fig. 10a,b).

### Palatine salivary glands

Usually, a few T-cell subsets and three types of Ig-containing cells were found within and around the compound tubular palatine salivary glands (Figs. 11-13). They were scattered in the duct epithelium and in the interstitium among the ducts. Also, in the keratinized,

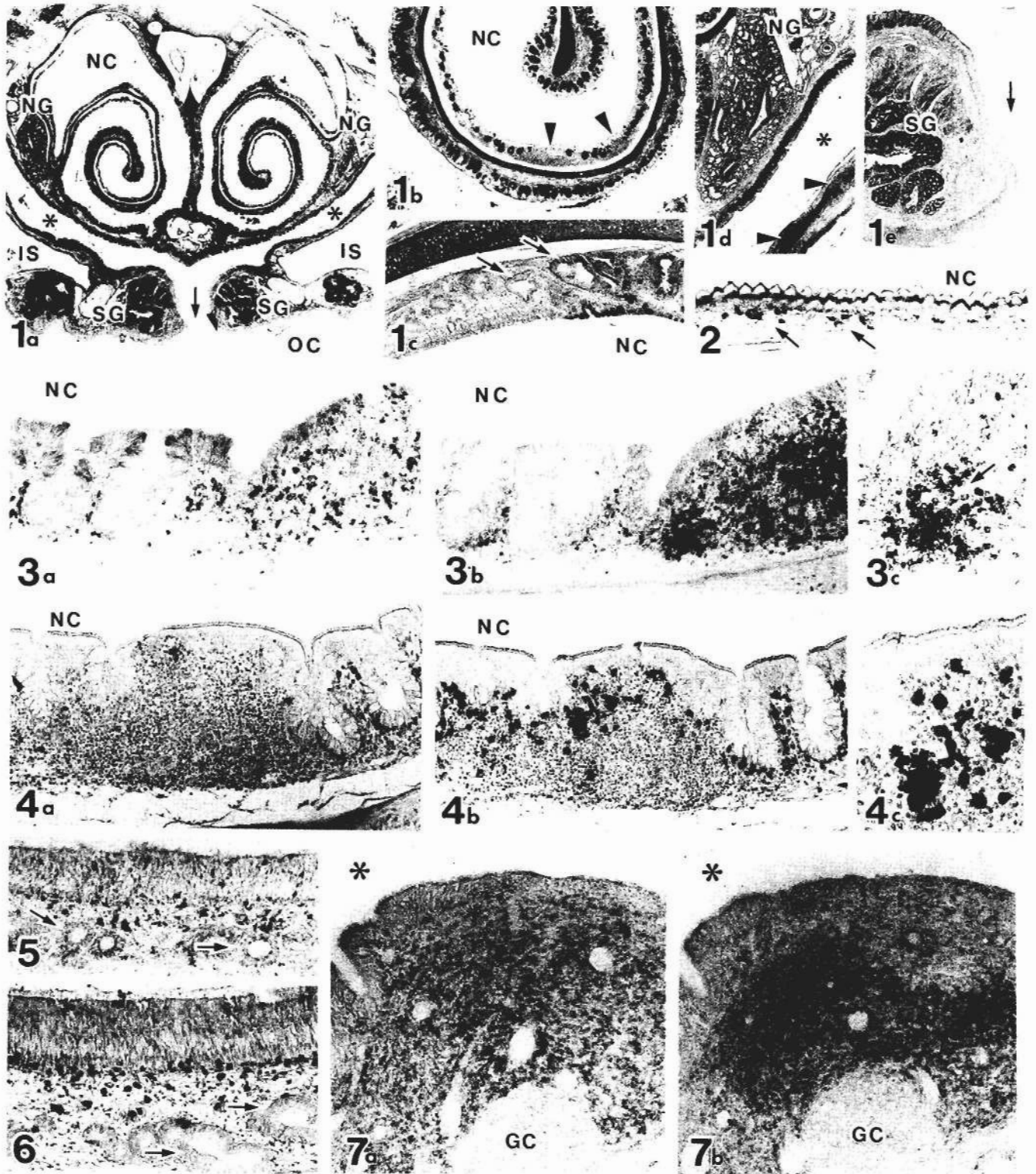
**Table 1.** Distribution of lymphoid cells in nasal mucosa and its accessory structures in chickens.

	IgA	IgM	IgG	CD4	CD8
Vestibule	-	-	-	-	±
Respiratory mucosa	±	±/+	+;++	±/+	+;++
Olfactory mucosa	±	±	±	±	±
Nasolacrimal ducts	±	±/+	+;++	+;++	+;++
Infra-orbital sinuses	±/+	±/+	±/+	±	+
Lateral nasal glands	+	+	+	±	++
Salivary glands	±	±	±	±	+
Oral epithelium	-	-	-	±	+

Abundance of different cell types in each tissue is indicated as follows: - none; ±, low; +, moderate; ++, high; +++, very high.

stratified, squamous epithelium lining the oral cavity just under the salivary glands, a large number of CD8+ cells were observed, especially around the orifice into the oral

cavity (Fig. 11a,b), but not CD4+ or Ig-containing cells. Also, a small number of Ig-containing cells were found in the orifice of the secretory duct in the oral cavity (Fig.



13).

## Discussion

The present study demonstrated the localization of T-cell subsets (CD4+ and CD8+) and three types of Ig-containing cells (IgA, IgM, and IgG) in the nasal mucosa and its accessory structures, especially in the lymphoid accumulations occasionally containing germinal centers. These lymphoid structures may be compared with NALT of rats (Hameleers et al., 1989; Spit et al., 1989; Kuper et al., 1990; van Poppel et al., 1993) and mice (van der Ven and Sminia, 1993; Heritage et al., 1997). However, immunohistochemical analysis with respect to immunocompetent cells has not yet been performed in the chicken NALT.

In the chicken NALT, T-cell subsets were more widely distributed than Ig-containing cells, especially in the lymphoid accumulations restricted to the respiratory mucosa lining the nasal cavity and the nasolacrimal duct. With respect to T/B-cell ratios, it has been demonstrated that the lymphoid tissues in the rat NALT and BALT differ from PP, in which the vast majority of the lymphocytes are B-cells (Sminia et al., 1983; Kuper et al., 1990; van der Ven and Sminia, 1993; Heritage et al., 1997). These studies implied that the lymphoid tissue in the respiratory tract is less engaged in the humoral immune responses at mucosal surfaces than PP. Kuper et al. (1992) concluded that NALT is more a T-cell organ, while PP are B-cell organs. Therefore, the chicken NALT appears to be mainly involved in cellular responses.

In this study, large lymphoid accumulations in the mucosa of the nasal cavity and nasolacrimal duct consist of widely distributed CD8+ cells and deeply aggregated CD4+ cells adjacent to germinal centers. These findings are in accordance with the observations in chicken BALT nodules, in which CD8+ cells were diffusely

scattered throughout interfollicular areas, whereas CD4+ cells were primarily in tightly packed clusters forming large asymmetric parafollicular caps around germinal centers and overlapped with B lymphocytes (Fagerland and Arp, 1993a). This localization may be able to facilitate exposure of B-lymphocytes to cytokines produced by CD4+ cells.

Mammalian GALT and BALT have been believed to function in the secretory IgA-linked immune system of antigen-recognition and antibody-production (Befus et al., 1980; Bienenstock et al., 1982; Brandzaeg, 1989). However, in the present study IgG-containing cells were more frequently observed than those containing IgM or IgA in the lymphoid accumulation of the chicken NALT. Also, in lymphoid tissues of the upper alimentary and respiratory tracts of chickens, relative frequency of IgG-containing cells was greater than those of IgM- and IgA-containing cells (Arai et al., 1988). In the respiratory tract, the area beneath the tracheal epithelium contained IgM and IgG plasma cells, but few IgA plasma cells (Jeurissen et al., 1989). Kuper et al. (1992) reported that B-cells expressing membrane-bound IgA are rare in NALT, but not in BALT, and in this respect BALT closely resembles PP more than NALT. Thus, in contrast to the prime importance of IgA in the mammalian mucosal immune system, IgG may be more important at avian mucosal surfaces.

However, Parry and Aitken (1973, 1977) demonstrated large numbers of IgA-containing cells in association with the upper respiratory tract of chickens, particularly in the Harderian gland during the early post-infective stage of mild Newcastle disease. Moreover, according to Heritage et al. (1997), although the NALT of normal mice generally contained few IgA-secreting B-cells, after intranasal immunization with cholera toxin (CT), CT-specific IgA antibody-forming cells were readily detected in their NALT. This suggested that B-cell isotype switching and differentiation occur in the

**Fig. 1.** Frontal sections through the chicken nasal tract. PAS-hematoxylin staining. **a.** Note the nasal respiratory mucosa and its accessory structures. IS: infra-orbital sinus; NC: nasal cavity; NG: lateral nasal glands; OC: oral cavity; SG: palatine salivary glands; asterisks: nasolacrimal ducts; arrow: choanae.  $\times 5$ . **b.** Higher magnification of the respiratory mucosa shown in (a). Note lymphoid accumulations (arrowheads) in the subepithelial region. NC: nasal cavity.  $\times 20$ . **c.** Higher magnification of the olfactory mucosa in (a). Note the olfactory glands (arrows). NC: nasal cavity.  $\times 40$ . **d.** Higher magnification of the lateral nasal gland (NG) and the nasolacrimal duct (asterisk) shown in (a). Note lymphoid accumulations (arrowheads) in the nasolacrimal duct mucosa.  $\times 15$ . **e.** Higher magnification of the palatine salivary gland (SG) in (a). Note the transitive portion from the oral epithelium to the respiratory epithelium in the choanae (arrow).  $\times 15$

**Fig. 2.** Distribution of CD8+ cells in the vestibular portion of the chicken nasal tract. Note the small number of CD8+ cells (arrows) scattered under the keratinized, stratified, squamous epithelium. NC: nasal cavity.  $\times 180$

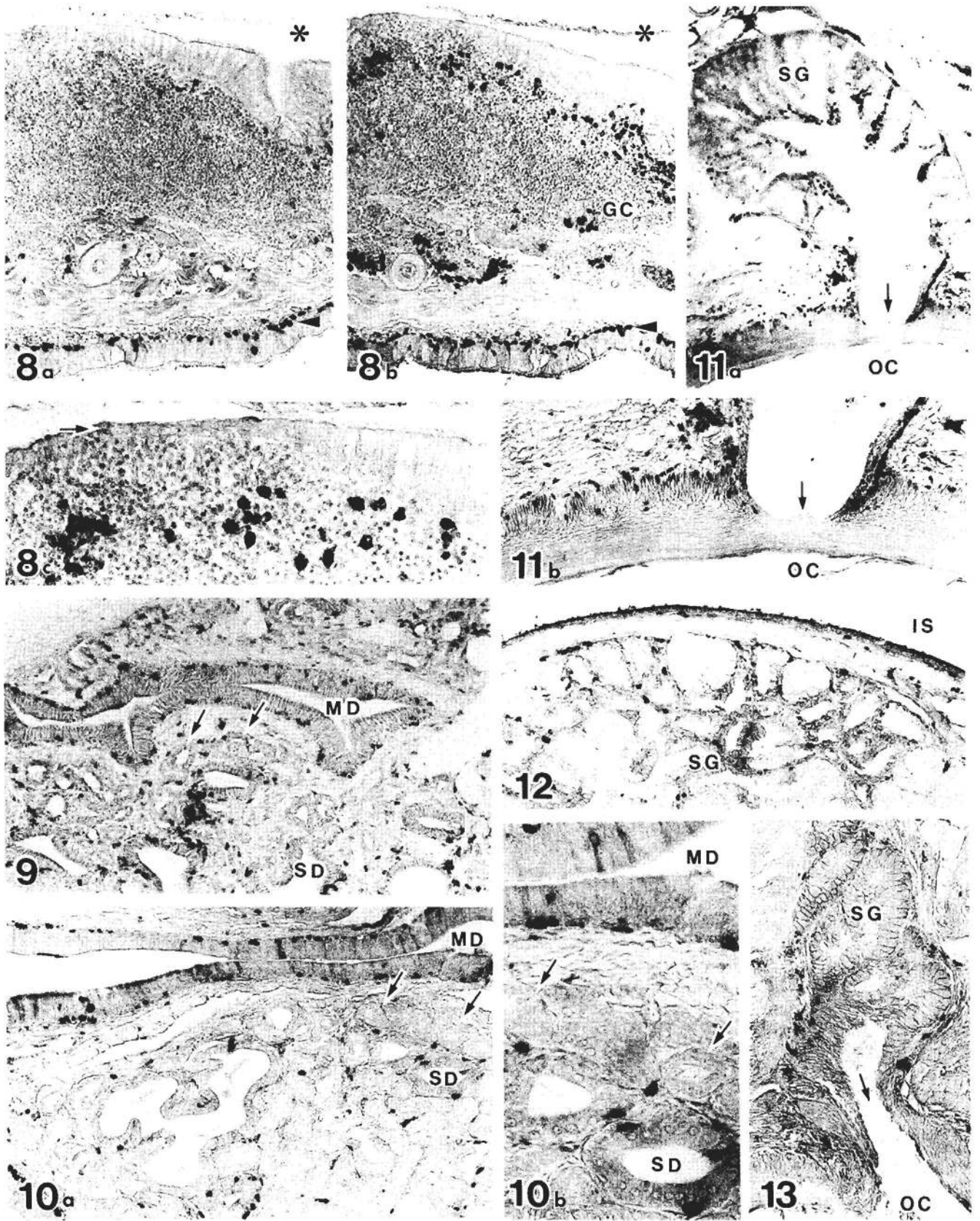
**Fig. 3.** Serial sections showing the distribution of T-cells in the respiratory mucosa of the chicken. Note CD8+ cells (**a**) and CD4+ cells (**b**) in the respiratory mucosa. NC, nasal cavity.  $\times 140$ . **c.** Higher magnification of the accumulation of CD4+ cells (arrow) shown in (b).  $\times 320$

**Fig. 4.** Serial sections showing the distribution of Ig-containing cells in the respiratory mucosa of the chicken. Note IgA-containing cells (**a**) and IgG-containing cells (**b**) in the respiratory mucosa. NC: nasal cavity.  $\times 140$ . **c.** Higher magnification of the accumulation of IgG-containing cells shown in (b).  $\times 320$

**Figs. 5 and 6.** Distribution of CD8+ cells (**5**) and IgG-containing cells (**6**) in the olfactory mucosa of the chicken. Note olfactory glands (arrows) in the mucosa.  $\times 140$

**Fig. 7.** Serial sections showing the distribution of T-cells in the nasolacrimal duct (asterisk) of the chicken. Note CD8+ cells (**a**) distributed throughout the lamina propria and CD4+ cells (**b**) accumulated in the deep portion adjoining the germinal center (GC).  $\times 140$

*Immunocompetent cells in chicken NALT*



*Immunocompetent cells in chicken NALT*

**Fig. 8.** Serial sections showing the distribution of Ig-containing cells in the nasolacrimal duct (asterisk) and in the infra-orbital sinus of the chicken. Note the small number of IgA-containing cells (**a**) and large number of IgG-containing cells (**b**) in the mucosa of the nasolacrimal duct (asterisk). Some IgG-containing cells were distributed in the germinal center (GC). Both types of Ig-containing cells were fairly numerous in the mucosa (arrowheads) of the infra-orbital sinus. x 140. Higher magnification of the accumulation of IgG-containing cells shown in (b). Note the squamous lymphoepithelium (arrow) with no cilia on the lymphoid accumulation. x 320

**Figs. 9 and 10.** Distribution of CD8+ cells (**9**) and IgM-containing cells (**10a**) in the ducts of various calibers and in the interstitium of the lateral nasal gland of the chicken. MD, main duct, SD, secondary duct. x 140. **10b.** Higher magnification of the distribution of the IgM-containing cells shown in (10a). Note the tertiary duct epithelium (arrows) containing CD8+ cells, but not those containing IgM. MD, main duct; SD: secondary duct. x 320

**Fig. 11. a.** Distribution of CD8+ cells in the palatine salivary gland and in the epithelium of the oral cavity (OC) of the chicken. Note numerous CD8+ cells around the orifice (arrow) in the oral cavity. x 70. **b.** Higher magnification of the orifice (arrow) leading in the oral cavity (OC) in (a). x 140

**Figs. 12 and 13.** **12.** Distribution of IgM-containing cells in the palatine salivary gland (SG) of the chicken. **13.** Note the small number of IgM-containing cells around the orifice (arrow) to the oral cavity (OC), but not in the oral epithelium. IS: infra-orbital sinus. x 140

NALT after direct antigenic stimulation.

In this study, the lymphoid accumulation with germinal centers were variable in both amount and distribution in the mucosa of the nasal cavity and the nasolacrimal duct of chickens. In addition, these lymphoid aggregations and their germinal centers in the nasolacrimal duct mucosa were more frequent and larger than those in the respiratory mucosa of the nasal cavity. Bang and Bang (1968) consistently found large lymphoid infiltrations incorporating germinal centers in the nasolacrimal duct only in domestic gallinaceous birds, not in any wild species. Further, they reported that the lymphoid structures in apparently healthy controls were indistinguishable from those in the nasal mucosa of chickens known to be infected with mycoplasma or laryngotracheitis virus. In conventionally housed, untreated rats, NALT is first present at the day of birth (Hameleers et al., 1989; van Poppel et al., 1993), whereas BALT is not seen until 4 days after birth (Plesch et al., 1983), and NALT has a more activated appearance than BALT (Kuper et al., 1990). These observations indicated that the earlier development and more activated appearance of NALT as compared to BALT were probably due to its strategic position with respect to incoming aero-antigens (Kuper et al., 1992).

As reviewed by Shirama et al. (1996), there is considerable evidence to suggest that the Harderian gland plays an important role in immunological protection along paraocular mucosal surfaces in the chicken. The conjunctiva-associated lymphoid tissue (CALT) in the chicken eyelid has also been proposed to function as a component of the paraocular mucosal immune system (Fix and Arp, 1991). These paraocular drainages into the mouth occur through the nasolacrimal duct (Bang and Bang, 1968). Therefore, lymphoid accumulations in the nasolacrimal mucosa of chickens might also be closely related to the paraocular immune functions.

Furthermore, in the chicken NALT these large lymphoid accumulations with germinal centers were covered by non-ciliated squamous epithelial cells. Also, van Alstine and Arp (1988) observed that the low cuboidal epithelium covering each lymphoid nodule of

the turkey BALT is morphologically similar to the lymphoepithelium of BALT and PP of chickens and mammals, which lack cilia and mucous-producing cells. These non-ciliated squamous or cuboidal cells shows morphological resemblance to the M-cells which have been demonstrated in the rat NALT (Spit et al., 1989; reviewed by Kuper et al., 1992). However, Fagerland and Arp (1990) found no typical M-cells in the turkey BALT, although epithelial cells are attempted and intimately associated with intraepithelial lymphocytes.

In chickens, the presence of plasma cells in the ducts of the lateral nasal gland suggested that it serves not only as the main source of the physiological vapor essential for respiration and olfaction, but also plays a role in the local immune system in the nasal cavity (Bang and Bang, 1968). The nasal gland of chickens can be divided into three parts according to the caliber of the ducts and the nature of their epithelium; i.e. the tertiary ducts, secondary duct, and main duct (McLelland et al., 1968). In the present study, although large numbers of CD8+ cells were distributed in the basal region of the epithelium of ducts of various calibers and in the interstitium among the ducts in the chicken, the three types of Ig-containing cells were not observed in the tertiary duct with the smallest caliber. Therefore, the lateral nasal gland in the chicken NALT may be mainly involved in cellular rather than in humoral responses.

Moreover, the appearance of numerous CD8+ cells and a few Ig-containing cells in the chicken salivary glands, especially around the orifice of their duct into the oral cavity, indicated that they contribute to the immune response in the oral cavity. In mammalian species, a number of immunocompetent cell types have been found in the duct-associated lymphoid tissue (DALT) of minor salivary glands (Nair and Schroeder, 1986).

On the basis of these immunohistological characteristics, it seems likely that the chicken NALT plays an important role in the upper respiratory tract, closely related to the paraocular immune system.

---

*Acknowledgements.* This study was supported in part by a scientific grant (No. 11876054) from the Ministry of Education, Science and Culture of Japan to K. Ohshima.

## References

- Aitken I.D. and Survashe B.D. (1977). Lymphoid cells in avian paraocular gland and paranasal tissues. *Comp. Biochem. Physiol.* 58, 235-244.
- Arai N., Hashimoto Y., Kitagawa H., Kon Y. and Kudo N. (1988). Immunohistological study on the distribution of lymphoid tissue in the upper alimentary and respiratory tract of chicken. *Jpn. J. Vet. Sci.* 50, 183-192.
- Bang B.G. and Bang F.B. (1968). Localized tissues and plasma cells in paraocular and paranasal organ systems in chickens. *Am. J. Pathol.* 53, 735-751.
- Befus A.D., Johnson N., Leslie G.A. and Bienenstock J. (1980). Gut-associated lymphoid tissue in the chicken. 1. Morphology, ontogeny and some functional characteristic of Peyer's patches. *J. Immunol.* 125, 2626-2632.
- Bienenstock M.R., McDermott M.R. and Befus A.D. (1982). The significance of bronchus-associated lymphoid tissue. *Bull. Eur. Physiopathol. Resp.* 18, 153-177.
- Brandzaeg P. (1989). Overview of the mucosal immune system. *Curr. Topics Microbiol. Immunol.* 146, 13-25.
- Fagerland J.A. and Arp L.H. (1990). A morphologic study of bronchus-associated lymphoid tissue in turkeys. *Am. J. Anat.* 189, 24-34.
- Fagerland J.A. and Arp L.H. (1993a). Distribution and quantitation of plasma cells, T lymphocyte subsets, and B lymphocytes in bronchus-associated lymphoid tissue of chickens: age-related differences. *Reg. Immunol.* 5, 28-36.
- Fagerland J.A. and Arp L.H. (1993b). Structure and development of bronchus-associated lymphoid tissue in conventionally reared broiler chickens. *Avian Dis.* 37, 10-18.
- Fix A.S. and Arp L.H. (1991). Morphologic characterization of conjunctiva-associated lymphoid tissue in chickens. *Am. J. Vet. Res.* 52, 1852-1859.
- Hameleers D.M.H., van der Ende M., Biewenga J. and Sminia T. (1989). An immunohistochemical study on the postnatal development of rat nasal-associated lymphoid tissue (NALT). *Cell Tissue Res.* 256, 431-438.
- Heritage P.L., Underdown B.J., Arsenault A.L., Snider D.P. and McDermott M.R. (1997). Comparison of murine Nasal-associated lymphoid tissue and Peyer's patches. *Am. Resp. Crit. Care Med.* 156, 1256-1262.
- Hodges R.D. (1974). The respiratory system. 1. The Nasal cavity. In: *The histology of the fowl.* Academic Press. London. pp 113-125.
- Ichikawa I., Kawauchi H., Fujiyosi T., Tanaka T. and Mogi G. (1991). Distribution of immunocompetent cells in normal nasal mucosa: Comparisons among germ-free, specific pathogen-free, and conventional mice. *Ann. Otol. Rhinol. Laryngol.* 100, 638-642.
- Jeurissen S.H.M., Janse E.M., Koch G. and Boer G.F. (1989). Postnatal development of mucosa-associated lymphoid tissues in chicken. *Cell Tissue Res.* 258, 119-124.
- King A.S. and McLelland J. (1975). Lymphatic system. In: *Outlines of avian anatomy.* Bailliere Tindall. London. pp 103-105.
- Kuper C.F., Hameleers D.M. H., Bruijntjes J.P., van der Ven I., Biewenga J. and Sminia T. (1990). Lymphoid and non-lymphoid cells in nasal-associated lymphoid tissue (NALT) in the rat. An immuno- and enzyme- histochemical study. *Cell Tissue Res.* 259, 371-377.
- Kuper C.F., Koornstra P.J., Hameleers D.M.H., Biewenga J., Spit B.J., Duijvestijn A.M., van Breda Vriesmann P.J.C. and Sminia T. (1992). The role of nasopharyngeal lymphoid tissue. *Immunol. Today* 13, 219-225.
- McLelland J., Moorhouse P.D.S. and Pickering E.G. (1968). An anatomy and histochemical study of the nasal gland of *Gallus domesticus*. *Acta Anat.* 71, 122-133.
- Nair P.N.R. and Schroeder H.E. (1986). Duct-associated lymphoid tissue (DALT) of minor salivary glands and mucosal immunity. *Immunology* 57, 171-180.
- Parry S.H. and Aitken I.D. (1973). Immunoglobulin A in the respiratory tract of the chicken following exposure to Newcastle disease virus. *Vet. Rec.* 91, 258-260.
- Parry S.H. and Aitken I.D. (1977). Local immunity in the respiratory tract of the chicken. II. The secretory immune response to Newcastle disease virus and the role of IgA. *Vet. Microbiol.* 2, 143-165.
- Plesch B.E.C., Gamelkoorn G.J. and Van de Ende M. (1983). Development of bronchus associated lymphoid tissue (BALT) in the rat, with special reference to T and B cells. *Dev. Comp. Immunol.* 7, 179-188.
- Rose M.E. (1981). Lymphatic system. In: *Form and function in bird.* Vol. 2. King A.S. and McLelland J. (eds). Academic Press. London. pp 341-384.
- Shirama K., Satoh T., Kitamura T. and Yamada J. (1996). The avian Harderian gland: morphology and immunology. *Microsc. Res. Tech.* 34, 16-27.
- Sminia T., Janse E.M. and Plesch B.E.C. (1983). Ontogeny of the Peter's patches of the rats. *Anat. Rec.* 207, 309-316.
- Spit B.J., Hendriksen E.G.J., Bruijntjes J.P. and Kuper C.F. (1989). Nasal lymphoid tissue in the rat. *Cell Tissue Res.* 255, 193-198.
- Van Alstine W.G. and Arp L.H. (1988). Histologic evaluation of lung and bronchus-associated lymphoid tissue in young turkeys infected with *Bordetella avium*. *J. Vet. Res.* 49, 835-839.
- Van der Ven I. and Sminia T. (1993). The development and structured of mouse nasal-associated lymphoid tissue: An immuno- and enzyme- histochemical study. *Reg. Immunol.* 5, 69-75.
- Van Poppel M.N.M., van den Berg van Rees E.P., Sminia T. and Biewenga J. (1993). Reticulum cells in the ontogeny of nasal-associated lymphoid tissue (NALT) in the rat. *Cell Tissue Res.* 273, 577-581.