

Divergent Social Functioning in Behavioral Variant Frontotemporal Dementia and Alzheimer Disease: Reciprocal Networks and Neuronal Evolution

William W. Seeley, MD,*† John M. Allman, PhD,‡ Danielle A. Carlin, MD,†§
Richard K. Crawford, BS,*† Marcelo N. Macedo, BS,*† Michael D. Greicius, MD,||
Stephen J. DeArmond, MD, PhD,¶ and Bruce L. Miller, MD*†

Abstract: Behavioral variant frontotemporal dementia (bvFTD) disrupts our most human social and emotional functions. Early in the disease, patients show focal anterior cingulate cortex (ACC) and orbital frontoinsula (FI) degeneration, accentuated in the right hemisphere. The ACC and FI, though sometimes considered ancient in phylogeny, feature a large bipolar projection neuron, the von Economo neuron (VEN), which is found only in humans, apes, and selected whales—all large-brained mammals with complex social structures. In contrast to bvFTD, Alzheimer disease (AD) often spares social functioning, and the ACC and FI, until late in its course, damaging instead a posterior hippocampal-cingulo-temporal-parietal network involved in episodic memory retrieval. These divergent patterns of functional and regional impairment remain mysterious despite extensive molecular-level characterization of bvFTD and AD. In this report, we further develop the hypothesis that VENs drive the regional vulnerability pattern seen in bvFTD, citing recent evidence from functional imaging in healthy humans, and also structural imaging and quantitative neuropathology data from bvFTD and AD. Our most recent findings suggest that bvFTD and AD target distinct, anticorrelated intrinsic connectivity networks and that bvFTD-related VEN injury occurs throughout the ACC-FI network. We suggest that the regional and neuronal vulnerability patterns seen in bvFTD and AD underlie the divergent impact of these disorders on recently evolved social-emotional functions.

Key Words: von Economo neuron, frontotemporal dementia, Alzheimer disease, anterior cingulate, frontoinsula

From the Departments of *Neurology; §Psychiatry; ¶Pathology, University of California at San Francisco; †UCSF Memory and Aging Center, San Francisco; ‡Division of Biology, California Institute of Technology, Pasadena; and ||Departments of Neurology and Psychiatry, Stanford University School of Medicine, Stanford, CA.

Supported by the National Institute of Aging grants K08 AG027086-01, 1P01 AG19724-01A1, and P50 AG1657303-75271, Larry L. Hillblom Foundation, James S. McDonnell Foundation, Doris Duke Foundation, Gordon and Betty Moore Foundation, and the David and Lucile Packard Foundation.

Reprints: William W. Seeley, MD, UCSF Department of Neurology, Memory and Aging Center, 350 Parnassus Ave., Suite 706, Box 1207, San Francisco, CA 94143-1207 (e-mail: wseeley@memory.ucsf.edu).
Copyright © 2007 by Lippincott Williams & Wilkins

(*Alzheimer Dis Assoc Disord* 2007;21:S50–S57)

The slow churn of evolution has rendered a human brain with remarkable flexibility. Like other primates and many mammals, we can manage dynamic, immediate stimuli and contexts using a fluid mix of cognitive and emotional processing. Humans and great apes may differ even from other primates, however, in their ability to represent the mental and emotional contents of the self and others¹ and to use self-anchored, visceral-autonomic, emotional salience assessments to reach decisions that serve both short- and long-term personal objectives. In parallel with these achievements, the human brain has evolved the capacity to perform mental time travel.² Thought by some to further distinguish humans,³ and possibly apes,⁴ from other species, mental time travel refers to projection of the self into one's personal past and future. The dementias can slowly undermine each of these recently evolved capacities, and this observation is the main theme of this manuscript.

In neurodegenerative diseases, genetic-molecular aberrations undermine specific neurons within specific brain regions. These changes disrupt function-critical neural networks, producing signature patterns of cognitive or behavioral impairment. In this report, we highlight selective vulnerability in behavioral variant frontotemporal dementia (bvFTD) and Alzheimer disease (AD), the most common dementia syndromes in patients less than 65 years of age.⁵ We describe how these disorders produce contrasting patterns of behavioral, regional, and cellular level impairment that reflect divergent assaults on “here and now” (emotional salience assessment) versus “there and then” (mental time travel) processing.

SOCIAL FUNCTIONING DIFFERENCES IN bvFTD AND AD REFLECT CONTRASTING REGIONAL VULNERABILITY PATTERNS

BvFTD is the commonest of 3 clinical syndromes caused by underlying frontotemporal lobar degeneration pathology. Patients with bvFTD develop early impairments in social cognitive and emotional functions, including self-conscious emotions, such as embarrassment⁶;

theory of mind^{7,8}; empathy^{7,9}; metacognitive judgment, including awareness of deficit⁸ and moral sensibility.^{7,10} Patients may even develop shifts in long-held core aspects of their personal identity, especially when asymmetric right hemisphere involvement is seen.¹¹ These deficits suggest impairment in the brain's ability to represent the self (both viscerally and abstractly) and to represent the feelings and thoughts of others.¹² During development, as in phylogeny, many aspects of self- and other-representation emerge late. Infants achieve mirror self-recognition at 15 to 24 months of age, providing a necessary substrate for the self-conscious emotions, such as embarrassment and shame, that follow.¹³ Patients with early bvFTD often retain core autonomic reflexes yet prove difficult to embarrass,⁶ perhaps because they cannot perceive the social-emotional significance of their own actions. Even more intriguingly, some patients can articulate the precise feelings of others' (eg, their spouse's distress) yet lack the emotional and behavioral responses normally evoked by those feelings. These selective social-emotional deficits arise in parallel with consistent¹⁴ and severe^{15,16} anterior cingulate cortex (ACC) and orbital frontalinsula (FI) degeneration. Previous pathologic studies have suggested that medial frontal and orbital frontoinsular regions are also the sites where bvFTD-related atrophy begins.^{17,18} Consistent with this idea, we recently showed that patients with very mild bvFTD (Clinical Dementia Rating scale score = 0.5) feature ACC/FI atrophy, accompanied by focal frontal pole, rostromedial and dorsolateral prefrontal, striatal, and thalamic injury.¹⁹ These early-affected regions may represent an anterior brain system for social-emotional functioning,²⁰ with a particular emphasis on regions that support visceral self- and other-representation.^{21–23} Notably, while this anterior network degenerates, posterior cortical functions survive or even thrive, at times associated with emergent visual creativity.²⁴

AD, in contrast, begins with episodic memory dysfunction and impaired mental time travel, accompanied by neuropathologic,^{25,26} metabolic,²⁷ and functional connectivity²⁸ changes within the medial temporal lobe. Entorhinal cortex layer 2 pyramidal projection neurons show early tangle formation and neuronal dropout.²⁶ In addition, prominent posterior cingulate cortex (PCC), precuneus (preCu), and lateral temporoparietal dysfunction is seen,^{15,28,29} suggesting impairment throughout a posterior episodic memory network^{30,31} equipped to perceive and re-represent the visual, spatial, auditory, and verbal elements of current or past experience. In AD, core social-emotional processes often persist as an island of spared functioning, even while cognition beyond the memory system progressively deteriorates. Indeed, patients with AD perform normally or better on the same tasks that have defined the bvFTD social-emotional syndrome.^{8–10} At the bedside, patients with AD are often warm, sensitive, and in tune with their caregivers, who describe them as "still the same person they were before."³² ACC and FI are often spared until late stages of AD,³² and direct comparisons highlight focal ACC-FI hypoperfusion³³ and atrophy³⁴ in bvFTD compared with AD.

In contrast, dorsolateral prefrontal regions critical for executive functioning are affected in both disorders,³⁴ explaining why social, not cognitive, frontal functions help differentiate bvFTD from AD.³⁵ For all of these reasons, studying the ACC and FI may reveal factors that affect neuron survival (for better or worse) in neurodegenerative disease.

HUMAN FUNCTIONAL NETWORK ARCHITECTURES RELATED TO bvFTD AND AD

Functional imaging studies suggest that a basic role of the frontal paralimbic cortex is to generate, through ACC, and re-represent, via FI, visceral-autonomic responses.^{36–38} Adaptive human behavior may rely on integration of these body state signals with social stimuli, situational context, and long-term personal goals. Consistent with these ideas, ACC and FI activate in response to diverse forms of biologic salience, including the emotional aspects of pain^{23,39}; metabolic stress⁴⁰; sensual touch⁴¹; faces of loved ones,⁴² allies,⁴³ or rivals⁴⁴; and certain forms of uncertainty⁴⁵ and task set engagement.⁴⁶ In essence, ACC and FI are engaged as one enters the here and now to deal with some salient cognitive, homeostatic, or emotional demand.^{47,48} We and others have shown that ACC and FI anchor an intrinsic connectivity network (ICN) in healthy humans, detectable using functional connectivity analysis of task-free functional magnetic resonance imaging (fMRI) data.^{48,49} Here and now dealings are perturbed in patients with bvFTD, for whom serious social transgressions^{7,10} and even threats to homeostasis⁵⁰ lack emotional weight.

A posterior ICN, closely related to the regions affected in AD, has received greater attention^{51,52} than the paralimbic "emotional salience network"⁴⁸ and routinely deactivates during tasks that activate the ACC and FI.^{42,53} This network, sometimes referred to as the default mode network (DMN), is made up of the hippocampi, PCC/preCu, lateral parietal regions, and rostromedial prefrontal cortex (rmPFC), structures critical for episodic memory formation and retrieval, mental imagery, and reflective contemplation.^{30,53–55} In essence, regions composing the DMN seem to support there and then functions we use to wander through thoughts and images from our personal past and future. When pressing here and now stimuli are detected and introspection must halt, the DMN deactivates and the ACC-FI network turns on. These functional imaging observations suggest a reciprocal relationship between the major networks that degenerate in early bvFTD and AD.

Recent fMRI data from anesthetized monkeys and humans suggest that ICNs are detectable independent of consciousness, are partly conserved in evolution, and may reflect the degree to which anatomically interconnected brain regions exhibit functional-metabolic coherence.⁵⁶ Regions heavily interconnected, that is, show greater intrinsic functional MR connectivity than do regions with light, indirect, or absent connections. Even so, functional covariance has also been demonstrated among functionally

related cortices connected across multiple synapses.⁵⁶ Furthermore, in healthy humans, the degree of subregional connectivity within ICNs can predict individual differences in cognitive and emotional function measured outside the scanner.⁴⁸ These new findings suggest that ICNs may provide a robust assay of network integrity in neurodegenerative disease.

NEURONAL EVOLUTION WITHIN THE ACC-FI NETWORK

The ACC and FI share several cytoarchitectural features that reflect their functional-anatomic kinship. These regions are agranular paralimbic cortices with a prominent layer 5, an absent layer 4, and a less conspicuous layer 2 than seen in adjacent neocortex. Both ACC and FI show prominent layer 5 myelination and sit at transition zones between limbic allocortex and frontal neocortex, leading some authors to consider them primitive, or at least more conserved throughout mammalian phylogeny, compared with the neocortex.⁵⁷ Nonetheless, ACC and FI are the unique homes to a class of large bipolar projection neurons (Fig. 1) first described by Betz⁵⁸ in 1881. Von Economo later studied these cells in depth, was struck by their peculiar topographic distribution, and speculated that ACC and FI have come to serve new functions in humans compared with our remote mammalian ancestors whose goal-seeking behaviors were more driven by olfaction.⁵⁹ Presciently, he surmised that

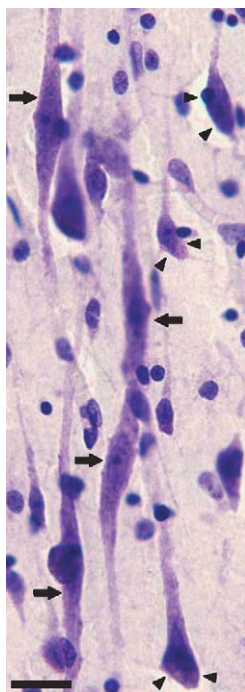


FIGURE 1. A VEN cluster in the normal adult brain. VENs (arrows) are identified by their large size and bipolar dendritic architecture. Often, VEN clusters are aligned next to small arterioles. Neighboring pyramidal neurons (arrowheads) provide a comparison. Cresyl violet. Scale bar = 20 μ m.

the shared features of ACC and FI might relate to joint processing of visceral-autonomic inputs and outputs. Although these von Economo neurons (VENs) have been referred to elsewhere as “spindle neurons,”⁶⁰ the term VEN was offered to sidestep terminologic confusion with other spindle-shaped cells described in the literature.⁶¹

In 1999, Nimchinsky and colleagues⁶² found VENs only in great apes and humans, despite an extensive search of 22 other primates and 30 additional mammalian species. In 2006, VEN-like neurons were observed in the ACC, FI, and frontal pole of humpback, fin, and killer whales, suggesting convergent evolution in a separate lineage of large-brained, socially complex mammals. In humans, VENs are notably larger, more clustered,⁶² and more abundant⁶¹ than in apes. VENs arise late in gestation and increase numerically until 4 to 8 years of age before they are reduced to their adult prevalence.⁶¹ Adult VENs show a simplified dendritic arbor that seems tailored to provide a narrow sampling of inputs within a small cortical column.⁶³ Large VEN axons project beyond the local circuitry to as yet unknown targets.⁶⁰ Consistent with a possible role for these cells in recently evolved social-emotional functions, VENs are 30% more abundant in the right hemisphere of apes and humans and express dopamine 3, serotonin 1b/2b, and vasopressin 1a receptors within the proximal somatodendritic compartment.⁶¹

Whether considering phylogeny, ontogeny, topology, or lateralization, VEN characteristics can be described in ways that are remarkably similar to how we might describe functions lost in bvFTD. That is, bvFTD targets recently evolved, late-developing functions that localize to ACC and FI, especially in the nondominant hemisphere. These factors led us to hypothesize that VENs are the early cellular target in bvFTD, akin to the layer 2 pyramidal neurons affected in early AD. In support of this hypothesis, we demonstrated that left pregenual ACC VENs are selectively vulnerable in bvFTD.⁶⁴ VEN dropout in this region was early and profound, ranging 50% to 90% versus controls (mean 74%, $n = 7$). Most importantly, the ratio of VENs to neighboring neurons was dramatically reduced, even among bvFTD patients with mild overall frontal atrophy. In AD, the mean VEN to neighboring neuron ratio was equal to controls, and we have yet to observe neurofibrillary tangles within VENs. These findings suggest that VEN selective vulnerability may be a unique and defining feature of bvFTD, but further work is needed to determine whether VENs represent the initial cellular target that triggers the broader bvFTD degenerative cascade. To test these possibilities, VENs need to be quantified in FI and in the right hemisphere.

Thus far, the goal of this paper has been to develop the hypotheses that bvFTD and AD target distinct, anticorrelated intrinsic brain networks and that bvFTD targets VENs. In the remaining sections, we provide new data supporting these ideas. First, we demonstrate the reciprocal relationship between the networks targeted in bvFTD and AD, replicating previous intrinsic functional connectivity MRI findings in a new set of healthy young

controls. Next, we provide preliminary neuropathologic data that VEN loss in bvFTD extends beyond the left pregenual ACC, as studied previously, and includes VENs populating the distributed, bihemispheric ACC-FI network.

METHODS AND RESULTS

ICN Analyses in Healthy Controls: Mapping the Networks Targeted in bvFTD and AD

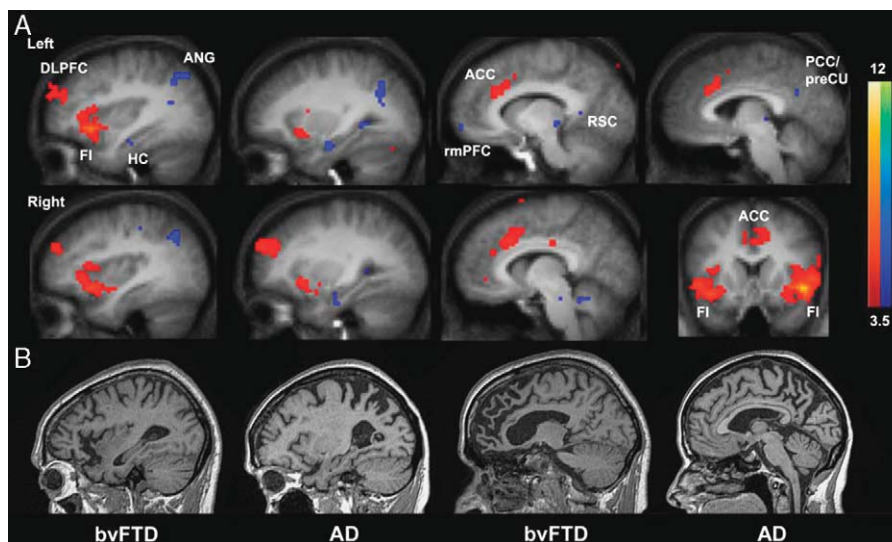
To replicate our previous findings regarding the normal human ICNs targeted in bvFTD⁴⁸ and AD,^{28,52} we performed new ICN analyses using the BrainSCAPE processing engine,⁶⁵ available online at <http://www.brainscape.org/app/template/Index.vm>. First, we analyzed data from 17 healthy control subjects (9 female, mean age = 23.1 y, range = 18 to 27 y) who lay quietly, undirected, in an MRI scanner (dataset BS002 at the BrainSCAPE website, fully described in Ref. 66). No task instructions or stimuli were provided, except that the subjects were to remain awake and fixate a cross in the center of their visual field. The scan parameters, preprocessing, and analysis methods have been described previously.⁶⁷ For this study, we chose a right FI region-of-interest (ROI) based on the atrophy pattern, described above, identified in very mild bvFTD.¹⁹ This ROI, a 4-mm radius sphere centered at (44, 15, -7) was used to seed a functional connectivity analysis in which we sought voxels, across the whole brain, whose blood oxygen level-dependent signal time course was highly correlated with that of the seed. Group level statistical maps were computed using a random effects analysis, and the data were corrected for multiple comparisons using the Monte-Carlo simulation to yield a cluster-level significance threshold of $P < 0.01$ (cluster size = 12 voxels, smoothing at 6 mm full width half maximum). The findings replicated our previous study,⁴⁸ which used a similar FI ROI obtained using task-activation maps from a working memory task in controls to select the seed. Again, the

right FI showed functional connectivity within a distributed ACC-FI network, as illustrated in Figure 2A (red color scale). Next, we examined the regions inversely correlated with the right FI seed. We found anticorrelated activity in PCC/preCu, retrosplenial cortex, lateral parietal areas, rmPFC, and hippocampi (Fig. 2A, blue color scale). Each of these clusters met the z-score threshold of 3.5. The bilateral lateral parietal and left hippocampal clusters also met the 12 voxel cluster-level threshold. PCC/preCu, retrosplenial cortex, rmPFC, and right hippocampus clusters fell below the cluster size threshold but are included in Figure 2A for illustrative purposes. Each of the anticorrelated regions identified is localized within the DMN, and no cortical regions were identified outside the DMN as previously characterized.⁵² Therefore, the ACC-FI network and the DMN, the ICNs which best recapitulate the neuronal injury patterns seen in bvFTD and AD (Fig. 2B), exhibit anticorrelated activity in the healthy human brain.

VEN Quantification in bvFTD and AD: Preliminary Evidence for Network-wide VEN Loss in bvFTD

The Yakovlev-Haleem Collection is a neuropathologic tissue archive at the National Museum of Health and Medicine that houses a range of human disease specimens prepared with whole brain sectioning. These materials, rarely generated at modern dementia research centers, provide a unique opportunity to probe specific regional and cellular anatomic questions. To gain preliminary support for the hypothesis that VENs are targeted in bvFTD throughout the ACC-FI network, we searched the collection for cases that would allow a comparison of VEN integrity in bvFTD and AD. We identified 1 patient with Pick disease (patient A) cut in the coronal plane. A patient with AD (patient B) provided a suitable comparison on the basis of a similar age and plane of section.

FIGURE 2. Reciprocal ICNs in the healthy human brain are targeted in bvFTD and AD. A, A right FI ROI was used to seed a functional connectivity MR analysis in 17 healthy young adults studied under task-free conditions. Regions exhibiting positive correlations with right FI (red color scale) recapitulate regions targeted in bvFTD. Regions negatively correlated with right FI (blue color scale) compose the DMN, targeted in AD. Colorbars indicate z-scores. B, Sagittal T1-weighted MRI scans from prototypical patients with bvFTD and AD. Selective regional atrophy in each disease follows the anticorrelated network connectivity patterns illustrated in (A). ANG indicates angular gyrus; DLPFC, dorsolateral prefrontal cortex; HC, hippocampus.



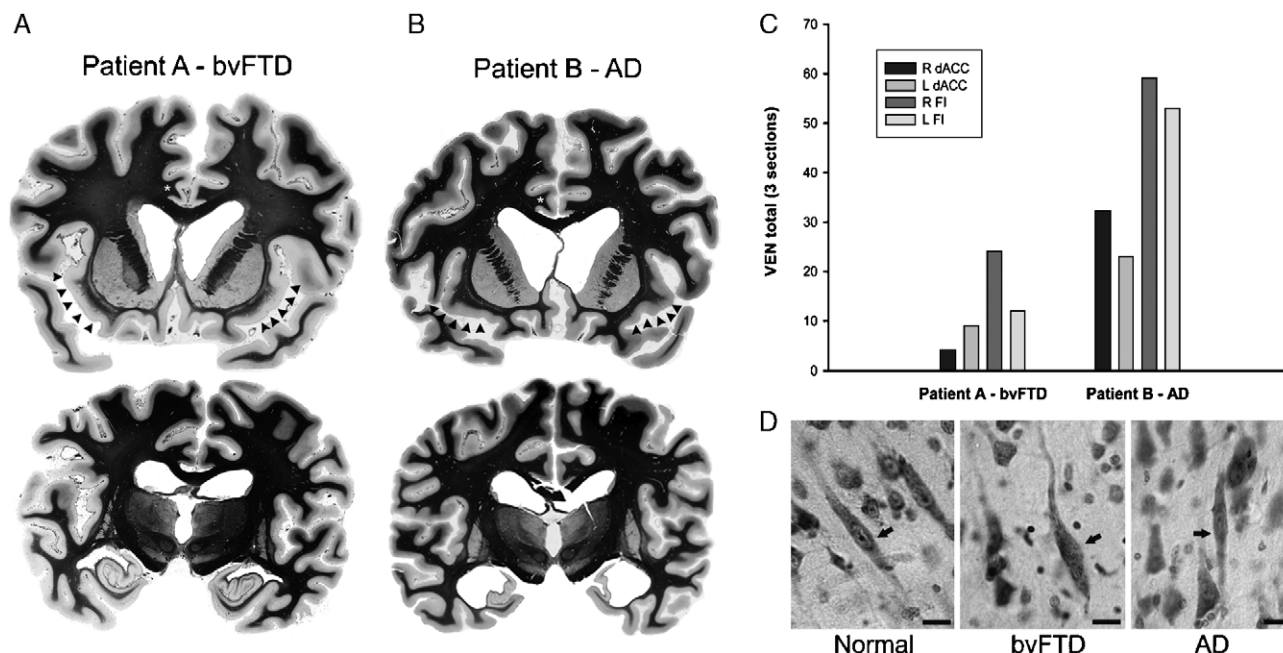


FIGURE 3. VEN loss in bvFTD: throughout the ACC-FI network? A and B, Myelin-stained sections from patients with bvFTD (A) and AD (B). VEN counting was performed on Nissl-stained sections, anatomically matched across subjects. VENs are located in the ACC (asterisks indicate white matter underlying right dorsal ACC) and FI (arrowheads). C, Patient A showed 60% to 90% lower VEN counts, throughout the ACC-FI network, compared with patient B. D, VENs in patient A, but not patient B, were also dysmorphic, consistent with a previous report.⁶⁴ Cresyl violet. Scale bars = 15 μ m.

Patient A was a 57-year-old man with progressive behavioral and cognitive decline, including childish overactivity, poor judgment, suspiciousness, distractibility, and memory loss, followed by late aphasia and parkinsonism. There was no family history of similar illness. Profoundly demented, he died of a pulmonary embolism 6 years after symptom onset. Applying bvFTD pathologic staging criteria,¹⁷ his gross atrophy was rated stage 1 to 2 on the basis of mild medial frontal, orbital-insular, and hippocampal atrophy, with flattening of the caudate head (Fig. 3A). The final pathologic diagnosis was Pick disease. Further histopathologic details were not available, but Nissl-stained sections revealed changes compatible with Pick's, including neuronal loss and increased cellularity suggestive of gliosis, with occasional swollen neurons. Because the diagnosis was rendered in 1963, it is uncertain whether Pick disease was meant to signify classical Pick-type histology or a nonspecific frontal degeneration. Therefore, we will refer to patient A's illness as bvFTD. Patient B was a 63-year-old man with a pathologic diagnosis of AD. No clinical or further histopathologic data were available, but profound hippocampal and moderate diffuse cortical atrophy support the diagnosis of AD (Fig. 3B).

Whole brain, 35- μ m-thick, celloidin-embedded, Nissl-stained coronal sections spanning FI and including the dorsal ACC were selected for counting. FI begins just caudal to the posterior orbital gyrus and runs laterally into the agranular anterior insula (Figs. 2A, B, arrow-

heads). VENs are found mainly in layer Vb. Dorsal ACC and FI VENs were counted, according to morphologic criteria described previously,⁶⁴ using 40 \times and 60 \times aperture objectives (as needed) on 3 sections per patient spaced 1.4 mm apart, moving from the rostral aspect of FI caudally. Counting sections were anatomically matched across patients to the nearest degree possible. Two examiners (W.W.S. and J.M.A.) visually searched the tissue at a 2-headed microscope, advancing through the ROIs manually because no motorized, computer-assistive technology was available at the collection at the time of study. Examiner consensus was required to designate any cell a VEN.

VEN counting results are summarized in Figure 3C. In patient A, VENs of the bilateral ACC and FI were devastated. Adding left and right ACC and FI counts over all sections, surviving VENs totaled 49. In contrast, 165 VENs were identified in patient B, including 39 VENs in a single section of left FI. Owing to the method used, these counts are likely underestimates of VEN abundance. Nonetheless, we found that VENs were reduced by 70% in a patient with bvFTD compared with a patient with AD, consistent with our previous larger study, which used systematic, unbiased stereologic techniques to quantify VENs in left ACC.⁶⁴ Furthermore, many VENs in patient A showed abnormal morphology, usually manifesting as twisted or distended somata, whereas VENs in patient B showed a normal size and shape (Fig. 3D). Collectively, these data suggest that VENs may

be targeted to a similar degree throughout the ACC-FI network, though this hypothesis requires larger scale investigation.

DISCUSSION

In bvFTD, the crowning social-emotional achievements of primate phylogeny and human ontogeny are relentlessly played in reverse. AD, in contrast, spares or even enhances these functions until moderate to severe disease stages. Our recent findings, combined with those presented here, suggest that bvFTD attacks a late-evolving and late-developing neuronal population, VENs. This neuronal selectivity occurs within a conserved paralimbic network dedicated, in humans and other mammals, to generation and re-representation of visceral-autonomic responses that serve adaptive behavioral choice. The limited neuropathologic data presented here are consistent with a large stereologic study of ACC VENs in controls, bvFTD, and AD.⁶⁴ Future studies should push these observations further by studying FI VENs in more patients and investigating the pathogenic cascade that leads to initial VEN injury and subsequent dropout.

How have VENs enhanced the human ACC-FI network? It seems that an ancestor common to apes and humans, living 10 to 15 million years ago, faced environmental pressures that selected for whatever new information processing capacity the VENs provide. Such pressures may have included, among others, the emergence of larger, more complex social groupings (requiring individuals to model and respond to other's intentions) and delayed sexual maturation (requiring long-term maternal-infant bonding). Encephalization itself may have created a pressure that favored VEN-containing brains, especially if VENs provide a service, such as fast, long-range impulse conduction; rapid summation of converging inputs; or a toggle between distributed reciprocal networks, from which large brains might benefit. The presence of VEN-like neurons in whales, also the most encephalized species of their lineage, supports the hypothesis that VENs are an evolutionary response to increasing brain size. The localization of VENs to ACC and FI (in both apes and whales) suggests that VENs require access to visceral-autonomic data to carry out their role in the brain. What this role might be remains a matter for further study.

The regional injury patterns of bvFTD and AD are now well-established.^{14,68} Functional imaging data from healthy humans, provided here and elsewhere,^{48,52,67,69} reveal that bvFTD and AD target distinct, large-scale, intrinsic brain networks that are anticorrelated in the undirected state. The ACC-FI network processes emotionally salient internal and external stimuli, in part by orchestrating visceral-autonomic responses. The DMN, in contrast, facilitates episodic memory retrieval and mental time travel^{30,31,70} but is deactivated when blood flow⁵¹ and electrophysiologic⁷¹ signals rise within ACC. Intriguingly, patient strengths may be as informative as

their impairments. Some patients with bvFTD develop newfound visual creativity. This disease-related gain of function has been hypothesized²⁴ and recently demonstrated⁷² to reflect enhancement of posterior cortical function. The reciprocal relationship between the ACC-FI network and the DMN helps explain this phenomenon, because ACC-FI impairment should predict intensified posterior parietal activity, which may, in turn, give rise to visual creativity. Conversely, many patients with AD show striking integrity, or even enhancement, of emotional sensitivity and social grace. Early AD-related damage to the DMN may amplify the ACC-FI network, facilitate VEN survival, and allow the sparing of empathy, eye contact, and social awareness that helps clinicians identify patients with AD and distinguish AD from other dementias.

Data summarized here suggest a clear link between bvFTD and human brain evolution. Might rapid brain evolution in humans have also predisposed us to AD? Medial temporal structures targeted in early AD are, like the ACC and FI, considered ancient in phylogeny, and a recent paper suggested conservation of the DMN among primates.⁵⁶ Yet chimpanzees, our nearest primate ancestors, do not develop dementia or form neuritic plaques or neurofibrillary tangles, even with advancing age, despite some senile amyloid plaque formation.⁷³ Conceivably, some subtle anatomic, functional, or epigenetic enhancement of the human DMN has rendered this large scale neural ensemble vulnerable to AD pathology. In this regard, we note that the rmPFC, the major anterior component of the DMN, is disproportionately expanded in humans compared with monkeys.³¹ This region, multifaceted in its roles,^{21,74,75} relates closely to ACC and may place new demands on both the ACC-FI and default mode networks. Perhaps some neural specializations, despite their advantages, have come at a cost. Further attention to human neuro-evolutionary adaptations may help clarify the pathogenesis of bvFTD, AD, and other diseases that strike at the core of the human experience.

ACKNOWLEDGMENTS

The authors thank Archibald Fobbs of the National Museum of Health and Medicine for his assistance at the Yakovlev-Haleem Collection and Michael Fox and Daniel Marcus for help with the BrainSCAPE website.

REFERENCES

1. Gallup GG Jr. Self-awareness and the emergence of mind in primates. *Am J Primatol.* 1982;2:237–248.
2. Wheeler MA, Stuss DT, Tulving E. Toward a theory of episodic memory: the frontal lobes and autoeotic consciousness. *Psychol Bull.* 1997;121:331–354.
3. Tulving E. Episodic memory: from mind to brain. *Annu Rev Psychol.* 2002;53:1–25.
4. Mulcahy NJ, Call J. Apes save tools for future use. *Science.* 2006;312:1038–1040.
5. Ratnavalli E, Brayne C, Dawson K, et al. The prevalence of frontotemporal dementia. *Neurology.* 2002;58:1615–1621.

6. Sturm VE, Rosen HJ, Allison S, et al. Self-conscious emotion deficits in frontotemporal lobar degeneration. *Brain*. 2006;129:2508–2516.
7. Lough S, Kipps CM, Treise C, et al. Social reasoning, emotion and empathy in frontotemporal dementia. *Neuropsychologia*. 2006;44:950–958.
8. Eslinger PJ, Dennis K, Moore P, et al. Metacognitive deficits in frontotemporal dementia. *J Neurol Neurosurg Psychiatry*. 2005;76:1630–1635.
9. Rankin KP, Kramer JH, Miller BL. Patterns of cognitive and emotional empathy in frontotemporal lobar degeneration. *Cogn Behav Neurol*. 2005;18:28–36.
10. Mendez MF, Anderson E, Shapira JS. An investigation of moral judgement in frontotemporal dementia. *Cogn Behav Neurol*. 2005;18:193–197.
11. Miller BL, Seeley WW, Mychack P, et al. Neuroanatomy of the self: evidence from patients with frontotemporal dementia. *Neurology*. 2001;57:817–821.
12. Seeley W, Miller B. Disorders of the self in dementia. In: Feinberg T, Keenan JP, ed. *The Lost Self: Pathologies of Brain and Identity*. New York: Oxford; 2005.
13. Lewis M, Sullivan MW, Stanger C, et al. Self development and self-conscious emotions. *Child Dev*. 1989;60:146–156.
14. Schroeter ML, Raczka K, Neumann J, et al. Neural networks in frontotemporal dementia—A meta-analysis. *Neurobiol Aging*. [Epub: 29 Nov 2006].
15. Brun A, Gustafson L. Limbic lobe involvement in presenile dementia. *Arch Psychiatr Nervenkr*. 1978;226:79–93.
16. Rosen HJ, Gorno-Tempini ML, Goldman WP, et al. Patterns of brain atrophy in frontotemporal dementia and semantic dementia. *Neurology*. 2002;58:198–208.
17. Broe M, Hodges JR, Schofield E, et al. Staging disease severity in pathologically confirmed cases of frontotemporal dementia. *Neurology*. 2003;60:1005–1011.
18. Kril JJ, Macdonald V, Patel S, et al. Distribution of brain atrophy in behavioral variant frontotemporal dementia. *J Neurol Sci*. 2005;232:83–90.
19. Seeley WW, Crawford RK, Rascovsky K, et al. Stage-related atrophy in frontotemporal dementia: early disease affects a frontal paralimbic network. *Arch Neurol*. In press.
20. Boccardi M, Sabatoli F, Laakso MP, et al. Frontotemporal dementia as a neural system disease. *Neurobiol Aging*. 2005;26:37–44.
21. Seeley W, Sturm V. Self-representation and the frontal lobes. In: Miller BL, Cummings J, eds. *The Human Frontal Lobes*. New York: Guilford; 2006.
22. Ochsner KN, Knierim K, Ludlow DH, et al. Reflecting upon feelings: an fMRI study of neural systems supporting the attribution of emotion to self and other. *J Cogn Neurosci*. 2004;16:1746–1772.
23. Singer T, Seymour B, O'Doherty J, et al. Empathy for pain involves the affective but not sensory components of pain. *Science*. 2004;303:1157–1162.
24. Miller BL, Cummings J, Mishkin F, et al. Emergence of artistic talent in frontotemporal dementia. *Neurology*. 1998;51:978–982.
25. Braak H, Braak E. Neuropathological staging of Alzheimer-related changes. *Acta Neuropathol*. 1991;82:239–259.
26. Hyman BT, Damasio AR, Van Hoesen GW, et al. Alzheimer's disease: cell-specific pathology isolates the hippocampal formation. *Science*. 1984;298:83–95.
27. de Leon MJ, Mosconi L, Blennow K, et al. Imaging and CSF studies in the preclinical diagnosis of Alzheimer's disease. *Ann N Y Acad Sci*. 2007;1097:114–145.
28. Greicius MD, Srivastava G, Reiss AL, et al. Default-mode network activity distinguishes Alzheimer's disease from healthy aging: evidence from functional MRI. *Proc Natl Acad Sci USA*. 2004;101:4637–4642.
29. Reiman EM, Caselli RJ, Yun LS, et al. Preclinical evidence of Alzheimer's disease in persons homozygous for the epsilon 4 allele for apolipoprotein E. *N Engl J Med*. 1996;334:752–758.
30. Buckner RL, Snyder AZ, Shannon BJ, et al. Molecular, structural, and functional characterization of Alzheimer's disease: evidence for a relationship between default activity, amyloid, and memory. *J Neurosci*. 2005;25:7709–7717.
31. Vincent JL, Snyder AZ, Fox MD, et al. Coherent spontaneous activity identifies a hippocampal-parietal memory network. *J Neurophysiol*. 2006;96:3517–3531.
32. Brun A, Gustafson L. Distribution of cerebral degeneration in Alzheimer's disease. A clinico-pathological study. *Arch Psychiatr Nervenkr*. 1976;223:15–33.
33. Varrone A, Pappata S, Caraco C, et al. Voxel-based comparison of rCBF SPET images in frontotemporal dementia and Alzheimer's disease highlights the involvement of different cortical networks. *Eur J Nucl Med Mol Imaging*. 2002;29:1447–1454.
34. Rabinovici GD, Seeley WW, Pagliaro TA, et al. MRI atrophy patterns in autopsy-proven Alzheimer's disease and frontotemporal lobar degeneration. *Am J Alzheimer Dis Other Demen*. In press.
35. Rascovsky K, Salmon DP, Ho GJ, et al. Cognitive profiles differ in autopsy-confirmed frontotemporal dementia and AD. *Neurology*. 2002;58:1801–1808.
36. Critchley HD, Wiens S, Rotshtein P, et al. Neural systems supporting interoceptive awareness. *Nat Neurosci*. 2004;7:189–195.
37. Critchley HD, Elliott R, Mathias CJ, et al. Neural activity relating to generation and representation of galvanic skin conductance responses: a functional magnetic resonance imaging study. *J Neurosci*. 2000;20:3033–3040.
38. Craig AD. How do you feel? Interoception: the sense of the physiological condition of the body. *Nat Rev Neurosci*. 2002;3:655–666.
39. Rainville P, Duncan GH, Price DD, et al. Pain affect encoded in human anterior cingulate but not somatosensory cortex. *Science*. 1997;277:968–971.
40. Teves D, Videen TO, Cryer PE, et al. Activation of human medial prefrontal cortex during autonomic responses to hypoglycemia. *Proc Natl Acad Sci USA*. 2004;101:6217–6221.
41. Craig AD. Interoception: the sense of the physiological condition of the body. *Curr Opin Neurobiol*. 2003;13:500–505.
42. Bartels A, Zeki S. The neural correlates of maternal and romantic love. *Neuroimage*. 2004;21:1155–1166.
43. Singer T, Kiebel SJ, Winston JS, et al. Brain responses to the acquired moral status of faces. *Neuron*. 2004;41:653–662.
44. Eisenberger NI, Lieberman MD, Williams KD. Does rejection hurt? An fMRI study of social exclusion. *Science*. 2003;302:290–292.
45. Grinband J, Hirsch J, Ferrera VP. A neural representation of categorization uncertainty in the human brain. *Neuron*. 2006;49:757–763.
46. Dosenbach NU, Visscher KM, Palmer ED, et al. A core system for the implementation of task sets. *Neuron*. 2006;50:799–812.
47. Critchley HD. Neural mechanisms of autonomic, affective, and cognitive integration. *J Comp Neurol*. 2005;493:154–166.
48. Seeley WW, Menon V, Schatzberg AF, et al. Dissociable intrinsic connectivity networks for salience processing and executive control. *J Neurosci*. 2007;27:2349–2356.
49. Beckmann CF, DeLuca M, Devlin JT, et al. Investigations into resting-state connectivity using independent component analysis. *Philos Trans R Soc Lond B Biol Sci*. 2005;360:1001–1013.
50. Snowden JS, Bathgate D, Varma A, et al. Distinct behavioural profiles in frontotemporal dementia and semantic dementia. *J Neurol Neurosurg Psychiatry*. 2001;70:323–332.
51. Raichle ME, MacLeod AM, Snyder AZ, et al. A default mode of brain function. *Proc Natl Acad Sci USA*. 2001;98:676–682.
52. Greicius MD, Krasnow B, Reiss AL, et al. Functional connectivity in the resting brain: a network analysis of the default mode hypothesis. *Proc Natl Acad Sci USA*. 2003;100:253–258.
53. Gusnard DA, Akbudak E, Shulman GL, et al. Medial prefrontal cortex and self-referential mental activity: relation to a default mode of brain function. *Proc Natl Acad Sci USA*. 2001;98:4259–4264.
54. Mason MF, Norton MI, Van Horn JD, et al. Wandering minds: the default network and stimulus-independent thought. *Science*. 2007;315:393–395.
55. Addis DR, Wong AT, Schacter DL. Remembering the past and imagining the future: common and distinct neural substrates during

- event construction and elaboration. *Neuropsychologia*. 2007;45:1363–1377.
56. Vincent JL, Patel GH, Fox MD, et al. Intrinsic functional architecture in the anaesthetized monkey brain. *Nature*. 2007;447:83–86.
57. Sanides F. Comparative architectonics of neocortex of mammals and their evolutionary interpretation. *Ann NY Acad Sci*. 1969;167:404–423.
58. Betz W. Ueber die feinere Structur der Gehirnrinde des Menschen. *Zentralbl Med Wiss*. 1881;19:193–115, 209–213, 231–234.
59. von Economo C. Eine neue Art Spezialzellen des Lobus cinguli und Lobus insulae. *Z Ges Neurol Psychiatr*. 1926;100:706–712.
60. Nimchinsky EA, Vogt BA, Morrison JH, et al. Spindle neurons of the human anterior cingulate cortex. *J Comp Neurol*. 1995;355:27–37.
61. Allman JM, Watson KK, Tetreault NA, et al. Intuition and autism: a possible role for Von Economo neurons. *Trends Cogn Sci*. 2005;9:367–373.
62. Nimchinsky EA, Gilissen E, Allman JM, et al. A neuronal morphologic type unique to humans and great apes. *Proc Natl Acad Sci USA*. 1999;96:5268–5273.
63. Watson KK, Jones TK, Allman JM. Dendritic architecture of the von Economo neurons. *Neuroscience*. 2006;141:1107–1112.
64. Seeley WW, Carlin DA, Allman JM, et al. Early frontotemporal dementia targets neurons unique to apes and humans. *Ann Neurol*. 2006;60:660–667.
65. Fox MD, Marcus DM, Snyder AZ, et al. BrainSCAPE: an online spontaneous correlation analysis processing environment for fMRI BOLD data. *Neuroimage: 13th Annual Meeting of the Organization for Human Brain Mapping*. 2007;36.
66. Fox MD, Snyder AZ, Vincent JL, et al. Intrinsic fluctuations within cortical systems account for inter-trial variability in human behavior. *Neuron*. 2007. In press.
67. Fox MD, Snyder AZ, Vincent JL, et al. The human brain is intrinsically organized into dynamic, anticorrelated functional networks. *Proc Natl Acad Sci USA*. 2005;102:9673–9678.
68. Whitwell JL, Jack CR Jr. Comparisons between Alzheimer disease, frontotemporal lobar degeneration, and normal aging with brain mapping. *Top Magn Reson Imaging*. 2005;16:409–425.
69. Fransson P. Spontaneous low-frequency BOLD signal fluctuations: an fMRI investigation of the resting-state default mode of brain function hypothesis. *Hum Brain Mapp*. 2005;26:15–29.
70. Mason MF, Banfield JF, Macrae CN. Thinking About actions: the neural substrates of person knowledge. *Cereb Cortex*. 2004;14:209–214.
71. Scheeringa R, Bastiaansen MC, Petersson KM, et al. Frontal theta EEG activity correlates negatively with the default mode network in resting state. *Int J Psychophysiol*. 2007.
72. Seeley WW, Matthews BL, Crawford RK, et al. Unravelling Bolero: progressive aphasia, transmodal creativity, and the right posterior neocortex. *Brain*. In press.
73. Gearing M, Rebeck GW, Hyman BT, et al. Neuropathology and apolipoprotein E profile of aged chimpanzees: implications for Alzheimer disease. *Proc Natl Acad Sci USA*. 1994;91:9382–9386.
74. Zysset S, Huber O, Ferstl E, et al. The anterior frontomedian cortex and evaluative judgment: an fMRI study. *Neuroimage*. 2002;15:983–991.
75. Johnson SC, Baxter LC, Wilder LS, et al. Neural correlates of self-reflection. *Brain*. 2002;125:1808–1814.