



Does genetic anticipation occur in familial Alexander disease?

Camille K. Hunt¹ · Ahmad Al Khleifat¹ · Ella Burchill¹ · Joerg Ederle² · Ammar Al-Chalabi¹ · Jemeen Sreedharan¹ 

Received: 8 January 2021 / Accepted: 18 April 2021 / Published online: 28 May 2021
© The Author(s) 2021

Abstract

Alexander Disease (AxD) is a rare leukodystrophy caused by missense mutations of glial fibrillary acidic protein (*GFAP*). Primarily seen in infants and juveniles, it can present in adulthood. We report a family with inherited AxD in which the mother presented with symptoms many years after her daughter. We reviewed the age of onset in all published cases of familial AxD and found that 32 of 34 instances of parent–offspring pairs demonstrated an earlier age of onset in offspring compared to the parent. We suggest that genetic anticipation occurs in familial AxD and speculate that genetic mosaicism could explain this phenomenon.

Keywords Alexander disease · GFAP · Anticipation · Mosaicism

Case history

The proband had no prior medical history and normal early development. She presented to the neurology department aged 45 with an 8-month history of stiffness in all four limbs and poor balance. Despite this, she was running a café independently. There were no sphincter or sensory disturbances. Examination revealed poorly responsive pupils, a prominent jaw jerk and slight dysarthria. She had slow, spastic speech and slow tongue movements with no tongue wasting. She had marked spasticity in all limbs with brisk reflexes, which was slightly worse on the left, with normal strength except for the left first dorsal interosseous muscle (MRC grade 4). Her plantar reflexes were equivocal. There were no lower motor neuron features, no cerebellar signs and sensory examination was normal.

MRI scans of her brain and cervical spine were conducted at her local hospital and reported as normal. Spinal fluid demonstrated normal cellular constituents, normal glucose and CSF protein and no oligoclonal bands. Clinical

neurophysiology assessments demonstrated normal nerve conduction and electromyography. However, central motor conduction times to intrinsic hand and foot muscles were markedly increased. Collectively, these findings were consistent with a progressive, degenerative purely upper motor neuron syndrome affecting limbs and with a pseudobulbar component. A presumptive diagnosis of primary lateral sclerosis was made and baclofen was commenced to treat spasticity. Her condition progressively deteriorated, impairing her mobility such that she had to retire from work. Six years after symptom onset, aged 51, she remained free of lower motor neuron signs. She was then lost to follow-up.

Three years after the proband's last assessment, her 71-year-old mother presented to our clinic with a history strikingly reminiscent of her daughter's ailments. The patient described weakness progressing over 4 years with recent dysphagia. At presentation she was wheelchair dependent. Examination demonstrated extreme weight loss, prominent palmomental reflexes, a bovine cough and spastic, dysarthric speech. No muscle wasting or fasciculations were observed in cranial or limb territories. Tone was increased in all limbs, with a pyramidal pattern of weakness, MRC grade 4 in the proximal limb muscles. Deep tendon reflexes were brisk and plantars were extensor. Brain MRI demonstrated cervicomedullary atrophy (Fig. 1a, b) suggesting a diagnosis of adult-onset AxD. A DNA sample for *GFAP* mutation screening to confirm the diagnosis could not be obtained, as the patient developed a chest infection and died soon after her

Camille K. Hunt and Ahmad Al Khleifat contributed equally to this work.

✉ Jemeen Sreedharan
Jemeen.sreedharan@kcl.ac.uk

¹ Department of Basic and Clinical Neuroscience, King's College London, London, UK

² Department of Neuroradiology, King's College Hospital NHS Trust, London, UK

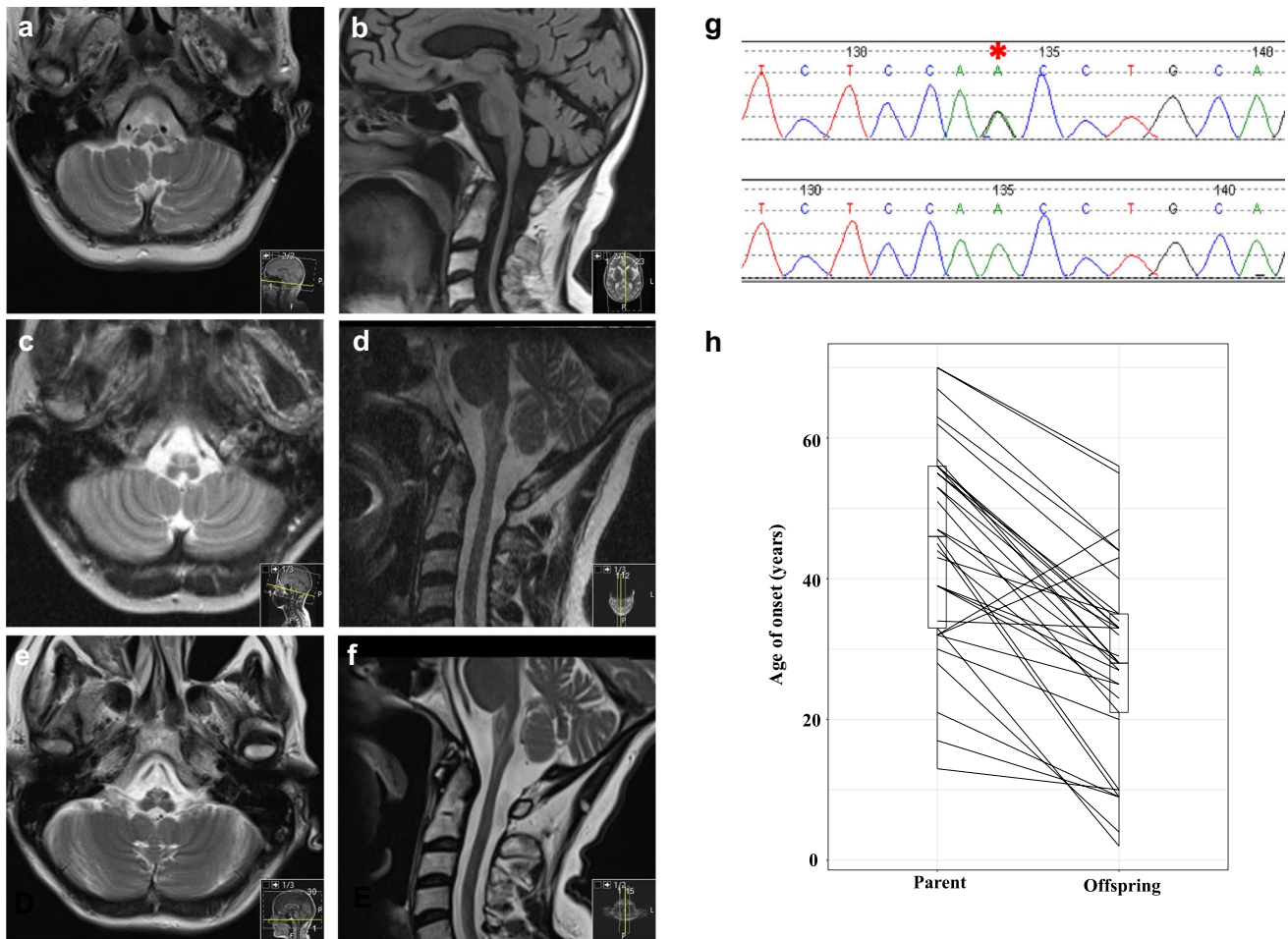


Fig. 1 a–f MRI scans of proband and mother. Axial T2 (a) and parasagittal FLAIR (b) of proband’s mother at the time of presentation showing upper cervical spinal cord and medullary volume loss and demyelination. Axial T2 (c) and sagittal T2 (d) of proband at initial presentation and at the time of re-call to clinic (e, f). g DNA chromatograms demonstrating proband’s DNA sequence (top, *GFAP* mutation highlighted with asterisk) and a control DNA sequence. h Paired

boxplot comparing age of onset between 34 parents and 34 offspring with familial AxD. Lines between boxplots represent individual parent–offspring pairs. Boxplot bars indicate 95% confidence intervals. PairedData package was used to generate the effect plot on R. Paired sample *t* test showed a mean 14% decrease in age of onset in the offspring group compared to parents ($p = 2.02 \times 10^{-9}$, 95% CI for the difference 12.64–20.93 years)

MRI scan. However, we reconnected with the proband who returned to clinic for review.

By now, aged 54, the proband was wheelchair dependent. She reported intermittent choking on food. On neurological examination, she was alert and oriented. The pupils were equal at 3 mm and slowly reactive to light. She had weakness of neck flexion, a weak cough, spastic speech and a brisk jaw jerk. In addition to marked spasticity in all four limbs, she had proximal weakness of grade 4 in both upper and lower limbs in a pyramidal pattern, and all deep tendon reflexes were brisk. There were no lower motor neuron signs and no sensory deficits.

She underwent a repeat MRI brain scan (Fig. 1e, f), which showed marked thinning of the medulla oblongata and cervical cord at the cervicomedullary junction. Increased T2 cord signal/FLAIR foci were noted in the

medulla with global cerebral atrophy in excess for her age. These features were similar to those of her mother and consistent with adult-onset AxD. Her previous imaging was obtained for comparison and on review by a specialist neuroradiologist was concluded to be consistent with AxD (Fig. 1c, d). A DNA sample was obtained and sequencing showed heterozygosity for the *GFAP* mutation c.1157A > G (p.Asn386Ser) (Fig. 1g). This mutation occurs in the C-terminal tail domain of GFAP and is predicted to be deleterious, with a combined annotation-dependent depletion score of 23.3 (CADD v1.6). The same sequence change has been reported several times in patients with AxD [1, 2] but only once in the gnomAD database of controls. Ours is the first description of this mutation in a case of familial AxD.

Analysis of familial Alexander disease

An intriguing aspect of this family is that the age of symptom onset in the mother was greater than in the daughter by over two decades. Variable expressivity occurs in AxD [3, 4], but here both mother and daughter had strikingly similar phenotypes. Whilst variable penetrance of the *GFAP* mutation could explain the daughter’s much earlier age of onset, another possibility is genetic anticipation. To investigate further, we reviewed all previously published cases of familial AxD, searching Pubmed using the criteria

“alexander [title] disease [title]”. We identified 22 studies reporting 37 instances of inherited AxD (Table 1) [3, 3–25]. Data on age of onset was available for 34 parents (27 female: 7 male) and 34 offspring (17 female: 17 male). The mean age of onset in the affected parents was 43.8 years (95% CI 38.2–49.4 years), and in offspring, 27.4 years (95% CI 22.4–32.4 years) (Fig. 1h). Paired sample *t* test showed a mean 14% decrease of the age of onset in the offspring group compared to parents ($p = 2.02 \times 10^{-9}$, 95% CI for the difference 12.64–20.93 years). This suggests that genetic anticipation is influencing disease onset in AxD.

Table 1 Summary of published cases of familial Alexander disease. Cases highlighted in blue text showed earlier age of onset in parent compared to offspring, whilst other cases demonstrated earlier age of onset in offspring. Purple cases were excluded from analysis as age

of onset (actual or approximate) for either parent or offspring was not given or parent was asymptomatic. *AoO*, age of onset. *N/A* not applicable as asymptomatic

AoO Parent	Sex	Mutation	AoO Offspring	Sex	Mutation	Notes	Supplementary Reference
67	F	Not done	44	F	N386S		Current study
		M45II	33	F	M45II		[5]
56	F	M45II	34	M	M45II		[5]
46	F	G18V	10	M	G18V		[6]
17	F	G18V	9	M	G18V		[6]
47	F	not done	28	F	R416W	47F had maternal aunt with similar but mild symptoms with AoO of 54 (progressing slowly)	[7]
		not done	56	F	D78N		[8]
70	F	not done	55	F	D78N		[8]
57	M	A330G & G332L	28	M	A330G & G332L	57M has affected sibling, AoO 53F	[9]
47	F	not done	33	F	E373A		[10]
44	M	not done	23	M	S385C		[10]
63	F	not done	44	M	not done	neither case genetically confirmed	[10]
30	F	Y242N	20	M	Y242N	The son was only able to pull himself up to stand after 1y of age. He performed exercise poorly around the time he entered high school. Age 20, diagnosed with developmental disorder. Age 35, lightheaded and prone to falling.	[11]
34	F	not done	33	F	S393I	33F is mother of patient below	[12]
33	F	S393I	2	M	S393I	33F is daughter of patient above	[12]
56	M	R330G & E332K	28	M	R330G & E332K	56M has two sisters AoO 53y; asymptomatic	[13]
			25	F	not done	Additional arm of this family appear to have AxD as well, but no details on AoO. MRI and pathology but no genetics. 39F said to have had AoO in 'late 30s'	[14]
			27	M	not done		[14]
39	F	Not done	29	F	not done		[14]
62	F	E223Q	40	M	E223Q	not stated that mother is suspected of being afflicted by AOAD	[15]
53	F	V87G	27	F	V87G		[16]
53	F	V87G	32	M	V87G	In offspring, hyperreflexia and extensor plantar noted age 32	[16]
32	M	D417A	43	F	D417A	Offspring has later AoO than parent	[17-19]
32	M	D417A	25	F	not done		[17-19]
32	M	D417A	47	F	not done	Offspring has later AoO than parent	[17-19]
43	F	D417A - inferred	35	F	not done	Offspring AoO noted as 'in 30s'	[17-19]
45	F	Q426L	9	F	Q426L	Offspring had scoliosis age 9. Bipolar disease. Died aged 21 from alcohol overdose. Had GFAP pathology	[17]
55	F	D78E	35	F	D78E		[3]
55	F	D78E	33	M	D78E		[3]
51	M	D78E	21	F	D78E	Parental AoO noted as '>50'. Offspring AoO '>20'	[3]
21	F	D78E	9	M	D78E	Parental AoO noted as '>20'. Offspring AoO '<10'. Possibly from consanguineous relationship	[3]
28	F	R376W	4	M	R376W		[20]
37	F	R416W	?	M	R416W	37F parent had scoliosis age 12, gait disturbance age 37. No AoO for son. Had intellectual disability, AoO not given.	[21]
13	F	R88C	10	M	R88C	The mother is patient '3' and the son patient '4' in this study	[22]
5	F	R88C & D295N	3	M	R88C & D295N	Lists AoO in childhood for both parent (AoO '>4') and offspring (AoO '>4') but says that mother has classical clinical picture of adult onset AxD	[23]
N/A	F	R79H	6	F	R79H	Daughter is patient '17' in this study. Mother was asymptomatic with MRI changes.	[24]
58	M	Y257C	?	M	not done	Offspring clearly had earlier onset but AoO not given.	[25]

Discussion

Genetic anticipation is a feature of neurological conditions linked to unstable nucleotide repeat motifs, such as Huntington's disease. Genetic anticipation has also been described in polygenic disorders including Crohn's disease and breast cancer, and in monogenic disorders such as von Hippel-Lindau syndrome. The mechanisms underlying apparent genetic anticipation in these conditions are unclear. Statistical artefacts such as ascertainment bias may be contributing factors, but these can be controlled for [26]. Indeed, in our family, this bias is highly unlikely given that the daughter was diagnosed before her mother had any symptoms. How genetic anticipation could occur in AxD, a disease caused largely by missense mutations, is unclear but there are several possibilities. For example, there may be a microsatellite repeat near the *GFAP* gene that influences its expression and expands during transmission, or epigenetic factors such as DNA methylation changes that influence *GFAP* expression. Alternatively, there may be linkage disequilibrium of the *GFAP* mutation with another variant that directly contributes to disease and gives rise to anticipation, such as a repeat expansion.

We postulate that another mechanism may explain apparent anticipation: genetic mosaicism. In AxD, most cases are caused by de novo mutations [27]. It is plausible that if an embryo developed a spontaneous *GFAP* mutation beyond the single-cell stage, it would be mosaic for this mutation, which could mean that only a fraction of the nervous system would express mutant *GFAP*. This could attenuate disease severity and delay the age of onset. If the mutation was present in the germ cells of this mosaic patient, it could be transmitted to their offspring, who would then express the mutation ubiquitously, resulting in a more severe phenotype and earlier age of onset. Interestingly, a person with AxD has been described in which a *GFAP* mutation was found to be present in cells taken from a cheek swab, but absent from DNA extracted from blood, indicating somatic mosaicism [28]. To our knowledge, mosaicism has not previously been suggested as a cause of apparent anticipation. We were unable to test this hypothesis in our family but suggest that this should be considered in future instances of inherited AxD. This would require sequencing of DNA extracted from different brain regions at post-mortem, or, where brain tissue is unavailable, comparison of peripheral tissues, such as skin, saliva and lymphocyte derived DNA.

Acknowledgements We are grateful for the participation and assistance of the proband and her family. We are grateful to the Rare & Inherited Disease Laboratory, London North Genomic Laboratory Hub, Great Ormond Street Hospital for performing *GFAP* mutation screening. This is an EU Joint Programme—Neurodegenerative Disease Research (JPND) project. The project is supported through the following funding organisations under the aegis of JPND—www.jpnd.eu (United

Kingdom, Medical Research Council (MR/L501529/1; MR/R024804/1) and Economic and Social Research Council (ES/L008238/1)). JS acknowledges funding support from the Rosetrees Trust (M799) and the van Geest Foundation. AAC is an NIHR Senior Investigator. This study represents independent research part funded by the National Institute for Health Research (NIHR) Biomedical Research Centre at South London and Maudsley NHS Foundation Trust and King's College London. AAK is funded by The Motor Neurone Disease Association and NIHR Maudsley Biomedical Research Centre.

Author contribution JS reviewed patient clinical details. CKH performed the literature search, acquired the age of onset data and generated Table 1. AA-K analysed the age of onset data. JE reviewed neuroimaging. AA-C analysed the age of onset data. EB referenced the article. JS examined the patient, designed the project and wrote the manuscript with contributions from all authors.

Funding This is an EU Joint Programme—Neurodegenerative Disease Research (JPND) project. The project is supported through the following funding organisations under the aegis of JPND—www.jpnd.eu (United Kingdom, Medical Research Council (MR/L501529/1; MR/R024804/1) and Economic and Social Research Council (ES/L008238/1)). JS acknowledges funding support from the Rosetrees Trust (M799) and the van Geest Foundation.

Declarations

Ethics approval/consent to participate Not applicable.

Consent for publication Consent was obtained from the proband of the family described.

Competing interests Ammar Al-Chalabi is a consultant for Mitsubishi-Tanabe Pharma, GSK, and Chronos Therapeutics and chief investigator for clinical trials for Cytokinetics and OrionPharma. All other authors declare no competing interests.

Open Access This article is licensed under a Creative Commons Attribution 4.0 International License, which permits use, sharing, adaptation, distribution and reproduction in any medium or format, as long as you give appropriate credit to the original author(s) and the source, provide a link to the Creative Commons licence, and indicate if changes were made. The images or other third party material in this article are included in the article's Creative Commons licence, unless indicated otherwise in a credit line to the material. If material is not included in the article's Creative Commons licence and your intended use is not permitted by statutory regulation or exceeds the permitted use, you will need to obtain permission directly from the copyright holder. To view a copy of this licence, visit <http://creativecommons.org/licenses/by/4.0/>.

References

1. Lichtenstein ML, Dwosh E, Chowdhury AR et al (2017) Neurobehavioral characterization of adult-onset Alexander disease A family study. *Neurol Clin Pract*. <https://doi.org/10.1212/CPJ.0000000000000356>
2. Draghi L, Salsano E, Farina L et al (2019) Neuropsychological features of adult form of Alexander disease. *J Neurol Sci*. <https://doi.org/10.1016/j.jns.2019.04.030>
3. Stumpf E, Masson H, Duquette A et al (2003) Adult Alexander disease with autosomal dominant transmission: a distinct entity

- caused by mutation in the glial fibrillary acid protein gene. *JAMA Neurol* 60:1307–1312. <https://doi.org/10.1001/archneur.60.9.1307>
4. Sreedharan J, Shaw CE, Jarosz J, Samuel M (2007) Alexander disease with hypothermia, microcoria, and psychiatric and endocrine disturbances. *Neurology*. <https://doi.org/10.1212/01.wnl.0000259543.95222.9d>
 5. Elmali AD, Çetinelik Ü, Işlak C et al (2016) Familial adult-onset alexander disease: clinical and neuroradiological findings of three cases. *Noropsikiyatri Ars*. <https://doi.org/10.5152/npa.2015.10193>
 6. Casasnovas C, Verdura E, Vélez V et al (2019) A novel mutation in the GFAP gene expands the phenotype of Alexander disease. *J Med Genet*. <https://doi.org/10.1136/jmedgenet-2018-105959>
 7. Liu Y, Zhou H, Wang H et al (2016) Atypical MRI features in familial adult onset Alexander disease: Case report. *BMC Neurol*. <https://doi.org/10.1186/s12883-016-0734-9>
 8. Wada Y, Yanagihara C, Nishimura Y, Namekawa M (2013) Familial adult-onset Alexander disease with a novel mutation (D78N) in the glial fibrillary acidic protein gene with unusual bilateral basal ganglia involvement. *J Neurol Sci*. <https://doi.org/10.1016/j.jns.2013.05.019>
 9. Balbi P, Seri M, Ceccherini I et al (2008) Adult-onset Alexander disease: report on a family. *J Neurol*. <https://doi.org/10.1007/s00415-007-0654-0>
 10. Graff-Radford J, Schwartz K, Gavrilova RH et al (2014) Neuroimaging and clinical features in type II (late-onset) Alexander disease. *Neurology*. <https://doi.org/10.1212/01.wnl.0000438230.33223.bc>
 11. Ogura H, Maki F, Sasaki N et al (2016) Familial adult-onset Alexander disease with a novel GFAP Mutation. *Mov Disord Clin Pract*. <https://doi.org/10.1002/mdc3.12296>
 12. Salmaggi A, Botturi A, Lamperti E, et al (2007) A novel mutation in the GFAP gene in a familial adult onset Alexander disease. *JNeurol*. <https://doi.org/10.1007/s00415-006-0361-2>
 13. Bachetti T, Caroli F, Bocca P et al (2008) Mild functional effects of a novel GFAP mutant allele identified in a familial case of adult-onset Alexander disease. *Eur J Hum Genet*. <https://doi.org/10.1038/sj.ejhg.5201995>
 14. Howard RS, Greenwood R, Gawler J et al (1993) A familial disorder associated with palatal myoclonus, other brainstem signs, tetraparesis, ataxia and Rosenthal fibre formation. *J Neurol Neurosurg Psychiatry*. <https://doi.org/10.1136/jnnp.56.9.977>
 15. Brockmann K, Meins M, Taubert A et al (2003) A novel GFAP mutation and disseminated white matter lesions: adult alexander disease? *Eur Neurol*. <https://doi.org/10.1159/000072507>
 16. Okamoto Y, Mitsuyama H, Jonosono M et al (2002) Autosomal dominant palatal myoclonus and spinal cord atrophy. *J Neurol Sci*. [https://doi.org/10.1016/S0022-510X\(01\)00687-6](https://doi.org/10.1016/S0022-510X(01)00687-6)
 17. Messing A, Li R, Naidu S et al (2012) Archetypal and new families with Alexander disease and novel mutations in GFAP. *Arch Neurol*. <https://doi.org/10.1001/archneurol.2011.1181>
 18. Seil FJ, Schochet SS, Earle KM (1968) Alexander's disease in an adult: report of a case. *Arch Neurol*. <https://doi.org/10.1001/archneur.1968.00480050064006>
 19. Schwankhaus JD, Parisi JE, Gullledge WR et al (1995) Hereditary adult-onset alexander's disease with palatal myoclonus, spastic paraparesis, and cerebellar ataxia. *Neurology*. <https://doi.org/10.1212/WNL.45.12.2266>
 20. Hirayama T, Fukae J, Noda K et al (2008) Adult-onset Alexander disease with palatal myoclonus and intraventricular tumour [6]. *Eur J Neurol*
 21. Thyagarajan D, Chataway T, Li R et al (2004) Dominantly-inherited adult-onset leukodystrophy with palatal tremor caused by a mutation in the glial fibrillary acidic protein gene. *Mov Disord*. <https://doi.org/10.1002/mds.20161>
 22. Van Der Knaap MS, Ramesh V, Schiffmann R et al (2006) Alexander disease: ventricular garlands and abnormalities of the medulla and spinal cord. *Neurology*. <https://doi.org/10.1212/01.wnl.0000198770.80743.37>
 23. Tonduiti D, Ardisson A, Ceccherini I et al (2016) Unusual presentations and intrafamilial phenotypic variability in infantile onset Alexander disease. *Neurol Sci*. <https://doi.org/10.1007/s10072-015-2466-9>
 24. Zang L, Wang J, Jiang Y et al (2013) Follow-up study of 22 Chinese children with Alexander disease and analysis of parental origin of de novo GFAP mutations. *J Hum Genet*. <https://doi.org/10.1038/jhg.2012.152>
 25. Howard KL, Hall DA, Moon M et al (2008) Adult-onset Alexander disease with progressive ataxia and palatal tremor. *Mov Disord*. <https://doi.org/10.1002/mds.21774>
 26. Fraser FC (1997) Trinucleotide repeats not the only cause of anticipation. *Lancet*. [https://doi.org/10.1016/S0140-6736\(05\)63077-2](https://doi.org/10.1016/S0140-6736(05)63077-2)
 27. Li R, Johnson AB, Salomons G et al (2005) Glial fibrillary acidic protein mutations in infantile, juvenile, and adult forms of Alexander disease. *Ann Neurol*. <https://doi.org/10.1002/ana.20406>
 28. Flint D, Li R, Webster LS et al (2012) Splice site, frameshift, and chimeric GFAP mutations in Alexander disease. *Hum Mutat*. <https://doi.org/10.1002/humu.22094>

Publisher's Note Springer Nature remains neutral with regard to jurisdictional claims in published maps and institutional affiliations.