

Does This Patient Have Deep Vein Thrombosis?

Sonia S. Anand, MD, MSc; Philip S. Wells, MD, MSc; Dereck Hunt, MD;
Pat Brill-Edwards, MD, MSc; Deborah Cook, MD, MSc; Jeffrey S. Ginsberg, MD

Objective.—To review the validity of the clinical assessment and diagnostic tests in patients with suspected deep vein thrombosis (DVT).

Methods.—A comprehensive review of the literature was conducted by searching MEDLINE from 1966 to April 1997.

Results.—Individual symptoms and signs alone do not reliably predict which patients have DVT. Overall, the diagnostic properties of the clinical examination are poor; the sensitivity of the clinical examination ranges from 60% to 96%, and the specificity ranges from 20% to 72%. However, using specific combinations of risk factors, symptoms, and physical signs for DVT, clinicians can reliably stratify patients with suspected DVT into low, moderate, or high pretest probability categories of actually suffering from DVT. This stratification process in combination with noninvasive testing, such as compression ultrasonography, simplifies the management strategies for patients with suspected DVT.

Conclusions.—Use of a clinical prediction guide that includes specific factors from both the history and physical examination in combination with noninvasive tests simplifies management strategies for patients with suspected DVT.

JAMA. 1998;279:1094-1099

DEEP VEIN thrombosis (DVT) affects approximately 2 million Americans per year¹ and is the third most common cardiovascular disease behind acute coronary syndromes and stroke.² Venous thromboembolism represents a single disease entity with 2 patterns of clinical presentation: DVT and pulmonary embolism (PE). The approach to patients who present with suspected DVT is problematic for several reasons. If left untreated, affected patients can suffer fatal PE. The clinical diagnosis of DVT is unreliable when used in isolation without objective testing.^{3,4} Also, about three quarters of the patients who present with suspected DVT have nonthrombotic causes of leg pain.^{5,6} Finally, although anticoagulant therapy is highly effective in preventing the extension, embolization, and recurrence of DVT, it is associated with an in-

creased risk of major bleeding (approximately 5%) and other potentially serious consequences such as heparin-induced thrombocytopenia (approximately 1%).⁷ Therefore, when possible, anticoagulation should be restricted to those with confirmed DVT. For all of these reasons, it is important to diagnose DVT accurately. This will allow administration of appropriate therapy for patients with documented DVT, and for patients without DVT it will avoid unnecessary exposure of patients to the hazards of anticoagulant therapy, and prevent many from being falsely labeled as suffering from venous thromboembolic disease.

The low specificity of clinical symptoms and signs means that most symptomatic patients will not have DVT. Of those symptomatic patients with confirmed DVT at presentation, which represents about one quarter of patients who are investigated,^{6,8} approximately 80% have proximal DVT (popliteal or more proximal veins) and 20% have DVT that is limited to the calf.⁹ The clinical significance of proximal DVT is different from that of calf vein thrombosis because proximal vein thrombosis is asso-

ciated with a higher incidence of PE. Pulmonary emboli are detected in approximately 50% of patients with documented proximal DVT.¹⁰ Therefore, proximal DVT should be identified and anticoagulant treatment should be initiated immediately in affected patients. The initiation of appropriate treatment reduces the risk of developing recurrent DVT to about 5% and reduces the incidence of fatal PE to less than 1%.¹¹ On the other hand, calf vein thrombosis rarely causes PE unless it first extends into the proximal veins. Proximal extension of calf DVT occurs in approximately 30%, with propagation occurring within 1 to 2 weeks of initial presentation.⁶

CLINICAL SCENARIO

A 55-year-old woman is referred to you with suspected DVT. She complains of pain, swelling, warmth, and redness of her right calf. She denies injury to the leg, or previous DVT. She has been receiving intravenous combination chemotherapy for ovarian carcinoma that was diagnosed 6 months earlier. Extensive pelvic lymph node involvement, especially on the right side, was present at diagnosis, and you consider the possibility that her leg symptoms are due to extrinsic compression of the right iliac vein. However, no lymph nodes are palpable and a recent pelvic ultrasound examination showed a reduction in the previously demonstrated adenopathy. On physical examination you find pitting edema, erythema, increased warmth of the right calf (diameter 3.5 cm greater than that of the left calf), and tenderness with palpation of the popliteal vein. You apply a clinical prediction rule⁶ and conclude that the probability of proximal DVT is very high.

From the Departments of Medicine (Drs Anand, Hunt, Brill-Edwards, Cook, and Ginsberg) and Clinical Epidemiology (Dr Cook), McMaster University, Hamilton, Ontario; and the Department of Medicine, Ottawa Civic Hospital, Ottawa, Ontario (Dr Wells).

Reprints: Sonia S. Anand, MD, MSc, Hamilton General Hospital, 237 Barton St E, Hamilton, Ontario, Canada L8L 2X2 (e-mail: anands@fhs.mcmaster.ca).

The Rational Clinical Examination section editors: David L. Simel, MD, MHS, Durham Veterans Affairs Medical Center and Duke University Medical Center, Durham, NC; Drummond Rennie, MD, Deputy Editor (West), *JAMA*.

Table 1.—Odds Ratios of Risk Factors for Deep Vein Thrombosis*

Risk Factors	Odds Ratios (95% CI)
Male gender	1.7 (1.4-2.0)
Age >60 y	1.6 (1.3-1.9)
Cancer	2.4 (1.9-2.8)
Heart failure	1.8 (1.3-2.3)
Systemic lupus erythematosus	4.4 (3.1-5.5)
Lower limb arteriopathy	1.9 (1.3-2.5)

*Data are from Cogo et al¹⁹; CI indicates confidence interval.

METHODS

Search Strategy

We conducted a MEDLINE search to retrieve all relevant articles pertaining to the clinical assessment of patients with suspected DVT. MEDLINE was searched from 1966 to April 1997 using Medical Subject Headings, EXP (explode) thrombosis (tw [textword]) and (EXP physical examination or EXP diagnostic tests or EXP sensitivity and specificity) and EXP phlebography. This was limited to human and English-language studies. One hundred fifteen articles were retrieved (available on request from the senior author); 68 articles that dealt with the diagnosis of DVT were selected for complete review. The bibliographies of the retrieved articles were examined for additional relevant articles. Only 5 studies provided information on the relationship between clinical findings and venographic confirmation of DVT.^{3,4,6,12,13} These studies were graded based on their methodologic quality using a standard scoring system.¹⁴

Principles of Diagnosis of DVT

The diagnostic assessment of patients with suspected DVT has evolved over the past 2 decades from reliance on clinical symptoms and signs alone to heavy reliance on objective diagnostic tests.¹⁵

RESULTS

Clinical Assessment

Over the past 30 years, the clinical assessment in patients with suspected DVT has been refined and now includes a careful review of risk factors, symptoms, and physical signs.^{5,16-18} Risk factors for DVT include immobility, paralysis, recent surgery and/or trauma, malignancy, cancer chemotherapy, advancing age (ie, >60 years), family history of venous thromboembolism, pregnancy, and estrogen use.^{19,20} In a recent prospective cohort study, 426 consecutive outpatients referred by general practitioners to a tertiary care thrombosis unit were assessed for DVT risk factors, and in approximately half of the patients with confirmed DVT, a major risk factor (immobility, trauma, and/or recent surgery) was pres-

Table 2.—Frequency of Symptoms and Signs in Patients With Suspected DVT*

Signs and Symptoms	Source					
	O'Donnell et al ³ Grade A, %†		Haeger ⁴ Grade B, %‡		Molloy et al ¹² Grade A, %†	
	DVT+	DVT-	DVT+	DVT-	DVT+	DVT-
Pain	78	75	90	97	48	23
Tenderness	76	89	84	74	43	35
Edema	78	67	42	32	43	26
Homans sign	56	61	33	21	11	11
Swelling	85	56	41	39
Erythema	24	38

*DVT indicates deep vein thrombosis. The DVT diagnosis was observed by venography. DVT+ indicates those with DVT; and DVT-, those without DVT. Ellipses indicate data not applicable.

†Grade A was an independent blind comparison of sign or symptom with a criterion standard of diagnosis among a large number of consecutive patients suspected of having the target condition.

‡Grade B was an independent blind comparison of sign or symptom with a criterion standard of diagnosis among a small number of consecutive patients suspected of having the target condition.

ent.¹⁹ The odds ratios for other risk factors independently associated with the presence of DVT, including male gender, age greater than 60 years, cancer, heart failure, systemic lupus erythematosus, and lower limb arteriopathy, are presented in Table 1. Commonly reported symptoms in patients with suspected DVT include leg pain, swelling, and other signs, such as pitting edema, warmth, dilated superficial veins, and erythema.³⁻⁵ Unfortunately, these findings are neither sensitive nor specific for DVT and may be caused by other disease processes,^{5,16} such as leg trauma, cellulitis, obstructive lymphadenopathy, superficial venous thrombosis, postphlebitic syndrome, or Baker cysts.^{6,21} The odds ratios for these factors range from 1.6 to 4.3.¹⁹ Furthermore, DVT can coexist with each of these processes. For example, the finding of a Baker cyst on an ultrasound examination does not rule out the presence of DVT.²¹

Traditionally, the routine physical examination in patients with suspected DVT included a careful inspection of the leg, measurement of the leg circumference, and elicitation of Homans sign,²² which refers to the development of pain in the calf or popliteal region on forceful and abrupt dorsiflexion of the ankle with the knee in a flexed position. Early studies evaluating the properties of individual physical signs such as these to diagnose DVT showed that they were inaccurate.^{3,4} In a study by O'Donnell et al,³ 102 patients who presented to the outpatient departments of 2 tertiary care hospitals with suspected DVT underwent a clinical assessment and venography. A combination of clinical signs and symptoms that included tenderness, swelling, redness, and the assessment of Homans sign could not adequately differentiate patients with or without DVT. The sensitivity of the clinical examination in this study was 88% (95% confidence interval [CI], 77%-97%) and the specificity was only 30% (95% CI, 18%-40%). Haeger⁴ conducted a prospective study of 72 outpatients who

presented with suspected DVT to a thrombosis clinic, were examined by 1 or 2 experienced surgeons, and underwent venography. No differences in the presenting symptoms or physical signs were identified between those with or without venographically confirmed DVT. The sensitivity of the clinical examination in this study was 66% (95% CI, 50%-82%) and the specificity only 53% (95% CI, 38%-69%). In a study by Molloy et al,¹² 100 patients with a clinical diagnosis of DVT who were referred to the radiology department of a general hospital were studied; the sensitivity of the clinical examination was 60% (95% CI, 45%-75%) and the specificity was 72% (95% CI, 60%-83%). Overall, these symptoms and signs occur in similar frequency in symptomatic patients with and without DVT (Table 2).

The results of these studies led to a shift away from the clinical examination to a heavy reliance on noninvasive objective tests for patients with suspected DVT. More recently, in a retrospective chart review by Landefeld et al¹⁵ of 354 inpatients and outpatients with suspected DVT who underwent venography, there were 5 clinical findings independently related to the presence of proximal DVT: swelling below the knee, swelling above the knee, recent immobility, cancer, and fever. These factors were determined by using multiple linear regression, were found to be significantly associated with the presence of proximal DVT in 236 patients, and then were confirmed in the remaining 119 patients. Overall, the sensitivity of a positive clinical examination (associated with the presence of 1 or more independent predictors) was 96% (95% CI, 92%-100%) and the specificity was 20% (95% CI, 15%-25%). The frequency of signs and symptoms seemed to predict the presence of proximal DVT; where the absence of any findings was associated with less than a 5% chance of proximal DVT, and the presence of 2 or more

Table 3.—Likelihood Ratio for Clinical Assessment in Patients With Suspected DVT Compared With Venographic Result*

Source	Positive Clinical Assessment for DVT (95% CI)	Negative Clinical Assessment for DVT (95% CI)
O'Donnell et al ³	1.25 (1.0-1.5)	0.40 (0.17-0.96)
Haeger ⁴	1.40 (0.95-2.2)	0.64 (0.34-1.06)
Molloy et al ¹²	2.10 (1.3-3.5)	0.55 (0.36-0.80)
Landefeld et al ¹³	1.20 (1.10-1.29)	0.21 (0.08-0.54)

*DVT indicates deep vein thrombosis; CI, confidence interval. Positive clinical assessment was defined as 1 or more clinical factors; negative clinical assessment, absence of clinical factors.

clinical findings was associated with a 46% chance of proximal DVT. This was the first study to demonstrate the potential role of a clinical prediction guide in patients with suspected DVT. The likelihood ratio estimates for the clinical assessment based on the 4 studies described above are shown in Table 3.

Recall that a likelihood ratio expresses the odds that a given finding on the history or physical examination would occur in a patient with the target disorder as opposed to a patient without it. Given a likelihood ratio above 1.0, the probability of disease (in this case DVT) increases when the finding is present, as the finding is more likely among the patients with the disease than among those without. When the likelihood ratio is below 1.0, the probability of disease declines as the finding is less likely to occur among patients with the disease than those without.²³

Objective Assessment

Venography is the reference standard for the diagnosis of DVT, and it is highly accurate for both proximal and calf DVT.²⁴ However, venography is invasive, expensive, technically inadequate in about 10% of patients (either because of an inability to cannulate a vein or lack of adequate visualization of the deep veins), and may induce DVT in approximately 3% of patients.²⁵ This led to the evaluation and validation of 2 noninvasive tests: impedance plethysmography and compression ultrasonography. These tests have proven to be sensitive to proximal, but not to calf vein thrombosis.

Impedance plethysmography reliably detects occlusive thrombi of the proximal veins (popliteal, femoral, or iliac veins) but is less reliable at detecting nonocclusive proximal DVT, and is insensitive to calf DVT.²⁶⁻²⁹ Impedance plethysmography does not allow direct visualization of the veins, but suggests that DVT is present when significant outflow obstruction is present, particularly in the absence of a comorbid condition that might cause a false-positive re-

Table 4.—Interpretation of Test Results in Patients With Suspected Initial DVT*

Tests	Results		
	Venography	Compression Ultrasonography	Impedance Plethysmography
Diagnose DVT	Intraluminal filling defect in at least 2 projections	Noncompressibility of the femoral and/or popliteal vein	Abnormal impedance plethysmography and a moderate to high clinical probability of DVT
Exclude clinically important DVT	Normal venogram	Normal compressibility of proximal venous segments combined with a low clinical pretest probability, or normal serial compression ultrasound examination	Normal impedance plethysmography combined with a normal D dimer or normal serial impedance plethysmography
Nondiagnostic for DVT	Technically inadequate study in which all deep veins are not adequately visualized	Noncompressibility of deep veins of the calf	Abnormal impedance plethysmography combined with low clinical suspicion

*DVT indicates deep vein thrombosis.

Table 5.—Estimation of Pretest Probability of DVT Using the Clinical Model*

Major Points
Active cancer (treatment ongoing or within previous 6 months or palliative)
Paralysis, bedridden >3 days and/or major surgery within 4 weeks
Localized tenderness along the distribution of the deep venous system in calf or thigh
Thigh and calf swollen (should be measured)
Calf swelling by >3 cm when compared with the asymptomatic leg (measured 10 cm below the tibial tuberosity)
Strong family history of DVT (>2 first-degree relatives with history of DVT)
Minor Points
History of recent trauma (≤60 days to the symptomatic leg)
Pitting edema in symptomatic leg only
Dilated superficial veins (nonvaricose) in symptomatic leg only
Hospitalization within previous 6 months
Erythema

*DVT indicates deep vein thrombosis. Items excluded from the model are age, duration of symptoms, sex, obesity, presence of varicose veins, a palpable cord, and Homans sign. Scoring method: high probability if ≥3 major points and no alternative diagnosis, ≥2 major points and ≥2 minor points and no alternative diagnosis; low probability if 1 major point and ≤2 minor points and an alternative diagnosis, 1 major point and ≤1 minor point and no alternative diagnosis, 0 major points and ≤3 minor points and an alternative diagnosis, 0 major points and ≤2 minor points and no alternative diagnosis; and moderate probability if all other combinations.

sult (ie, extrinsic venous compression or conditions associated with elevated central venous pressure).¹⁵ Although studies before 1990 reported that impedance plethysmography detected over 90% of proximal DVT, more recent studies reported sensitivities for proximal DVT of about 70%.³⁰⁻³² This apparent decrease in sensitivity is probably caused by changes in referring patterns to specialty centers with a strong interest in DVT.³³

Compression ultrasonography assesses compressibility of the femoral and popliteal veins and is highly sensitive and specific for detecting proximal DVT (noncompressibility is diagnostic of DVT, whereas compressibility excludes DVT).^{6,15,34-36} Neither impedance plethysmography nor compression ultrasonography reliably detects isolated calf vein thrombosis.³⁷ It should be noted that while the specificity of compression ultrasonography and impedance plethysmography for DVT remains high in both symptomatic and asymptomatic patients, the sensitivity declines dramatically when impedance plethysmography and compression ultrasonography are used to evaluate asymptomatic patients (ie, 22% and 58%, respectively) vs symptomatic patients (ie, 96% and 96%,

respectively).³⁸ Several diagnostic algorithms using serial compression ultrasonography or impedance plethysmography have been evaluated and validated in large clinical trials.^{26,29,34-36,39-44} Although compression ultrasonography appears to be more accurate than impedance plethysmography, serial testing with either is acceptable in patients with suspected DVT.^{39,45} Therefore, as most clinicians consider clinically important proximal DVT excluded by normal impedance plethysmography or compression ultrasonography on the day of presentation, anticoagulants can be safely withheld in such patients, as the probability of suffering from proximal DVT is less than 2% in the following 3 months.⁴⁶ If the initial test results are normal, repeat testing over the next 5 to 7 days is recommended; if they become abnormal during this period, extending proximal DVT is likely and an anticoagulant therapy should be initiated. However, impedance plethysmography and compression ultrasonography have limitations too, such as availability, and the inconvenience and expense of repeat testing.

Recently the D-dimer assays have been demonstrated to be useful adjuncts to noninvasive testing for suspected DVT because they are highly sensitive

Table 6.—Likelihood Ratios for Ultrasonography Results by Clinical Probability Strata

Pretest Probability	Ultrasonography	Positive Likelihood Ratio (95% CI)*
High	Abnormal	Infinity (∞) (3- ∞)
Moderate	Abnormal	72 (13-412)
Low	Abnormal	34 (14-76)
High	Normal	0.06 (0.03-0.16)
Moderate	Normal	0.17 (0.07-0.34)
Low	Normal	0.20 (0.06-0.52)

*CI indicates confidence interval.

and, therefore, have high negative predictive values.⁴⁷⁻⁴⁹ D dimer is formed when crossed-linked fibrin contained within a thrombus is proteolyzed by plasmin. Various D-dimer assays are available, including enzyme-linked immunosorbent assays, latex agglutination assays, and a whole blood agglutination test.⁴⁸ The whole-blood agglutination assay appears to be best for exclusion of DVT, since it is suitable for individual testing (unlike enzyme-linked immunosorbent assays), and has high sensitivity and reasonable specificity. Recent studies show that DVT can be reliably excluded in patients with suspected DVT who have a normal impedance plethysmograph and a normal D dimer (using the SimpliRed assay) and that such results occur in about two thirds of patients.⁴⁷ This supports the role of the SimpliRed assay as a simple and rapid adjunct to noninvasive tests for the exclusion of clinically important DVT.^{47,48} For a summary of diagnostic algorithms for patients with suspected DVT see Table 4.

Clinical Prediction Guide

Recently, the clinical assessment of patients with suspected DVT was re-evaluated. This was sparked by 2 observations that many patients with a high pretest probability (using clinical judgment) and a normal impedance plethysmograph had proximal DVT,³⁰ and that the pretest probability of patients had an important influence on diagnosing PE, a closely related disease. For example, in patients with a low pretest probability and a high probability lung scan, the prevalence of PE was approximately 50% to 60%.⁵⁰ These results generated the hypothesis that when pretest probability and further tests are concordant, DVT can be ruled in or out, whereas when they are discordant, further tests are necessary.

Development of a Clinical Prediction Guide

Recently, a clinical prediction guide that seeks to standardize the estimation of the pretest probability among clinicians was developed⁶ and is described

Table 7.—Simplified Clinical Model*

Clinical Parameter	Score
Active cancer (treatment ongoing or within previous 6 months or palliative)	1
Paralysis, paresis, or recent plaster immobilization of the lower extremities	1
Recently bedridden for >3 days of major surgery within 4 weeks	1
Localized tenderness along the distribution of the deep venous system	1
Entire leg swelling	1
Calf swelling by >3 cm when compared with the asymptomatic leg (measured 10 cm below the tibial tuberosity)†	1
Pitting edema (greater in the symptomatic leg)	1
Collateral superficial veins (nonvaricose)	1
Alternative diagnosis as likely or greater than that of deep vein thrombosis	-2

*Scoring method: high probability if score is ≥ 3 ; moderate if score is 1 or 2; and low if score is ≤ 0 .

†In patients with symptoms in both legs, the more symptomatic leg was used.

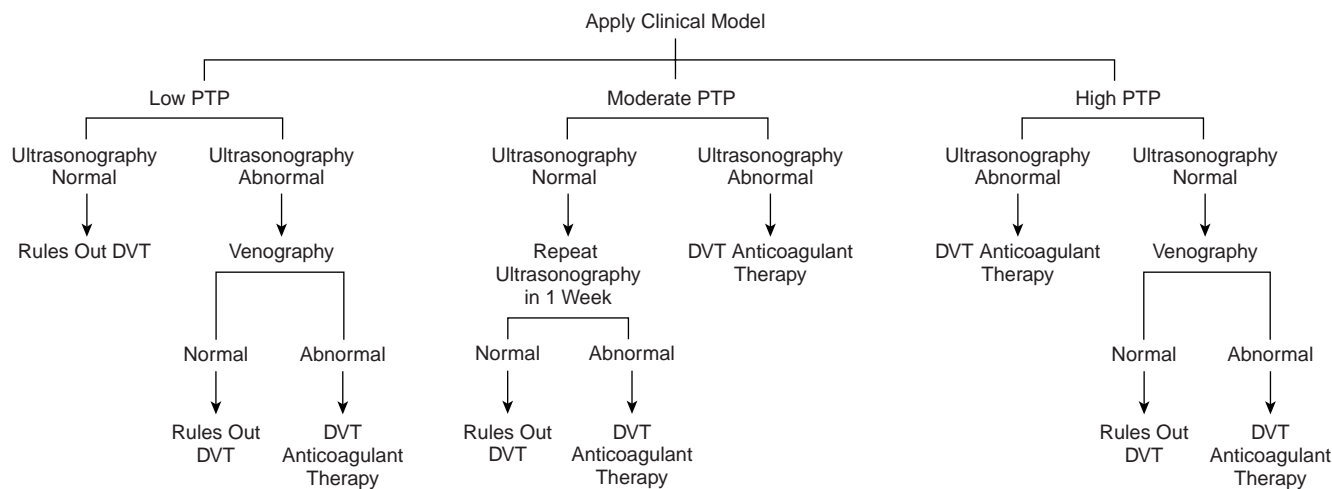
below. This model enables clinicians to reliably stratify patients with suspected DVT into high, moderate, or low probability groups by following uniform criteria. After a review of the literature^{3,4,8,15,19} and input from experienced thrombosis investigators, categories deemed to be important in the estimation of a patient's pretest probability were considered and categorized as follows: (1) signs and symptoms of DVT, (2) risk factors for DVT, and (3) the presence or absence of diagnoses that were deemed at least as likely as DVT to explain the patient's symptoms. These include musculoskeletal injuries, cellulitis, and prominent lymphadenopathy of the inguinal area. The clinical prediction guide uses a scoring system that combines important symptoms and signs, risk factors for DVT, and the presence or absence of an alternative diagnosis. The results stratify patients with suspected DVT into low, moderate, or high probability groups. The original clinical prediction guide was initially developed in a training set of 100 outpatients at a thrombosis referral center, at McMaster University, Hamilton, Ontario, who presented with suspected DVT. All patients underwent venography, and a simple regression model determined the relative importance of individual and various clusters of factors to predict the probability that a patient suffered from DVT.

The clinical prediction guide was then prospectively validated in a test set of 529 patients who presented with suspected DVT to 3 tertiary care referral centers, 2 in Hamilton and 1 in Padua, Italy.⁶ Clinicians recorded their assessment of pretest probability of DVT, then all patients underwent venography and compression ultrasound examination. This model cannot be applied to certain subgroups of patients who were excluded from the study, such as those with previous venous thromboembolism, those with concomitantly suspected PE, pregnant women, or patients receiving treatment with anticoagulants. Using the clinical model, eligible patients were

initially stratified into low, moderate, or high pretest probability groups.

Although individual physical findings on their own are not predictive of DVT, when specific physical signs are incorporated into the clinical prediction guide they contribute to the generation of the pretest probability of DVT. In Table 5, the physical signs and the scoring system of the clinical prediction guide are outlined. The physical signs classified as major points include localized tenderness to palpation along the distribution of the deep venous system; thigh and calf swelling—indicating that the entire leg has an increased diameter when compared with the asymptomatic side; and calf swelling in which the calf is measured approximately 10 cm below the tibial plateau (at the tibial tuberosity) and is considered present if the difference between calf diameters is greater than 3 cm. Minor points include the presence of a unilateral pitting edema of the leg using standard assessment measures; the presence of dilated superficial veins (nonvaricose) that persist with elevation in the lower limb or if present in any new pattern in the groin region on the symptomatic leg only; and the presence of diffuse or streaking erythema.

The test-set confirmed that the clinical model could reliably classify patients into high, moderate, and low probability groups. The prevalence of all DVT (proximal and calf) using the venogram as the criterion standard in patients who were classified by the clinical model into the high probability strata was 85%, compared with 33% in the moderate probability and 5% in the low probability categories. The positive likelihood ratios for the high-, moderate-, and low-risk categories are 16.2 (95% CI, 9.3-28.2), 1.3 (95% CI, 1.0-1.7), and 0.2 (95% CI, 0.1-0.3), respectively. The specificity of compression ultrasonography to detect proximal DVT in all strata was between 98% and 100%. When interpreted in conjunction with pretest probability, the ability of compression ultrasonography to reliably diagnose DVT decreased as the pretest probability declined. The



Suggested diagnostic approach in patients with suspected deep vein thrombosis (DVT); PTP indicates pretest probability of DVT.

sensitivities of compression ultrasonography in the high, moderate, and low strata were 94%, 83%, and 80%, respectively. The corresponding likelihood ratios for compression ultrasonography in pretest probability strata are provided in Table 6. By combining pretest probability and compression ultrasonography results, the posttest probabilities of DVT for each possible combination of results were generated. In the high pretest probability strata, an abnormal compression ultrasonogram resulted in a 100% posttest probability; in the moderate strata, a 96% posttest probability; and in the low strata, a 63% posttest probability. In patients whose compression ultrasonogram was normal, the posttest probabilities of DVT in the high, moderate, and low strata were 24%, 5%, and less than 1%, respectively.

The original clinical prediction guide was recently simplified using stepwise logistic regression and reevaluated.⁵¹ Recent trauma, family history, erythema, and recent hospitalization within the previous 6 months did not remain in the simplified model, which in combination with compression ultrasonography was recently prospectively tested in 593 patients with suspected DVT who were referred to tertiary care thrombosis clinics⁵¹ (Table 7). Similar to the original clinical prediction guide, the simplified guide was able to reliably stratify patients into high, moderate, or low probability groups, with corresponding prevalences of DVT of 75% (95% CI, 63%-81%), 17% (95% CI, 12%-23%), and 3% (95% CI, 1.7%-5.9%), respectively.

These data support the use of a clinical prediction guide to simplify the diagnostic approach for patients with suspected DVT (Figure). In patients with a high or moderate pretest score who have an ab-

normal compression ultrasonogram, DVT can be reliably diagnosed (positive likelihood ratios of ∞ and 72, respectively) and treatment should be initiated. In patients with a low pretest probability of DVT who have a normal compression ultrasonogram (negative likelihood ratio of 0.2), DVT can be reliably excluded without further testing. For patients with discordant results (ie, high pretest probability and normal compression ultrasonogram, or low pretest probability and an abnormal compression ultrasonogram), further testing is recommended (ie, venography or serial compression ultrasonography). Patients with a moderate pretest probability and a normal ultrasonogram have a 5% probability of having DVT and a repeat compression ultrasound examination in 7 days is recommended.

BACK TO THE PATIENT

The patient described in the "Clinical Scenario" section is a 55-year-old woman who presents with suspected DVT. Using the clinical prediction guide checklist found in Table 5, you determine that she has 5 clinical features predictive of DVT: a diagnosis of active cancer, calf swelling, erythema, localized tenderness along the popliteal vein, and pitting edema of the symptomatic leg. Although the possibility of enlarging pelvic lymph nodes in the right inguinal area offers a potential alternative diagnosis, you note that a recent pelvic ultrasound report indicates that these nodes have shrunk, rendering this a less likely alternative diagnosis. Therefore, with 5 clinical features of DVT, and no convincing alternative diagnosis, following the approach of the clinical prediction guide you conclude that she has a high clinical probability of suffering from

acute DVT. The next step is to perform a compression ultrasound examination, and, if the results are abnormal, the posttest probability of DVT being present approaches 100%. However, if the ultrasonogram is normal (ie, showing normal compressibility of the proximal veins), the posttest probability is approximately 24%, and further testing with venography would be required.

CONCLUSIONS

Although physical findings of patients with suspected DVT are not useful on their own, this state-of-the-art clinical prediction guide that includes factors from both the history and physical examination is able to assist in the diagnosis of DVT. When used in combination with noninvasive tests, such as compression ultrasonography, it can simplify and reduce the expense of management strategies.

THE BOTTOM LINE

Individual symptoms and signs on their own are not useful to diagnose DVT. However, a systematic review of patients' risk factors, symptoms, and physical signs allows the clinician to reliably determine the pretest probability that a patient suffers from DVT. This strategy, in combination with the results of noninvasive diagnostic test results, guides further diagnostic testing and treatment strategies.

Dr Anand is a recipient of a Research Fellowship of the Heart and Stroke Foundation of Canada, Ottawa, Ontario; Dr Ginsberg, a Career Investigator Award of the Heart and Stroke Foundation of Ontario, Toronto; Dr Wells, a Research Scholarship of the Heart and Stroke Foundation of Canada, Ottawa, Ontario; and Dr Cook, the Ontario Ministry of Health Career-Investigator Award, Toronto.

The authors would like to acknowledge the contributions of Brian Gage, MD, MSc, and Gino Merli, MD, for their critical review of the manuscript.

References

- Hirsh J, Hoak J. Management of deep vein thrombosis and pulmonary embolism. *Circulation*. 1996;93:2212-2245.
- Gunintini C, Di Rieco G, Marini C, Melillo E, Palla A. Epidemiology. *Chest*. 1995;107:3S-9S.
- O'Donnell T, Abbott W, Athanasoulis C, Millan V, Callow A. Diagnosis of deep venous thrombosis in the outpatient by venography. *Surg Gynecol Obstet*. 1980;150:69-74.
- Haeger K. Problems of acute deep venous thrombosis, I: the interpretation of signs and symptoms. *Angiology*. 1969;20:219-223.
- Hull RD, Raskob GE, Leclerc J, Jay RM, Hirsh J. The diagnosis of clinically suspected venous thrombosis. *Clin Chest Med*. 1984;5:439-452.
- Wells P, Hirsh J, Anderson D, Lensing A, Foster G, Kearon C. Accuracy of clinical assessment of deep-vein thrombosis. *Lancet*. 1995;345:1326-1330.
- Hirsh J, Raschke R, Warkentin T. Heparin: mechanism of action, pharmacokinetics, dosing considerations, monitoring, efficacy, and safety. *Chest*. 1995;108:258S-275S.
- Vine H, Hillman B, Hessel S. Deep venous thrombosis: predictive value of signs and symptoms. *Am J Radiol*. 1981;136:167-171.
- Cogo A, Lensing A, Prandoni P, Hirsh J. Distribution of thrombosis in patients with symptomatic deep vein thrombosis: implications for simplifying the diagnostic process with compression ultrasound. *Arch Intern Med*. 1993;153:2777-2780.
- Hull RD, Hirsh J, Carter CJ, Jay RM, Ockelford PA, Buller HR. Pulmonary angiography, ventilation lung scanning, and venography for clinically suspected pulmonary embolism with abnormal perfusion lung scanning. *Ann Intern Med*. 1983;98:891-899.
- Hyers TM, Hull RD, Weg JG. Antithrombotic therapy for venous thromboembolic disease. *Chest*. 1995;108(suppl):335S-351S.
- Molloy W, English J, O'Dwyer R, O'Connell J. Clinical findings in the diagnosis of proximal deep venous thrombosis. *Ir Med J*. 1982;75:119-120.
- Landefeld CS, McGuire E, Cohen A. Clinical findings associated with acute proximal deep vein thrombosis: a basis for quantifying clinical judgment. *Am J Med*. 1990;88:388.
- Holleman D, Simel D. Does the clinical examination predict airflow limitations? *JAMA*. 1995;273:313-319.
- Lensing A, Hirsh J, Buller H. Diagnosis of venous thrombosis. In: Colman R, Hirsh J, Marder V, Salzman E, eds. *Hemostasis and Thrombosis: Basic Principles and Clinical Practice*. Philadelphia, Pa: JB Lippincott; 1994:1297-1321.
- Hirsh J, Hull RD, Raskob GE. Clinical features and diagnosis of venous thrombosis. *J Am Coll Cardiol*. 1986;8(suppl B):114B-127B.
- Browne N. Deep vein thrombosis: diagnosis. *BMJ*. 1969;684:676-678.
- McLachlin J, Richard T, Paterson JC. An evaluation of clinical signs in the diagnosis of venous thrombosis. *Arch Surg*. 1962;85:738.
- Cogo A, Bernardi E, Prandoni P, Girolami B, Noventa F, Simioni P. Acquired risk factors for deep-vein thrombosis in symptomatic outpatients. *Arch Intern Med*. 1994;154:164-168.
- Salzman EW, Hirsh J. The epidemiology, pathogenesis, and natural history of venous thrombosis. In: Colman RW, Hirsh J, Marder VJ, Salzman EW, eds. *Hemostasis and Thrombosis: Basic Principles and Clinical Practice*. Philadelphia, Pa: JB Lippincott; 1994:1275-1296.
- Simpson PG, Bark M, Robinson PJ, Losowsky MS. Prospective study of thrombophlebitis and pseudothrombophlebitis. *Lancet*. 1980;1:331-333.
- Barnes RW, Wu KK, Hoak JC. Fallibility of the clinical diagnosis of venous thrombosis. *JAMA*. 1975;234:605-607.
- Sackett DL. A primer on the precision and accuracy of the clinical examination [abstract]. *JAMA*. 1992;267:2638-2644.
- Rabinov K, Paulin S. Roentgen diagnosis of venous thrombosis in the leg. *Arch Surg*. 1972;104:134.
- Lensing AWA, Prandoni P, Buller H, Casara D, Cogo A, ten Cate JW. Lower extremity venography with iohexol: results and complications. *Radiology*. 1990;177:503-505.
- Hull RD, Hirsh J, Carter CJ. Diagnostic efficacy of impedance plethysmography for clinically-suspected deep-vein thrombosis. *Ann Intern Med*. 1985;102:21-28.
- Prandoni P, Lensing AWA, Huisman MV, et al. A new computerized impedance plethysmograph: accuracy in the detection of proximal deep-vein thrombosis in symptomatic outpatients. *Thromb Hemost*. 1991;65:229-232.
- Hull RD, van Acken WG, Hirsh J, et al. Impedance plethysmography using the occlusive cuff technique in the diagnosis of venous thrombosis. *Circulation*. 1976;53:696.
- Huisman MV, Buller HR, ten Cate JW, Heijermans HSF, van der Laan J, van Maanen DJ. Management of clinically suspected acute venous thrombosis in outpatients with serial impedance plethysmography in a community hospital setting. *Arch Intern Med*. 1989;149:511-513.
- Anderson DR, Lensing AW, Wells PS, Levine MN, Weitz JI, Hirsh J. Limitations of impedance plethysmography in the diagnosis of clinically suspected deep-vein thrombosis. *Ann Intern Med*. 1993;118:25-30.
- Prandoni P, Lensing AWA, Buller HR, et al. Failure of computerized impedance plethysmography in the diagnostic management of patients with clinically suspected DVT. *Thromb Hemost*. 1991;65:233.
- Ginsberg JS, Wells PS, Hirsh J, et al. Reevaluation of the sensitivity of impedance plethysmography for the detection of proximal deep vein thrombosis. *Arch Intern Med*. 1994;154:1930-1933.
- Cogo A, Prandoni P, Villalta S, Polistena D, Bernardi E, Simioni P. Changing features of proximal vein thrombosis over time. *Angiology*. 1994;45:377-382.
- Heijboer H, Cogo A, Buller HR, Prandoni P, ten Cate JW. Detection of deep vein thrombosis with impedance plethysmography and real time compression ultrasonography in hospitalized patients. *Arch Intern Med*. 1992;152:1901-1903.
- White RH, McGahan JP, Daschbach MM, Harthing RP. Diagnosis of deep-vein thrombosis using duplex ultrasound. *Ann Intern Med*. 1989;111:297-304.
- Lensing AWA, Prandoni P, Brandjes P, Huisman MV, Vigo M, Tomasella G. Detection of deep vein thrombosis by real time B-mode ultrasonography. *N Engl J Med*. 1989;320:342-345.
- Mattos MA, Londrey GL, Leutz DW, et al. Color-flow duplex scanning for the surveillance and diagnosis of acute deep venous thrombosis. *J Vasc Surg*. 1992;15:366-376.
- Ginsberg JS, Caco CC, Brill-Edwards PA, et al. Venous thrombosis in patients who have undergone major hip or knee surgery: detection with compression US and impedance plethysmography. *Radiology*. 1991;181:651-654.
- Heijboer H, Buller H, Lensing A, Turpie A, Colly L, ten Cate J. A comparison of real-time compression ultrasonography with impedance plethysmography for the diagnosis of deep-vein thrombosis in symptomatic outpatients. *N Engl J Med*. 1993;329:1365-1369.
- Hull R, Hirsh J, Sackett DL, Powers P. Combined use of leg scanning and impedance plethysmography in suspected venous thrombosis: an alternative to venography. *N Engl J Med*. 1977;296:1497-1500.
- Huisman MV, Buller HR, ten Cate JW, Vreeken J. Serial impedance plethysmography for suspected deep venous thrombosis in outpatients: the Amsterdam General Practitioner Study. *N Engl J Med*. 1986;314:823-828.
- Cogo A, Lensing AWA, Koopman MMW. Compression ultrasound for the diagnostic management of clinically suspected deep-vein thrombosis. *Thromb Hemost*. 1995;73:1098.
- Hull R, Hirsh J, Sackett DL. Replacement of venography in suspected venous thrombosis by impedance plethysmography and ¹²⁵I-fibrinogen leg scanning. *Ann Intern Med*. 1981;94:12-15.
- Cogo A, Lensing AWA, Prandoni P, Buller HR, Girolami A, ten Cate JW. Comparison of real-time B-mode ultrasonography and Doppler ultrasound with contrast venography in the diagnosis of venous thrombosis in symptomatic outpatients. *Thromb Hemost*. 1993;70:404-407.
- Wells PS, Hirsh J, Anderson DR, et al. Comparison of the accuracy of impedance plethysmography and compression ultrasonography in outpatients with clinically suspected deep vein thrombosis. *Thromb Hemost*. 1995;74:1423-1427.
- Ginsberg JS. Management of venous thromboembolism. *N Engl J Med*. 1996;335:1816-1828.
- Wells PS, Brill-Edwards P, Stevens P, et al. A novel and rapid whole-blood assay for D-dimer in patients with clinically suspected deep vein thrombosis. *Circulation*. 1995;91:2184-2187.
- Sale S, Gogstad GO, Brosstad F, et al. Comparison of three D-dimer assays for the diagnosis of DVT: ELISA, latex, and an immunofiltration assay (NucoCard D-dimer). *Thromb Hemost*. 1994;71:270-274.
- Bounameaux H, De Moerloose P, Perrier A, Raber G. Plasma measurement of D-dimer as diagnostic aid in suspected venous thromboembolism: an overview. *Thromb Hemost*. 1994;71:1-7.
- The PIOPED Investigators. The value of the ventilation/perfusion scan in acute pulmonary embolism. *JAMA*. 1990;263:2753-2759.
- Wells P, Anderson DR, Bormanis J, et al. Value of assessment of pretest probability of deep-vein thrombosis in clinical management. *Lancet*. 1997;350:1795-1798.

zyme A (HMG-CoA) reductase inhibitor class. We are unaware of any published reports of TEN associated with atorvastatin or related compounds.⁵

Report of a Case.—A 73-year-old, moderately obese woman with type 2 diabetes and hypertension had a total cholesterol value of 6.88 mmol/L (266 mg/dL), a high-density lipoprotein cholesterol value of 1.03 mmol/L (40 mg/dL), a low-density lipoprotein cholesterol value of 4.58 mmol/L (177 mg/dL), and a triglyceride value of 6.88 mmol/L (266 mg/dL). She had been receiving the following medications without adverse effects: enalapril and glyburide, 6 years; potassium chloride, 14 years; hydrochlorothiazide, 15 months; and metformin and nabumetone, 1 year. Atorvastatin, 10 mg/d, was prescribed.

Four days later, after receiving a total dose of 40 mg of atorvastatin, the patient noted a pruritic, erythematous rash and discontinued atorvastatin therapy. The rash became confluent over the next 2 days. Therapy with prednisone and diphenhydramine was initiated; however, the condition progressed, with the development of severe stomatitis, diffuse erythema, and edema of the face, trunk, and extremities, with bulla formation and desquamation in multiple areas. Fever, malaise, and weakness were present.

The patient required hospitalization for 2 weeks. All pre-hospital medication use was discontinued. Supportive care was provided with intravenous fluids, mouth care, liquid diet, corticosteroids, and intravenous morphine.

The hemoglobin level decreased from 114 g/L to 90 g/L and the white blood cell count was $6.9 \times 10^9/L$ (84% neutrophils, 10% lymphocytes, 5% monocytes, and 1% eosinophils). Electrolyte levels were within the normal range. Liver function tests had normal results and the total cholesterol value was 4.55 mmol/L (172 mg/dL). A positive Nikolsky sign was elicited. Skin biopsy revealed detached epidermal tissue with extensive necrosis and mononuclear cell infiltration and was consistent with the clinical diagnosis of TEN. The patient was severely ill but eventually recovered. Complete resolution of dermatologic manifestations (including partial alopecia and severe dystrophic changes of the fingernails and toenails) required 4 months. Glyburide, enalapril, and hydrochlorothiazide were reinstated without adverse effect.

Comment.—HMG-CoA reductase inhibitors are widely prescribed for the management of hypercholesterolemia because of their effectiveness and tolerability. The most serious toxic effects associated with HMG-CoA reductase inhibitors are liver dysfunction, myalgia, and rhabdomyolysis. Significant dermatologic reactions are uncommon. In the case reported herein, the patient received multiple medications for many months without adverse effects. After 4 days of atorvastatin therapy, the patient developed a rash that progressed to a painful, potentially life-threatening dermatosis requiring a 2-week hospitalization.

The temporal relationship of the reaction to the initiation of atorvastatin therapy, as well as the long-term tolerance of the previously prescribed medications, make atorvastatin the most likely cause of TEN in this case. No rechallenge with atorvastatin was attempted. Whether a similar reaction

would occur with other HMG-CoA reductase inhibitors is uncertain. The patient's hyperlipidemia is currently managed by dietary measures.

This is the first reported case of TEN associated with HMG-CoA reductase inhibitors to our knowledge. Physicians and other health care professionals should be aware of the possibility of such reactions to atorvastatin and similar drugs.

Constance M. Pfeiffer, PharmD
Rutgers University College of Pharmacy
Piscataway, NJ
The Medical Center at Princeton
Princeton, NJ
Steven Kazenoff, MD
Harvey D. Rothberg, MD
The Medical Center at Princeton
Princeton, NJ
University of Medicine and Dentistry—
Robert Wood Johnson School of Medicine
New Brunswick, NJ

1. Fritsch PO, Elias PM. Erythema multiforme and toxic epidermal necrolysis. In: Fitzpatrick TB, Eisen AZ, Wolff K, Freedberg IM, Austen KF, eds. *Dermatology in General Medicine*. New York, NY: McGraw-Hill Book Co; 1993:585-599.
2. Nowakowski PA, Rumsfeld JA, West DP. Drug-induced skin disorders. In: DiPiro JT, Talbert RL, Yee GC, et al, eds. *Pharmacotherapy: A Pathophysiologic Approach*. East Norwalk, Conn: Appleton & Lange; 1993:1835-1844.
3. Roujeau JC, Stern RS. Severe adverse cutaneous reactions to drugs. *N Engl J Med*. 1994;331:1272-1285.
4. Roujeau JC, Kelly JP, Luigi N, et al. Medication use and the risk of Stevens-Johnson syndrome or toxic epidermal necrolysis. *N Engl J Med*. 1995;333:1600-1607.
5. Bakker-Arkema RG, Davidson MH, Goldstein RJ, et al. Efficacy and safety of a new HMG-CoA reductase inhibitor, atorvastatin, in patients with hypertriglyceridemia. *JAMA*. 1996;275:128-133.

CORRECTIONS

Author Omitted.—In the reply letter for “Sertraline for Premenstrual Dysphoric Disorder” published in the February 4, 1998, issue of THE JOURNAL (1998;279:357-358), Barbara L. Parry, MD, was omitted from the list of contributing authors.

Incorrect Wording.—In The Rational Clinical Examination entitled “Does This Patient Have Deep Vein Thrombosis?” published in the April 8, 1998, issue of THE JOURNAL (1998;279:1094-1099), wording in a table was incorrect. On page 1096, in Table 5, the sentence that reads “Scoring method: high probability if ≥ 3 major points and no alternative diagnosis, ≥ 2 major points and ≥ 2 minor points and no alternative diagnosis; low probability if 1 major point and ≥ 2 minor points and an alternative diagnosis, 1 major point and ≥ 1 minor point and no alternative diagnosis, 0 major points and ≥ 3 minor points and an alternative diagnosis, 0 major points and ≥ 2 minor points and no alternative diagnosis; and moderate probability if all other combinations” should have read as follows: “Scoring method: high probability if ≥ 3 major points and no alternative diagnosis, ≥ 2 major points and ≥ 2 minor points and no alternative diagnosis; low probability if 1 major point and ≤ 2 minor points and an alternative diagnosis, 1 major point and ≤ 1 minor point and no alternative diagnosis, 0 major points and ≤ 3 minor points and an alternative diagnosis, 0 major points and ≤ 2 minor points and no alternative diagnosis; and moderate probability if all other combinations.”

maining supernatant was analyzed directly by CE-MS and CE-MS/MS. The composition of 4 different commercial samples (2 lot numbers) of SKIN-CAP spray formulation was examined. Another commercial spray product containing zinc pyrithione was also prepared and analyzed by CE-MS using identical conditions.

Results of preliminary CE-MS studies of SKIN-CAP using reconstructed ion electropherograms (the sum of all detected ions) and 2 ion channels (mass charge [m/z] 467 and m/z 469) were consistent with the protonated molecular weight of clobetasol (m/z 467) and the chloride 37 isotope response of this steroid (m/z 469) (data not shown). Detection of significant peaks in the m/z 467 and m/z 469 channels, coincident with the migration time of authentic clobetasol, led us to suspect that the analyzed samples of SKIN-CAP were contaminated by this corticosteroid. To substantiate these findings, we performed CE-MS/MS analysis, in which the m/z 467 response detected in SKIN-CAP was fingerprinted and compared with authentic clobetasol (Sigma, St Louis, Mo). The product ion spectrum resulting from the analysis of the SKIN-CAP contaminant (Figure, top) indicated significant similarity with authentic clobetasol when analyzed under the same conditions (Figure, bottom). Similarly, the product ion spectrum of the m/z 469 response detected for SKIN-CAP was consistent with the spectrum produced by CE-MS/MS analysis of m/z 469 of clobetasol (data not shown). The presence of a contaminant exhibiting an electrophoretic migration and mass spectrometric properties consistent with those of the authentic standard of clobetasol was detected in all 4 SKIN-CAP samples. These results strongly suggest that the 2 lots of SKIN-CAP we analyzed contained clobetasol, which is a superpotent corticosteroid available only by prescription for topical use in the United States. The other commercial brand of zinc pyrithione spray showed no evidence of clobetasol propionate and provided a negative control.

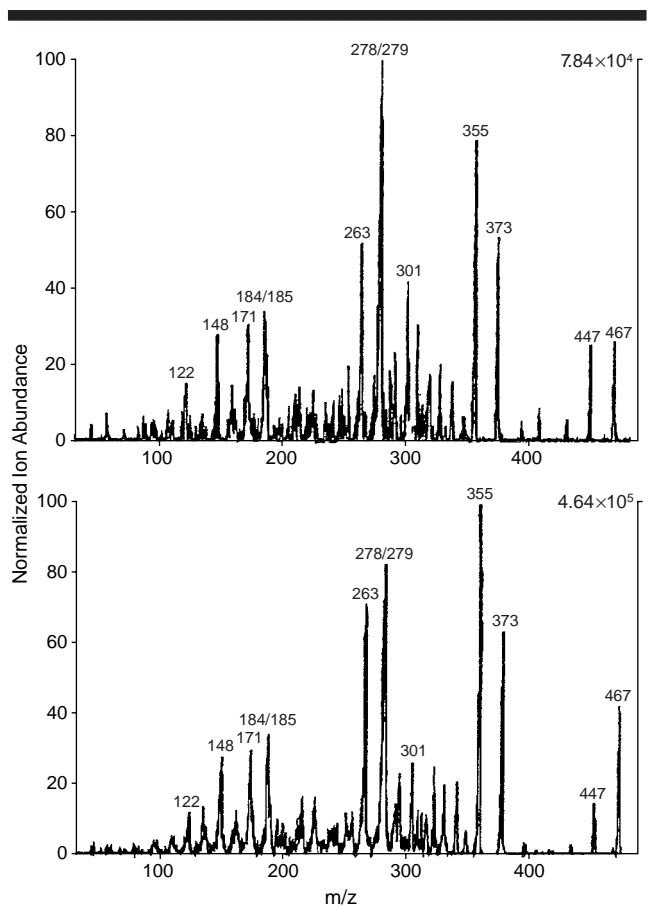
We informed the FDA of these findings and, subsequently, they confirmed the presence of clobetasol in spray, shampoo, and cream formulations of SKIN-CAP. In August 1997, the FDA issued an alert to halt importation of SKIN-CAP into the United States.¹ The medical community should be aware of possible corticosteroid contamination and attendant risks of SKIN-CAP therapy and urge patients using this product to consult their physicians.

Mark R. Pittelkow, MD
Linda M. Benson, BS
Stephen Naylor, PhD, DSc
Andy J. Tomlinson, PhD
Mayo Clinic
Rochester, Minn

1. Kupec IF. FDA warns consumers not to use SKIN-CAP. *HHS News*. August 8, 1997.

In Reply.—There has been a wide polemic concerning the ingredients contained in the SKIN-CAP product and, at this time, Cheminova International, SA, does not want to enter into more discussion.

The final evidence for the defense of SKIN-CAP has been provided to the corresponding FDA inspectors, and it is now their turn to make a decision and to inform us and the public about their verdict.



Production ion spectrum resulting from capillary electrophoresis and tandem mass spectrometry analysis of m/z (mass to charge) 467 component of a commercial SKIN-CAP spray formulation (top) and from analysis of authentic clobetasol (bottom).

After several analyses conducted by official institutions, SKIN-CAP has been reintroduced in the United Kingdom, Germany, France, and most East European countries. We trust that the US FDA will follow the decision of their European colleagues and will allow a prompt return of SKIN-CAP to the US market.

Aly F. Santa Marta
Cheminova International, SA
Madrid, Spain

CORRECTION

Calculation Error.—In the Rational Clinical Examination entitled “Does This Patient Have Deep Vein Thrombosis?” published in the April 8, 1998, issue of *THE JOURNAL* (1998;279:1094-1099), there was a calculation error. On page 1097, in the third column, second paragraph, the likelihood ratio for the high-risk category was stated as 3.3 (95% CI, 2.6-4.3) and should have been 16.2 (95% CI, 9.3-28.2).