cell-based vaccines, and adoptive T-cell therapy are in progress.[10] However, our findings strongly suggest that caution has to be taken when applying such HCMV-targeted immunotherapy for pediatric medulloblastomas.

Funding

This work was supported by a research grant from Cancer Foundation Koppie-Au.

Conflict of interests statement. The authors declare no conflict of interest.

Jeroen F. Vermeulen, Wim van Hecke, Mieke K. Jansen, Wim G.M. Spliet, Roel Broekhuizen, Niels Bovenschen
Department of Pathology, University Medical Center Utrecht, Netherlands (J.F.V., W.v.H., M.K.J., W.G.M.S., R.B., N.B.); Laboratory of Translational Immunology, University Medical Center Utrecht, Netherlands (N.B.)

Corresponding author: Niels Bovenschen, PhD, Department of Pathology, University Medical Center Utrecht, Heidelberglaan 100, 3584 CX UTRECHT, Netherlands (n.bovenschen@umcutrecht.nl).

References

1. Lanzieri TM, Kruszon-Moran D, Amin MM, et al. Seroprevalence of cytomegalovirus among children 1 to 5 years of age in the United States from the National Health and Nutrition Examination Survey of 2011 to 2012. *Clin Vaccine Immunol*. 2015;22(2):245–247.
2. Baryawno N, Rahbar A, Wolmer-Solberg N, et al. Detection of human cytomegalovirus in medulloblastomas reveals a potential therapeutic target. *J Clin Invest*. 2011;121(10):4043–4055.
3. Wakefield A, Pignata A, Ghazi A, et al. Is CMV a target in pediatric glioblastoma? Expression of CMV proteins, pp65 and IE1-72 and CMV nucleic acids in a cohort of pediatric glioblastoma patients. *J Neurooncol*. 2015;125(2):307–315.
4. Cobbs CS, Harkins L, Samanta M, et al. Human cytomegalovirus infection and expression in human malignant glioma. *Cancer Res*. 2002;62(12):3347–3350.
5. Scheurer ME, Bondy ML, Aldape KD, Albrecht T, El-Zein R. Detection of human cytomegalovirus in different histological types of gliomas. *Acta Neuropathol*. 2008;116(1):79–86.
6. Soderberg-Naucler C, Johnsen JI. Cytomegalovirus infection in brain tumors: A potential new target for therapy? *Oncoimmunology*. 2012;1(5):739–740.
7. Baumgarten P, Michaelis M, Rothweiler F, et al. Human cytomegalovirus infection in tumor cells of the nervous system is not detectable with standardized pathologico-virological diagnostics. *Neuro Oncol*. 2014;16(11):1469–1477.
8. Sardi I, Lucchesi M, Becciani S, et al. Absence of human cytomegalovirus infection in childhood brain tumors. *Am J Cancer Res*. 2015;5(8):2476–2483.
9. Cobbs C. Response to "Human cytomegalovirus infection in tumor cells of the nervous system is not detectable with standardized pathologico-virological diagnostics". *Neuro Oncol*. 2014;16(11):1435–1436.
10. Lawler SE. Cytomegalovirus and glioblastoma; controversies and opportunities. *J Neurooncol*. 2015;123(3):465–471.

Received 11 May 2016; accepted 6 June 2016
Advance Access date 12 August 2016

doi:10.1093/neuonc/now151

Dynamic O-(2-[18F]fluoroethyl)-L-tyrosine PET imaging for the detection of checkpoint inhibitor-related pseudoprogression in melanoma brain metastases

Keywords: brain metastases, FET-PET, melanoma, pseudoprogression.

Identifying patients with pseudoprogression, which is characterized by an initial increase of contrast-enhancing lesions that resolve or at least stabilize spontaneously on follow-up imaging without any treatment change, is critical for avoiding premature termination of potentially effective treatment. With the advent and success of checkpoint inhibitors such as ipilimumab, nivolumab, or pembrolizumab in particular, detecting pseudoprogression in patients with malignant melanoma has become a major challenge in clinical practice given a frequency as high as 7%–10% of cases.[1,2] Diagnosing progressive disease and excluding pseudoprogression in melanoma metastases using the immune-related Response Criteria (irRC)[2] require the initial increase of at least 25% in lesions load to be confirmed by follow-up imaging at least 4 weeks later.[2] However, particularly for brain metastases from malignant melanoma, follow-up imaging might not be feasible for patients with clinical deterioration at the time of initial increase of lesions load. These patients might not be able to wait 4 weeks for a follow-up investigation to decide on potentially required therapy adjustments. In this scenario, a noninvasive imaging technique for timely detection of pseudoprogression in this patient population would be very useful but has not been investigated to date.

PET using radiolabeled amino acids such as O-(2-[18F]fluoroethyl)-L-tyrosine (FET) allows imaging of amino acid transport in brain tumors and has shown promise in distinguishing pseudoprogression from true progressive tumor in glioblastoma. FET-PET has detected early and late pseudoprogression in glioblastoma patients with an accuracy of 96 % and 85%, respectively.[3,4]

To assess whether FET-PET might be valuable for distinguishing pseudoprogression in patients with malignant melanoma brain metastases, we conducted a small retrospective pilot study. A total of 5 patients with brain metastases from histologically proven malignant melanoma were enrolled for FET-PET imaging while under immune checkpoint inhibitor treatment at the time of the initial increase of brain tumor burden by at least 25% as evidenced by contrast-enhanced MR imaging. Four patients were treated with ipilimumab and one patient with nivolumab at the time of PET investigation. Patients' characteristics are given in supplementary Table 1. Pursuant to irRC, the final diagnosis was assessed built on follow-up MR imaging at least 4 weeks later. Three experienced observers analyzed each image independently (one board-certified in neuroradiology). One patient was classified as having pseudoprogression (Fig. 1A), while the remaining 4 patients presented signs of true tumor progression (Fig. 1B).

Metabolic tumor activity of FET-PET was evaluated by calculating the mean and maximum tumor-to-brain ratio (TBR_{mean}, TBR_{max}, respectively) (Fig. 1C).[5] In the 4 patients with true tumor progression, TBRmax values were considerably higher (median TBR_{max}, 5.4; range, 2.9–8.6) as compared with the patient diagnosed with pseudoprogression (TBR_{max}, 2.5). Furthermore, time-to-peak values (TTP; time in minutes from the beginning of the dynamic acquisition up to the maximum standardized uptake value of the lesion), which has been shown to be inversely correlated with pseudoprogression,[4] was accordingly shortened in the patients with true progression (median TTP, 17 min; range, 10–20 min) as compared with the patient with pseudoprogression (TTP, 45 min). Additionally, a time-activity curve (TAC) with a constantly increasing FET uptake was present in the patient with pseudoprogression, consistent with TAC in high-grade glioma patients with pseudoprogression.[3,4] MR and PET images of patients with true progression and pseudoprogression are presented in Fig. 1.

Our report uncovers a previously unrecognized applicability of FET-PET imaging for detecting checkpoint inhibitor-related pseudoprogression in patients with melanoma brain metastases at the early stages of increasing tumor burden. This might particularly facilitate the care of patients with rapidly deteriorating clinical courses. However, the very small sample size limits our study; therefore, a systematic analysis in a larger cohort is warranted.

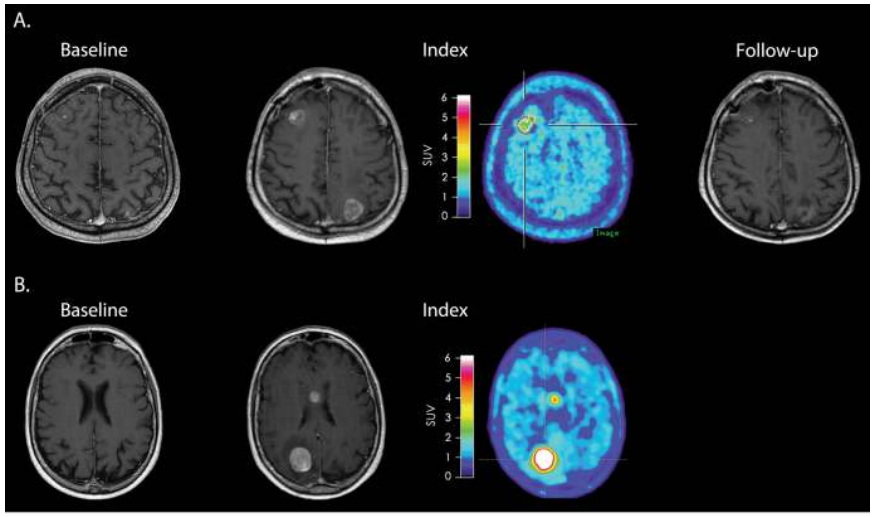

C.

(18)F-FET-PET analysis					
Patient ID	#1	#2	#3	#4	#5
Number of suspicious lesions in PET	>10	4	6	2	3
PET diagnosis	progression	progression	progression	progression	pseudoprogression
TBRmean*	2.01	4.50	4.20	2.30	1.80
TBRmax*	2.90	7.40	8.60	3.40	2.50
TTP* (min)	n/a	10	17	20	45
Kinetic pattern*	n/a	3	2	2	1

Abbreviations: PET, positron emission tomography; TBRmax, maximal tumor-to-brain ratio; TBRmean, mean tumor-to-brain ratio; TTP, time-to-peak.
* For this calculation only the patient's brain metastasis with highest TBR values was considered.

Fig. 1. A. MRI and PET images of patient #5, who was diagnosed with pseudoprogression using immune-related response criteria (irRC). The index MRI shows a clear >25% increase in contrast-enhancing melanoma metastases (frontal and occipital). Only a low tracer uptake was observed on FET-PET. Accordingly on follow-up, MRI (obtained 8 weeks later) showed a clear decrease in tumor burden consistent with pseudoprogression. B. MRI and PET images of patient #3, who was diagnosed with true progression using irRC. The index MRI again showed a clear >25% increase in contrast-enhancing melanoma metastases (central and occipital). A very high tracer uptake was observed on FET-PET. A follow-up MRI was not feasible as the patient died 8 weeks later. C. FET-PET imaging parameters of all patients included in the present study. The kinetic pattern represents 3 patterns of time-activity curves: constantly increasing FET uptake without identifiable peak uptake (pattern I); FET uptake peaking at a midway point (> 20–40 min) followed by a plateau or a small descent (pattern II); and FET uptake peaking early (≤ 20 min) followed by a constant descent (pattern III). Patterns II and III are known to be associated with true progression in glioblastoma.[3]

Supplementary material

Supplementary material is available online at *Neuro-Oncology* (http://neuro-oncology.oxfordjournals.org/).

Conflict of Interest statement. none

Sied Kebir, Laurèl Rauschenbach,* Norbert Galldiks, Max Schlaak, Elke Hattingen, Jennifer Landsberg, Ralph A. Bundschuh, Karl-Josef Langen, Björn Scheffler, Ulrich Herrlinger, Martin Glas

Division of Clinical Neurooncology, Department of Neurology, University of Bonn Medical Center, Bonn, Germany (S.K., M.G., U.H.); Stem Cell Pathologies Group, Institute of Reconstructive Neurobiology, Bonn, Germany (S.K., L.R, B.S., M.G.); Center of Integrated Oncology (CIO), Universities of Cologne and Bonn, Germany (S.K., N.G., M.S., U.H., M.G.); Department of Neurology, University of Cologne, Cologne, Germany (N.G.), Institute of Neuroscience and Medicine, Forschungszentrum Jülich, Jülich, Germany (N.G., K-J.L.); Department of Dermatology, University of Cologne, Cologne, Germany (M.S.); Neuroradiology, Department of Radiology, University of Bonn Medical Center, Bonn, Germany (E.H.); Laboratory of Experimental Dermatology, Department of Dermatology and Allergy, University of Bonn Medical Center, Bonn, Germany (J.L.); Department of Nuclear Medicine, University of Bonn Medical Center, Bonn, Germany (R.A.B.); Dept. of Nuclear Medicine, University of Aachen, Aachen, Germany (K-J.L.); DKFZ-Division of Translational Oncology / Neurooncology, German Cancer Consortium (DKTK) & University Hospital Essen, Essen, Germany (B.S.); Clinical Cooperation Unit Neurooncology, MediClin Robert Janker Klinik, Bonn, Germany (M.G.)

*SK and LR contributed equally

Corresponding author: PD Dr. Martin Glas, Division of Clinical Neurooncology, Department of Neurology, University of Bonn Medical Center, Bonn, Sigmund-Freud-Straße 25, 53127 Bonn, Germany (Martin.Glas@ukb.uni-bonn.de)

References

1. Hodi FS, Hwu WJ, Kefford R, et al. Evaluation of Immune-Related Response Criteria and RECIST v1.1 in Patients With Advanced Melanoma Treated With Pembrolizumab. *J Clin Oncol*. 2016;34(13):1510–1517.
2. Wolchok JD, Hoos A, O'Day S, et al. Guidelines for the evaluation of immune therapy activity in solid tumors: immune-related response criteria. *Clin Cancer Res*. 2009; 15(23):7412–7420.
3. Galldiks N, Dunkl V, Stoffels G, et al. Diagnosis of pseudoprogression in patients with glioblastoma using O-(2-[18F]fluoroethyl)-L-tyrosine PET. *Eur J Nuc Med Mol Imag*. 2015;42(5):685–695.
4. Kebir S, Fimmers R, Galldiks N, et al. Late Pseudoprogression in Glioblastoma: Diagnostic Value of Dynamic O-(2-[18F]fluoroethyl)-L-Tyrosine PET. *Clin Cancer Res*. 2016;22(9):2190–2196.
5. Bette S, Peschke P, Kaesmacher J, et al. Static FET--PET and MR Imaging in Anaplastic Gliomas (WHO III). *World Neurosurg*. doi:http://dx.doi.org/10.1016/j.wneu.2016.02.094.

Received 11 May 2016; accepted 6 June 2016
Advance Access date 2 September 2016

doi:10.1093/neuonc/now154