

Cite this article as: Scarci M, Abah U, Solli P, Page A, Waller D, van Schil P *et al.* EACTS expert consensus statement for surgical management of pleural empyema. *Eur J Cardiothorac Surg* 2015;48:642–53.



EACTS expert consensus statement for surgical management of pleural empyema

Marco Scarci^{a,*}, Udo Abah^{a,†}, Piergiorgio Solli^{a,†}, Aravinda Page^a, David Waller^b, Paul van Schil^c, Franca Melfi^{d,‡}, Ralph A. Schmid^e, Kalliopi Athanassiadi^f, Miguel Sousa Uva^{g,¶} and Giuseppe Cardillo^{h,§}

- ^a Department of Cardiothoracic Surgery, Papworth Hospital, Cambridgeshire, UK
^b Department of Thoracic Surgery, Glenfield Hospital, Leicester, UK
^c Department of Thoracic and Vascular Surgery, Antwerp University Hospital, Antwerp, Belgium
^d Department of Cardiothoracic Surgery, Azienda Ospedaliero Universitaria Pisana, Pisa, Italy
^e Division of General Thoracic Surgery, Berne University Hospital, Berne, Switzerland
^f Unit of Thoracic Surgery, Evangelismos Hospital, Athens, Greece
^g Unit of Cardiac Surgery, Hospital Cruz Vermelha, Lisbon, Portugal
^h Unit of Thoracic Surgery, Az. Osped. S. Camillo Forlanini, Carlo Forlanini Hospital, Rome, Italy

* Corresponding author. Papworth Hospital NHS Foundation Trust, Papworth Everard, Papworth, Cambridge CB23 3RE, UK. Tel: +44-1480-364474, fax: +44-1480-364740; e-mail: marco.scarci@nhs.net (M. Scarci).

Received 29 January 2015; received in revised form 10 June 2015; accepted 15 June 2015

Abstract

Pleural infection is a frequent clinical condition. Prompt treatment has been shown to reduce hospital costs, morbidity and mortality. Recent advances in treatment have been variably implemented in clinical practice. This statement reviews the latest developments and concepts to improve clinical management and stimulate further research. The European Association for Cardio-Thoracic Surgery (EACTS) Thoracic Domain and the EACTS Pleural Diseases Working Group established a team of thoracic surgeons to produce a comprehensive review of available scientific evidence with the aim to cover all aspects of surgical practice related to its treatment, in particular focusing on: surgical treatment of empyema in adults; surgical treatment of empyema in children; and surgical treatment of post-pneumonectomy empyema (PPE). In the management of Stage 1 empyema, prompt pleural space chest tube drainage is required. In patients with Stage 2 or 3 empyema who are fit enough to undergo an operative procedure, there is a demonstrated benefit of surgical debridement or decortication [possibly by video-assisted thoracoscopic surgery (VATS)] over tube thoracostomy alone in terms of treatment success and reduction in hospital stay. In children, a primary operative approach is an effective management strategy, associated with a lower mortality rate and a reduction of tube thoracostomy duration, length of antibiotic therapy, reintervention rate and hospital stay. Intrapleural fibrinolytic therapy is a reasonable alternative to primary operative management. Uncomplicated PPE [without bronchopleural fistula (BPF)] can be effectively managed with minimally invasive techniques, including fenestration, pleural space irrigation and VATS debridement. PPE associated with BPF can be effectively managed with individualized open surgical techniques, including direct repair, myoplastic and thoracoplastic techniques. Intrathoracic vacuum-assisted closure may be considered as an adjunct to the standard treatment. The current literature cements the role of VATS in the management of pleural empyema, even if the choice of surgical approach relies on the individual surgeon's preference.

Keywords: Video-assisted thoracic surgery • Pleural infection • Empyema

INTRODUCTION

Pleural infection is a frequent clinical condition with an approximate annual incidence of 80 000 cases in the UK and USA combined [1]. Of these, 20% may require surgical intervention, and prompt treatment has been shown to reduce hospital costs, morbidity and mortality [2]. The Pleural Disease Guideline Group of the British Thoracic Society (BTS) published in 2010 a comprehensive

guideline document for the medical management of pleural infection [3], with the aim to cover all aspects of surgical practice related to the treatment of pleural empyema. It is the aim of the European Association for Cardio-Thoracic Surgery (EACTS) to assess the topics of pleural empyema focusing on surgical treatment of empyema in adults and in children, and on surgical treatment of post-pneumonectomy empyema (PPE).

METHODOLOGY

The EACTS Thoracic Domain and the Pleural Diseases Working Group established a team of surgeons to produce a statement on

[†]The first three authors contributed equally to the development of the paper.

[‡]Franca Melfi, Chair of EACTS Thoracic Domain.

[¶]Miguel Sousa Uva, Chair of Clinical Guidelines Committee.

[§]Giuseppe Cardillo, Chair of EACTS Working Group for Pleural Diseases.

Table 1: Methodology checklist

	Yes	No
Panel assembly		
Experts from thoracic and cardiovascular surgery	x	
Experts vetted for conflict of interest	x	
Experts from Working Group on pleural diseases	x	
Experts from Clinical Guidelines Committee	x	
Literature review		
Performed in collaboration with librarian	x	
Searched in multiple electronic databases (Medline/PUBMED/EMBASE/Cochrane Library)	x	
Reviewed reference list of retrieved articles	x	
Evidence synthesis		
Pre-specified inclusion and exclusion criteria applied		x
Evaluation of included studies for source of bias	x	
Explicitly summarized benefits and harms	x	
Grading system used		x
Included studies evaluated		
Recommendations for clinical practice		x
Summary/opinions	x	

Table 2: Level of evidence

Level A	Data derived from multiple randomized clinical trials or meta-analyses
Level B	Data derived from a single randomized clinical trial or large non-randomized trials
Level C	Consensus of opinion of the experts and/or small studies, retrospective studies, registries

the surgical treatment of pleural empyema. A statement is considered a comprehensive scientific review by a group of experts, which is based on a body of scientific evidence identified by systematic searches and documented by references supporting the conclusions. Initially, a set of key clinical questions was formulated on the epidemiology, diagnosis and classification of empyema, and also on (i) surgical treatment of empyema in adults, (ii) surgical treatment of empyema in children and (iii) surgical treatment of PPE. To obtain a body of scientific evidence, a systematic literature search was performed on medical databases Medline/PUBMED (National Library of Medicine, USA), EMBASE (Elsevier, Netherlands) and Cochrane Library (UK) [4, 5].

The initial search was performed in January 2013 and repeated in September 2014. The search was limited to reference material published since 1975 (Table 1).

Levels of evidence are derived from published papers (Table 2) and recommendations classed by the strength of their recommendation (Table 3).

The preliminary document was circulated among all the involved members for further input and comments. A final version was then revised to incorporate all the pertinent comments suggested and submitted to the EACTS Thoracic domain and the Working Group on Pleural Diseases for further input and implementation. The final revised version of the document was reviewed by the authors, finalized, approved and submitted to the EACTS Thoracic Domain during the Annual Meeting in Milan, Italy, 11–15 October 2014, for endorsement. After endorsement, the paper was submitted to the Clinical Guidelines Committee for

Table 3: Grade of recommendation

Class I	Evidence and/or general agreement that a given treatment or procedure is beneficial, useful, effective.
Class II	Conflicting evidence and/or a divergence of opinion about the usefulness/efficacy of the given treatment or procedure.
Class IIa	Weight of evidence/opinion is in favour of usefulness/efficacy.
Class IIb	Usefulness/efficacy is less well established by evidence/opinion.
Class III	Evidence or general agreement that the given treatment or procedure is not useful/effective, and in some cases may be harmful.

formal evaluation and after final approval submitted to the European Journal of Cardio-Thoracic Surgery (EJCTS) for peer review. This statement describes the current evidence and practices for pleural empyema.

It does not make recommendations for clinical practice.

DEFINITIONS OF PARAPNEUMONIC EFFUSION AND EMPYEMA

The development of empyema in association with pneumonia is a progressive process and has been classified [3] into three stages as follows:

- (1) *Parapneumonic effusion (Stage 1)*, whereby the fluid is a free-flowing exudate characterized by a low white cell count, an LDH level less than half that in the serum, normal pH and glucose levels and does not contain bacterial organisms.
- (2) *Fibrinopurulent stage (Stage 2)*, whereby there is bacterial invasion across the damaged lung epithelium, and this stimulates the immune response, creating fibrin deposition and loculations in the fluid. At this stage, fluid analysis may identify the characteristic finding of a pH <7.20, glucose <2.2 mmol/l and LDH over 1000 IU/l. Without pus, this may be termed a complicated parapneumonic effusion, but if frank pus is found, then this is most correctly called an empyema.
- (3) *Chronic organizing stage (Stage 3)*, with scar tissue (pleural cortex) formation. In the later stages, a solid fibrous pleural cortex begins to form, which may encase the lung, preventing re-expansion, impairing lung function and creating a persistent pleural space with continuing potential for infection.

STAGING INVESTIGATIONS

A staging assessment, based mainly on the start of symptoms, is not an easy task in some cases. Chest X-ray, ultrasound (US), and computed tomographic (CT) scan are all required and considered the mainstay imaging modalities for effusion [3]. The last decade has seen a significant trend worldwide to employ thoracic US at the bedside to assess for the presence of effusions, especially in the context of pleural infection.

Pleural ultrasound

Pleural US is fast, safe and effective in confirming the presence of pleural fluid and estimating its volume, can differentiate between

pleural fluid and thickening, and aids thoracentesis in localizing the optimal site for diagnostic and therapeutic intervention in real time. The use of real-time pleural US by trained operators has been shown to improve the safety of sampling effusions, with reductions in iatrogenic pneumothoraces [3]. It has been currently incorporated into diagnostic algorithms in major centres, it is sensitive in detecting small volumes of fluid and loculations often not evident on CT, and is rapidly being considered as an extension of the clinical examination and a core skill.

Computed tomography

On the other hand, contrast-enhanced thoracic CT-scan images are commonly able to detect and assess concomitant pneumonia and is the imaging investigation of choice. Thoracic CT allows not only assessment of the pleura itself, but also chest tube position if existing, the presence and degree of loculations, any parenchymal changes, endobronchial lesions and differentiation of lung abscess from empyema. Mostly, CT scan is crucial in the evaluation of pleural thickening (nodular, mediastinal pleural thickening suggesting underlying malignancy, circumferential pleural thickening), can display both visceral and parietal pleural thickening >1 cm and, in this sense, is fundamental for planning management strategy according to the expected stage of the empyema (trapped lung with very fibrotic visceral pleural peel or loculated early stage empyema). Anyway, we did not find CT helpful in predicting the success of video-assisted thoracoscopic surgical (VATS) decortication [3].

Bronchoscopy

The role of bronchoscopy in patients with empyema has not been addressed specifically by any studies. It is usually performed at the time of surgery, but only a small number of cases have obstructing lesions predisposing to empyema (i.e. tumour or inhaled foreign body). Bronchoscopy is particularly recommended where there is a mass or volume loss on imaging; nevertheless, sputum removal prior to decortication will facilitate lung re-expansion.

THE SURGICAL TREATMENT OF ADULT EMPYEMA

Thoracentesis

All patients with a pleural effusion in association with sepsis or a pneumonic illness require a prompt diagnostic pleural fluid sampling, because any effusion identified on chest X-ray could possibly turn into a pleural infection, and it is impossible clinically to differentiate the presence of a complicated parapneumonic effusion requiring chest tube drainage from a simple effusion that may resolve with antibiotics alone [3].

The role of therapeutic-repeated thoracentesis as an alternative to formal chest drain placement or an early VATS procedure in order to prevent 'empyema stage migration' in uncomplicated parapneumonic effusion and early empyema is unknown. Therapeutic thoracentesis and antibiotics alone have demonstrated to be successful in one study [3], but thoracentesis has not yet been compared with formal drainage in randomized controlled trials and, currently, the evidence suggests its use as a

preoperative crucial diagnostic tool rather than in influencing surgical management.

Tube thoracostomy

Historically, early stage empyema was managed with tube thoracostomy with more advanced stages requiring open thoracotomy and decortication. The current BTS guidelines recommend tube thoracostomy and antibiotics for the treatment of early stage empyema, with surgical intervention reserved for failure of these initial measures in the presence of persistent pleural collection. The introduction of VATS added new therapeutic techniques to the armament of surgical strategies, with many surgeons preferring the VATS approach for the management of empyema. Currently, there is no consensus on which surgical option is first line. A literature search was performed to investigate whether VATS decortication is superior to either decortication via thoracotomy or simple tube thoracostomy. This search is fully documented in the *Interactive CardioVascular and Thoracic Surgery Journal (ICVTS)* [6] and the results tabulated in Table 3. The majority of data from surgical series address the management of Stage 2 and 3 empyema.

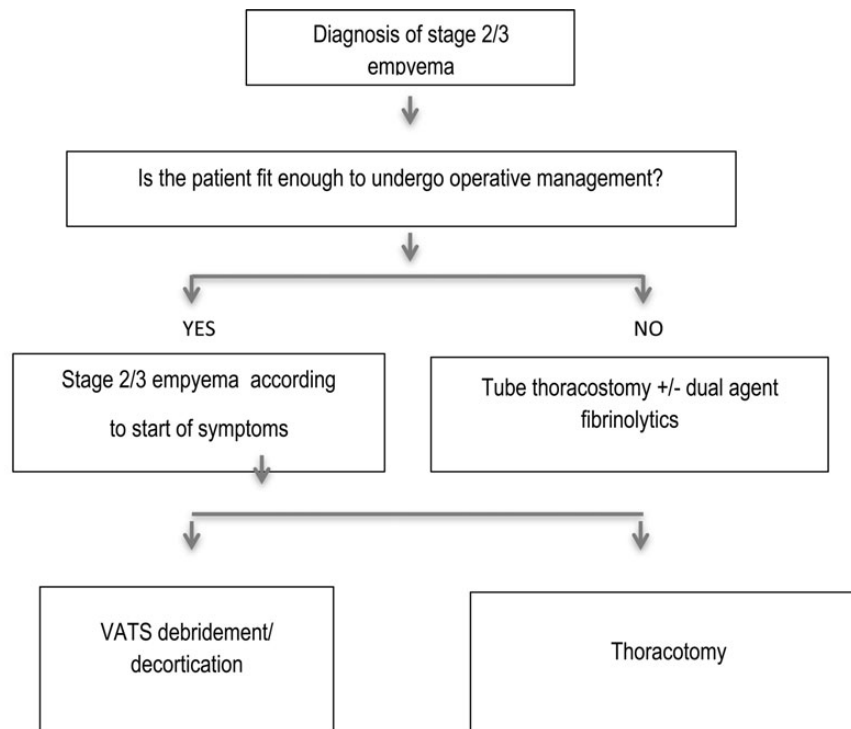
Summary. In the management of Stage 1 empyema, we are in agreement with the recommendation of the BTS guideline; patients with frankly purulent or turbid/cloudy pleural fluid on sampling should receive prompt pleural space chest tube drainage. The efficacy of drainage is assessed by a complete lung expansion and a resolution of symptoms [3].

In the management of Stage 2 and 3 empyema, there is a demonstrated benefit of surgical debridement or decortication over tube thoracostomy alone in terms of treatment success and reduction in hospital stay [6–8] (Fig. 1, Table 4).

Intrapleural fibrinolysis

The use of intrapleural fibrinolytics via tube thoracostomy has gained recent interest among the thoracic surgical community. The introduction of fibrinolytic agents into the pleural space is thought to cleave fibrous septations and improve the drainage of fibrinopurulent empyema. Although a number of observational studies report an improved drainage with fibrinolytic use [29–34], the first large multicentre trial (Multicenter Intra-pleural Sepsis Trial, MIST1 [35]) reported no benefit of intrapleural fibrinolysis (with streptokinase) and this finding was further validated by a meta-analysis [36]. However, the MIST2 trial [37] found that a combination of tissue plasminogen activator (t-PA) and DNase improved fluid drainage and reduced the frequency of surgical referral and duration of hospital stay. Although the MIST2 trial confirmed a role for intrapleural fibrinolysis, debate still exists regarding its efficacy when compared with primary VATS in the management of fibrinopurulent empyema. A randomized trial [38] comparing tube thoracostomy with streptokinase ($n = 9$) with VATS ($n = 11$) found that primary intervention with VATS resulted in higher treatment success (91 vs 44%), lower chest tube duration (5.8 vs 9.8 days) and decreased total hospital stay (8.7 vs 12.8 days), and this was further demonstrated by observational studies by Petrakis *et al.* [39] and Muhammed *et al.* [9].

Summary. Currently, the specific role of intrapleural fibrinolysis is yet to be defined; however, due to the favourable outcomes of



INDICATIONS FOR THE SURGICAL MANAGEMENT OF EMPYEMA IN ADULTS	
(1)	In patients with stage 2 or 3 empyema who are fit enough to undergo an operative procedure surgical intervention with video-assisted thoracoscopic surgery is suggested. Class I Level B
(2)	In patients with stage 2 empyema intra-pleural fibrinolysis with dual agent fibrinolytics may be considered as an alternative to surgical intervention Class IIa Level B
(3)	In patients with stage 3 empyema and a prolonged period from symptom onset, decortication may be performed by open decortication. Class IIb Level C. In experienced units VATS might be considered as a primary approach even in stage 3, provided that conversion is justified if the procedure is not able to achieve a complete resolution of the disease

Figure 1: Management of empyema in the adult. VATS: video-assisted thoracoscopic surgery.

VATS, it may well be reserved for those patients unsuitable for surgical intervention and single lung ventilation (Fig. 1, Table 4).

Video-assisted thoracoscopic surgery

The goals of surgery for empyema are: (i) to debride the pleural cavity and (ii) to achieve lung re-expansion.

Debridement of the pleural cavity comprises drainage of all fluid, breaking of all loculations and removal of all the pleural exudate. Decortication entails thorough removal of the restrictive cortex of fibrous and infected tissue overlying the visceral pleura to allow the lung to re-expand.

The method of approach by which these goals are achieved remains controversial and while some surgeons advocate VATS, others strongly favour an open approach. Studies reporting outcomes for a mixed population of Stage 2/3 empyema report at least equivalent outcomes in terms of resolution of disease for VATS when compared with open surgery [10–15], and many authors report additional benefits of a minimally invasive approach including a reduction in operative time [9], postoperative

pain, duration of chest tube [13, 16] and length of hospital stay [9, 13–15]. Other potential benefits include greater satisfaction with postoperative wound appearance [11, 14] and an earlier return to work. It must be acknowledged that non-randomized studies may introduce selection bias, possibly attributing technically more challenging procedures to an open approach.

The need for intraoperative conversion from VATS to thoracotomy correlates with the stage of disease and time from symptom onset [17]. Higher conversion rates are also associated with male gender, post-pneumonic empyema and gram-negative organisms [18]. Lardinois *et al.* reported that the probability of conversion to thoracotomy rose from 22 to 86% between an interval of 12 and 16 days, respectively [18].

In the management of Stage 3 disease, VATS has been shown to be as effective as open decortication in a significant proportion of patients [17, 19, 20] with the associated benefits of a minimally invasive approach. There is, however, the caveat of a high conversion rate to open decortication, with some series reporting conversion rates above 40% [20]. Decortication of Stage 3 empyema via VATS requires a significant learning curve and success with VATS correlates with operative experience and skill [20].

Table 4: Studies detailing the management of pleural empyema in the adult

Study	Stage of empyema	Procedure (no. of patients)	Operative time (min)	Chest tube drainage (days)	Postoperative length of stay (days)—mean unless stated	Postoperative morbidity	Procedure success	Reintervention	Mortality	Conversion rate
VATS versus thoracotomy										
Muhammed [9]	Stage 2/3	VATS (25)	84.68 ± 23.98	5.72 ± 3.27	7.76 ± 4.63	–	92%	0%	0%	8%
Prospective		Open (24)	137.37 ± 26.9	7.25 ± 2.31	8.87 ± 2.59	–	100%	0%	0%	
Cardillo [10]	Stage 2/3	VATS (185)	79.7 ± 6.8	–	8.6 ± 1.8	18.3%	98.4%	1.62%	0%	5.9%
Retrospective		Open (123)	70.0 ± 7.4	–	10 ± 7.8	25.2%	100%	4.8%	3.3%	
Chan [11]	Stage 2/3	VATS (41)	150 ± 57.6	7.9 ± 5.7	16 ± 6.5	22% ^a	100%	0%	0%	0%
Prospective		Open (36)	228 ± 84	8.5 ± 4.4	21 ± 14.2	–	100%	0%	0%	
Tong [12]	Stage 2/3	VATS (326)	97	7.0 ± 13.7	7 ^b	–	92.3%	7.7%	7.6%	11.4%
Retrospective		Open (94)	155	9.7 ± 10.1	10 ^b	–	89.4%	10.6%	16.1%	
Casali [13]	Stage 2	VATS (27)	100.4	4.0	6.4	24% ^a	100%	–	0%	8%
Retrospective		Open (24)	115.4	7.3	9.0	–	100%	–	0%	
Angelillo [14]	Stage 3	Open (68)	131.5	5.7	14.6	–	97.1%	–	2.94%	
Stage 2	VATS (31)	119 ± 32.5	4.3 ± 1.5	6.7 ± 3.0	16.1%	100%	0%	3.2%	10%	
Retrospective		Open (33)	123 ± 25.8	6.1 ± 2.3	11.6 ± 9.1	15.1%	88%	12%	3%	
Marks [15]	Stage 2/3	VATS (116)	–	–	5 ^b	25.1% ^a	95.1% ^a	–	5.7%*	14.7%
Retrospective		Open (277)	–	–	7 ^b	–	–	–	–	
Podbielski [16]	Stage 2/3	VATS (16)	76.2 ± 30.7	4.7 ± 2.8	17.6 ± 16.8	6.25%	–	–	–	6.7%
Retrospective		Open (14)	125.0 ± 71.7	8.3 ± 4.6	10.0 ± 7.2	7.14%	–	–	–	
Chung [17]	Stage 3	VATS (14)	138.6 ± 52.1	10 ± 4.2	13.5 ± 6.4	–	92.9%	7.1%	0%	0%
Retrospective		Open (8)	299.4 ± 74.7	18.75 ± 19.8	19 ± 12.8	–	–	–	–	
Lardinois [18]	Stage 2/3	VATS (178)	–	–	–	9% ^a	56%	2%	3%	44%
Retrospective		Open (150)	–	–	–	–	97.4%	2.6%	4%	
Shahin [19]	Stage 2	VATS debridement (28)	–	–	6 ^b	3.5%	–	–	0%	0%
Retrospective	Stage 3	VATS decortication (32)	–	–	5 ^b	9.3%	–	–	0%	19%
	Stage 2/3	Open (21)	–	–	8 ^b	26.1%	–	–	0%	–
Waller [20]	Stage 3	VATS decortication (21)	78.8 ± 6.5	–	5.5 ± 0.6	–	100%	0%	4.8%	41.7%
Retrospective		Open-converted (15)	119.6 ± 13.5	–	8.5 ± 1.3	–	100%	0%	6.7%	
		Primarily open (12)	109 ± 5.5	–	8.4 ± 0.7	–	100%	0%	0%	
Series of VATS for management of empyema										
Stefani [21]	Stage 2/3	VATS (97)	146	4.4	8.3	5%	100%	–	0%	59%
Retrospective		Converted to open	162	5.0	8.4	18%	–	–	–	
Solaini [22]	Stage 2/3	110	–	6.0	7.1	11%	99.1%	–	–	8.2%
Retrospective										
Drain [23]	Stage 3	52	–	3.9	10 ^b	0%	94%	6%	0%	0%
Retrospective										
Luh [17]	Stage 2/3	234	64.3 ± 22.5	7 ^b	12 ^b	7.7%	86.3%	6.8%	3.4%	10.3%
Retrospective										
Kim [24]	Stage 2/3	70	–	5 ± 3	5 ± 0.7	0%	92.9%	–	0%	7.1%
Retrospective										
Roberts [25]	Stage 2/3	VATS (172)	–	10.5	15.3	9%	38.4%	3.0%	0%	61.6%
Retrospective		Converted to open	–	–	–	21%	97.2%	2.8%	10.4%	
Striffeler [26]	Stage 2	67	82.1	4.1	12.3	–	–	4%	4%	28%
Retrospective										
Lawrence [27]	Stage 2/3	VATS (42)	–	4.0 ± 0.3	5.3 ± 0.4	–	71.4%	23.8%	0	4.8%
Retrospective		Converted to open	–	8.5 ± 2.0	10.3 ± 2.1	–	–	–	–	
Chung [17]	Stage 2/3	120	111.9	7.4	10.0	–	95.8%	4.2%	0%	1.4%
Retrospective										
Landreneau [28]	Stage 2/3	76	–	3.3 ± 2.9 (in 67 patients)	7.4 ± 7.2	–	83%	7.9%	6.6%	17%
Retrospective										

^aStudy did not differentiate outcomes between the VATS and open group.^bMedian values.

Interestingly, Kho *et al.* [40] recently published a study comparing debridement and formal decortication. Sixteen patients underwent debridement by a limited thoracotomy and 9 decortication via full thoracotomy. There was a 30% reduction in cavity size on discharge in both groups and equivalent results at the 45-day follow-up. It is therefore reasonable to consider a primary VATS approach in both Stage 2 and Stage 3 empyema in patients who are fit for surgery.

Early surgical referral is advised for successful VATS and the delay in surgical intervention has been shown to have an impact on empyema stage migration. Several authors have documented that time of referral is the most common and independent factor affecting rate of conversion from VATS to open thoracotomy [10, 18, 22, 23, 24–17]. One study demonstrated that the probability of thoracotomy increased from 28% if the operation was performed within 10 days from the onset of symptoms to 81% if it was performed with a delay of between 30 and 40 days [25].

Summary. In summary, the current literature cements the role of VATS in the management of pleural empyema. While there is significant heterogeneity between studies, with discrepancies in the definition of debridement/decortication, stage and aetiology of empyema, all studies demonstrate successful management with VATS [25–28, 41–44]. Many reports suggest additional benefits over open surgery or tube thoracostomy with or without fibrinolytic agents. Ultimately, the choice of surgical approach relies on the individual surgeon's preference, with many advocates of open decortication stating completeness of decortication as their motivation. In conclusion, there is nothing to be lost in attempting VATS in all cases, provided that conversion to open thoracotomy is performed if resolution of the empyema and lung expansion is not adequately achieved (Fig. 1, Table 4).

Thoracotomy

The exact placement of the open incision can be planned from preoperatively especially in the presence of a loculated empyema. Open surgery should include evacuation of all purulent material and thorough decortication of the parietal and visceral pleura together with complete separation of the diaphragm from the lung. Attention should be directed to the complete enucleation of the infected sac: 'empyemectomy'.

This is best achieved through extra-pleural dissection and is a safe and time-saving procedure.

Empyemectomy is difficult to achieve by VATS; nevertheless, in the light of the great majority of the works in the recent literature, the minimally invasive approach could represent the treatment of choice for pleural empyema.

Tuberculosis (TB)-related empyema remains an area in which there is no level A evidence to guide practice; suggested indications include cancer, destroyed lung, haemoptysis, multidrug-resistant TB, pleural disease and aspergilloma [45]. More recently, larger series (1297 operative cases) with promising results (1.37% early and 2.83% late mortality after the exclusion of window thoracostomy) have provided more compelling evidence for the incorporation of surgical treatment into practice guidelines and recommendations [46].

Summary. In summary, the current literature supports the use of VATS as the initial step at least for exploration and evacuation of necrotic material from the cavity (debridement). Visceral decortication and 'empyemectomy' can be technically demanding and even in the presence of a reported high success rate for VATS (from 68 to

93%), there should be increased awareness of its limitations in patients with a symptomatic history over 5 weeks (presumed Stage III) (Fig. 1, Table 1).

EMPYEMA IN CHILDREN

In the management of empyema in the paediatric population, the optimal first-line therapeutic strategy remains controversial. A best evidence topic was performed to investigate whether VATS decortication is superior to either decortication via thoracotomy or simple tube thoracostomy [47]. The literature search failed to show definitive significant advantages of surgery over conservative chest tube drainage.

On the basis of the reported studies, we concluded that early VATS (or thoracotomy if VATS is not possible) leads to shorter hospitalization [47]. *Streptococcus pneumoniae* remains one of the most common causative organisms of empyema, particularly in the developed world and especially so in children [48]. The current management guidelines, as published by the British Thoracic Society [3], reserve surgical intervention as an adjunct to antibiotic therapy either when maximal antibiotic therapy has not been sufficient or when there is some associated lung pathology, related complications or sepsis. Currently, there is no definitive evidence to suggest that early surgical management may be indicated based purely on the causative pathogen.

The argument for primary surgery

A systematic review of 44 retrospective studies involving 1369 patients concluded that early VATS or thoracotomy was associated with a shorter hospital stay and a trend towards shorter duration of postoperative fever when compared with tube thoracostomy alone or in combination with fibrinolytic therapy [49]. The benefit of primary operative therapy was echoed by a meta-analysis of 67 studies, which concluded that primary operative intervention is associated with a lower in-patient mortality, reintervention rate, hospital stay, duration of tube thoracostomy and duration of antibiotic therapy when compared with non-operative management [50]. Subsequently, a number of retrospective studies have further described the benefits of primary surgical intervention. It should be noted that, in children, tube thoracostomy may require sedation or even anaesthesia. Therefore, VATS should be considered if the patient is so prepared [51–56].

The argument for primary non-operative treatment

However, contrasting retrospective series have reported successful outcomes with primary non-operative management [57–59] and a subsequent review of the literature concluded that the main steps in treatment are percutaneous drainage with consideration of fibrinolysis, with VATS reserved for failure of initially non-operative management [60]. Three randomized control trials compared VATS with chest drainage with fibrinolytics and found no significant difference in outcomes in two of the three trials [61]. Sonnappa *et al.* [62] and St Peter *et al.* [63] used small (8–12 French) chest drains with routine administration of fibrinolytics, whereas Kurt *et al.* [64] used larger chest drains (16–24 French) and

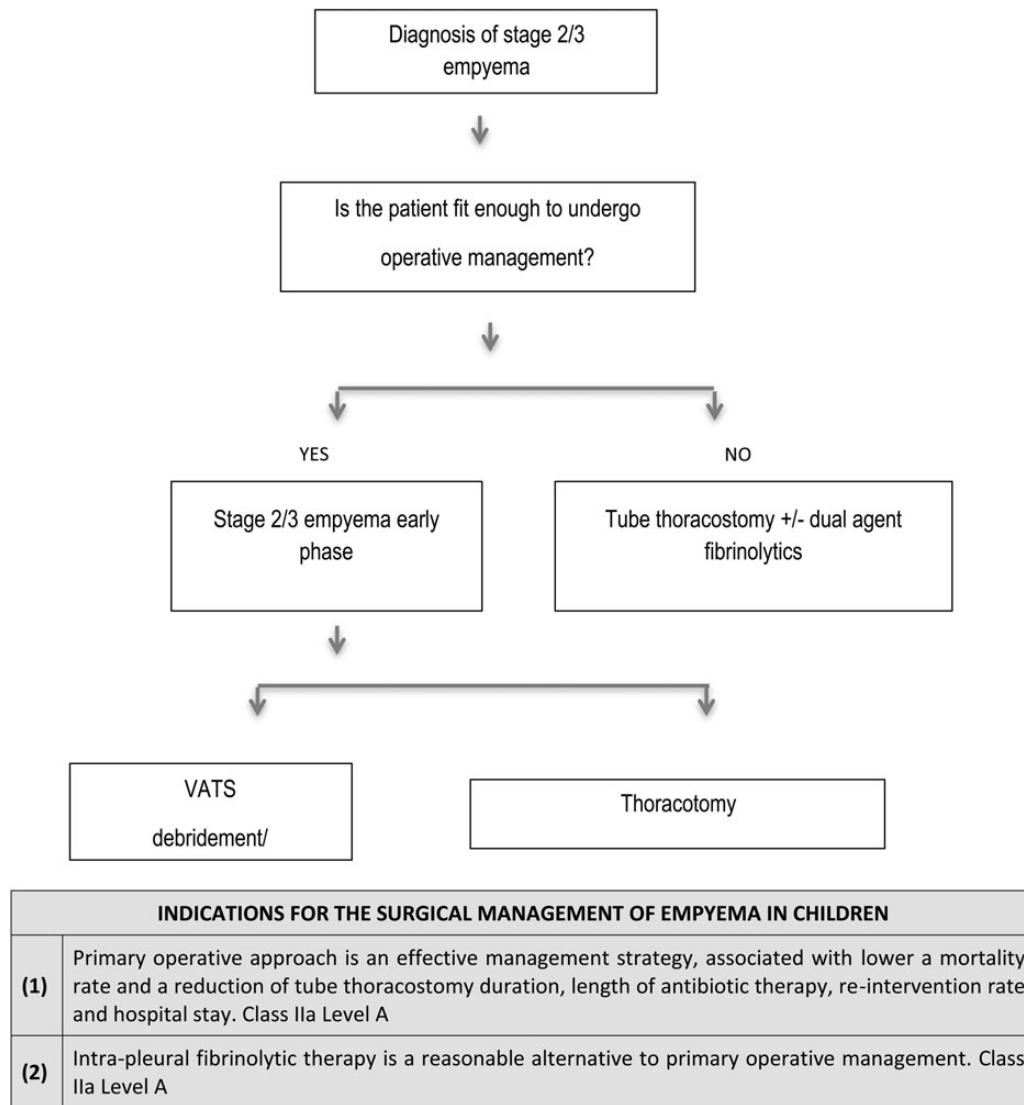


Figure 2: Management of empyema in children. VATS: video-assisted thoracoscopic surgery.

administered fibrinolytics as a rescue therapy based on imaging and drainage. The study by Kurt *et al.* was stopped early owing to an observed benefit in the mean hospital stay (5.8 ± 2.8 vs 13.2 ± 7.2 days, $P < 0.01$) with VATS. Hospital stays were equivalent between VATS and chest drain with fibrinolytics in the other two studies (St Peter: 6.9 ± 3.7 vs 6.8 ± 2.9 days; Sonnappa: 6 vs 6 days, respectively). St Peter later reported successful implementation of an evidence-based protocol using fibrinolysis as the first-line treatment for empyema in children; 16 of 102 patients required subsequent VATS [59]. Proponents of VATS suggest that VATS may reduce cytokine responses compared with conventional surgery [40].

Summary

In conclusion, the current evidence suggests the primary operative management with VATS is a safe and effective method of treating empyema in children; however, non-operative management with tube thoracostomy and fibrinolytics has been shown to be equally successful in some populations. It is therefore reasonable to manage patients with either treatment strategy based upon local expertise and success rates.

The role of VATS as 'primary surgical treatment' as the first-line approach for empyema in paediatric patients remains unclear. Although the few randomized trials in paediatric patients failed to show definitive significant advantages of surgery over conservative chest tube drainage, one might argue that, in the vast majority of paediatric conditions, tube thoracostomy could require sedation or even general anaesthesia for proper insertion and intrapleural agent therapy. In this regard, VATS seems a reasonable alternative and patients may be more likely to fail rescue VATS treatment following fibrinolytic agents, as it is suggested that urokinase causes intrapleural loculations to become very adhesive and increases the difficulty of a subsequent VATS procedure [49] (Fig. 2, Table 5).

POST-PNEUMONECTOMY EMPYEMA

A best evidence topic was performed to investigate the best treatment for PPE [65]. A literature search showed that an open surgical approach has a high success rate, low hospital stay and low re-intervention rate despite its use in arguably more challenging

Table 5: Studies detailing the management of pleural empyema in children

Study	Stage of empyema	Procedure (no. of patients)	Operative time (min)	Chest tube drainage (days)	Postoperative length of stay (days)—mean unless stated	Postoperative morbidity	Procedure success	Reintervention	Mortality	Conversion rate
Gates [42] Systematic review	All stages	Tube thoracostomy = 611	N/A	-	16.4	-	75%	25%	-	-
		Primary fibrinolytic = 83	N/A	-	18.9	-	-	-	-	-
		Thoracotomy = 226	-	-	9.9	-	-	-	-	-
		VATS = 449	-	-	10.5	-	-	-	-	-
Avansino [43] Meta-analysis	All stages	Non-operative = 3418	N/A	10.6 ± 3.4	20.0 ± 8.3	5.6%	76.4%	-	3.3%	N/A
		Primary operative = 363	-	4.4 ± 1.6	10.8 ± 4.8	5%	97.5%	-	0%	1.1%
		Primary fibrinolytic = 64	N/A	-	-	10.6 ± 5.1	12.5%	90.7%	-	0%
Aziz [44] Retrospective	All stages	Thoracostomy = 21	-	-	-	-	-	-	-	N/A
		Thoracostomy, then VATS = 15	-	-	18 ± 3 ^a	-	-	-	-	-
		Primary VATS = 13	-	-	11 ± 0.8 ^a	-	-	-	-	-
Meirer [40] Retrospective	All stages	VATS = 151	-	-	10.1	13.8%	95.4%	4.6%	1.3%	-
Schneider [45] Retrospective	All stages	Thoracocentesis/ thoracostomy = 30	N/A	-	19 ^a	-	62.5%	37.5%	-	N/A
		Secondary VATS = 18	-	7.7	10.3 (15 ^a)	-	-	-	-	6%
		Primary VATS = 31	-	4.2	7.43 (10.5 ^a)	-	-	-	-	-
Li [46] Retrospective	All stages	Non-operative = 953	N/A	-	13.6	8.9%	60.7%	39.3%	1.0%	N/A
		Primary operative = 220	-	-	9.8	8.6%	94.5%	5.5%	0%	-
Shah [47] Retrospective	All stages	Thoracostomy (714)	-	-	10 ^b	-	-	-	-	N/A
		VATS (50)	-	-	7 ^b	-	-	-	-	-
Bishay [48] Retrospective	All stages	VATS = 114	90 ^b	4 ^b	7 ^b	6%	91%	2.6%	0%	4.4%
Carter [49] Retrospective	All stages	Antibiotics = 95	-	-	7.0 ± 3.5 ^a	0%	99.0%	1.1%	0%	-
		Drainage procedures = 87	-	-	11.0 ± 4.0 ^a	6.9%	-	-	0%	-
Grisaru-Soen [50] Retrospective	All stages	Thoracostomy = 20	-	-	14.08 ^a	-	-	-	0%	N/A
		Thoracostomy + fibrinolysis = 16	-	-	15.9 ^a	-	-	-	0%	N/A
		VATS = 11	-	-	14.2 ^a	-	-	-	0%	-
Gasior [51] Retrospective	All stages	Fibrinolysis = 102	N/A	-	7.2 ± 3.2	0%	84.3%	15.7%	0%	N/A
Sonnappa [54] Prospective RCT	All stages	Fibrinolytics = 30	N/A	-	6 ^b	0%	82.1%	17.9%	0%	N/A
		VATS = 30	-	-	6 ^b	0%	83.4%	3.3%	0%	13.3%
St Peter [55] Prospective RCT	All stages	Fibrinolytics = 18	N/A	-	6.8 ± 2.9	0%	83.4%	16.6%	0%	N/A
		VATS = 18	-	-	6.9 ± 3.7	11.1%	100%	0%	0%	-
Kurt [56] Prospective RCT	All stages	Thoracostomy ± fibrinolytic = 8	N/A	9.6 ± 5.5	13.3 ± 7.2	0%	100%	37.5%	0%	N/A
		VATS = 10	47.4 ± 14.6	2.8 ± 0.6	5.8 ± 2.8	0%	100%	0%	0%	0%

^aTotal hospital length of stay.^bMedian length of stay.

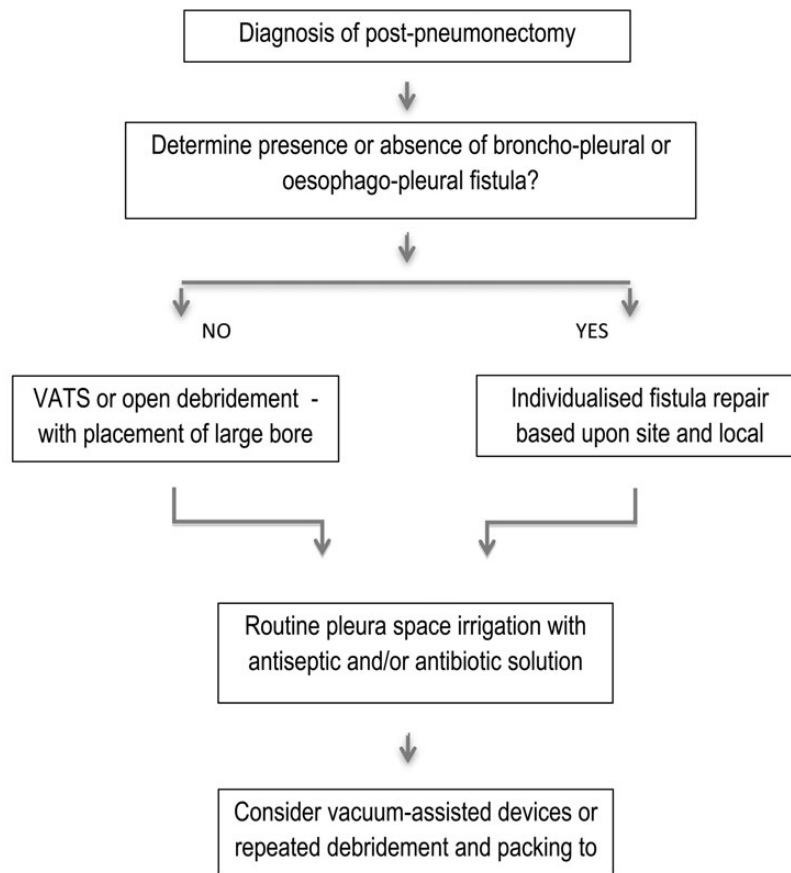
situations. This suggests that an open surgical approach may be more effective than minimally invasive options in treating patients with PPE [65] (Fig. 3).

The management of PPE ranges from minimally invasive surgical techniques such as VATS debridement to fenestration to extensive open procedures involving myoplastic and thoracoplastic techniques. Operative approach is largely guided by the presence or absence of a bronchopleural fistula (BPF), which requires more aggressive surgical intervention. A BPF is found in >80% of patients [65]. The surgical principles include control of pleural space infection by drainage, debridement or by space obliteration and—in case of a fistula—closure of the BPF with a vascularized flap. Control of pleural space infection has been achieved by different techniques, such as pleural drainage lavage, thoracotomy and removal of necrotic tissue associated with open pleural packing for many weeks followed by obliteration of the empyema space

with antibiotic fluid or muscle, or pleural space irrigation followed by obliteration of the pleural space with an antibiotic solution [65]. Published series of PPE often report a mixed cohort of patients with or without fistulae, with many institutional reviews involving the sequential use of interventions according to local practice. This heterogeneity of the existing literature makes detailed comparison of interventions challenging [65].

Thoracostomy and open debridement

In 1979, Goldstraw [66] reported a series of PPEs managed by fenestration, based on previous techniques described by Eloesser [67] and Clagett and Geraci [68]. Fenestration was performed under general anaesthesia, opening the middle third of the previous thoracotomy wound and removing 6–8 cm of the underlying rib



SURGICAL MANAGEMENT OF POST-PNEUMONECTOMY EMPYEMA	
(1)	Uncomplicated post-pneumonectomy empyema (without bronchopleural or oesophagopleural fistula) can be effectively managed with minimally invasive techniques, including fenestration, pleural space irrigation and VATS debridement. Class IIa Level B
(2)	Post-pneumonectomy empyema associated with bronchopleural or oesophagopleural fistula can be effectively managed with individualised open surgical techniques, including direct repair, myoplastic and thoracoplastic techniques. Class IIa Level C
(3)	Intra-thoracic vacuum-assisted closure (VAC) may be considered as an adjunct to the standard treatment. Class IIb Level C

Figure 3: Management of post-pneumonectomy empyema.

and up to three of the adjacent ribs; the skin edges were then sutured to the parietal pleura to create a skin-lined fenestra. The success rate of this series was 77% in keeping with earlier reports detailing fenestration for PPE [68–70]. Further series have confirmed the high success rate (81%); however, they have also highlighted a high morbidity (55%) and mortality (7.1%) associated with the procedure [71] and demonstrated a benefit of early intervention [72]. Goldstraw and colleagues later reported a second series detailing the management of simple PPE with rib resection, tube thoracostomy and irrigation with good success rates,

Video-assisted thoracoscopic surgical debridement

Over the past decade, the new techniques have been introduced for the management of PPE with the continuing aim of reducing the associated morbidity and mortality. VATS debridement has been shown to be effective in the management of PPE (in the absence of BPF or in the presence of microfistula) with good success rates and low associated morbidity or mortality [73, 74].

Thoracoplasty

Thoracoplasty is rarely indicated nowadays, but this does not imply that the procedure should be avoided, especially as less extensive thoracoplastic procedures are possible. Complete space obliteration may be achieved by combining a thoracoplasty confined to a few rib segments and intrathoracic-restricted muscle flap transposition. The disadvantages of thoracoplasty are progressive scoliosis, chronic postoperative pain and ‘mutilating’ cosmetic appearance.

Vacuum-assisted closure

A search for evidence was performed to investigate whether vacuum-assisted closure (VAC) therapy could increase the speed of recovery in patients with an open wound after lung resection. This search is fully documented in the *ICVTS* [75]. All papers were retrospective and included a total of 69 patients treated with intrathoracic VAC. The technique involves the packing of the intrathoracic cavity with polyurethane foam (the mediastinum and the bronchus can be covered using polyvinyl alcohol foam) and application of a negative pressure of ~ -25 to -75 mmHg, which is adjusted depending on the presence or absence of signs of mediastinal traction. The pressure can be gradually decreased to -125 mmHg over time, with regular VAC changes every 2–5 days. One cohort study reported a significantly shorter duration of open window thoracostomy in those managed with VAC (39 ± 17 days) compared with those managed without VAC (933 ± 1422 days) [74]. A second study reported the median length of VAC treatment as 22 days (range 6–66 days) [76]. Interestingly, Groetzner *et al.* [77] reported the safe use of VAC in patients with BPF after covering the bronchus stump with an intrathoracic muscle flap. This accumulating evidence, though limited, suggests that VAC as an adjunct to the standard treatment can potentially alleviate the morbidity and decrease hospital stay in patients with empyema after lung resection.

Direct bronchopleural fistula repair

In contrast, Gharagozloo *et al.* [78] reported a 100% success rate for patients with PPE and BPF managed with direct repair and pleural space irrigation, followed by obliteration of the space with an antibiotic solution. The mean hospital stay was 12.9 days, and

there was no recurrence of the empyema at the 1-year follow-up. The pedicled greater omentum or a pedicled diaphragmatic muscle flap can be used to buttress the bronchial stump.

Muscle interposition

Myoplasty has a dual role either in the direct closure of BPF or as a secondary process due to pleural space obliteration. Cases complicated by fistulae required complex individualized surgery [79]. This was reinforced in two further series, which demonstrated superior success rates with more radical approaches involving myoplasty and thoracoplasty [80, 81]. Vast majority of reports favour the use of extrathoracic muscle flaps to cover the fistula (latissimus dorsi or part of it, pectoralis major, serratus anterior, trapezius and the rhomboid muscles, depending on the location of the space to be obliterated).

There is general consensus that myoplasty should be performed in a clean environment, as in the presence of gross sepsis, a failure rate of 25% has been reported.

Accelerated regimen

In 2008, Schneiter reported a series of 75 patients managed with an accelerated regimen, of thoracotomy with radical debridement followed by packing with povidone-iodine dressings, repeated every second day. Any BPF was repaired with direct closure and/or reinforcement with muscle flap/omental patch. The group reported an 86.7% success rate and a mortality rate of 1.3%. Patients returned to theatre an average of 3 times and the chest definitively closed in 94.6% within 8 days [74].

Apart from the disadvantages of repeated surgical and general anaesthesia sessions, the authors report the following benefits: between debridements there are no painful dressing changes in the ward; (because the chest is closed and is water- and airtight) respiratory mechanics are not impaired; patients also remain mobile and profit from physiotherapy; the procedure greatly improves independent bodily hygiene and spares patients the burden of an open chest wound. In some cases, it might have been possible to achieve successful healing with fewer surgical interventions.

Summary

In summary, the management of PPE is greatly determined by the presence or absence of associated fistulae. In simple PPE with no associated fistulae, minimally invasive methods such as VATS debridement or pleural space irrigation via large bore tube thoracostomy or fenestration are associated with good success rates. Complex empyema spaces associated with fistulae require complex individualized surgical strategies, which are dependent upon individual patient characteristics and different local practice (Table 4).

Conflict of interest: none declared.

REFERENCES

- [1] Ferguson AD, Prescott RJ, Selkon JB, Watson D, Swinburn CR. The clinical course and management of thoracic empyema. *QJM* 1996;89:285–9.
- [2] Finley C, Clifton J, Fitzgerald JM, Yee J. Empyema: an increasing concern in Canada. *Can Respir J* 2008;15:85–9.

- [3] Davies HE, Davies RJ, Davies CW. Management of pleural infection in adults: British Thoracic Society Pleural Disease Guideline 2010. *Thorax* 2010;65(Suppl 2):ii41–53.
- [4] Dunning J, Prendergast B, Mackway-Jones K. Towards evidence-based medicine in cardiothoracic surgery: best BETS. *Interact CardioVasc Thorac Surg* 2003;2:405–9.
- [5] Kolh P, Wijns W, Danchin N, Di Mario C, Falk V, Folliguet T *et al.* Guidelines on myocardial revascularization. *Eur J Cardiothorac Surg* 2010;38(Suppl): S1–S52.
- [6] Chambers A, Routledge T, Dunning J, Scarci M. Is video-assisted thoracoscopic surgical decortication superior to open surgery in the management of adults with primary empyema? *Interact CardioVasc Thorac Surg* 2010; 11:171–7.
- [7] Mandal AK, Thadepalli H, Chettipally U. Outcome of primary empyema thoracis: therapeutic and microbiologic aspects. *Ann Thorac Surg* 1998;66: 1782–6.
- [8] Bilgin M, Akcali Y, Oguzkaya F. Benefits of early aggressive management of empyema thoracis. *ANZ J Surg* 2006;76:120–2.
- [9] Muhammad MI. Management of complicated parapneumonic effusion and empyema using different treatment modalities. *Asian Cardiovasc Thorac Ann* 2012;20:177–81.
- [10] Cardillo G, Carleo F, Carbone L, Di Martino M, Salvadori L, Petrella L *et al.* Chronic postpneumonic pleural empyema: comparative merits of thoracoscopic versus open decortication. *Eur J Cardiothorac Surg* 2009;36:914–8.
- [11] Chan DT, Sihoe AD, Chan S, Tsang DS, Fang B, Lee TW *et al.* Surgical treatment for empyema thoracis: is video-assisted thoracic surgery 'better' than thoracotomy? *Ann Thorac Surg* 2007;84:225–31.
- [12] Tong BC, Hanna J, Toloza EM, Onaitis MW, D'Amico TA, Harpole DH *et al.* Outcomes of video-assisted thoracoscopic decortication. *Ann Thorac Surg* 2010;89:220–5.
- [13] Casali C, Storelli ES, Di Prima E, Morandi U. Long-term functional results after surgical treatment of parapneumonic thoracic empyema. *Interact CardioVasc Thorac Surg* 2009;9:74–8.
- [14] Angelillo Mackinlay TA, Lyons GA, Chimondeguy DJ, Piedras MA, Angaramo G, Emery J. VATS debridement versus thoracotomy in the treatment of loculated postpneumonia empyema. *Ann Thorac Surg* 1996;61: 1626–30.
- [15] Marks DJ, Fisk MD, Koo CY, Pavlou M, Peck L, Lee SF *et al.* Thoracic empyema: a 12-year study from a UK tertiary cardiothoracic referral centre. *PLoS One* 2012;7:e30074.
- [16] Podbielski FJ, Maniar HS, Rodriguez HE, Hernan MJ, Vigneswaran WT. Surgical strategy of complex empyema thoracis. *JSLs*. 2000;4:287–90.
- [17] Chung JH, Lee SH, Kim KT, Jung JS, Son HS, Sun K. Optimal timing of thoracoscopic drainage and decortication for empyema. *Ann Thorac Surg* 2014;97: 224–9.
- [18] Lardinois D, Gock M, Pezzetta E, Buchli C, Furrer M, Ris HB. Delayed referral and gram-negative organisms increase the conversion thoracotomy rate in patients undergoing video-assisted thoracoscopic surgery for empyema. *Ann Thorac Surg* 2005;79:1851–6.
- [19] Shahin Y, Duffy J, Beggs D, Black E, Majewski A. Surgical management of primary empyema of the pleural cavity: outcome of 81 patients. *Interact CardioVasc Thorac Surg* 2010;10:565–7.
- [20] Waller DA, Rengarajan A. Thoracoscopic decortication: a role for video-assisted surgery in chronic postpneumonic pleural empyema. *Ann Thorac Surg* 2001;71:1813–6.
- [21] Storm HK, Krasnik M, Bang K, Frimodt-Moller N. Treatment of pleural empyema secondary to pneumonia: thoracocentesis regimen versus tube drainage. *Thorax* 1992;47:821–4.
- [22] Waller DA, Rengarajan A, Nicholson FHG, Rajesh PB. Delayed referral reduces the success of video-assisted thoracoscopic debridement for post-pneumonic empyema. *Respir Med* 2001;95:836–40.
- [23] Roberts JR. Minimally invasive surgery in the treatment of empyema: intraoperative decision making. *Ann Thorac Surg* 2003;76:225–30.
- [24] Chapman SJ, Davies RJ. The management of pleural space infections. *Respirology* 2004;9:4–11.
- [25] Stefani A, Aramini B, Della Casa G, Ligabue G, Kaleci S, Casali C *et al.* Preoperative predictors of successful surgical treatment in the management of parapneumonic empyema. *Ann Thorac Surg* 2013;96:1812–9.
- [26] Solaini L, Prusciano F, Bagioni P. Video-assisted thoracic surgery in the treatment of pleural empyema. *Surg Endosc* 2007;21:280–4.
- [27] Drain AJ, Ferguson JI, Sayeed R, Wilkinson S, Ritchie A. Definitive management of advanced empyema by two-window video-assisted surgery. *Asian Cardiovasc Thorac Ann* 2007;15:238–9.
- [28] Luh SP, Chou MC, Wang LS, Chen JY, Tsai TP. Video-assisted thoracoscopic surgery in the treatment of complicated parapneumonic effusions or empyemas: outcome of 234 patients. *Chest* 2005;127:1427–32.
- [29] Davies RJ, Traill ZC, Gleeson FV. Randomised controlled trial of intrapleural streptokinase in community acquired pleural infection. *Thorax* 1997;52: 416–21.
- [30] Bouros D, Schiza S, Tzanakis N, Chalkiadakis G, Drositis J, Siafakas N. Intrapleural urokinase versus normal saline in the treatment of complicated parapneumonic effusions and empyema: a randomized, double-blind study. *Am J Respir Crit Care Med* 1999;159:37–42.
- [31] Tuncozgun B, Ustunsoy H, Sivrikoz MC, Dikensoy O, Topal M, Sanli M *et al.* Intrapleural urokinase in the management of parapneumonic empyema: a randomised controlled trial. *Int J Clin Pract* 2001;55:658–60.
- [32] Talib SH, Verma GR, Arshad M, Tayade BO, Rafeeqe A. Utility of intrapleural streptokinase in management of chronic empyemas. *J Assoc Phys India* 2003;51:464–8.
- [33] Diacon AH, Theron J, Schuurmans MM, Van de Wal BW, Bolliger CT. Intrapleural streptokinase for empyema and complicated parapneumonic effusions. *Am J Respir Crit Care Med* 2004;170:49–53.
- [34] Misthos P, Sepsas E, Konstantinou M, Athanassiadi K, Skottis I, Lioulias A. Early use of intrapleural fibrinolytics in the management of empyema: a prospective study. *Eur J Cardiothorac Surg* 2005;28:599–603.
- [35] Maskell NA, Davies CWH, Nunn AJ, Hedley EL, Gleeson FV, Miller R *et al.* U.K. controlled trial of intrapleural streptokinase for pleural infection. *N Engl J Med* 2005;352:865–74.
- [36] Tokuda Y, Matsushima D, Stein GH, Miyagi S. Intrapleural fibrinolytic agents for empyema and complicated parapneumonic effusions: a meta-analysis. *Chest* 2006;129:783–90.
- [37] Rahman NM, Maskell NA, West A, Teoh R, Arnold A, Mackinlay C *et al.* Intrapleural use of tissue plasminogen activator and DNase in pleural infection. *N Engl J Med* 2011;365:518–26.
- [38] Wait MA, Sharma S, Hohn J, Dal Nogare A. A randomized trial of empyema therapy. *Chest* 1997;111:1548–51.
- [39] Petrakis IE, Kogerakis NE, Drositis IE, Lasithiotakis KG, Bouros D, Chalkiadakis GE. Video-assisted thoracoscopic surgery for thoracic empyema: primarily, or after fibrinolytic failure? *Am J Surg* 2004;187:471–4.
- [40] Kho P, Karunanantham J, Leung M, Lim E. Debridement alone without decortication can achieve lung re-expansion in patients with empyema: an observational study. *Interact CardioVasc Thorac Surg* 2011;12:724–7.
- [41] Kim BY, Oh BS, Jang WC, Min YI, Park YK, Park JC. Video-assisted thoracoscopic decortication for management of postpneumonic pleural empyema. *Am J Surg* 2004;188:321–4.
- [42] Striffeler H, Gugger M, Im Hof V, Cerny A, Furrer M, Ris HB. Video-assisted thoracoscopic surgery for fibrinopurulent pleural empyema in 67 patients. *Ann Thorac Surg* 1998;65:319–23.
- [43] Lawrence DR, Ohri SK, Moxon RE, Townsend ER, Fountain SW. Thoracoscopic debridement of empyema thoracis. *Ann Thorac Surg* 1997; 64:1448–50.
- [44] Landreneau RJ, Keenan RJ, Hazelrigg SR, Mack MJ, Naunheim KS. Thoracoscopy for empyema and hemothorax. *Chest* 1996;109:18–24.
- [45] Pezzella AT, Fang W. Surgical aspects of thoracic tuberculosis: a contemporary review. *Curr Probl Surg* 2008;45:715.
- [46] Dewan RK. Surgery for pulmonary tuberculosis. A 15-year experience. *Eur J Cardiothorac Surg* 2010;37:473–7.
- [47] Scarci M, Zahid I, Bille A, Routledge T. Is video-assisted thoracoscopic surgery the best treatment for paediatric pleural empyema? *Interact CardioVasc Thorac Surg* 2011;13:70–6.
- [48] Sakran W, Ababseh Zel D, Miron D, Koren A. Thoracic empyema in children: clinical presentation, microbiology analysis and therapeutic options. *J Infect Chemother* 2014;20:262–5.
- [49] Gates RL, Caniano DA, Hayes JR, Arca MJ. Does VATS provide optimal treatment of empyema in children? A systematic review. *J Pediatr Surg* 2004;39:381–6.
- [50] Avansino JR, Goldman B, Sawin RS, Flum DR. Primary operative versus nonoperative therapy for pediatric empyema: a meta-analysis. *Pediatrics* 2005;115:1652–9.
- [51] Aziz A, Healey JM, Qureshi F, Kane TD, Kurland G, Green M *et al.* Comparative analysis of chest tube thoracostomy and video-assisted thoracoscopic surgery in empyema and parapneumonic effusion associated with pneumonia in children. *Surg Infect (Larchmt)* 2008;9:317–23.
- [52] Meier AH, Hess CB, Cilley RE. Complications and treatment failures of video-assisted thoracoscopic debridement for pediatric empyema. *Pediatr Surg Int* 2010;26:367–71.
- [53] Schneider CR, Gauderer MW, Blackhurst D, Chandler JC, Abrams RS. Video-assisted thoracoscopic surgery as a primary intervention in pediatric parapneumonic effusion and empyema. *Am Surg* 2010;76:957–61.
- [54] Li ST, Gates RL. Primary operative management for pediatric empyema: decreases in hospital length of stay and charges in a national sample. *Arch Pediatr Adolesc Med* 2008;162:44–8.

- [55] Shah SS, Ten Have TR, Metlay JP. Costs of treating children with complicated pneumonia: a comparison of primary video-assisted thoracoscopic surgery and chest tube placement. *Pediatr Pulmonol* 2010;45:71–7.
- [56] Bishay M, Short M, Shah K, Nagraj S, Arul S, Parikh D *et al.* Efficacy of video-assisted thoracoscopic surgery in managing childhood empyema: a large single-centre study. *J Pediatr Surg* 2009;44:337–42.
- [57] Carter E, Waldhausen J, Zhang W, Hoffman L, Redding G. Management of children with empyema: pleural drainage is not always necessary. *Pediatr Pulmonol* 2010;45:475–80.
- [58] Grisaru-Soen G, Eisenstadt M, Paret G, Schwartz D, Keller N, Nagar H *et al.* Pediatric parapneumonic empyema: risk factors, clinical characteristics, microbiology, and management. *Pediatr Emerg Care* 2013;29:425–9.
- [59] Gasior AC, Knott EM, Sharp SW, Ostlie DJ, Holcomb GW III, St Peter SD. Experience with an evidence-based protocol using fibrinolysis as first line treatment for empyema in children. *J Pediatr Surg* 2013;48:1312–5.
- [60] Paraskakis E, Vergadi E, Chatzimichael A, Bouras D. Current evidence for the management of paediatric parapneumonic effusions. *Curr Med Res Opin* 2012;28:1179–92.
- [61] Mahant S, Cohen E, Weinstein M, Wadhwa A. Video-assisted thoracoscopic surgery vs chest drain with fibrinolytics for the treatment of pleural empyema in children: a systematic review of randomized controlled trials. *Arch Pediatr Adolesc Med* 2010;164:201–3.
- [62] Sonnappa S, Cohen G, Owens CM, van Doorn C, Cairns J, Stanojevic S *et al.* Comparison of urokinase and video-assisted thoracoscopic surgery for treatment of childhood empyema. *Am J Respir Crit Care Med* 2006;174:221–7.
- [63] St Peter SD, Tsao K, Spilde TL, Keckler SJ, Harrison C, Jackson MA *et al.* Thoracoscopic decortication vs tube thoracostomy with fibrinolysis for empyema in children: a prospective, randomized trial. *J Pediatr Surg* 2009;44:106–11; discussion 111.
- [64] Kurt BA, Winterhalter KM, Connors RH, Betz BW, Winters JW. Therapy of parapneumonic effusions in children: video-assisted thoracoscopic surgery versus conventional thoracostomy drainage. *Pediatrics* 2006;118:e547–53.
- [65] Zahid I, Routledge T, Bille A, Scarci M. What is the best treatment of post-pneumonectomy empyema? *Interact CardioVasc Thorac Surg* 2011;12:260–4.
- [66] Goldstraw P. Treatment of postpneumonectomy empyema: the case for fenestration. *Thorax* 1979;34:740–5.
- [67] Eloesser L. An operation for tuberculous empyema. *Surg Gynaecol Obstet* 1935;60:1096–7.
- [68] Clagett OT, Geraci JE. A procedure for the management of postpneumonectomy empyema. *J Thorac Cardiovasc Surg* 1963;45:141–5.
- [69] Adler RH, Plaut ME. Postpneumonectomy empyema. *Surgery* 1972;71:210–4.
- [70] Conklin WS. Postpneumonectomy empyema, single-stage operative treatment. *J Thorac Cardiovasc Surg* 1968;55:634–7.
- [71] Zaheer S, Allen MS, Cassivi SD, Nichols FC III, Johnson CH, Deschamps C *et al.* Postpneumonectomy empyema: results after the Clagett procedure. *Ann Thorac Surg* 2006;82:279–86; discussion 286–277.
- [72] Massera F, Robustellini M, Pona CD, Rossi G, Rizzi A, Rocco G. Predictors of successful closure of open window thoracostomy for postpneumonectomy empyema. *Ann Thorac Surg* 2006;82:288–92.
- [73] Gossot D, Stern JB, Galetta D, Debrosse D, Girard P, Caliandro R *et al.* Thoracoscopic management of postpneumonectomy empyema. *Ann Thorac Surg* 2004;78:273–6.
- [74] Ng T, Ryder BA, Maziak DE, Shamji FM. Treatment of postpneumonectomy empyema with debridement followed by continuous antibiotic irrigation. *J Am Coll Surg* 2008;206:1178–83.
- [75] Haghshenas-kashani A, Rahnavardi M, Yan TD, McCaughan BC. Intrathoracic application of a vacuum-assisted closure device in managing pleural space infection after lung resection: is it an option? *Interact CardioVasc Thorac Surg* 2011;13:168–74.
- [76] Groetzner J, Holzer M, Stockhausen D, Tchashin I, Altmayer M, Graba M *et al.* Intrathoracic application of vacuum wound therapy following thoracic surgery. *Thorac Cardiovasc Surg* 2009;57:417–20.
- [77] Saadi A, Perentes JY, Gonzalez M, Tempia-Caliera A, Demartines N, Ris HB *et al.* The intrathoracic vacuum assisted closure (VAC) device as tool to control thoracic sepsis. In: 17th European Conference on General Thoracic Surgery 2009, p. S27. European Association for Cardio-Thoracic Surgery, Krakow, Poland.
- [78] Gharagozloo F, Trachiotis G, Wolfe A, DuBree KJ, Cox JL. Pleural space irrigation and modified Clagett procedure for the treatment of early post-pneumonectomy empyema. *J Thorac Cardiovasc Surg* 1998;116:943–8.
- [79] Wong PS, Goldstraw P. Post-pneumonectomy empyema. *Eur J Cardiothorac Surg* 1994;8:345–9; discussion 349–350.
- [80] Jadczyk E. Postpneumonectomy empyema. *Eur J Cardiothorac Surg* 1998;14:123–6.
- [81] Kacprzak G, Marciniak M, Addae-Boateng E, Kolodziej J, Pawelczyk K. Causes and management of postpneumonectomy empyemas: our experience. *Eur J Cardiothorac Surg* 2004;26:498–502.

European Journal of Cardio-Thoracic Surgery 48 (2015) 653–654
doi:10.1093/ejcts/ezv290 Advance Access publication 7 September 2015

EDITORIAL COMMENT

Cite this article as: Mathisen DJ. Searching for answers!. *Eur J Cardiothorac Surg* 2015;48:653–4.

Searching for answers!

Douglas J. Mathisen*

Department of Thoracic Surgery, Massachusetts General Hospital, Boston, MA, USA

* Corresponding author. Department of Thoracic Surgery, Massachusetts General Hospital, 55 Fruit Street, Blake 1570, Boston, MA 02114, USA.
Tel: +1-617-7266826; fax: +1-617-7267667; e-mail: dmathisen@partners.org (D.J. Mathisen).

Keywords: Empyema • Pleural infection • Lung

This is an editorial comment on the EACTS expert consensus statement for surgical management of pleural empyema, published in this issue of the journal [1].

Empyema is a major problem worldwide. It presents in developed and undeveloped countries alike, countries with unlimited

resources and countries with minimal resources to manage this problem, respectively. Doctors today taking care of patients with the spectrum of presentations of empyema need guidance regarding therapeutic options and when they are appropriate. Ideally, randomized prospective studies would answer many of the questions