

Eagle's Syndrome- Elongated Styloid Process

¹Dr. Surekha Teki, ²Dr. D. Asha latha, ³Dr. Srihari babu,
⁴Dr. K. Lakshmi kumari, ⁵Dr. G. Siva Prasad, ⁶Dr. A. Vasanthi.
Department Of Anatomy, Andhra Medical College, Visakhapatnam.

Abstract: Eagle's syndrome is a condition in which an elongated styloid process or calcified stylohyoid ligament causes occasional pain in the neck, a feeling of a foreign body (in the pharynx) or some other form of retromandibular-cervical pain. In adults the styloid process is approximately 25 mm long with a tip which is located between the external and internal carotid arteries, lateral to the pharyngeal wall and the tonsillar fossa. Ossification of the stylohyoid and stylo-mandibular ligament causes prolongation of the styloid process and clinical symptoms.

Radiographic finding may show several possible variations: elongated, pseudoarticulated and segmented styloid process, and according to the calcification: peripheral, partial, complete or nodular type calcification. Treatment is primarily surgical. The physician's knowledge of possible clinical variations and diverse symptomatology is important.

Key words: Elongated styloid process, Eagle's syndrome, tonsillar fossa, stylo-hyoid ligament, stylo-mandibular ligament.

I. Introduction

The styloid process is a bony projection, situated immediately anterior to the stylo-mastoid foramen, averaging from 20 to 25 mm in length. It is of cylindrical form and projects downwards from the inferior surface of the temporal bone towards the front, downwards and medially narrowing towards the tip. The location of the tip is particularly important, which is situated between the internal and external carotid arteries, laterally from the pharyngeal wall and immediately behind the tonsil fossa. Three muscles and two ligaments are attached to the styloid process. Stylopharyngeus attaches medially and from the posterior side next to the base of the process, stylohyoid from the posterior side and laterally on the central part of the process and styloglossus which starts from the anterior part of the process immediately next to the tip. The muscles are innervated by glossopharyngeal, facial and hypoglossal nerve. The stylohyoid ligament extends from the tip of the styloid process up to the lesser cornu of the hyoid bone and the stylo-mandibular ligament, which commences under the attachment of styloglossus muscle and ends on the angle of mandible.

Eagle's syndrome Synonyms: Elongated styloid process syndrome, Styloid process and carotid artery syndrome, Stylohyoid syndrome, Styloid process neuralgia, Stylalgia. In 1937 Eagle first presented two cases with symptomatology of elongated styloid process in an article entitled "Elongated Styloid Processes. Hence the name eagle's syndrome.

II. Case Report

During our routine osteology demonstration classes for the undergraduate students in the Department of Anatomy, Andhra Medical college, we have come across two dried skulls showing abnormally elongated styloid process. These findings are shown in the figure 1 and figure 2. The details are mentioned in Table 1.

Figure 1: showing elongated styloid process in the skull .

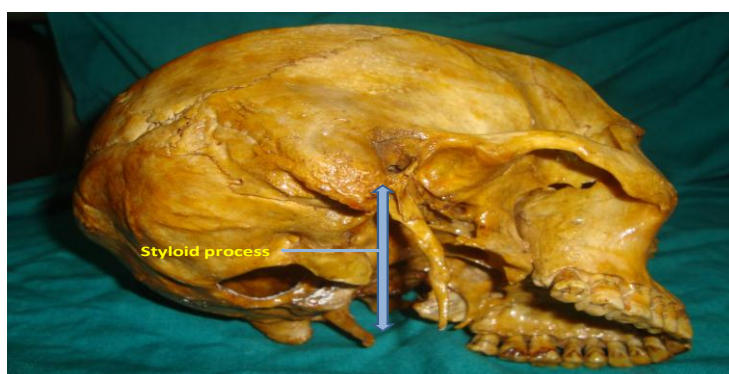


Figure 2: showing elongated styloid process in two skulls.

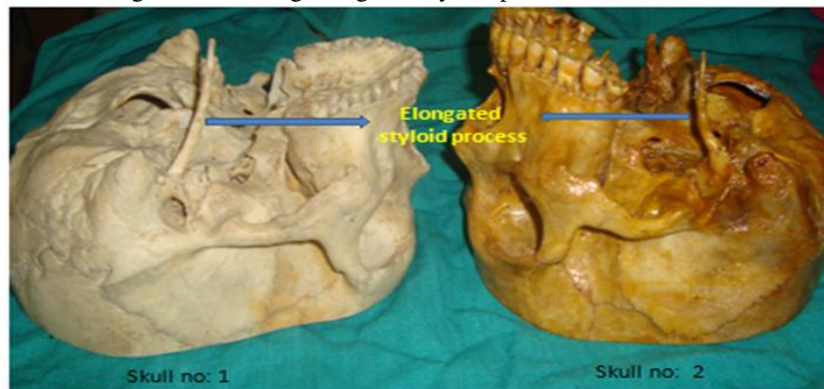


Table 1:

SL.NO	Length on Right side	Length on Left side
Skull no. 1	3.8 cms	7.2 cms
Skull no. 2	6.8 cms	2.5 cms

III. Discussion

Styloid process length ranges from 5 mm to 50 mm. The normal length of the styloid process ranges from 25 mm to 30 mm . Some authors claim that a length between 15.2 mm and 47.7 mm could be considered as normal . Other studies accept that a length of over 30 mm is considered elongated and by others 40 mm . Some rare cases exist with length of 73 mm. Incidence seems to range from 1.4 to 84.4% of population, that's due to great variations in radiological methodology and technique, surgical or anatomic (cadaveric or dry) specimens, ethnic variability and predominance of unilateral to bilateral occurrence. Sometimes a distinct border between apex and stylohyoid ligament is not clearly identifiable. Styloid process elongation can occur unilaterally or bilaterally.

The stylohyoid chain components are derived embryologically from the first and second branchial arches in four distinct segments: tympanohyal, stylohyal, ceratohyal and hypohyal segments. These segments are derived from Reichert's cartilages that ossify in two parts. The styloid process develops from the tympanohyal and stylohyal segments that usually fuse at puberty. The lesser cornu of the hyoid bone arises from the hypohyal segment. Connecting these two structures, the stylohyoid ligament originates from the ceratohyal segment. The styloid process and the stylohyoid ligament have been linked to Eagle's syndrome, which has a symptomatology characterized by the sensation of having a foreign body in the pharynx, causing difficult and painful swallowing and earache. It has also been referred to as styloid syndrome, stylohyoid syndrome, stylalgia, stylohyoid disorder, neuralgia of styloid process, cervicopharyngeal pain syndrome. It can also cause vertigo, tinnitus, dysphonia, carotidynia, pain on turning the head, reduced mandibular opening, and change in voice, hypersalivation, and even alteration in taste . Although 4% of the population is thought to have an elongated styloid, only 4–10% of this group is symptomatic . Frommer observed that the direction and curvature of styloid process were more important than its length in causing symptoms .

In the study of Massey, there were only 11 cases of styloid process having length of more than 4 cm out of 2000 cases studied. Harma gives incidence of 4-7%for elongated styloid process. Elongation was seen four times more in males than females and in 75% of cases the elongation was bilateral. There are many reports of elongated styloid process but all of them have measured only the length. There were no reports of such thick and long process like our case in literature.

The pathophysiological mechanism of symptoms is not very clear. The following theories are proposed

- Traumatic fracture of styloid causing proliferation of granulation tissue, which compresses the adjacent structures.
- Compression of adjacent nerves, glossopharyngeal, lower branch of trigeminal or chorda tympani.
- Stylohyoid insertion tendonitis.
- Irritation of pharyngeal mucosa by direct compression or post tonsillectomy scarring .

IV. Conclusion

The elongation and thickening of styloid process to an extent reported here is very rare. The possible clinical course, causes for thickening and surgical approaches in this case needs to be evaluated.

References:

- [1]. Williams PL. Gray's Anatomy. 38th Ed., London, ELBS with Churchill Livingstone. 1999; 592.
- [2]. Sokler K, Sandev S. New classification of the styloid process length--clinical application on the biological base. Coll Anthropol. 2001; 25: 627-632.
- [3]. Kim E, Hansen K, Frizzi J. Eagle syndrome: case report and review of literature. Ear Nose Throat J. 2008; 87: 631-633.
- [4]. Rodriguez-Vazquez JF, Merida-Velasco JR, Verdugo-Lopez S, Sanchez-Montesinos I, Merida-Velasco JA. Morphogenesis of the second pharyngeal arch cartilage (Reichert's cartilage) in human embryos. J Anat. 2006; 208: 179-189.
- [5]. Restrepo S, Palacios E, Rojas R. Eagle's syndrome - Imaging Clinic. Ear Nose Throat J. Oct 2002.
- [6]. Frommer J. Anatomic variations in the stylohyoid chain and their possible clinical significance. Oral Surg Oral Med Oral Pathol. 1974; 38: 659-667.
- [7]. Massey EW. Facial pain from an elongated styloid process. (Eagles syndrome). South Med J. 1978; 71: 1156-1159.
- [8]. Harma R. Stylalgia: clinical experiences of 52 cases. Acta Otolaryngol. 1966; suppl 224: 149+.
- [9]. Cawich SO, Gardner M, Shetty R, Harding HE. A post mortem study of elongated styloid processes in a Jamaican population. The Internet Journal of Biological Anthropology. 2009; Volume 3: Number 1.