



CASE REPORT

Ectodermal Dysplasia and Anodontia associated with Ring Chromosome 18

¹Shouvik Mandal, ²Nitin N Kadam, ³Sabita M Ram, ⁴Bani B Ganguly, ⁵Vanitha U Shenoy

ABSTRACT

Ectodermal dysplasia (ED) is a heritable condition and represents a multifarious group of diseases comprising different clinical signs and symptoms. The ED occurs as a result of disturbances in the ectoderm of the evolving embryo. Agenesis of teeth or anodontia is also the result of disturbance in this process, which prevents the proliferation of tooth buds. In the present case, an 18-month-old child with history of congenital anomalies (CAs), severely delayed developmental milestones, and mental retardation presented with complete anodontia and ED. The CA included pulmonary stenosis, pulmonary valvar regurgitation, ventricular septal defect (VSD), absence of grips, absence of head-holding capacity, inability to sit, simian crease (R), visual impairment with corectopia, blepharitis, lagophthalmos with cortical visual impairment, telecanthus, hypotrichosis, hypertelorism, high philtrum, high arched palate, degenerated nails, and depressed third toes. Routine karyotyping via peripheral blood culture revealed a ring chromosome 18, which was confirmed *de novo* after parental karyotyping. Although a straightforward association between r(18) and anodontia is yet to be established, it is apparent that anodontia coupled with multiple CA and systemic complications was caused by chromosomal/genetic mutations in the present case, and thus, this report strongly recommends phenotypic and genotypic examination in dental management in such a complex scenario.

Keywords: Anodontia, Ectodermal dysplasia, Karyotyping, Ring chromosome r(18).

How to cite this article: Mandal S, Kadam NN, Ram SM, Ganguly BB, Shenoy VU. Ectodermal Dysplasia and Anodontia associated with Ring Chromosome 18. *J Contemp Dent* 2016;6(3):220-224.

Source of support: Nil

Conflict of interest: None

¹Lecturer, ²Professor, ³Dean, Professor and Head, ^{4,5}Professor and Head

^{1,5}Department of Conservative Dentistry, Mahatma Gandhi Mission's Dental College and Hospital, Navi Mumbai, Maharashtra India

²Department of Pediatrics, Mahatma Gandhi Mission's Dental College and Hospital, Navi Mumbai, Maharashtra, India

³Department of Prosthodontics, Mahatma Gandhi Mission's Dental College and Hospital, Navi Mumbai, Maharashtra, India

⁴MGM Center for Genetic Research and Diagnosis, Mahatma Gandhi Mission's Dental College and Hospital, Navi Mumbai Maharashtra, India

Corresponding Author: Shouvik Mandal, Lecturer, Department of Conservative Dentistry, Mahatma Gandhi Mission's Dental College and Hospital, Navi Mumbai, Maharashtra, India, e-mail: shouvik.dr@gmail.com

INTRODUCTION

Ectodermal dysplasia (ED) refers to an outsized group of heritable conditions in which a minimum of two ectodermal structures fail to grow normally. The tissues primarily reported to be affected are skin, sweat glands, hair, nails, and teeth apart from the possibility of involvement of other organs and parts.¹ The ED is a genetic disorder with different modes of inheritance, which is presented by different clinical and genetic findings.² The condition involves overlapping features, thereby preventing a perfect classification. One of the more common types of ED is X-linked recessive hypohidrotic ED (XLHED), which is also called anhidrotic ED and Christ-Siemens-Touraine syndrome.³ A rare autosomal recessive form is clinically identical to XLHED.⁴ The hydrotic form of ED follows autosomal dominant inheritance.⁴ An autosomal dominant ED was described by Giansanti et al⁵ as "tooth and nail" type, which is also called Witkop syndrome. Expression of ED is seen in both sexes, particularly if there is consanguinity with full expression in males.⁶

The oral manifestations in ED range from minimal to complex patterns. The dentition may be affected by atypical teeth or partial to complete anodontia.⁷ Anodontia, total (complete agenesis) or partial (hypodontia), is usually characterized by the absence of teeth, which may also be associated with other phenotypic abnormalities.¹ Total anodontia may affect either or both deciduous and permanent dentition. Children with a number of missing primary and permanent teeth may have some or all of the signs of a type of ED and should undertake thorough clinical and genetic evaluation.³ Anodontia has been associated with systemic disorders and diagnosed with several syndromes, e.g., oculomandibulodyscephaly, mesoectodermal dysplasia, and ED.⁸ Lack of proliferation and differentiation of ectodermal tissues causes deficient or absence of development of tooth buds and results in anodontia.⁶ It is a relatively common congenital condition with an incidence of ~8%.⁹ Therefore, such dental condition may be given significant diagnostic importance.

The present case report describes ED in an 18-month-old child detected with ring chromosome 18 in association with total anodontia.

CASE REPORT

An 18-month-old Asian male with a history of severely delayed developmental milestones and noisy respiration

(distressed) was referred for karyotyping and genetic counseling to the Department of Genetics, Mahatma Gandhi Mission Hospital, Navi Mumbai, Maharashtra, India. The natal history included that the child was born 1 month preterm to nonconsanguineous parents with 1.2 kg birth weight, cried after 30 minutes, and was kept in an incubator for 10 days.

Medical history revealed major malformations apart from history of fever and pneumonia at 1 month of age, which had required hospitalization and blood transfusion. The child did not have grips, head-holding capacity, sitting capacity, any social development, and had severely deferred age-related milestones with severe mental retardation. The facial appearance of the child included hypotrichosis, hypertelorism, wide and flattened frontonasal bridge, and sparsely scattered straight hairs on scalp and in eyebrows and eyelashes (Fig. 1A). Extraoral examination of the child revealed high philtrum, wide open mouth (Fig. 1A), incompetent lips, protruding tongue (Fig. 1A), drooling saliva, and intraoral examination revealing high arched palate, soft ridges, and complete absence of teeth in the oral cavity at the age of 18 months. The general features, including presence of simian crease (R) (Fig. 1B), dystrophic finger and toenails, shorter and elevated second toe bilaterally, bilateral depressed third toe (Fig. 1C), hypotonia, and hypohidrosis, were noticed. The skin appeared thin, dry, and scaly. The child was dependent on significantly noisy oral breathing.

Medical investigations were scheduled to determine other possible malformations. Echocardiography was done at the age of 1 year, which detected malaligned ventricular septal defect (VSD) with left-to-right shunt, absent pulmonary valve syndrome, moderate pulmonary stenosis, mild pulmonary valvar regurgitation, and aneurysmally dilated pulmonary artery. The child had failure to thrive and airway anomalies due to severe dilated main pulmonary artery (MPA), which caused difficulty in breathing.

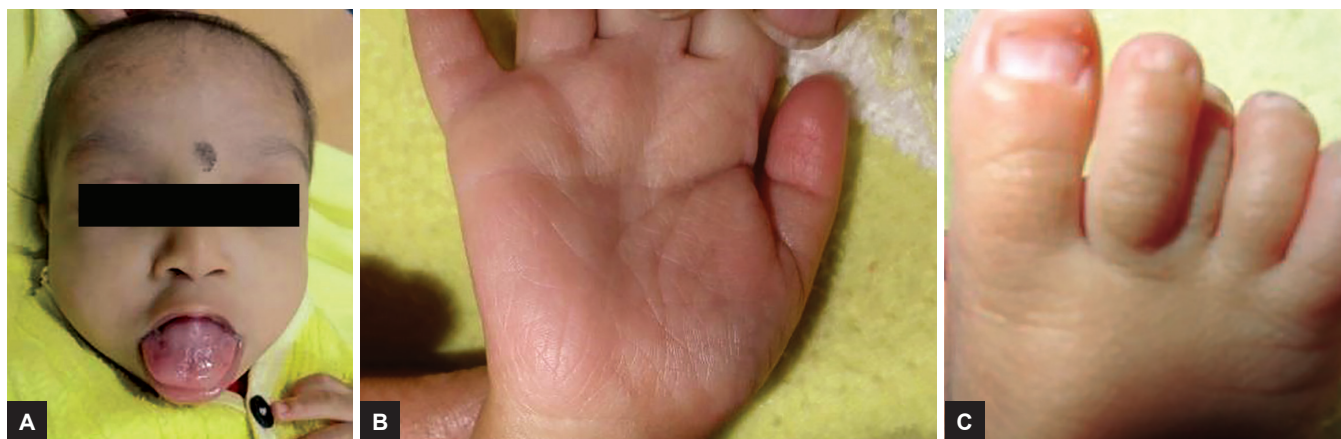Eye examination revealed cortical visual impairment with corectopia, blepharitis, lagophthalmos with cortical visual impairment, telecanthus, and corneal opacity with mild vascular tortuosity. He was unable to respond to any sound. Brainstem evoked response audiometry (BERA) test at this age revealed prolonged latency to waveform V on the right side affecting right auditory pathway.

Genetic investigation using peripheral whole blood was done to check the genomic karyotype of the proband. Phytohemagglutinin (PHA) (Gibco, USA)-stimulated culture in Roswell Park Memorial Institute (RPMI) 1640 medium (Gibco, USA) supplemented with fetal bovine serum (FBS) (Gibco, USA) was carried out following incubation at 37°C for 72 hours. Metaphase chromosome preparation was performed using standard colchicine hypotonic fixation technique.¹⁰ Chromosome analysis following Giemsa (G) banding was carried out following International System for Human Cytogenetic Nomenclature (ISCN).¹¹ Imaging of 50 metaphases with the help of IKAROS software (MetaSystems, Germany) revealed a male karyotype with 46,XY,r(18) (p11.3q23) pattern in all 30 cells evaluated (Fig. 2A).

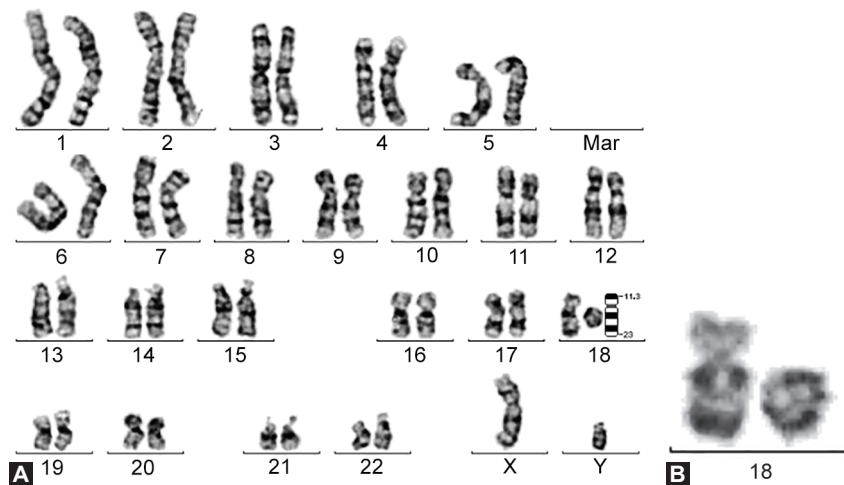
Phenotypic correlation with thorough medical and dental examination and genetic evaluation of the child confirmed the case with ED associated with total anodontia, which could be attributed to the presence of one r(18). Counseling-guided parental karyotyping confirmed *de novo* origin of the rearrangement as health histories and karyotypes were normal for both parents and his 5-year-old sibling.

DISCUSSION

The science of genetics is relatively a new concept in dental management. However, people have apprehended the heritable nature of traits and have used genetics for thousands of years. Advances in genetic tests have allowed important insights into the nature of disease and facilitated



Figs 1A to C: Phenotypic features of the patient: (A) Frontal face with open mouth and protruding tongue; (B) simian crease in right hand; and (C) shorter and elevated second toe and depressed third toe



Figs 2A and B: Karyotype of the proband showing 46,XY,r(18); (A) Full karyotype; and (B) partial karyotype of 18 with ring (on right)

health management in a very comprehensive direction in the present era. The present case has direct association of chromosomal aberration with anodontia and ED.

Ring chromosome 18 [r(18)] is the result of two breaks on two arms followed by rejoining of the two broken ends, which has caused deletion of genetic material from terminal regions of both p (18p p11.31-pter) and q arms (18q23-qter)¹² (Fig. 2B). Thus, the child in the present case had partial monosomy of 18 in both p and q segments. Ring chromosome 18 was first reported in 1964.⁹ R(18) is relatively common among all ring chromosomes and the rate of having typical clinical signs of 18p and 18q syndromes vary depending on the length of the deletion in 18p and 18q.¹³ R(18) causes a wide range of medical and developmental concerns.¹⁴ The phenotypic features of distal 18q- and 18p- also vary greatly because of the variability of the deletion size and breakpoint locations.¹⁵ In general, children with r(18) usually show an unspecific pattern of clinical manifestations in addition to characterized developmental retardation and moderate-to-severe mental retardation and facial dysmorphism. In the present case, the child presented with numerous phenotypic and systemic abnormalities coupled with dental aplasia. There were certain unique and certain overlapping clinical findings, similar to that of another reported case.¹⁶

The deciduous teeth begin to erupt into the oral cavity from 6 months and continue till two and half years of age. The first tooth may erupt as late as 14 months.¹⁷ However, the present case did not have any tooth even at an age as late as 18 months. Therefore, the child with anodontia in conjunction with ED is apparent considering all other findings. The patient was scheduled for orthopantomograph and further imaging for a comprehensive evaluation; however, the child expired of severe respiratory distress before the radiograph and necessary documentation could be completed.

Although association of chromosomal aberrations and oral manifestations has been established,¹⁸ the genetic etiology of anodontia has not been fully elucidated. Genetic and/or epigenetic mutations in ED1 gene at Xq12-q13, including missense, nonsense, and indels, were reported in XLHED and abnormal development of eccrine sweat glands, hair, and hypodontia.¹⁹ R(18) was associated with sparse hair, dry skin, bronchitis, otitis media, and dental caries in a Chinese girl.²⁰ The clinical expression of r(18) varies depending on the amount of genes lost at two ends. Two partial deletions of 19 genes (3.88 Mb, 1 bp to nearly 3,881,000 bp) and 12 genes (4.83 Mb, 73,239,191 bp) in p (p11.31-pter) and q (q23-qter) arms respectively, have been measured in r(18),¹⁹ which revealed heterozygous terminal deficiencies. It is apparent that the deletions of the genes in r(18) are responsible for phenotypic dysmorphism, dental and other systemic disorders, and growth and mental retardation in the present case. Also, immunoglobulin A deficiency is frequently reported in patients with ring chromosome 18 syndrome.²¹

Mutations in TGIF gene at 18p11.31 are associated with brain malformation. Holoprosencephaly with microcephaly, ocular hypotelorism, flat nasal bridge, and single central incisor were reported to be associated with del(18p) (18p11.3-pter) in carriers of r(18) patients. Genotype-phenotype studies have been carried out in people with 18q deletions of various sizes, so that critical areas corresponding to the characteristic clinical symptoms of the 18q deletion syndrome could be demarcated.²² The region from 18q22.3 to q23 has been ascribed to white matter disorders and delayed myelination, growth hormone insufficiency, foot deformities, and congenital aural atresia (CAA). The CAA may vary from a mild abnormality with narrowing of the external auditory canal and hypoplasia of the tympanic membrane and middle ear cavity to entire nonappearance of the middle ear along with anotia, bony

atresia, and hypoplasia of inner ear structures.²³ Anodontia, in the present case, might have been associated with bone atresia caused by TGIF mutation. TSHZ1 at 18q was considered to be the candidate gene for the observed CAA phenotype on the basis of the deletion overlap.¹⁷ Cleft palate has also been tentatively linked to deletions of this gene.²⁴ TCF4 at 18q21.2 has been linked to a condition first described in 1978 called Pitt–Hopkins syndrome.²⁵

The oral and medical examinations, and systemic scanning and genetic investigation have established association of anodontia with constitutional chromosomal aberration. Further research using molecular techniques are essential for delineation of the exact loss of genes that leads to signs and symptoms of the disorder. Conventional karyotyping can give a general idea of the location of the deletion's breakpoint. For precise characterization of gene loss, more specialized tests, such as microarray and/or sequencing analysis would be important.

CONCLUSION

Phenotype and physiological systems are governed by the genetic architecture of one organism. Dentition is defined at the embryonic age as early as 4 weeks after fertilization beginning from ectodermal proliferation. The ED and complete or partial anodontia may have overlapping symptoms and follow autosomal or X-linked transmission. Although a direct genotype–phenotype correlation has not been established yet, some of the isolated cases have indicated association of r(18) with craniofacial dysmorphism and systemic disorders. The present case with r(18) associated with complete anodontia is the first of its kind in dental science. Thus, this case report suggests that genes of chromosome 18 particularly located at terminal regions of p and q arms lost from one 18 could be responsible for ED and anodontia, although exact genes could not be specified by the technology followed for the present investigation. Nevertheless, the present report highlights the importance of genetic correlation of dental anomalies for diagnosis and management, more so for a complete clinical workup.

ACKNOWLEDGMENT

The authors wish to acknowledge Mahatma Gandhi Mission Trust for providing laboratory facility. Authors also acknowledge the consent of the parents of the proband for this reproduction.

REFERENCES

- Rajendran, R. Shafer's textbook of oral pathology. Elsevier India; 2009. p. 805.
- McGrath JA, McMillan JR, Shemanko CS, Runswick SK, Leigh IM, Lane EB, Garrod DR, Eady RA. Mutations in the plakophilin 1 gene result in ectodermal dysplasia/skin fragility syndrome. *Nat Genet* 1997 Oct;17(2):240-244.
- Monreal AW, Zonana J, Ferguson B. Identification of a new splice form of the EDA1 gene permits detection of nearly all X-linked hypohidrotic ectodermal dysplasia mutations. *Am J Hum Genet* 1998 Aug;63(2):380-389.
- McDonald, RE.; Avery, DR.; Dean, JA. Dentistry for the child and adolescent. St. Louis: Mosby; 2004. p. 64.
- Giansanti JS, Long SM, Rankin JL. The "tooth and nail" type of autosomal dominant ectodermal dysplasia. *Oral Surg Oral Med Oral Pathol* 1974 Apr;37(4):576-582.
- Schneider PE. Complete anodontia of the permanent dentition: case report. *Pediatr Dent* 1989 Dec;12(2):112-114.
- Glick, M. Burket's oral medicine. PMPH-USA; 2015. p. 672.
- Gorlin, RJ.; Pindborg, JJ. Syndromes of the head and neck. Vol. 1. New York: McGraw-Hill; 1964. p. 172,298,432.
- Pilo R, Kaffe I, Amir E, Sarnat H. Diagnosis of developmental dental anomalies using panoramic radiographs. *ASDC J Dent Child* 1986 Dec;54(4):267-272.
- Santra M, Talukder G, Sharma A. Comparison of chromosome damage induced by three zinc compounds using human leukocyte culture. *Biol Trace Elem Res* 2000 Winter;78(1-3):113-119.
- Shaffer, LG.; McGowan-Jordan, J.; Schmid, M., editors. ISCN 2013: an international system for human cytogenetic nomenclature. Karger Medical and Scientific Publishers; 2013.
- Gropp A, Jussen A, Offeringer K. Multiple congenital anomalies associated with a partially ring-shaped chromosome probably derived from chromosome No. 18 in man. *Nature* 1964 May;202:829-830.
- Samli H, Özgöz A, İçduygu FM, Hekimler K, Sıvacı Y, İmirzaloğlu N. A case with mosaic ring chromosome 18. *Gazi Med J* 2013 Oct;24(3):90-91.
- Carter E, Heard P, Hasi M, Soileau B, Sebold C, Hale DE, Cody JD. Ring 18 molecular assessment and clinical consequences. *Am J Med Genet Part A* 2015;167A:54-63.
- Heard PL, Carter EM, Crandall AC, Sebold C, Hale DE, Cody JD. High resolution genomic analysis of 18q- using oligo-microarray comparative genomic hybridization (aCGH). *Am J Med Genet A* 2009 Jul 1;149A(7):1431-1437.
- Heydari S, Hassanzadeh F, Hassanzadeh Nazarabadi M. Ring chromosome 18: a case report. *Int J Mol Cell Med* 2014 Fall;3(4):287-289.
- Verma N, Bansal A, Tyagi P, Nashine N, Kulkarni A, Gupta A. Effect of developmental milestones on patterns of teeth eruption. *Int J Sci Stud* 2015;3(5):14-17.
- Patil S, Rao RS, Majumdar B. Chromosomal and multifactorial genetic disorders with oral manifestations. *J Int Oral Health* 2014 Sep;6(5):118-125.
- Vincent MC, Biancalana V, Ginisty D, Mandel JL, Calvas P. Mutational spectrum of the ED1 gene in X-linked hypohidrotic ectodermal dysplasia. *Eur J Hum Genet* 2001 May 1;9(5):355-363.
- Yao H, Yang C, Huang X, Yang L, Zhao W, Yin D, Qin Y, Mu F, Liu L, Tian P, et al. Breakpoints and deleted genes identification of ring chromosome 18 in a Chinese girl by whole-genome low-coverage sequencing: a case report study. *BMC Med Genet* 2016 Jul 22;17(1):49.
- Litzman J, Brysová V, Gaillyová R, Thon V, Pijácková A, Michalová K, Zemanová Z, Lokaj J. Agammaglobulinaemia in a girl with a mosaic of ring 18 chromosome. *J Paediatr Child Health* 1998 Feb 1;34(1):92-94.
- Feenstra I, Vissers LE, Pennings RJ, Nillessen W, Pfundt R, Kunst HP, Admiraal RJ, Veltman JA, van Ravenswaaij-Arts CM,

- Brunner HG, et al. Disruption of teashirt zinc finger homeobox 1 is associated with congenital aural atresia in humans. *Am J Hum Genet* 2011 Dec 9;89(6):813-819.
23. Cremers, CW.; Teunissen, E.; Marres, EH. Classification of congenital aural atresia and results of reconstructive surgery. In: *Pediatric Otology*. Karger Publishers; 1988. p. 9-14.
 24. Cody JD, Sebold C, Heard P, Carter E, Soileau B, Hasi-Zogaj M, Hill A, Rupert D, Perry B, O'Donnell L, et al. Consequences of chromosome 18q deletions. *Am J Med Genet C Semin Med Genet* 2015 Sep 1;169(3):265-280.
 25. Pitt D, Hopkins I. A syndrome of mental retardation, wide mouth and intermittent overbreathing. *Aust Paediatr J* 1978 Sep;14(3):182-184.