

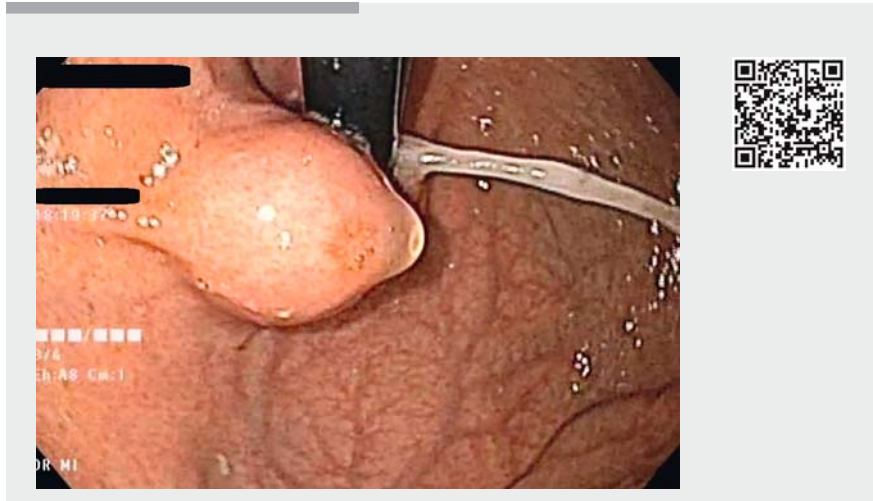Ectopic pancreas mimicking gastrointestinal stromal tumor in the stomach fundus

Ectopic or heterotopic pancreas refers to healthy pancreatic tissue that lacks anatomical, vascular or neural communication with the normal pancreas. However, heterotopic pancreas is seldom considered as a diagnostic hypothesis when symptomatic or when located outside of the gastric antral wall [1]. This case report describes the clinical and paraclinical features of pancreatic heterotopia in the gastric fundus in a previously healthy 25-year-old woman.

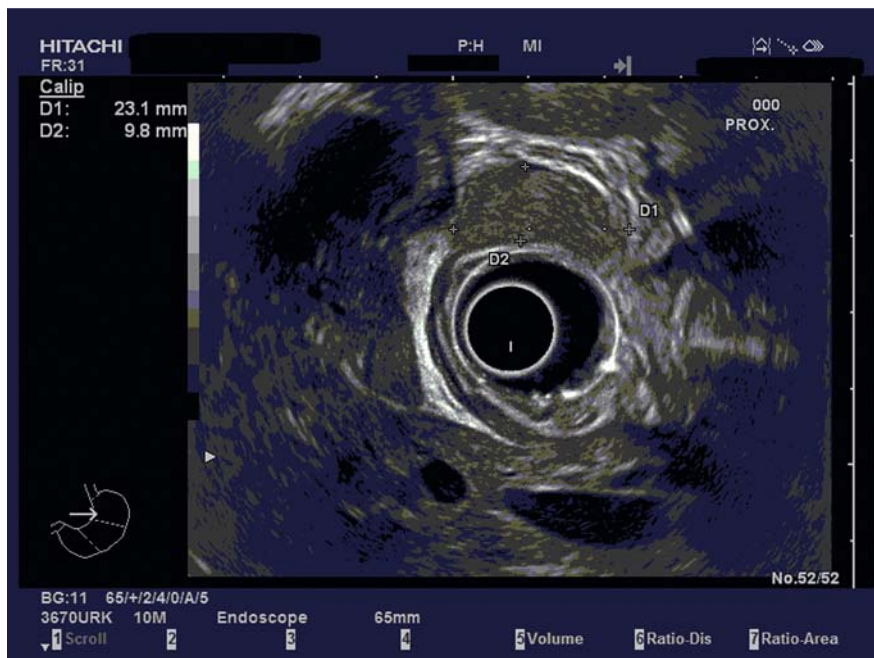
Initially, a gastrointestinal stromal tumor (GIST) was highly suspected because of its endoscopic (location and shape; ▶ **Video 1**), endoscopic ultrasound (emerging layer; ▶ **Fig. 1**, ▶ **Fig. 2**), and computed tomography characteristics; however, the histopathological evaluation revealed pancreatic heterotopia (▶ **Fig. 3**). Although the patient was asymptomatic, we opted for surgical treatment because of the large size of the lesion, the atypical location in a highly vascularized part of the stomach, and the patient's young age.

On postsurgical follow-up, only a small granuloma was found on the suture site, even though the surgery was not curative (R1 with remaining pancreatic tissue on one margin of the resection specimen) (▶ **Fig. 4**). We emphasize the unusual location of the pancreatic heterotopia (gastric fundus – despite up to 95% of cases being found in the antral location), and the layer from which the tissue developed (muscularis propria – which is seen in only 17% of cases) [2]. Moreover, we emphasize the difficulty in making an accurate diagnosis, which can only be obtained after surgery, and the need for regular postoperative follow-up to assess for remaining pancreatic rests, as some studies have shown up to 12.7% malignant transformation in pancreatic rests [3].

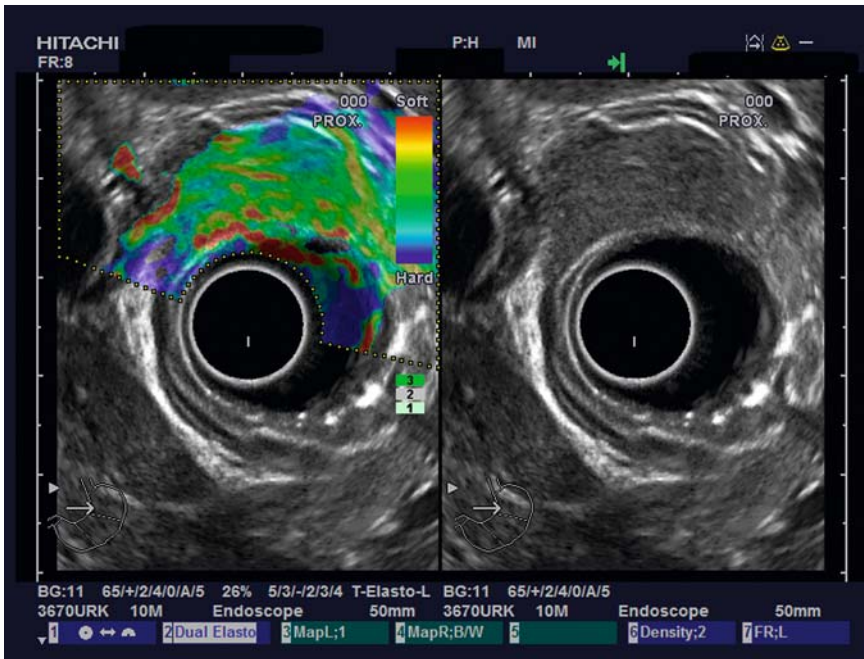
Despite the fact that ectopic pancreas is a rare condition, one must consider the differential diagnosis of extramucosal gastric lesions. Even though endoscopic



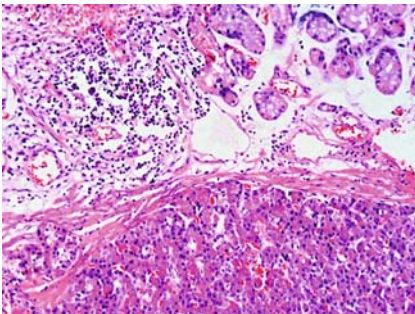
▶ **Video 1** Endoscopic appearance of a submucosal lesion, with central ulceration, in the gastric fundus. Narrow-band imaging revealed regular microvascular and surface patterns, except for the central zone, which had irregular surface and vascular patterns.



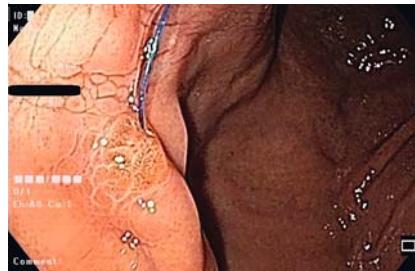▶ **Fig. 1** A 23.1 × 9.8 mm oval lesion, homogeneous, located within the 4th hypoechoic layer, well delineated, and with possible extension of the lesion through the 5th hyperechoic outer layer.



► **Fig. 2** Soft aspect of the lesion shown by elastography scanning.



► **Fig. 3** Histopathological evaluation revealed gastric mucosa with fundic glands and pancreatic tissue beneath the muscularis mucosae fibers (Hematoxylin and eosin, $\times 200$).



► **Fig. 4** Post-resection endoscopic appearance, with mucosal proliferation near the suture site with surgical thread in place, highly suggestive of suture granuloma.

ultrasonography has become an essential tool in diagnosing submucosal masses, sometimes it cannot make a clear distinction between pancreatic rests and GISTs. Preoperative and even intraoperative diagnosis is rare, and surgical excision by minimally invasive approach remains the recommended treatment in symptomatic cases [1, 4].

Endoscopy_UCTN_Code_CCL_1AB_2AD_3AB

Competing interests

None

The authors

Cătălina Diaconu¹, Mihai Ciocîrlan², Mariana Jînga³, Raluca Simona Costache³, Gabriel Constantinescu¹, Mădălina Ilie¹, Mircea Diculescu⁴

- 1 Department of Gastroenterology, Floreasca Clinical Emergency Hospital, Bucharest, Romania
- 2 Department of Gastroenterology, Agripa Ionescu Hospital, Bucharest, Romania
- 3 Department of Gastroenterology, Central Military Emergency University Hospital, Bucharest, Romania
- 4 Department of Gastroenterology, Fundeni Clinical Institute, Bucharest, Romania

Corresponding author

Cătălina Diaconu, MD

Department of Gastroenterology, Floreasca Clinical Emergency Hospital, Floreasca Street 8, PC 014461 Bucharest, Romania
 Fax: +40-21-5992300
 catalinadiaconu89@gmail.com

References

- [1] Podolsky D, Camilleri M, Kalloo A, Shanahan F. Yamada's textbook of gastroenterology. 6th edn. Sussex: Wiley Blackwell; 2016: 126, 1152–1153
- [2] Tărcoveanu E, Vasilescu A, Vlad N et al. Cystic pancreatic heterotopia – rare case of antro-pyloric stenosis in adults. Heterotopie pancreatică chistică – cauză rară de stenoză antropilorică la adulți. Rom J Surg 2011; 7: 424–430
- [3] Nakao T, Yanoh K, Itoh A. Aberrant pancreas in Japan. Review of the literature and report of 12 surgical cases. Med J Osaka Univ 1980; 30: 57–63
- [4] Guimarães M, Rodrigues P, Gonçalves G et al. Heterotopic pancreas in excluded stomach diagnosed after gastric bypass surgery. BMC Surg 2013; 13: 56

Bibliography

DOI <https://doi.org/10.1055/a-0605-2996>
 Published online: 9.5.2018
 Endoscopy 2018; 50: E186–E187
 © Georg Thieme Verlag KG
 Stuttgart · New York
 ISSN 0013-726X

ENDOSCOPY E-VIDEOS

<https://eref.thieme.de/e-videos>



Endoscopy E-Videos is a free access online section, reporting on interesting cases and new

techniques in gastroenterological endoscopy. All papers include a high quality video and all contributions are freely accessible online.

This section has its own submission website at <https://mc.manuscriptcentral.com/e-videos>