



a study was undertaken to find whether  $\alpha$ -tocopherol pretreatment could enhance myocardial tolerance towards experimental myocardial infarction. Since lipid peroxidation has been reported to be associated with various deleterious effects including tissue damage and necrosis, direct evidence like histology of the organs involved may throw more light on the effect of  $\alpha$ -tocopherol on isoproterenol induced myocardial infarction in rats.

### METHODS

Adult male Wistar rats weighing 120–150 g, obtained from Fredrick Institute of Plant Protection and Toxicology, Padappai, Madras were used for the study. They were acclimatised to animal house condition and were fed with commercial pelleted rat chow, (Hindustan Lever Ltd, Bombay). The rats were divided into 4 groups. Group I served as control. Group II rats were administered isoproterenol (20 mg/100 g body wt, subcutaneously, twice at an interval of 24 hrs at the end of experimental period). Group III rats were orally administered  $\alpha$ -tocopherol (6 mg/100 g body wt, orally, in pure olive oil daily for a period of 90 days). Group IV rats were orally administered  $\alpha$ -tocopherol in pure olive oil at the above mentioned dosage for a period of 90 days and were administered isoproterenol (20 mg/100 g body wt, sc, twice at an interval of 24 hrs) at the end of the experimental period.

ECGs of rats were recorded using Physio-control, Life Pak 9B, cardiac monitor defibrillator. Under light anaesthesia, recordings were made on the bipolar standard leads, i.e., I, II and III and the augmented extremity leads, i.e., aVR, aVL and aVF. However, it was observed that in all cases of myocardial infarction, lead II appeared to show the individual waves best and hence ECG monitoring thereafter was done on lead II only.

After the recordings of the ECG, the animals

were sacrificed by cervical decapitation. Blood was collected and the serum separated was used for the assay of marker enzymes. Immediately after the sacrifice, the heart and aorta were dissected out and washed in ice-cold saline. A portion of the tissues was fixed in 10% formalin saline and stained with hematoxylin and eosin for histological examination. Another portion of the tissues was homogenised in 0.1M Tris-HCl buffer (pH 7.4) and used for the estimation of aspartate amino transferase (EC 2. 6. 1. 1) (7), alanine amino transferase (EC. 2. 6. 1. 2) (7), lactate dehydrogenase (EC 1. 1. 1. 27) (7) and Creatine Kinase (2. 7. 3. 2) (8). Lipid peroxides in serum, heart and aorta were estimated by the method of Okhawa et al (9). Protein was determined by the method of Lowry et al (10). Since no significant change was observed in any of the parameters studied by olive oil, the values for olive oil are not included.

### RESULTS

Fig. 1 shows the ECG pattern and heart rate of control and experimental animals. A significant elevation of ST segment and significant reductions in PR interval, QRS interval and QT interval was observed in isoproterenol administered rats when compared to control. A significant increase in heart rate was also observed. In  $\alpha$ -tocopherol pretreated rats, administered isoproterenol, ECG pattern and heart rate was maintained near normal.

In isoproterenol treated rats, a significant increase in serum and tissue lipid peroxides was observed. Animals protected with  $\alpha$ -tocopherol maintained the level of lipid peroxides in serum and tissues at near normal values (Table I).

Isoproterenol administered rats showed a significant decrease in the activities of marker enzymes such as ALT, AST, LDH and CK in heart and aorta with a concomitant increase in their activities in serum. Rats protected with

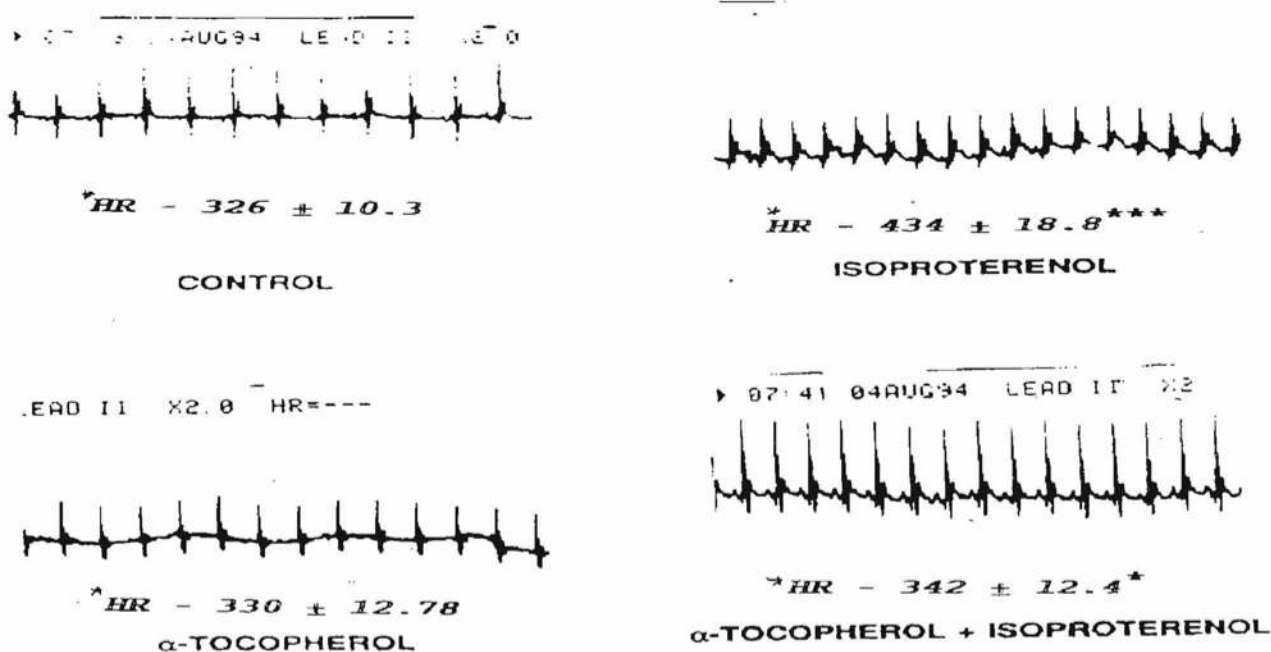


Fig. 1 : ECG pattern of control and experimental animals. Mean  $\pm$  S. D. for 6 animals in each group \*HR-Heart Rate statistically significant variations when compared with controls are expressed as  $^{***}P < 0.001$ ,  $^{**}P < 0.01$ ,  $^*P < 0.05$ .

TABLE I : The levels of lipid peroxides (TBA reactants) in serum, heart and aorta of control and experimental animals. Values are expressed as mean  $\pm$  S.D. for 6 animals in each group.

Group	Lipid peroxides		
	Serum	Heart	Aorta
I Control	2.1 $\pm$ 0.1	3.5 $\pm$ 0.3	3.7 $\pm$ 0.3
II Isoproterenol	4.4 $\pm$ 0.3 $^{***}$	6.3 $\pm$ 0.5 $^{***}$	4.3 $\pm$ 0.4 $^{**}$
III $\alpha$ -Tocopherol	1.9 $\pm$ 0.1 $^*$	3.0 $\pm$ 0.2 $^*$	3.5 $\pm$ 0.2
IV $\alpha$ -Tocopherol + Isoproterenol	2.4 $\pm$ 0.2 $^*$	4.0 $\pm$ 0.4 $^*$	3.9 $\pm$ 0.3

The level of lipid peroxides in serum is represented as nmoles of TBA reactants/ml.

The levels of lipid peroxides in heart and aorta are expressed as nanomoles of TBA reactants/mg protein.

Statistically significant variations when compared with controls are expressed as  $^{***}P < 0.05$ .

$\alpha$ -tocopherol maintained the activities of marker enzymes in serum, heart and aorta at near normal values (Table II).

In isoproterenol administered rats, the heart shows an area of myocytolysis and infiltration by mononuclear cells. The lumen shows a thrombus and the aorta shows an early

thrombus formation. Microscopic examination of heart and aorta of isoproterenol administered rats and protected with  $\alpha$ -tocopherol showed normal architecture except a few areas with slight haemorrhage and an area of early thrombus formation in the heart and aorta showed a normal architecture.

TABLE II : The activities of aspartate amino transferase (AST), alanine amino transferase (ALT), lactate dehydrogenase (LDH) and creatine kinase (CK) in serum, heart and aorta of control and experimental animals. Values are expressed as mean  $\pm$  S.D. for 6 animals in each group.

		Control	Isoproterenol	$\alpha$ -Tocopherol	$\alpha$ -Tocopherol + isoproterenol
Aspartate amino transferase (AST)	A	24.3 $\pm$ 1.7	41.3 $\pm$ 3.7***	22.9 $\pm$ 1.9	27.2 $\pm$ 1.7*
	B	37.2 $\pm$ 2.8	24.3 $\pm$ 1.8***	38.7 $\pm$ 2.5	32.9 $\pm$ 2.8*
	C	32.1 $\pm$ 2.3	27.3 $\pm$ 1.9**	34.2 $\pm$ 2.6	32.0 $\pm$ 2.8
Alanine amino transferase (ALT)	A	13.8 $\pm$ 1.1	24.4 $\pm$ 1.9***	12.9 $\pm$ 0.8	14.7 $\pm$ 0.9
	B	21.4 $\pm$ 1.8	12.1 $\pm$ 0.8***	23.5 $\pm$ 1.8	19.1 $\pm$ 1.8
	C	18.5 $\pm$ 1.4	15.8 $\pm$ 1.3**	18.3 $\pm$ 1.5	17.9 $\pm$ 1.4
Lactate dehydrogenase	A	75.6 $\pm$ 5.5	149.7 $\pm$ 9.4***	73.9 $\pm$ 6.1	83.64 $\pm$ 6.4
	B	96.5 $\pm$ 7.1	61.3 $\pm$ 5.4***	98.7 $\pm$ 7.9	86.2 $\pm$ 8.2
	C	87.4 $\pm$ 8.1	76.1 $\pm$ 6.9	88.8 $\pm$ 7.9	85.9 $\pm$ 7.8
Creatine Kinase	A	274.1 $\pm$ 19.1	610.4 $\pm$ 32.2***	256.3 $\pm$ 17.3	306.2 $\pm$ 20.5*
	B	12.2 $\pm$ 1.0	6.3 $\pm$ 0.4***	13.0 $\pm$ 1.1	11.0 $\pm$ 0.8*
	C	10.2 $\pm$ 0.8	8.4 $\pm$ 0.6**	11.2 $\pm$ 0.8	9.8 $\pm$ 0.8

A : Serum, B : Heart, C : Aorta.

The activities of aspartate amino transferase, alanine amino transferase, lactate dehydrogenase and creatine kinase in serum are expressed as IU/ litre.

The activities of aspartate amino transferase, alanine amino transferase and lactate dehydrogenase in heart and aorta are expressed as nanomoles of pyruvate liberated/min/mg of protein.

The activity of creatine kinase in heart and aorta is expressed as micromoles of phosphorous liberated /min/mg protein.

Statistically significant variations when compared to controls are expressed as \*\*\*P<0.001, \*\*P<0.01, \*P<0.05.

## DISCUSSION

Normal ECG of the rat resembles in essential the detail, that of man. Heart rates of the control rats and isoproterenol administered rats obtained in this study are comparable to the values reported by Kela et al (11).

Control rats showed a normal P wave and no Q waves were observed and every P wave was followed by a narrow QRS of normal contour. In isoproterenol administered rats a significant elevation in the ST segment and a higher heart rate was observed when compared to control. ST segment elevation is a sign of myocardial infarction (12). Similar findings on isoproterenol induced myocardial infarction have been reported by Hill et al (13).

Group IV rats showed a normal ECG with P-QRS-T configuration except slight elevation in ST segment. Heart rate was maintained near

normal. The maintenance of normal ECG pattern confirms the protective effect of  $\alpha$ -tocopherol in preventing free radical mediated myocardial damage.

The diagnostic marker enzymes of myocardial infarction are creatine kinase, lactate dehydrogenase and transaminases (14). Isoproterenol treated rats showed a significant decrease in the activity of the enzymes such as LDH, CK, AST and ALT in the heart and aorta with a subsequent significant increase in their activities in serum when compared to control (15). An increase in the activity of these marker enzymes in serum could be due to the leakage of the enzymes from heart as a result of necrosis. The amount of enzyme released from the damaged myocardium is a measure of the size of infarction (16). Damage to the myocardial and aortic tissues could be due to the free radical mediated lipid peroxidation by isoproterenol (17).

$\alpha$ -Tocopherol pretreatment in Group IV rats

maintained the activities of the marker enzymes in serum and tissues near normal. This could be due to the effective free radical quenching property of  $\alpha$ -tocopherol (18). According to the antioxidant hypothesis, the primary function of  $\alpha$ -tocopherol *in vivo* is the prevention of the destructive peroxidation of polyunsaturated fatty acid (PUFA) (19).  $\alpha$ -Tocopherol may physically stabilise biological membranes that are rich in PUFA by specific physicochemical interactions of the phytyl side chain of vitamin E and arachidonyl residues of phospholipid molecules in the hydrophobic regions of biological membranes (20).

A significant increase in the levels of lipid peroxides in serum, heart and aorta, in terms of TBA reactive substances, on isoproterenol administration indicates enhanced lipid peroxidation by free radicals.  $\alpha$ -tocopherol pretreatment maintained the lipid peroxide levels at near normal values in Group IV rats, indicating its ability to inhibit free radical mediated lipid peroxidation (21).

Rats pretreated with  $\alpha$ -tocopherol alone showed a significant decrease in serum lipid peroxide levels compared to control, which could be attributed to the high serum  $\alpha$ -tocopherol concentration. Reports reveal an inverse relationship between serum  $\alpha$ -tocopherol

concentration and lipid peroxide levels (22).

As noted from the histology reports of heart and aorta, isoproterenol administration accompanied marked fragmentation of muscle fibres, appearance of mononuclear inflammatory cells and necrotic lesions in the left ventricle. This is in accordance with the observation of Narinder et al (23). Myocytolysis could have resulted in the leakage of the marker enzymes into the serum and the severity of lesions is related to the severity of myocardial necrosis. Group IV rats showed a near normal tissue architecture, which establishes the ability of  $\alpha$ -tocopherol as an antioxidant, in reducing lipid peroxidation and the severity of myocardial necrosis.

The results obtained from this study confirm the role of  $\alpha$ -tocopherol as a potent antioxidant against isoproterenol induced experimental myocardial infarction.

#### ACKNOWLEDGEMENTS

The authors (API and CSS) thank University Grants Commission for the financial support. The authors are grateful to Dr. Baba Krishnan and Dr. Rama Gopalan, Department of Pathology, Postgraduate Institute of Basic Medical Sciences, Taramani, Madras for the help rendered by them for the histological studies.

#### REFERENCES

1. Wexler BC, Greenberg BP. Protective effects of clofibrate on isoproterenol-induced myocardial infarction in arteriosclerotic and non-arteriosclerotic rats. *Atherosclerosis* 1978; 29: 373-375.
2. Dwivedi S, Chansouria JPN, Somain PN. An experimental model for myocardial ischemia in rabbits. *Ind J Exp Biol* 1987; 25: 753-757.
3. Klonner RA, Braunwals E. Observations on experimental myocardial ischemia. *Cardiovasc Res* 1980; 14 : 371-395.
4. Young IS, Purvis JA, Lightbody JH, Adgey AA, Trimble ER. Lipid peroxidation and antioxidant status following thrombolytic therapy for acute myocardial infarction. *Eur Heart J* 1993; 14: 1027-1033.
5. Wexler BC. Protective effects of propranolol in isoproterenol induced myocardial infarction. *Atherosclerosis* 1973; 18 : 11-14.
6. Tappel AL. Vitamin E as the biological lipid antioxidant. *Vitam Horm* 1962; 20 : 493-510.
7. King J. In "Practical Clinical Enzymology" 1965 D Von Nostrand Co. Ltd, London.
8. Okinaka S, Kumagai H, Ebashi E, Sugaita M, Momoi Y, Tayokura Y, Fujie Y. Serum creatine phosphokinase activity in progressive muscular dystrophy and neuromuscular disease. *Arch Neurol* 1961; 4 : 520-526.



9. Okhawa H, Ohishi N, Yagi K. Reaction of linoleic acid hydroperoxide with thiobarbituric acid. *Anal Biochem* 1979; 95 : 351-354.
10. Lowry OH, Rosebrough NJ, Farr LA, Randall RJ. A colorimetric method for protein determination. *J Biol Chem* 1951; 193: 265-275.
11. Kela AK, Prakasam Reddy L, Thombre DP. E.C.G. findings in normal rats and after administration of isoproterenol. *Indian J Physiol Pharmacol* 1980; 24: 84-90.
12. Miller NE, Mjos OD, Oliver MF. Relationship of epicardial ST segment elevation to the plasma FFA to albumin ratio during coronary occlusion in dogs. *Clin Sci Mol Med* 1976; 51: 209-213.
13. Hill RAN, Howard, Greshman GA. The electrocardiographic appearances of myocardial infarction in rat. *Br J Exptl Pathol* 1966; 41: 633-637.
14. Witteveen Sagi AGJ, Hemker HC, Hollar L, Hermens W. Th. Quantitation of infarct size in man by means of plasma enzyme levels. *Br Heart J* 1975; 37: 795-803.
15. Manjula TS, Geetha A, Shyamala Devi CS. Effect of aspirin on isoproterenol induced myocardial infarction A pilot study. *Ind J Biochem Biophys* 1992; 29: 378-379.
16. Geetha A, Sankar R, Thankamani Marar, Shyamala Devi CS.  $\alpha$ -tocopherol reduces doxorubicin induced toxicity in rats - Histological and biochemical evidences. *Indian J Physiol Pharmacol* 1990; 34: 94-100.
17. Sushmakumari S, Jayadeep A, Sureshkumar JS, Menon VP. Effect of carnitine on malondialdehyde, taurine and glutathione levels in heart of rats subjected to myocardial stress by isoproterenol. *Ind J Exp Biol* 1989; 27: 134-137.
18. Tappel AL. Measurement of and protection from *in vivo* lipid peroxidation. In "Free radicals in biology" by Pryor WA, Academic Press, New York, 1980; Vol 4: 1-47.
19. Mc Cay PB, King MM. In Vitamin E, A comprehensive treatise, L.J.Machlin (ed.) Marcel Dekkar, New York, 1980; 289-317.
20. Diplock AT, Lucy JA. The biochemical modes of action of vitamin E and Selenium a hypothesis. *FEBS Lett* 1973; 20: 205-210.
21. Burton GW, Joyce A, Ingold KV. Is vitamin E the only lipid soluble chain-breaking antioxidant in human blood plasma and erythrocyte membranes? *Arch Biochem Biophys* 1983; 221: 215-223.
22. Sies H. Relationship between free radicals and vitamins; an overview. *Int J Vitam Nutr Res Suppl* 1989; 30: 215-223.
23. Narinder KK, Subhash Dhawan, Swarn Nityanand. Isoproterenol induced myocardial necrosis and biogenic amine levels in rats. *Ind J Exp Biol* 1979; 17: 292-294.