

Effect of continued rt-PA administration on the residual stenosis after initially successful recanalization in acute myocardial infarction — a quantitative coronary angiography study of a randomized trial

P. W. SERRUYS, A. E. R. ARNOLD, R. W. BROWER, D. P. DE BONO, M. BOKSLAG, J. LUBSEN, J. H. C. REIBER, W. R. RUTSCH, R. UEBIS, A. VAHANIAN, M. VERSTRAETE, FOR THE EUROPEAN CO-OPERATIVE STUDY GROUP FOR RECOMBINANT TISSUE-TYPE PLASMINOGEN ACTIVATOR*

KEY WORDS: rt-PA, myocardial infarction, reocclusion, quantitative coronary angiography.

Quantitative angiography was performed in 68 out of 123 patients treated with intravenous rt-PA for acute myocardial infarction. At 90 min angiography, the median minimal cross-sectional area was 1.11 mm² and the median percentage area stenosis was 80%. A percentage area stenosis greater than 70% was seen in 78% of the patients.

Patients with a patent infarct related artery at the first angiogram were randomized to receive subsequent infusions either of rt-PA + heparin or placebo + heparin. There was a persistent trend of improvement in minimal lumen diameter and percentage diameter stenosis of the residual stenosis in the infarct related artery in both treatment groups when re-examined 6–24 hours later and at the time of hospital discharge. A reduction in 'plaque area', the area between the detected and the reference contours of the infarct related segment, was more frequently seen in patients receiving a second infusion of rt-PA than in patients with no prolonged thrombolytic therapy (83% versus 57%, $P < 0.025$, chi square).

Introduction

It has been suggested that both the early and late reocclusion rate following intravenous administration of rt-PA^[1,2] may be higher than the reocclusion rate observed with intravenous or intracoronary streptokinase^[3–15]. The short half life of rt-PA (g-11021) and the relatively minor systemic fibrinolytic effect could lead to a high incidence of reocclusion as soon as the infusion of the drug is terminated^[2]. A trial was, therefore, performed to determine the reocclusion rate after successful recanalization by intravenous rt-PA, and to establish whether a continued infusion with rt-PA over a 6 hour period after the initial recanalization could influence the reocclusion rate. The quali-

tatively assessed reocclusion rate, as has been published separately^[16], was low at 6–24 hours (7%, 95% confidence limits 2 to 15%) and at predischARGE (5%, 95% confidence limits 1 to 14%), without differences between the 2 treatment groups.

Quantitative coronary angiography allows a more detailed and objective analysis of any change, however gradual, of the morphology of the coronary stenosis which cannot accurately be obtained by subjective assessment. We used it in the present study to investigate whether a prolonged infusion of rt-PA could achieve a further 'clean-up' of the recanalized infarct related vessel in the first 6–24 hours following the initial recanalization obtained after a 90 minutes infusion of rt-PA.

The specific objectives of this report are:

- (1) to quantify the residual lesions after thrombolysis following a 90 minute infusion of rt-PA,
- (2) to determine their spontaneous evolution and whether a prolonged infusion of rt-PA further enhances lysis of the remaining intraluminal thrombus,
- (3) to identify the lesions that are liable to reocclude during hospital stay.

Submitted for publication on 4 March 1987 and in revised form 26 June 1987.

*For details of participants and participating centres, see at end of text before references.

Address for correspondence: P. W. Serruys, Core Laboratory for Quantitative Angiography, Westzeedijk 120, 3016 AH Rotterdam, The Netherlands.

Methods

PATIENTS

Among the 123 patients enrolled in a reocclusion trial of the European Co-operative Study Group, 119 underwent coronary angiography 90 minutes after the start of an infusion with 40 mg rt-PA and a bolus of 5000 IU heparin^[16]. According to local assessment, 86 patients had a patent infarct related vessel and 33 patients were judged to have an occluded infarct related vessel. Out of the 86 patients with a patent infarct related vessel, 42 patients were randomized to receive a second infusion of 30 mg rt-PA over a time period of 6 hours and heparin while 40 patients received placebo and heparin (see Fig. 2).

Patients were excluded from analysis if either mechanical recanalization or other pharmacological agents such as streptokinase were applied. This included patients who were recanalized during angiography, probably under the influence of forceful manual injection of contrast medium into the coronary artery, as this is basically a form of mechanical recanalization.

ANALYTIC PROCEDURE

The coronary cineangiograms were analysed by CAAS*, a computer-assisted Cardiovascular Angiography Analysis System, described extensively elsewhere^[17-19]. Briefly, this system allows an objective and reproducible quantification of coronary stenosis. A 35 mm cineframe was selected and digitized with a CCD-camera at very high resolution (1330 × 1770 pixels) and electronically a region of interest (512 × 512 pixels) encompassing the arterial segment to be analysed was selected for subsequent analysis by the computer.

Contours of the arterial segment were detected automatically on the basis of first and second derivative functions of the brightness profile, and corrected for pincushion distortion from the image intensifiers. A calibration factor was derived from a computer processed segment of the angio catheters. From the arterial contour data, a diameter-function was computed. The minimal lumen diameter and a reference diameter, computer-estimated by the interpolated diameter technique^[17-21], were expressed in millimeters. On the basis of the proximal and distal centreline segments and the computed reference diameter function, the reference contours over the obstructed region were reconstructed (Fig. 1). The extent of the obstruction was

determined from the diameter function on the basis of curvature analysis and expressed in millimeters^[17]. The difference in area between the reference and the detected contours over the lesions ('plaque area', in mm²) is a measure for the atherosclerotic plaque^[22], which in the setting of acute myocardial infarction may include partially dissolved thrombus. In addition, this technique allowed the assessment of the eccentricity of the lesion for a given view. The symmetry index ranges from 0 (totally asymmetric) to 1 (symmetric).

The severity of the obstruction can also be expressed as a percentage area stenosis: assuming circular cross-sections at the obstruction and reference position, corresponding luminal areas (mm²) were calculated by comparing the minimal area value at the obstruction with the reference value obtained following the interpolated diameter technique.

ANGIOGRAPHIC PROTOCOL

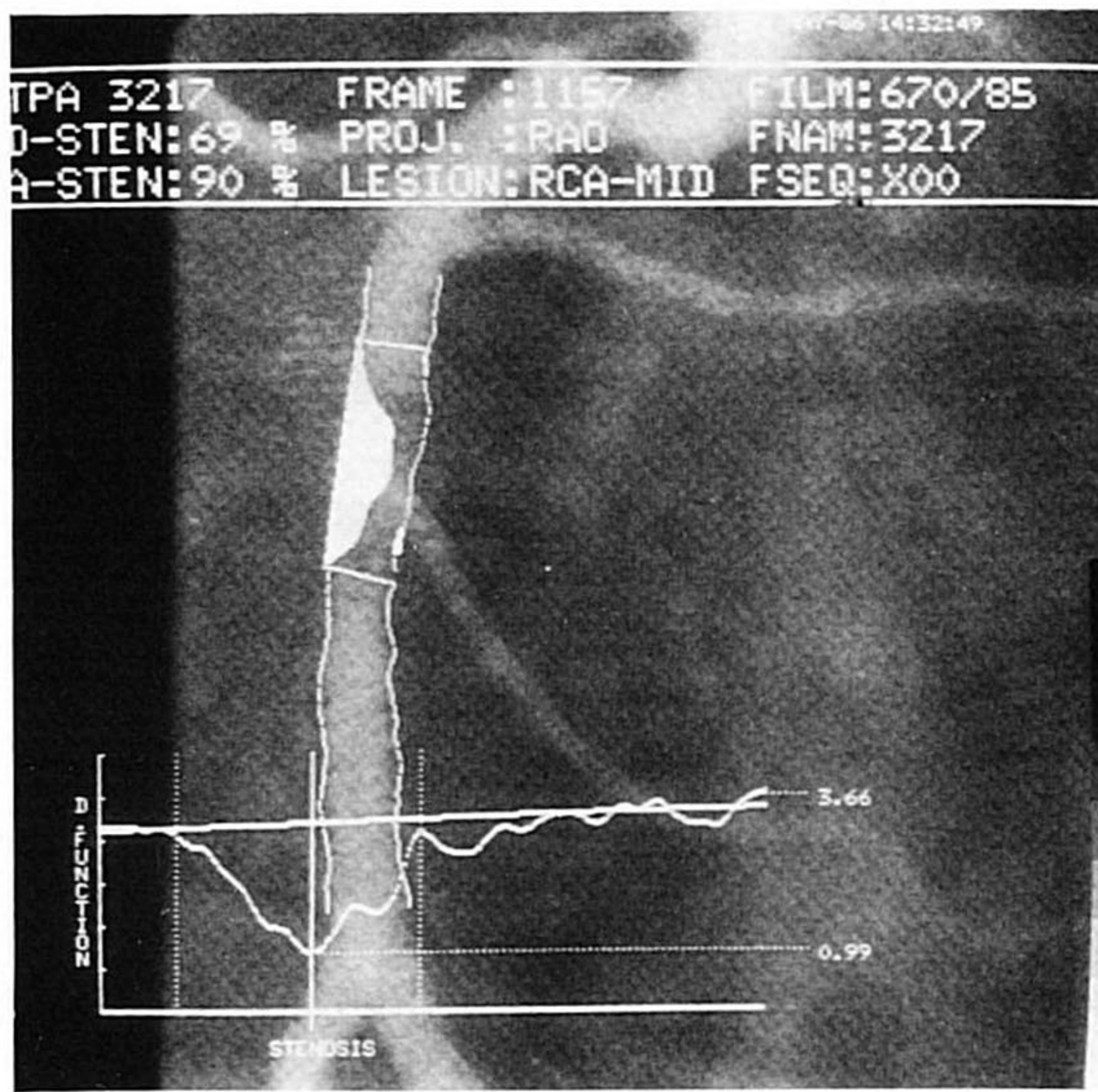
For each series of angiograms following the initial angiogram, the X-ray system was repositioned in projections corresponding as closely as possible to those obtained previously. Angiograms were obtained in multiple views, including hemi-axial views for the left coronary artery. The infarct related segment was identified for all films on the basis of electrocardiographic and angiographic evidence. In those patients in whom the site of occlusion could not be established with certainty because of multiple lesions, the segment with the smallest minimal lumen diameter at the first film was assumed to be infarct related (9 patients). End-diastolic cineframes were selected to avoid the blurring effect produced by the motion of the coronary artery during ejection and to limit the foreshortening often observed during systole^[17].

Only those projections which were reproduced during sequential filming were selected and quantitatively analysed. Average values of measurements obtained in multiple angiographic projections were determined for each segment. For the symmetry index, results from different projections were not averaged, but the lowest value was selected.

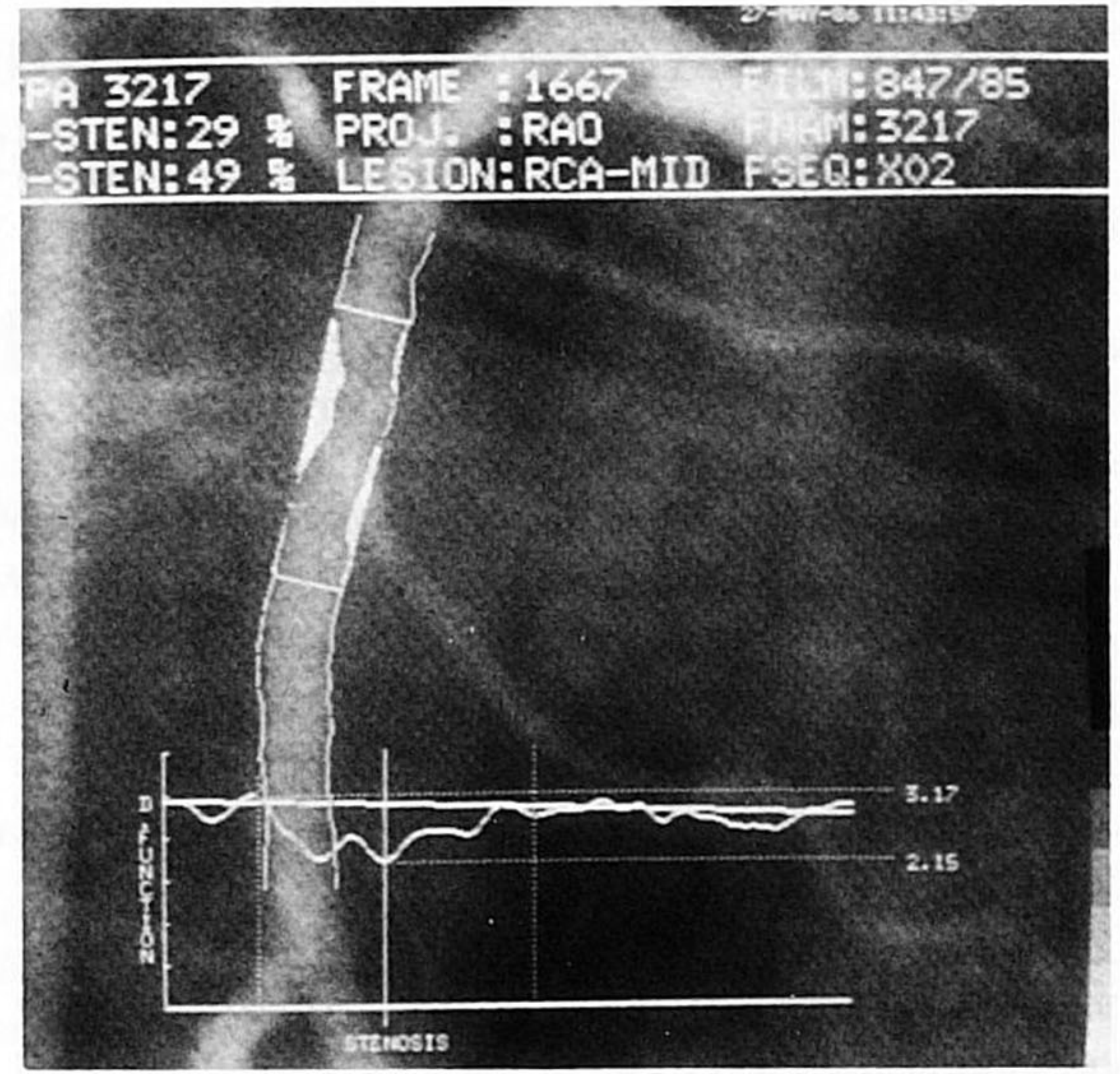
MEASUREMENT ERROR OF REPEATED ANGIOGRAPHY AND QUANTITATIVE ANALYSIS

The accuracy of the quantification method has been validated with plexiglass phantoms filled with contrast medium (perspex models)^[18]. The measurement error of repeated coronary angiography and quantitative analysis (2 standard deviations of

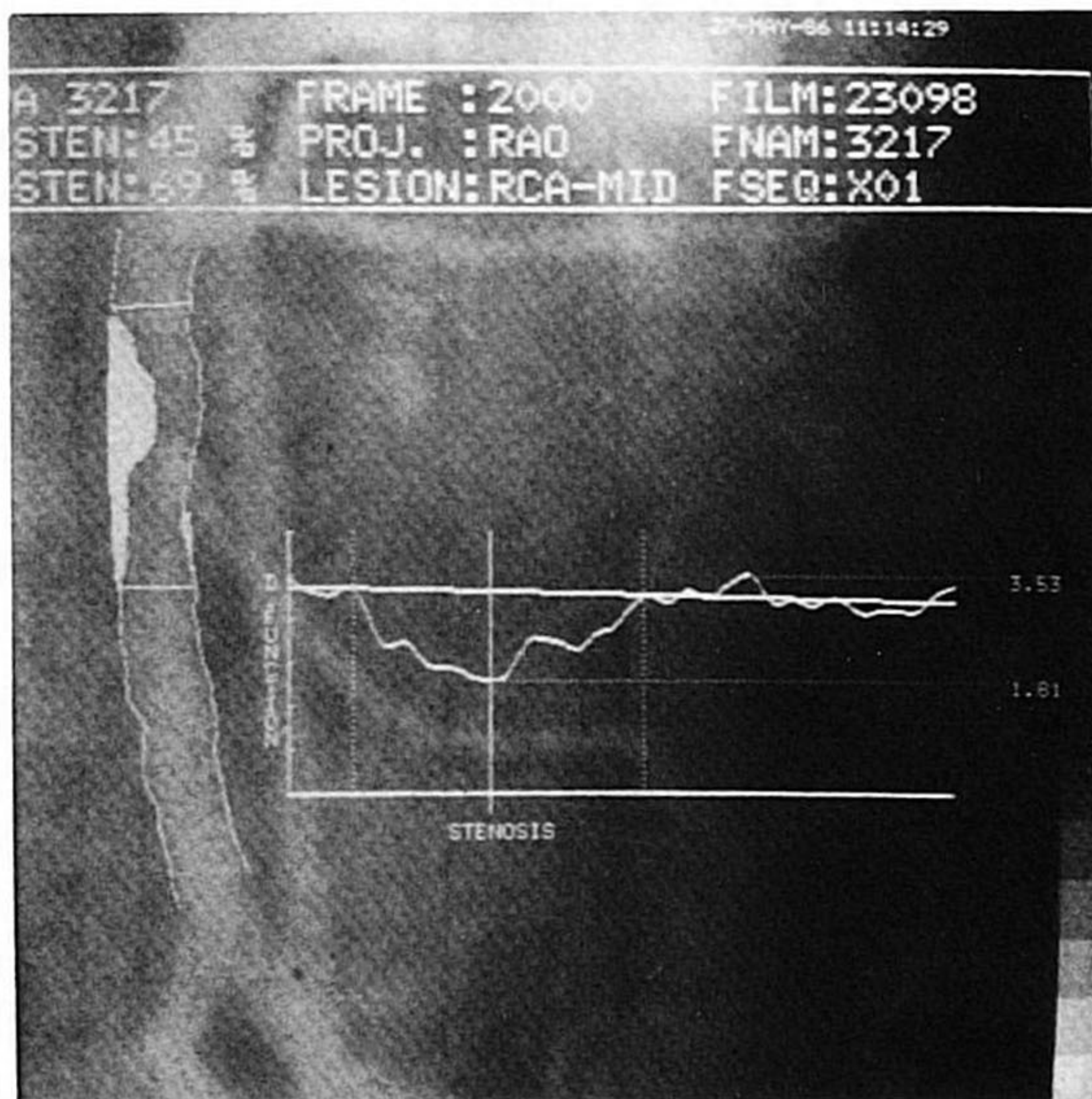
*Pie Data Medical, Maastricht, The Netherlands.



(a)



(c)



(b)

the difference of duplicate measurements) in minimal lumen diameter and interpolated reference diameters have recently been described^[19]. The measurement error of the minimal lumen diameter is 0.72 mm, whereas the measurement error of the 'plaque area' is 5.34 mm². A change greater than the measurement error was considered to be indicative of substantial change in the residual stenosis.

STATISTICAL METHODS

Either the chi square test or analysis of variance was performed where appropriate, under the 'null

Figure 1 Detected contours for a right coronary artery stenosis superimposed on the original video image for sequential filming at 90 minutes (a), 6–24 hours (b) and predischage (c). The diameter function is shown at the bottom. The calibrated diameter measurements in mm are plotted along the ordinate, from the proximal to the distal part of the analysed segment along the abscissa. The minimal luminal diameter is represented by a thick vertical line, the limits of the lesions by thin vertical lines. The normal size of the artery over the obstruction has been estimated by the interpolated diameter technique. The resulting reference contours are shown and the difference in area between this boundary and the detected contours is a measure of the 'plaque area' (shaded area).

hypothesis' that there was no difference in the measured variables between the two treatment groups. Double sided *P*-values are reported.

Results

Multiple matched angiographic projections were obtained during serial cineangiography (at 90 min, at 6–24 hours and predischage angiography) in 55% of the patients (2 views in 42%, 3 views in 13%), while a single matched view was available in the remaining 45% of patients.

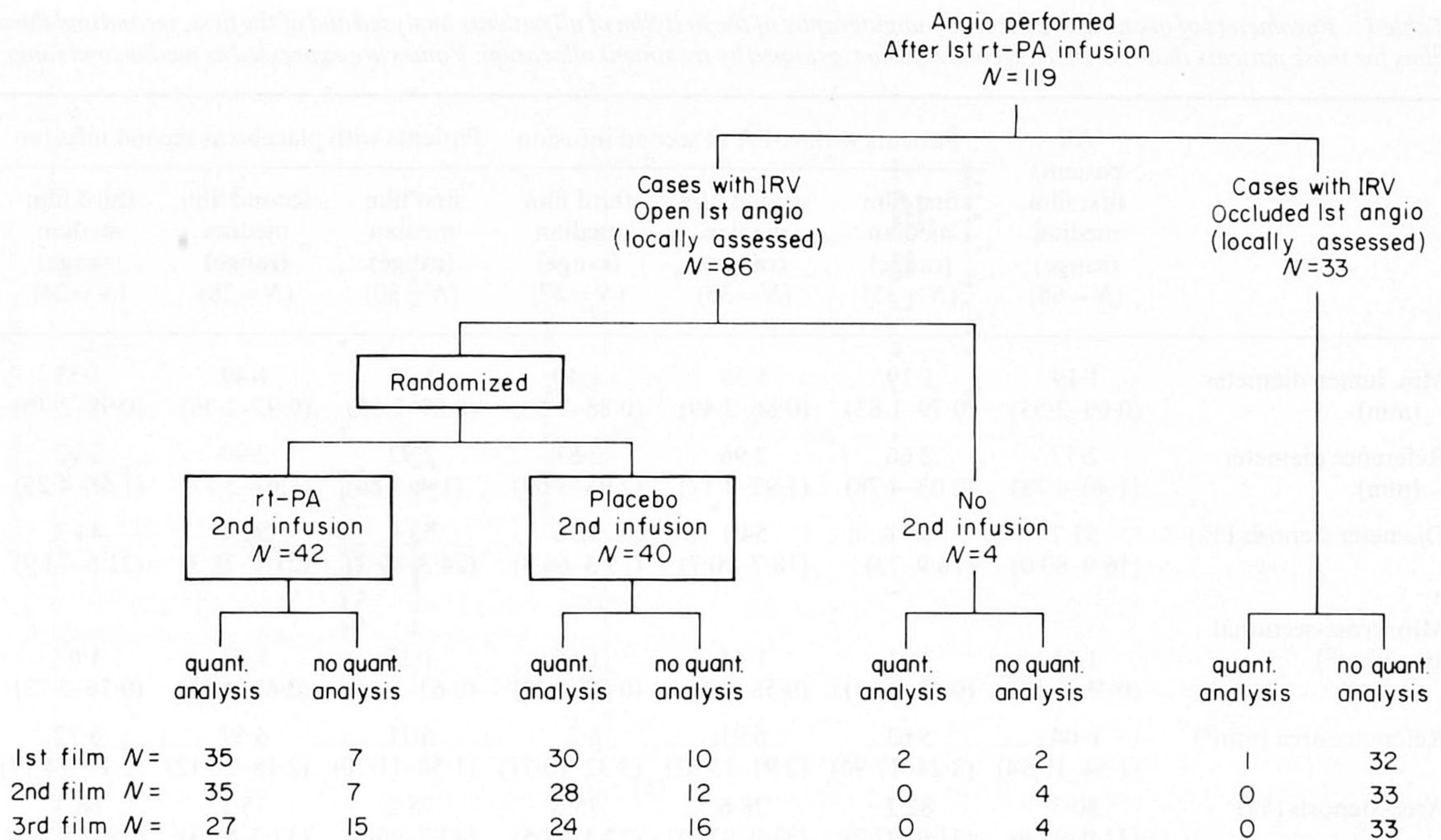


Figure 2 Survey of the study population.

Out of 119 cineangiograms performed 90 minutes after the start of the first rt-PA infusion (see Fig. 2), 51 infarct related stenotic segments could not be analysed because of total occlusion ($N=32$), recording of the angiogram on video tape not suitable for quantitative analysis ($N=7$), inadequate quality of the cineangiography ($N=7$), and because of recanalization by forceful manual injection of contrast medium ($N=4$) or by intracoronary infusion of streptokinase ($N=1$).

At 6–24 hours after the start of the first rt-PA infusion, angiography was performed in 79 out of 82 patients allocated to a second infusion of either rt-PA or placebo. In 3 patients catheterization was not performed for clinical reasons: coronary artery bypass grafting ($N=1$), hypotension ($N=1$) and impossibility to pass the aortic bifurcation ($N=1$). Out of these 79 angiograms, 16 could not be quantitatively analysed because of total occlusion ($N=3$), recording of the angiogram on video tape ($N=5$), or inadequate quality ($N=8$).

At the time of hospital discharge, coronary angiography was performed in 69 patients allocated to a second infusion. This limited number was due to patient refusal ($N=6$), coronary artery bypass grafting ($N=6$), and death ($N=1$). Quantitative analysis was not possible in another 18 angiograms

because of total occlusion ($N=3$), recording of the angiogram on video tape ($N=5$), inadequate quality ($N=7$), or angioplasty during the hospital stay ($N=3$).

RESIDUAL LESIONS AT 90 MINUTES AFTER START OF rt-PA INFUSION

The quantitative angiographic parameters obtained from the first film for all patients and regrouped according to the treatment allocation are given in Table 1. Individual data of the minimal cross-sectional area and the percentage area stenosis of 68 stenotic lesions at 90 min are presented in Fig. 3. The median value for the minimal cross-sectional area was 1.11 mm^2 and the values of the 5th and 95th centiles were 0.60 mm^2 and 2.64 mm^2 respectively. The median value for the percentage area stenosis was 80% while the 5th and 95th centiles were 53 and 91%, respectively.

A percentage area stenosis of less than 50% was seen in only 3 out of 68 patients (4%) and an area stenosis greater than 70% was seen in 53 patients (78%).

EVOLUTION OF THE RESIDUAL LESION AFTER INITIAL THROMBOLYSIS

The sequential changes in the angiographic parameters (paired data) are shown in Table 2,

Table 1 Parameters of quantitative coronary angiography of the first film of all patients analysed and of the first, second and third films for those patients that received a second infusion, grouped by treatment allocation. Values are expressed as median and range

	All patients first film median (range) (N = 68)	Patients with rt-PA at second infusion			Patients with placebo at second infusion		
		first film median (range) (N = 35)	second film median (range) (N = 35)	third film median (range) (N = 27)	first film median (range) (N = 30)	second film median (range) (N = 28)	third film median (range) (N = 24)
Min. lumen diameter (mm)	1.19 (0.69–2.55)	1.19 (0.79–1.83)	1.36 (0.86–2.49)	1.40 (0.88–2.58)	1.25 (0.89–2.55)	1.40 (0.92–2.36)	1.55 (0.98–2.70)
Reference diameter (mm)	2.77 (1.40–4.78)	2.66 (2.03–4.78)	2.96 (1.92–4.17)	2.81 (2.05–3.69)	2.92 (1.4–3.86)	2.90 (1.67–5.77)	2.92 (1.66–4.25)
Diameter stenosis (%)	55.7 (16.9–80.0)	58.1 (16.9–73)	54.1 (18.7–90.7)	52.6 (15.3–66.3)	53.4 (24.3–69.2)	50.4 (21.1–78.3)	44.3 (21.6–73.9)
Min. cross-sectional area (mm ²)	1.11 (0.38–5.12)	1.11 (0.49–2.64)	1.44 (0.58–4.9)	1.56 (0.61–5.23)	1.23 (0.63–5.12)	1.53 (0.67–4.37)	1.67 (0.76–5.73)
Reference area (mm ²)	6.04 (1.54–17.94)	5.63 (3.24–17.94)	6.91 (2.91–13.63)	6.2 (3.32–10.71)	6.71 (1.54–11.70)	6.59 (2.18–26.12)	6.72 (2.17–14.17)
Area-stenosis (%)	80.3 (31.0–95.9)	82.2 (31.0–92.7)	78.6 (33.9–87.2)	75.6 (27.4–88.5)	78.2 (42.7–90.5)	75.3 (37.7–95.3)	68.3 (38.6–93.2)
'Plaque area' (mm ²)	6.85 (1.19–34.29)	6.99 (2.25–18.42)	6.66 (1.57–16.12)	5.04 (1.18–17.25)	6.73 (1.19–16.6)	6.81 (1.26–19.57)	5.78 (1.86–15.57)
Symmetry index	0.43 (0.01–0.93)	0.42 (0.01–0.93)	0.45 (0.14–0.91)	0.28 (0.04–0.67)	0.43 (0.09–0.85)	0.26 (0.06–0.98)	0.36 (0.05–0.95)

Table 2 Changes in parameters of quantitative coronary angiography between first and second film and first and third film, respectively, in patients that received a second infusion, grouped by treatment allocation. Values are expressed as means \pm SD

	rt-PA at second infusion		Placebo at second infusion	
	Difference 1st film – 2nd film (mean \pm SD; N = 32)	Difference 1st film – 3rd film (mean \pm SD; N = 24)	Difference 1st film – 2nd film (mean \pm SD; N = 26)	Difference 1st film – 3rd film (mean \pm SD; N = 23)
Minimal lumen diameter (mm)	-0.21 \pm 0.41	-0.26 \pm 0.51	-0.11 \pm 0.25	-0.17 \pm 0.40
Reference diameter (mm)	-0.09 \pm 0.27	0.05 \pm 0.36	-0.07 \pm 0.51	-0.03 \pm 0.28
Diameter stenosis (%)	4.2 \pm 14.3	8.4 \pm 17.0	3.6 \pm 9.1	6.5 \pm 12.6
Min. cross-sectional area (mm ²)	-0.52 \pm 1.09	-0.70 \pm 1.36	-0.24 \pm 0.59	-0.36 \pm 1.01
Reference area (mm ²)	-0.43 \pm 1.37	0.34 \pm 2.03	-0.57 \pm 3.35	0.07 \pm 1.30
Area-stenosis (%)	5.5 \pm 14.3	9.0 \pm 19.6	4.0 \pm 9.3	6.5 \pm 13.0
'Plaque area' (mm ²)	0.60 \pm 1.90	1.80 \pm 2.57	0.37 \pm 2.21	1.19 \pm 2.57
Symmetry index	-0.04 \pm 0.19	0.09 \pm 0.25	0.08 \pm 0.24	0.01 \pm 0.28

comparing the change from angiography at 90 min to angiography at 6–24 hours and from the 90 min angiogram to the predischage film. The magnitude of the residual lesion, as quantified by minimal lumen diameter, percentage diameter stenosis as

well as 'plaque area' showed a decreasing trend at the 6–24 hours and predischage angiogram in both treatment groups. This is illustrated in Figs 4 and 5, where the minimal lumen diameter and the 'plaque area' measured at predischage are plotted against

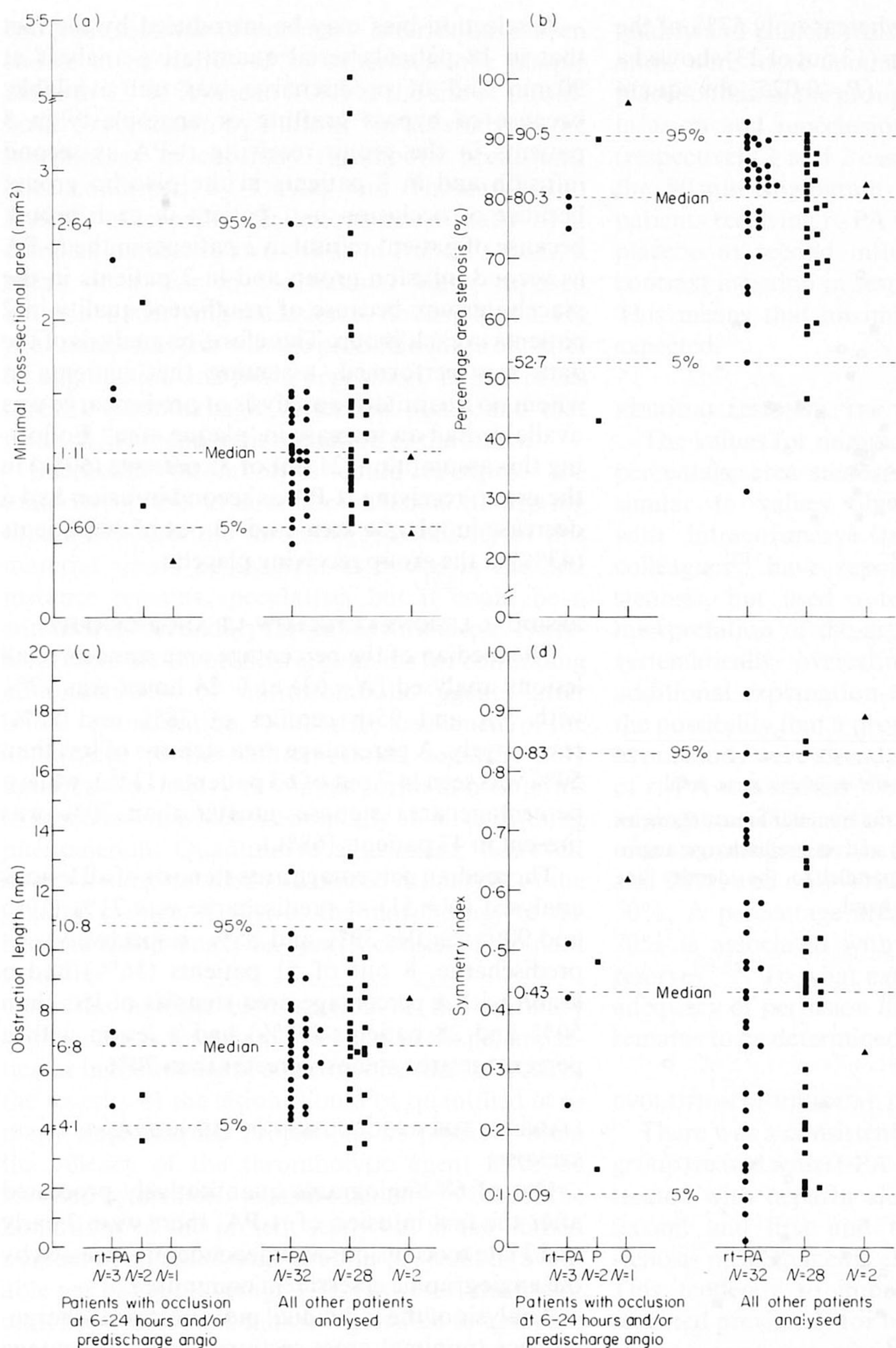


Figure 3 Plot of (a) minimal cross-sectional area, (b) percentage area stenosis, (c) obstruction length and (d) symmetry index at 90 min angiography of the patients with reocclusion during follow-up angiography (3 left hand columns of each part) and of all other patients analysed (P = placebo, O = others).

the measurements obtained from the 90 min angio with the measurement error bands imposed.

On the predischage film, 6 lesions exhibited an increase in minimal lumen diameter exceeding the

measurement error of 0.72 mm. Of these 6 lesions, 4 belonged to the rt-PA group. Eighty-eight percent of the lesions (21 out of 24) in patients treated with a continued infusion of rt-PA were found to have a

decrease in 'plaque area' whereas only 57% of the lesions in the placebo group (13 out of 23) showed a reduction in 'plaque area' ($P < 0.025$, chi square test).

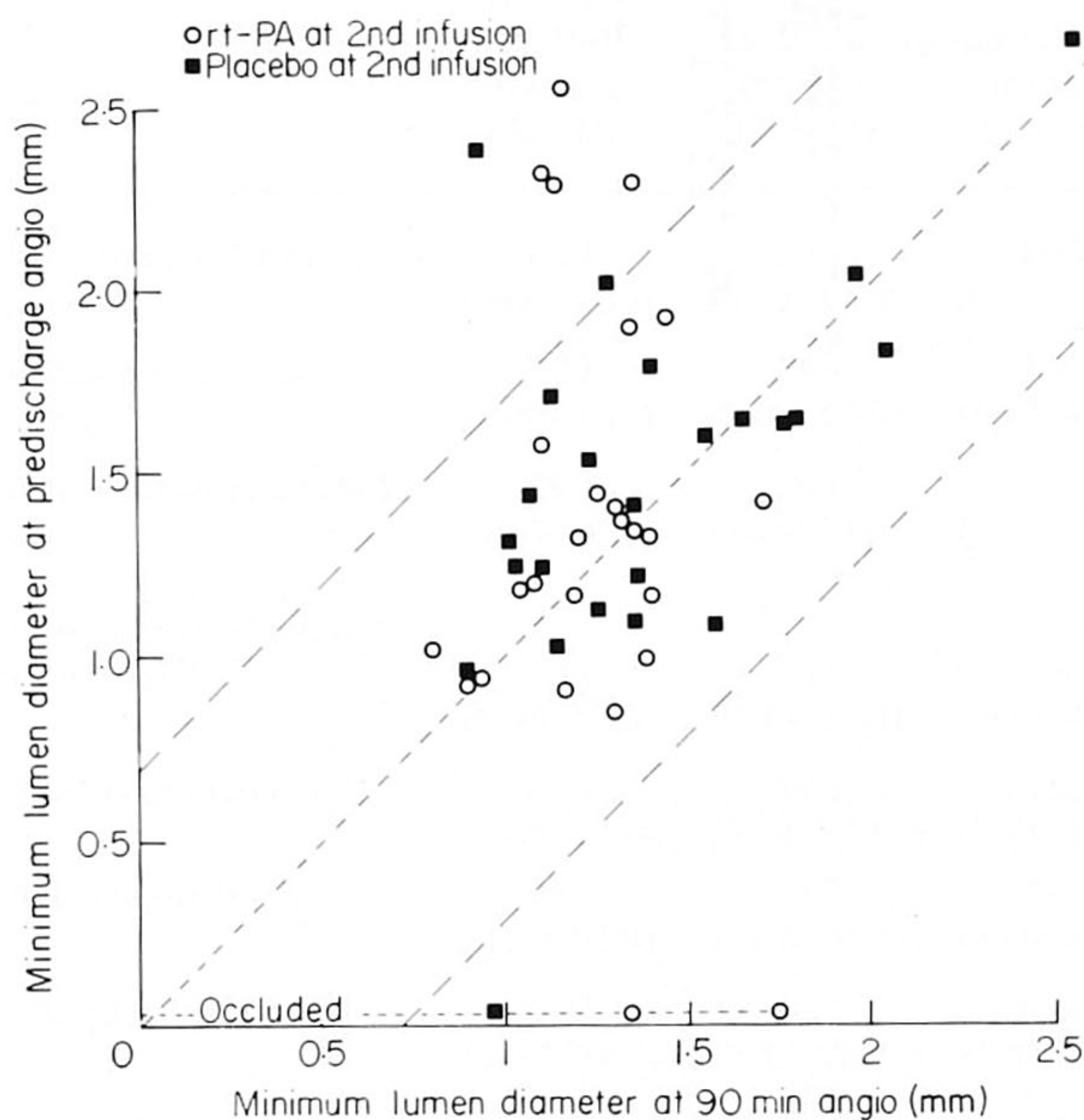


Figure 4 Scatterplot showing the minimal lumen diameter at 90 min angiography (x-axis) and at predischage angiography (y-axis). The 2 lines parallel to the identity line indicate the measurement error band.

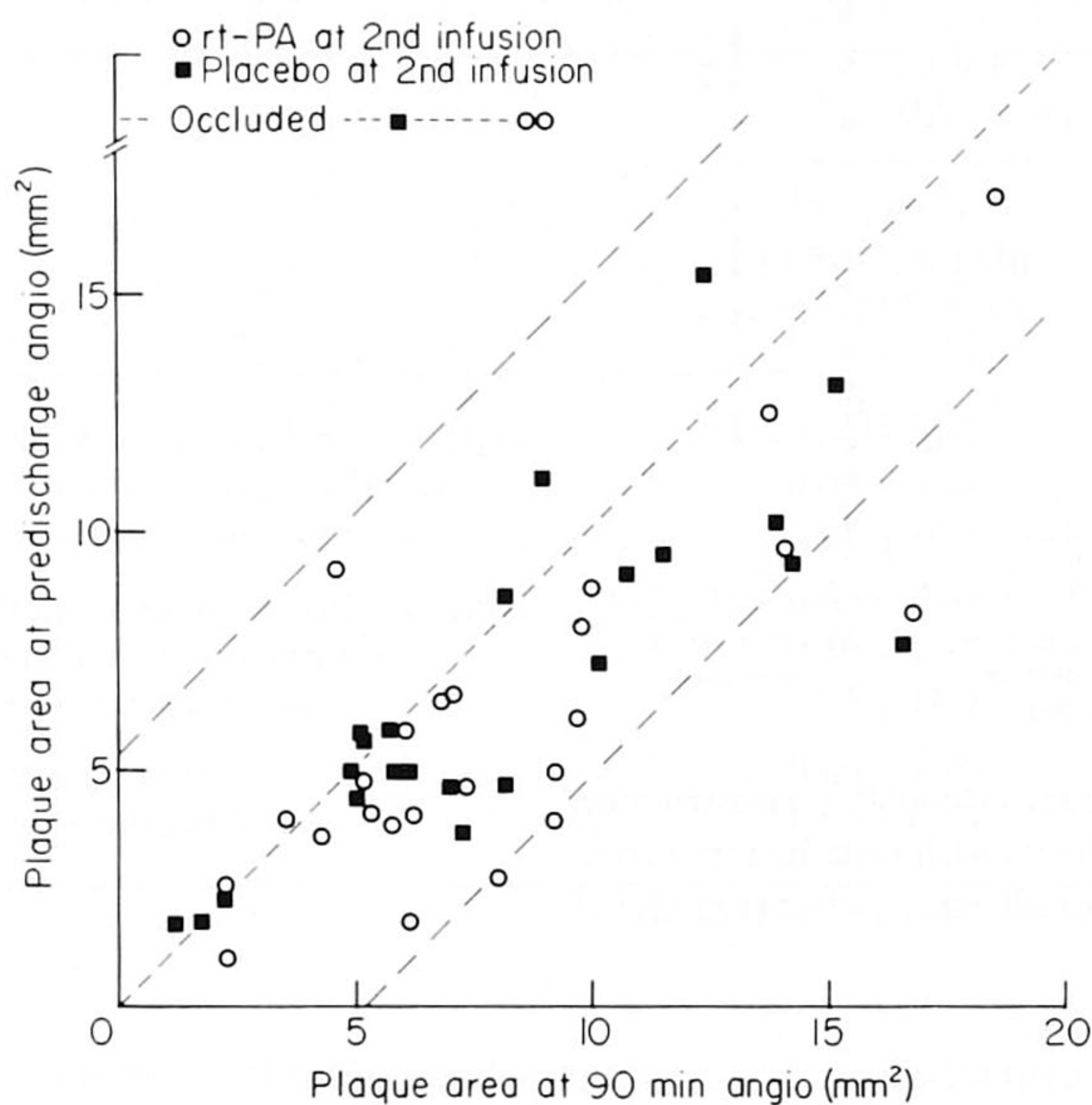


Figure 5 Scatterplot showing the 'plaque area' at 90 min angiography (x-axis) and at predischage (y-axis). The 2 lines parallel to the identity line indicate the measurement error band.

A selection bias may be introduced by the fact that in 18 patients serial quantitative analysis at 90 min and at predischage was not available: because of bypass grafting or angioplasty in 5 patients in the group receiving rt-PA as second infusion and in 2 patients in the placebo group; because of occlusion in 1 patient in each group; because of patient refusal in 3 patients in the rt-PA as second infusion group and in 2 patients in the placebo group; because of insufficient quality in 2 patients in each group. Therefore, re-analysis of the data was performed, assuming that patients in whom no quantitative analysis at predischage was available had an increase in 'plaque area'. Following this assumption, 21 out of 35 patients (60%) in the group receiving rt-PA as second infusion had a decrease in 'plaque area' and 13 out of 30 patients (43%) in the group receiving placebo.

RESIDUAL LESIONS AT FOLLOW-UP ANGIOGRAPHY

The median of the percentage area stenosis of all lesions analysed ($N = 63$) at 6–24 hours was 77% with 5th and 95th centiles of 38% and 87%, respectively. A percentage area stenosis of less than 50% was seen in 7 out of 63 patients (11%), while a percentage area stenosis greater than 70% was present in 43 patients (68%).

The median percentage area stenosis of all lesions analysed ($N = 51$) at predischage was 71% (10th and 90th centiles 39% and 85%, respectively). At predischage, 8 out of 51 patients (16%) had a lesion with a percentage area stenosis of less than 50% and 28 patients (55%) had a lesion with a percentage area stenosis greater than 70%.

LIABILITY FOR REOCCLUSION OF THE RESIDUAL STENOSIS

Out of 68 angiograms quantitatively processed after the first infusion of rt-PA, there were 3 early and 3 late reocclusions as independently assessed by the angiographic assessment committee.

Analysis of the individual morphological characteristics (minimal cross-sectional area, percentage area stenosis, length of obstruction and asymmetry) of the residual lesions which reoccluded versus those which remained patent revealed no systematic pattern. No single parameter could be identified to predict reocclusion (Fig. 3).

Discussion

In patients with transmural acute myocardial infarction and coronary arterial thrombi, histologi-

cal cross-sections of coronary arteries have been shown to be narrowed by atherosclerotic plaque alone to 33–98% (mean 81%) at the site of thrombosis^[23]. As shown by Fulton^[24] in his study on the morphology of coronary thrombotic occlusions, later confirmed by Davies and Thomas^[25] and Falk^[26], atherosclerotic lesions are usually of a complex nature. In two-thirds of Fulton's cases, a break or a tear in the luminal lining exposed material underlying the lesion to flowing blood. He postulated that this was the probable cause of platelet aggregation and fibrin deposition. In half of his cases, a haemorrhagic dissection was found that resulted in an apparent reduction of the lumen.

Successful thrombolysis could re-expose the material of the atheromatous lesion to flowing blood. Whether the thrombogenic activity of this material would be as great as it was in the first instance remains speculative, but it could be a stimulus for secondary thrombus formation. Therefore, there are theoretical arguments for continuing administration of antithrombotic agents after initial recanalization. Qualitative assessment of the angiogram of the infarct related segment only describes secondary thrombus formation in terms of reocclusion, which is essentially an all or nothing phenomenon. Quantitative assessment, however, allows a more detailed and objective analysis of the gradual change, if any, of the morphology of the residual lesion which may partly consist of remnant thrombi.

As the luminal cross-section at the coronary obstruction is frequently irregular in shape, in particular in the setting of acute myocardial infarction, the severity of the lesion should be quantified in as many angiographic projections as possible when the efficacy of the thrombolytic agent is to be assessed by diameter measurements^[20,27]. One of the limitations of the present study lies in the limited number of matched angiographic projections available per patient (average 1.7). However, the use of matched projections makes it possible to compare pairs of observations.

It could be argued that a selection bias is introduced by the fact that in some cases serial quantitative analysis was not possible because of inadequate quality, reocclusion or because recatheterization was not performed for clinical reasons. The assumption that all these patients have an increase in 'plaque area', did not abolish the beneficial effect of a second infusion of rt-PA on the residual stenosis from 90 min to pre-discharge. Furthermore, concerning the 6–24 hours angiogram, inadequate

quality and clinical reasons impeding recatheterization were more common in the group receiving placebo than in the group receiving rt-PA at second infusion and reocclusion nearly equally frequent (respectively 1 and 2 cases). This was also true for the 90 min angiogram (insufficient quality in 2 patients receiving rt-PA and in 4 patients receiving placebo at second infusion; recanalization after contrast injection in respectively 1 and 3 patients). This means that an important bias is not to be expected.

RESIDUAL LESIONS AFTER THROMBOLYSIS

The values for minimal cross-sectional area and percentage area stenosis in the present study are similar to values obtained after thrombolysis with intracoronary streptokinase^[3]. Gold and colleagues^[2] have reported a greater degree of stenosis, but used a technique requiring visual interpretation of the arterial contours which may systematically overestimate the stenosis^[28]. An additional explanation for this difference may be the possibility that a proportion of vessels included in our study were already patent before the infusion of rt-PA was started^[3,29]. At the time of the 90 min angiogram, 78% of the patients had a percentage area stenosis greater than 70%, 18% between 50% and 70%, and only 4% had a stenosis of less than 50%. A percentage area stenosis of greater than 70% is associated with a limited coronary flow reserve^[30–35]. To what extent this can be applied to adequacy of perfusion in the post infarct situation remains to be determined.

EVOLUTION OF RESIDUAL LESIONS

There was a consistent improvement in both the group treated with rt-PA + heparin and in the group treated with heparin alone between the first and second and first and third angiograms for all stenosis measurements except the symmetry index. This tendency to improve with time has been reported previously for both streptokinase induced and spontaneous reperfusion^[12,15,29,36–39]. In contrast with diameter measurements, the 'plaque area' which under these conditions is probably an index of the thrombus associated with the stenosis, showed a significant difference between heparin alone and rt-PA + heparin groups. The 'plaque area' measurement is based on a series of measurements along the length of the stenosis, and may therefore be more sensitive than measurement of the minimal cross-sectional area. It could be argued that rt-PA was helping to clear up thrombus both

upstream and downstream to the site of obstruction, rather than affecting the stenotic lesion itself.

Even when the data are adjusted to account for the possible selection bias introduced by the fact that not in all patients serial quantitative angiography was possible, there is still some evidence for a beneficial effect of a second infusion of rt-PA on the evolution of the residual lesion during hospital stay. This beneficial effect has not been found in terms of reocclusion rate^[16], which is probably less sensitive than the quantitative parameters.

In contrast to some other reports suggesting frequent reocclusion following thrombolysis with rt-PA, there were only three early (1 patient receiving rt-PA at second infusion) and three late reocclusions (2 patients receiving rt-PA at second infusion) among the 68 patients whose films were analysed after the first infusion. It was not possible to relate the risk of reocclusion with any of the angiographic measurements. This would suggest that other factors unrelated to the shape and the size of the residual lesion may be playing a major role.

In conclusion, the majority of patients after thrombolysis is left with a considerable degree of residual stenosis and may require some additional therapeutic intervention to optimize myocardial perfusion. It may not be possible to establish from the morphology of the lesion which patient is at greatest risk for re-occlusion. Finally, this study provides some evidence that prolonged infusion of rt-PA may have a beneficial effect on the residual lesion.

We thank Pauli van Eldik-Helleman and Nicolet Visser-Akkerman for their technical assistance and Brenda Bos-Wolters for preparation of the manuscript.

STEERING COMMITTEE: M. Verstraete (Leuven, chairman); R. J. Lennane (Ingelheim, clinical coordinator); D. P. de Bono (Edinburgh); J. Lubsen (Rotterdam); D. Mathey (Hamburg); R. von Essen (Aachen). ADVISORY BOARD: J. Hampton (Nottingham); H. J. Jesdinsky (Duesseldorf); D. G. Julian (Newcastle-upon-Tyne); W. Schaper (Bad Nauheim); L. Wilhelmsen (Goeteborg). DATA CENTRE: J. Lubsen. R. W. Brower, A. E. R. Arnold, M. Bokslag, E. P. M. Bos-Wolters (Rotterdam). ANGIOGRAPHY EVALUATION GROUP: D. P. de Bono (Edinburgh, Secretary); W. S. Hillis (Glasgow); D. Reid (Newcastle-upon-Tyne); W. Rutsch (Berlin); P. W. Serruys (Rotterdam). CENTRAL COAGULATION LABORATORY: D. Collen, H. R. Lijnen (Leuven). PARTICIPATING CLINICAL CENTRES: Innere Medizin I, Reinisch-Westfaelische Technische Hochschule, Aachen (S. Effert, R. von Essen, R. Uebis, W. Schmidt); Academisch Ziekenhuis van de Vrije Universiteit, Amsterdam (F. W. A. Verheugt, A. J. Funke Kuepper, J. Res); Klinikum Charlottenburg, Freie Universitaet Berlin (H. Schmutzler, W. Rutsch, M. Schartl); Royal

Infirmiry Edinburgh (D. P. de Bono, M. Been); Stobhill General Hospital, Glasgow (F. G. Dunn, W. S. Hillis, K. J. Hogg, R. S. Hornung); 2 Medizinische Universitaets-klinik, UK Eppendorf, Hamburg (W. Bleifeld, D. Mathey, J. Schofer); Sint Annadal Ziekenhuis, Maastricht (C. de Zwaan, H. J. J. Wellens); II. Medizinische Klinik und Poliklinik, Johannes Gutenberg Universitaet, Mainz (J. Meyer, R. Erbel, K. J. Henrichs, T. Pop); Freeman Hospital, Newcastle-upon-Tyne (D. S. Reid); Hôpital Tenon, Paris (J. Acar, A. Vahanian, P. L. Michel, J. M. Weber); Thorax Centrum, Erasmus Universiteit, Rotterdam (P. G. Hugenholtz, P. W. Serruys, M. L. Simoons).

References

- [1] Williams DO, Borer J, Braunwald E *et al.* Intravenous recombinant tissue-type plasminogen activator in patients with acute myocardial infarction: a report from the NHLBI thrombolysis in myocardial infarction trial. *Circulation* 1986; 73: 338–46.
- [2] Gold HK, Leinbach RC, Garabedian HD *et al.* Acute coronary reocclusion after thrombolysis with recombinant human tissue-type plasminogen activator: prevention by a maintenance infusion. *Circulation* 1986; 73: 347–52.
- [3] Serruys PW, Wijns W, Van den Brand M *et al.* Is transluminal coronary angioplasty mandatory after successful thrombolysis? *Br Heart J* 1983; 50: 257–65.
- [4] Merx W, Dörr R, Rentrop P *et al.* Evaluation of the effectiveness of intracoronary streptokinase infusion in acute myocardial infarction: postprocedure management and hospital course in 204 patients. *Am Heart J* 1981; 102: 1181–7.
- [5] Schwarz F, Schuler G, Katus H *et al.* Intracoronary thrombolysis in acute myocardial infarction: correlations among serum enzyme, scintigraphics and hemodynamic findings. *Am J Cardiol* 1982; 50: 32–8.
- [6] Gold HK, Leinbach RC, Palacios IF *et al.* Coronary reocclusion after selective administration of streptokinase. *Circulation* 1983; 68 (Suppl I): 50–4.
- [7] Cribier A, Berland J, Champoud O, Moore N, Behar P, Letac B. Intracoronary thrombolysis in evolving myocardial infarction. Sequential angiographic analysis of left ventricular performance. *Br Heart J* 1983; 50: 401–10.
- [8] Rogers WJ, Mantle JA, Hood WP *et al.* Prospective randomized trial of intravenous and intracoronary streptokinase in acute myocardial infarction. *Circulation* 1983; 68: 1051–61.
- [9] Neuhaus KL, Tebbe V, Sauer G, Vereuzer H, Kosterling H. High dose intravenous streptokinase in acute myocardial infarction. *Clin Cardiol* 1983; 6: 426–34.
- [10] Rentrop KP, Feith F, Blanke H *et al.* Effects of intracoronary streptokinase and intracoronary nitroglycerine infusion on coronary angiographic patterns and mortality in patients with acute myocardial infarction. *N Engl J Med* 1984; 311: 1457–63.
- [11] Ferguson DW, White CW, Schwartz JL *et al.* Influence of baseline ejection fraction and success of thrombolysis on mortality and ventricular function after acute myocardial infarction. *Am J Cardiol* 1984; 54: 705–11.
- [12] Harrison DG, Ferguson DW, Collins SM *et al.* Re-thrombosis after reperfusion with streptokinase: importance of geometry of residual lesions. *Circulation* 1984; 69: 991–9.

- [13] Spann JF, Sherry S, Carabello BA *et al.* Coronary thrombolysis by intravenous streptokinase in acute myocardial infarction: acute and follow-up studies. *Am J Cardiol* 1984; 53: 655-61.
- [14] Charuzi Y, Beeder C, Marshall L *et al.* Improvement in regional and global left ventricular function after intracoronary thrombolysis: assessment with two-dimensional echocardiography. *Am J Cardiol* 1984; 53: 662-5.
- [15] Schroeder R, Voehringer H, Linderer T, Biamino G, Brueggeman T, von Leitner ER. Follow up after coronary arterial reperfusion with intravenous streptokinase in relation to residual myocardial infarct artery narrowings. *Am J Cardiol* 1985; 55: 313-17.
- [16] Verstraete M, Arnold AER, Brower RW *et al.* Acute coronary thrombolysis with recombinant human tissue-type plasminogen activator—initial patency and influence of maintained infusion on reocclusion rate. *Am J Cardiol* 1987; 60: 231-7.
- [17] Reiber JHC, Serruys PW, Slager CJ. Quantitative coronary and left ventricular cineangiography. Martinus Nijhoff Publishers, 1986.
- [18] Reiber JHC, Kooijman CJ, Slager CJ *et al.* Coronary artery dimensions from cineangiograms—methodology and validation of a computer-assisted analysis procedure. *IEEE Trans Med Imag* 1984; MI-3: 131-41.
- [19] Reiber JHC, Serruys PW, Kooijman CJ *et al.* Assessment of short-, medium-, and long-term variations in arterial dimensions from computer-assisted quantitation of coronary cineangiograms. *Circulation* 1985; 71: 280-8.
- [20] Serruys PW, Reiber JHC, Wijns W *et al.* Assessment of percutaneous transluminal coronary angioplasty by quantitative coronary angiography: Diameter vs densitometric area measurements. *Am J Cardiol* 1984; 54: 482-8.
- [21] Wijns W, Serruys PW, Reiber JHC *et al.* Quantitative angiography of the left anterior descending coronary artery: correlations with pressure gradient and results of exercise thallium scintigraphy. *Circulation* 1985; 71: 273-9.
- [22] Crawford DW, Brooks SH, Selzer RH, Brandt R, Beckenbach ES, Blankenhorn DH. Computer densitometry for angiographic assessment of arterial cholesterol contents and gross pathology in human atherosclerosis. *J Lab Clin Med* 1977; 89: 378-92.
- [23] Brosius III FC, Roberts WC. Significance of coronary arterial thrombus in transmural acute myocardial infarction. A study of 54 necropsy patients. *Circulation* 1981; 63: 810-16.
- [24] Fulton WFM. The morphology of the coronary thrombotic occlusions relevant to thrombotic intervention. In: Kaltenbach M *et al.*, eds. *Transluminal coronary angioplasty and intracoronary thrombolysis*. Berlin: Springer-Verlag, 1982; 244-52.
- [25] Davies MJ, Thomas A. Thrombosis and acute coronary artery lesions in sudden cardiac ischemic death. *N Engl J Med* 1984; 310: 1137-40.
- [26] Falk E. Plaque rupture with severe pre-existing stenosis precipitating coronary thrombosis. *Br Heart J* 1983; 50: 127-34.
- [27] Thomas AC, Davies MJ, Dilly S, Dilly N, Franc F. Potential errors in the estimation of coronary arterial stenosis from clinical arteriography with reference to the shape of the coronary arterial lumen. *Br Heart J* 1986; 55: 129-39.
- [28] Bove AA, Holmes DR, Owen RM *et al.* Estimation of the effects of angioplasty on coronary stenosis using quantitative video angiography. *Cath Cardiovasc Diagnosis* 1985; 11: 5-16.
- [29] DeWood MA, Spores J, Notske R *et al.* Prevalence of total coronary occlusion during the early hours of transmural myocardial infarction. *N Engl J Med* 1980; 303: 897-902.
- [30] Sheehan FH, Mathey DG, Schofer J, Dodge HT, Bolson EL. Factors that determine recovery of left ventricular function after thrombolysis in patients with acute myocardial infarction. *Circulation* 1985; 71: 1121-8.
- [31] Hodgson JMCB, LeGrand V, Bates ER *et al.* Validation in dogs of a rapid digital angiographic technique to measure relative coronary blood flow during routine cardiac catheterization. *Am J Cardiol* 1985; 55: 188-93.
- [32] Kirkeeide RL, Gould KL, Parsel L. Assessment of coronary stenosis by myocardial perfusion imaging during pharmacologic coronary vasodilation. VII. Validation of coronary flow reserve as a single integrated functional measure of stenosis severity reflecting all its geometric dimensions. *J Am Coll Cardiol* 1986; 7: 103-13.
- [33] Zijlstra F, Ommeren J v, Reiber JH, Serruys PW. Does quantitative assessment of coronary artery dimensions predict the physiological significance of a coronary stenosis? *Circulation* 1987; 75: 1154-61.
- [34] Gould KL, Lipscomb K, Hamilton GW. Physiological basis for assessing critical coronary stenosis: instantaneous flow response and regional distribution during coronary hyperemia as measures of coronary flow reserve. *Am J Cardiol* 1974; 33: 87-94.
- [35] Gould KL. Pressure-flow characteristics of coronary stenoses in unsedated dogs at rest and during coronary vasodilatation. *Circ Res* 1978; 43: 242-53.
- [36] Cribier A, Saoudi N, Berland J, Letac B. Regression of residual coronary stenosis after recanalization by fibrinolysis in myocardial infarction. Quantitative analysis of coronary angiography immediately after obstruction removal, at a 15-day and 3-month follow-up. *Arch Mal Coeur* 1985; 78: 353-60.
- [37] Uebis R, von Essen R, Schmidt WG, Franke A, Effert S. Residual stenosis following successful selective lysis of complete thrombotic coronary artery occlusion in acute myocardial infarction. *Z Kardiol* 1985; 74: 519-24.
- [38] Brown BG, Gallery CA, Badger RS *et al.* Incomplete lysis of thrombus in the moderate underlying atherosclerotic lesion during intracoronary infusion of streptokinase for acute myocardial infarction: quantitative angiographic observations. *Circulation* 1986; 73(4): 653-61.
- [39] Erbel R, Pop T, Henrichs KJ *et al.* Percutaneous transluminal coronary angioplasty after thrombolytic therapy: a prospective controlled randomized trial. *J Am Coll Cardiol* 1986; 8: 485-95.