

RESEARCH ARTICLE

Open Access

Effect of methanol extract of *Dicranopteris linearis* against carbon tetrachloride- induced acute liver injury in rats

Farah Hidayah Kamisan¹, Farhana Yahya¹, Siti Syariah Mamat¹, Mohamad Fauzi Fahmi Kamarolzaman¹, Norhafizah Mohtarrudin², Teh Lay Kek³, Mohd Zaki Salleh³, Mohd Khairi Hussain¹ and Zainul Amiruddin Zakaria^{1,3*}

Abstract

Background: *Dicranopteris linearis* (family Gleicheniaceae) has been reported to possess anti-inflammatory and antioxidant activities but no attempt has been made to study its hepatoprotective potential. The aim of the present study was to determine the hepatoprotective effect of methanol extracts of *D. linearis* (MEDL) against carbon tetrachloride (CCl₄)-induced acute liver injury in rats.

Methods: 6 groups (n = 6) of rats received oral test solutions: 10% dimethyl sulfoxide (DMSO), 200 mg/kg silymarin, or MEDL (50, 250, and 500 mg/kg), once daily for 7 consecutive days, followed by hepatotoxicity induction with CCl₄. Blood and liver were collected for biochemical and microscopic analysis. The extract was also subjected to antioxidant studies (e.g. 2, 2-diphenyl-1-picrylhydrazyl (DPPH)- and superoxide anion-radical scavenging assays, oxygen radical absorbance capacity (ORAC) test and total phenolic content (TPC) determination), phytochemical screening and HPLC analysis.

Results: Pretreatment with MEDL and silymarin significantly (P < 0.05) reduced the serum levels of AST, ALT and ALP, which were increased significantly (P < 0.05) in DMSO-pretreated group following treatment with CCl₄. Histological analysis of liver tissues in groups pretreated with MEDL and silymarin showed mild necrosis and inflammation of the hepatocytes compared to the DMSO-pretreated group (negative control group). The MEDL showed higher DPPH- and superoxide anion-radical scavenging activity as well as high TPC and ORAC values indicating high antioxidant activity.

Conclusions: MEDL exerts hepatoprotective activity that could be partly contributed by its antioxidant activity and high phenolic content, and hence demands further investigation.

Keywords: *Dicranopteris linearis*, Methanol extract, Carbon tetrachloride, Antioxidant, Hepatoprotective effect

Background

The liver has a pivotal role in regulating many important functions, such as metabolism, secretion, storage; and plays a role in regulating various physiological processes [1]. Furthermore, it is involved in detoxification of a variety of drugs and xenobiotics and therefore at increased susceptible to the toxicity from these agents. It is frequently abused by poor drug habits and alcohol and

widely exposed to environmental toxins, prescribed and over-the-counter drugs, which cause various liver diseases [2]. Liver diseases have become a worldwide problem as a result of extremely poor prognosis and high mortality due to the lack of effective prevention or drug available that stimulates liver function, offer protection against liver damage, or help to regenerate hepatic cells [3,4]. Therefore, attempts are perpetually being made to discover new treatment for liver disease, and the discovering process have been paid great attention to the investigation of the efficacy of plant-based drugs used in traditional medicine as they are cheap and have little

* Correspondence: zaz@upm.edu.my

¹Department of Biomedical Science, Faculty of Medicine and Health Sciences, Universiti Putra Malaysia, 43400 UPM Serdang, Selangor, Malaysia

³Integrative Pharmacogenomics Institute (iPROMISE), Level 7, FF3, Universiti Teknologi MARA, Puncak Alam Campus, 42300 Puncak Alam, Selangor, Malaysia
Full list of author information is available at the end of the article

side effects. Besides, WHO reported that 80% of the world population relies mainly on plant-based drugs [5].

In lieu of the aforementioned problem, patients suffering from liver diseases have turned to complementary and alternative medicine (CAM), which includes among others the use of herbal medicines as their sources of hepatoprotective agents. According to White et al. [6], over 50% of patients that required health care used CAM either in conjunction with, or separate from, conventional health care. Despite its uses for treatment of various types of diseases, the use of CAM is also popular in patients with liver disease but is not well documented [6]. According to Bhawna and Kumar [7], hepatoprotective plants contain a variety of phytochemicals like phenols, coumarins, monoterpenes, glycosides, alkaloids, and xanthenes. In addition, hepatoprotective properties are related with phytoextracts or phytochemicals rich in natural antioxidants as reported from previous studies [8-10]. One of the plants that have been studied extensively in our laboratory for its medicinal potentials is *Dicranopteris linearis* (L. (Gleicheniaceae), locally known as "resam", is common in secondary forests and grows well in poor clay soil [11]. *D. linearis* has been used in Malay traditional medicine to reduce body temperature and to control fever [12]. In addition, there are few reports of its traditional uses in other parts of the world, with only 2 reports describing its use to treat external wounds, ulcers, and boils by the people of Papua New Guinea, to eliminate intestinal worms by the people of Indochina, and to treat asthma and female sterility by the tribes living on an Indian mountain [13]. Scientifically, the leaf extracts of *D. linearis* have been reported to possess antinociceptive, anti-inflammatory and antipyretic [12], gastroprotective [14], antistaphylococcal [15], antioxidant [16], and anticancer activities [17] properties.

The present study was performed based on three reasons, namely: i) the previous reports on the anti-inflammatory and antioxidant activities of *D. linearis* leaves; ii) the reports linking the anti-inflammatory and antioxidant activities to the hepatoprotective mechanism [3,18,19], and; iii) no scientific report to date to prove on the hepatoprotective potential of *D. linearis* leaves. It is postulated that *D. linearis* leaves will exert hepatoprotective activity that could be linked to its antioxidant activity. Therefore, the aim of the present study was to determine the hepatoprotective activity of methanol extract of *D. linearis* (MEDL) using the carbon tetrachloride (CCl₄)-induced acute liver damage in rats model. In addition, the antioxidant activity, phytochemical content and HPLC profile of MEMM were also verified to support the hepatoprotective potential of MEDL. The hepatoprotective potential of the MEDL was compared with silymarin, a known, commercially available hepatoprotective agent.

Methods

Collection of plant material

The plant material (*D. linearis*) was obtained from its natural habitat in Serdang, Selangor, Malaysia. The plant was authenticated by Dr. Shamsul Khamis, a botanist at the Institute of Bioscience (IBS), Universiti Putra Malaysia (UPM), Serdang, Selangor, Malaysia, and voucher specimen SK 1987/11 was deposited in the herbarium of the IBS, UPM. The leaves were shade-dried for a week at room temperature (27 ± 2°C) and powdered mechanically.

Preparation of plant extract

The powdered dried leaves were weighed (160 g) and then soaked (72 hours; room temperature) in methanol in the ratio of 1:20 (w/v). The solutions were collected and filtered with cotton wool followed by Whatman No. 1 filter paper. This procedure was repeated three times. Then, the collected supernatant was pooled together and evaporated using a rotary vacuum evaporator at 40°C under reduced pressure. The evaporation of the MEDL resulted in a yield of 48.4 g (30.3%). The crude dried extract obtained was kept at 4°C prior to use.

Phytochemical screening

The phytochemical screening was carried out to determine the presence of alkaloids, saponins, flavonoids, hydrolysable and condensed tannins, triterpenes and steroids according to the method described by Ikhiri et al. [20]. Analyses were performed based on 5 g of dried powder material and 100 mg of extract (organic).

HPLC analysis of MEDL

The HPLC analysis of MEDL was performed according to the previous report [21] but with slight modifications. Briefly, 10 mg of MEDL was dissolved in 1 ml methanol and then filtered through the membrane filter (pore size 0.45 µm). A Waters Delta 600 with 600 Controller and Waters 2996 Photodiode Array (Milford, MA, USA) equipped with an autosampler, online degasser and column heater was used to analyze the filtered sample. Data was evaluated and processed using the installed Millennium 32 Software (Waters Product). The filtered samples were separated at 27°C on a minibore Phenomenex Luna 5 µm C₁₈ column (dimensions 250 × 4.60 mm) using a one-step linear gradient. The solvents were (A) 0.1% aqueous formic acid and (B) acetonitrile and the elution system was as follows: Initial conditions were 85% A and 15% B with a linear gradient reaching 25% B at t = 12 minutes. This was maintained for 10 minutes after which the programme returned to the initial solvent composition at t = 25 minutes and continued for 10 minutes. The flow rate used was 1 ml/min and the injection volume was 10 µl. The chromatogram was monitored at 254 and 366 nm. In addition, the extract was also spiked with pure

flavonoids, namely rutin and quercitrin, and the chromatograms obtained were compared to the chromatograms of the pure standards of flavonoids, respectively.

Antioxidant activity of MEDL

Total phenolic content

Total phenolic contents (TPC) of all plant extracts were determined using Folin-Ciocalteu reagent as described by Singleton and Rossi [22] with slight modifications. Methanolic solution of the extract in the concentration of 1 mg/ml was used in the analysis. In brief, 1 mg MEDL was extracted with 1 ml 80% methanol containing 1% hydrochloric acid and 1% distilled water at room temperature on the shaker set at 200 rpm for 2 hours. Then, the mixture was centrifuged at $2817 \times g$ for 15 minutes and supernatant decanted into vials. The reaction mixture was prepared by mixing 200 μ l supernatant extract, 400 μ l (0.1 ml/0.9 ml) Folin-Ciocalteu reagent and allowed to stand at room temperature for 5 minutes. Then, 400 μ l sodium bicarbonate (60 mg/ml) solution was added and the mixture was allowed to stand at room temperature for 90 minutes. The absorbance was determined using a spectrophotometer at 725 nm. A calibration curve was generated by using the gallic acid standard optical density, and the levels in the samples were expressed in terms of gallic acid equivalent (GAE) - TPC mg/100. Based on the measured absorbance, the concentration of phenolics was read (mg/ml) from the calibration line.

DPPH radical scavenging activity

The ability of MEDL to induce free radicals scavenging action was determined using the 2, 2-diphenyl-1-picrylhydrazyl (DPPH) assay according to the method of Blois [23] but with modifications involving the use of a high-throughput microplate system. Forty microliters of extracts (1 mg/ml) were mixed with 50 μ l DPPH (FG: 384.32) (1 mM in ethanolic solution) and 150 μ l absolute ethanol on a 96-well microtiter plate in triplicate. The 96-well microtiter plate was shaken for 15 seconds at 500 rpm. Then, the plate was left to stand at room temperature for 30 minutes and the absorbance was recorded at 520 nm.

Superoxide anion radical scavenging

The ability of MEDL to induce the superoxide anion radicals scavenging action was measured according to the method described by Liu et al. [24] with slight modifications. Briefly, the superoxide radicals are produced in phenazine methosulphate - nicotinamide adenine dinucleotide (PMS - NADH) systems via oxidation of NADH and evaluated by the reduction of nitroblue tetrazolium (NBT). In these experiments, the superoxide radicals were produced in 3 ml of Tris-HCl buffer

(16 mM, pH 8) containing 1 ml of NBT (50 μ M), 1 ml NADH (78 μ M) and MEDL (25 - 50 μ g). The reaction was started by adding 1 ml of PMS solution (10 μ M) to the mixture. The reaction mixture was incubated at 25°C for 5 minutes, the absorbance was read at 560 nm using a spectrophotometer (Schimadzu UV-Vis 1700) against blank samples using l-ascorbic acid as a control. Decreased absorbance of the reaction mixture indicated increasing superoxide anion scavenging activity. The percentage inhibition of superoxide anion production was evaluated using the following formula:

$$\% \text{ inhibition} = [(A_C - A_T) / A_C] \times 100$$

where A_C was the absorbance of the control (l-ascorbic acid), and A_T was the absorbance in the presence of MEDL or standards.

Oxygen radical absorbance capacity

The antioxidant capacity of MEDL was also determined using the oxygen-radical absorbance-capacity (ORAC) assay as described by Huang et al. [25], with some modifications. In the assay, 2, 2-azobis (2-amidinopropane) dihydrochloride (AAPH) was dissolved in 10 ml of 75 mM phosphate buffer (pH 7.4) which was prepared daily as peroxy-radical generator. A fluorescein stock solution (1 mM) was prepared in 75 mM phosphate buffer (pH 7.4) and stored in wrapping foil at 5°C. During the analysis, the sodium fluorescein stock solution was diluted 1: 100 000 with 75 mM phosphate buffer (pH 7.4). The microplate wells were filled with 150 μ l of working solution of sodium fluorescein and 25 μ l of Trolox dilution in blank wells, or with 25 μ l of MEDL extracts in sample wells and then was equilibrate by incubating for 10 minutes at 37°C. After the solutions equilibrated, 25 μ l of 240 mM AAPH solution was added to the wells to initiate the reactions. BMG Omega Fluostar Fluorescent Spectrophotometer (Company, state & country) with injector was used with an excitation filter of 485 nm and an emission filter of 520 nm. The fluorescence intensity of each well was then measured kinetically with data taken every one minute for 3 hours. ORAC values were calculated using MARS Data Analysis Reduction Software.

Animals

Male Sprague Dawley rats (180-200 g; 8-10 weeks old) and male ICR mice (25-30 g; 5-7 weeks old) were obtained from the Veterinary Animal Unit, Faculty of Veterinary Medicine, Universiti Putra Malaysia (UPM), Malaysia and were housed at room temperature ($27 \pm 2^\circ\text{C}$; 70 - 80% humidity; 12 h light/darkness cycle) in the Animal Holding Unit (UPM). They were supplied with food and water *ad libitum* from the beginning of the

experiments. The rats were handled in accordance with current UPM guidelines for the care of laboratory animals and the ethical guidelines for investigations of experimental pain in conscious animals. All experiments were conducted between 09.30 and 18.30 h to minimize the effects of environmental changes. The study protocol of the present study was approved by the Animal House and Use Committee, Faculty of Medicine and Health Sciences, UPM (Ethical approval no.: UPM/FPSK/PADS/BR-UUH/00449).

Hepatoprotective assay

Carbon tetrachloride-induced hepatotoxicity test

For this *in vivo* study, male Sprague-Dawley rats weighing 180–200 g were used. The animals were kept in separate cages with *ad libitum* access to food and water in a room with controlled temperature ($22 \pm 3^\circ\text{C}$) and on a 12-hour light/dark cycle with lights switched on at 7:00 a.m. The animals were divided into 6 groups comprising 6 rats in each group as described below:

- Group I: only 10% DMSO orally (p.o.) for 7 days + 50% olive oil on day 7
- Group II: 10% DMSO p.o. for 7 days + CCl_4 on day 7
- Group III: 200 mg/kg silymarin p.o. for 7 days + CCl_4 on day 7
- Group IV, V, and VI: 50, 250, and 500 mg/kg of MEDL p.o. for 7 days + CCl_4 on day 7

Each group received respective dose of the solution and extract once daily for 7 consecutive days. We administered 1 ml/kg of 50% CCl_4 on day 7 to all animals except Group 1 and animals were sacrificed by exposure to diethyl ether 48 hours after administration of CCl_4 . Three millilitres of blood were collected by cardiac puncture. Blood samples were collected into lithium heparinized tubes using a sterile disposable syringe for biochemical analysis. After 20 minutes, the blood was separated by centrifugation for 10 minutes at $1000 \times g$ using a refrigerated centrifuge. Following centrifugation, the plasma was transferred into a clean polypropylene tube and stored at -80°C . Liver was removed from rats and weighed.

Biochemical analysis

Biochemical parameters were assayed according to standard methods. The enzymes alanine aminotransferase (ALT), alkaline phosphatase (ALP), and aspartate aminotransferase (AST) were measured using a Hitachi 902 Automatic Chemical Analyser.

Histopathology

After the liver tissue was fixed in 10% formalin, specimens were embedded in paraffin, sectioned (3–5 μm),

and stained with hematoxylin and eosin. The histochemical sections were evaluated under an electron microscope and evaluated by a pathologist according to the severity of the hepatic injury as described by El-Beshbishy et al. [26] with modifications.

Statistical analysis

All the data are presented as mean \pm SEM. Statistical analysis was performed using GraphPad Prism version 5. Data obtained were analyzed using the one-way analysis of variance and the differences between groups and the control group were determined using Dunnett's post hoc test with $P < 0.05$ as the limit of significance.

Results

Phytochemical screening of MEDL

Phytochemicals screening of *D. linearis* was carried out using two types of samples, which are the powdered leaf and MEDL. From the results obtained, several phytoconstituents were detected. Only saponins, flavonoids, tannins and polyphenolic compounds, steroids, but not alkaloids, were detected in the respective leaves and MEDL. In comparison to MEDL, the leaves of *D. linearis* show no presence of triterpenes at all.

HPLC analysis of MEDL

In an attempt to establish the HPLC profile of MEDL, the extract underwent the HPLC analysis at several wavelengths of which the peaks were clearly separated at the wavelengths of 254 and 366 nm (Figure 1A). At 366 nm, in particular, four major peaks were clearly detected in the chromatogram at the respective retention time (R_T) of 19.76, 20.36, 21.29, and 23.32 minutes, respectively. Further analysis demonstrated that the four peaks showed λ_{max} values in the region of 228–349, 234–350, 254–350 and 264–347 nm, respectively (Figure 1B). The extract spiked with either rutin or quercitrin was found to share the same peak, respectively, indicating their presence in the MEDL (Figure 1A).

Antioxidant activity of MEDL

For total phenolic content, the absorbance values resulted from the reaction between the extract solution and Folin-Ciocalteu reagent was compared to the standard solutions of GAE; the results of the colorimetric analysis of the TPC of the MEDL was 1757.25 ± 29.39 mg GAEs/g extract. According to the standard procedure, any extract with the TPC value of >1000 mg GAEs/g extract is considered to have high TPC value. At the concentration of 200 $\mu\text{g}/\text{ml}$, the MEDL caused $98.94 \pm 1.14\%$ antioxidant activities against DPPH free radical as compared to the standard drug, 200 $\mu\text{g}/\text{ml}$ ascorbic acid. For the superoxide anion radical scavenging, at the concentration of 200 $\mu\text{g}/\text{ml}$, the MEDL caused $93.2 \pm 1.81\%$

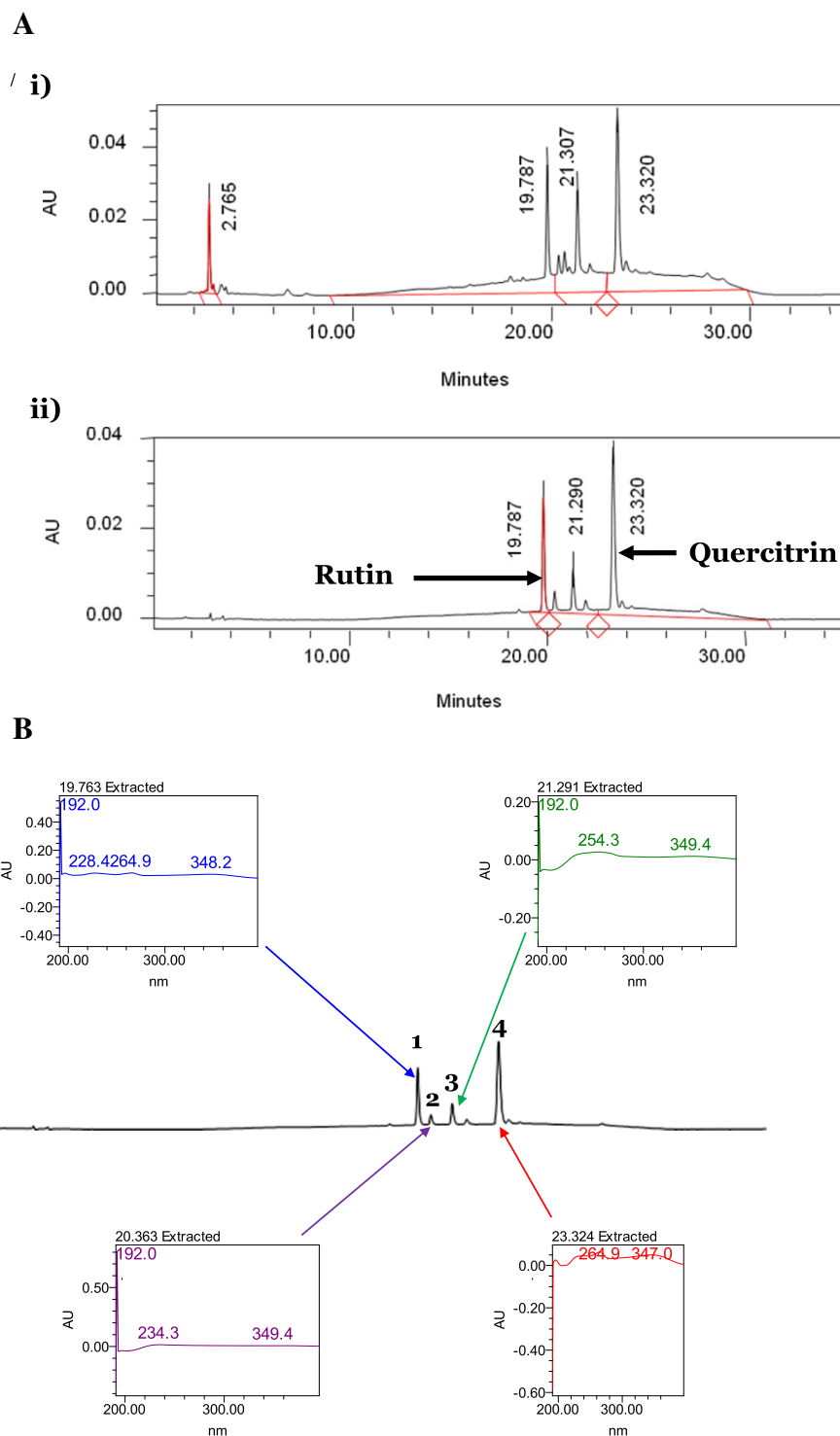


Figure 1 The HPLC analysis of MEDL. **A.** HPLC profile of MEDL at two different wavelength; i) 254 nm, and ii) 366 nm. Attempt was made to standardize the MEDL using various pure flavonoids standard. Based on the HPLC analysis, rutin and quercitrin was detected in the extract. **B.** HPLC profile of MEDL at 366 nm shows four major peaks, labelled as 1, 2, 3 and 4, that was successfully separated. Each peak was represented by their respective UV-Vis spectra with λ_{\max} value of 228-349, 234-350, 254-350 and 264-347 nm, respectively. These ranges of UV-Vis spectra indicated the presence of flavonoids-types of compounds.

antioxidant activities against superoxide anion free radical as compared to the standard drug, 200 µg/ml ascorbic acid. The ORAC value for 200 µg/ml MEDL, which is expressed as µM Trolox Equivalent (TE)/100 g, was 24272.50 ± 2056.53.

In vivo hepatoprotective study

Effect of MEDL on the body weight and liver weight after induction with CCl₄

The body and liver weights of the rats after treatments are shown in Table 1. Overall, there were no significant differences of body weight and liver weight between the different experimental groups compared to the negative control group. However, the rats in the CCl₄-intoxicated group exhibited significantly ($P < 0.05$) higher liver/body weight ratio when compared to rats in the vehicle control group. The administration of MEDL lowered the liver/body weight ratio and this was comparable to the effects observed in silymarin-treated rats.

Histopathological study of the CCl₄-induced hepatotoxic liver with and without pretreatment with MEDL

The livers of the normal control rats pretreated with 10% DMSO followed by treatment with 10% DMSO showed normal histoarchitecture. As seen in Figure 2A, the liver section of normal rat showed distinct hepatic cells with well-preserved cytoplasm, prominent nucleus, hepatocytes radiately arranged around the central vein, and well-defined sinusoidal line. The liver section of rats pretreated with 10% DMSO followed by treatment with CCl₄ showed severe cytoplasmic vacuolation, microvesicular and macrovesicular fatty changes, karyopiknosis, loss of cellular boundaries, infiltration of inflammatory cells around the central vein and in the portal areas, congestion in the sinusoids, and necrosis of the liver cells (Figure 2B). Interestingly, those observations were markedly ameliorated in the groups pretreated with silymarin or MEDL indicated by significant reduction in the number of ballooning-degenerated hepatocytes and significant decreased in the necrosis area (Figure 2D-2F). In the group pretreated with 200 mg/kg silymarin followed by CCl₄

administration, only slight steatosis and infiltration of lymphocytes and, spotty and focal necrosis were observed (Figure 2C). Pretreatment with MEDL exhibited a dose-dependent hepatoprotective effect wherein the group pretreated with 50 mg/kg MEDL exerted moderate necrosis and infiltration of leucocytes with mild steatosis. In the liver section pretreated with 250 mg/kg MEDL a moderate damage to the liver's architecture was seen indicated by the presence of moderate steatosis with some fatty changes and mild leucocytes infiltration around the centrilobular region (Figure 2E). Figure 2F presents liver section of the group pretreated with 500 mg/kg MEDL showing slight necrosis and mild steatosis (Figure 2F). The histopathological scoring of CCl₄-treated rat's liver sections after pre-treatment with MEDL is shown in Table 2. The extract as well as silymarin caused remarkable decrease in the signs of CCl₄-induced toxicity.

Biochemical analysis of blood samples

The changes in serum liver biomarkers are shown in Table 3. As indicated from the results, CCl₄-intoxicated rats showed a significant ($p < 0.05$) increased in the activities of ALT, AST, and ALP compared to the normal control group. Pretreatment of rats with high dose of MEDL or silymarin significantly ($p < 0.05$) decreased the level of serum marker enzymes compared to the CCl₄-intoxicated group.

Discussion

CCl₄ has been widely used in animal models to investigate chemical-induced liver injury. The CCl₄-induced experimental damage involves the formation of free radicals and the occurrence of lipid peroxidation in cellular and organelle membranes [27]. CCl₄ will be metabolized in the liver to form highly reactive trichloromethyl free radicals (-CCl₃), which are responsible in triggering the toxicity processes in the liver. This free radicals are further converted to trichloromethyl peroxy radical (CCl₃OO·) that act as the initiator of lipid peroxidation [28-30]. The presence of excessive amount of free radicals accelerate peroxidative degradation of cellular membrane, which resulted

Table 1 Effect of MEDL on percentage change of body and liver weight in CCl₄- treated rats

Treatment	Dose (mg/kg)	Body weight, BW (g)	Liver weight, LW (g)	LW/BW (%)
Vehicle	-	208.7 ± 5.546	5.852 ± 0.2873	2.797 ± 0.0726
Vehicle + CCl ₄	-	208.9 ± 6.539	10.34 ± 0.2623 ^a	4.969 ± 0.1627 ^a
Silymarin + CCl ₄	200	222.1 ± 4.42	7.830 ± 0.5425 ^b	3.523 ± 0.2324 ^b
MEDL + CCl ₄	50	204.6 ± 1.893	8.672 ± 0.2498 ^b	4.237 ± 0.1902 ^b
	250	220.4 ± 5.541	9.335 ± 0.2631 ^b	4.240 ± 0.1020 ^b
	500	209.3 ± 3.336	8.759 ± 0.4539 ^b	4.181 ± 0.1924 ^b

Values are expressed as means ± S.E.M. of six replicates.

^aSignificant different as compared to the normal control group in the respective column, $p < 0.05$.

^bSignificant different as compared to negative control group in the respective column, $p < 0.05$.

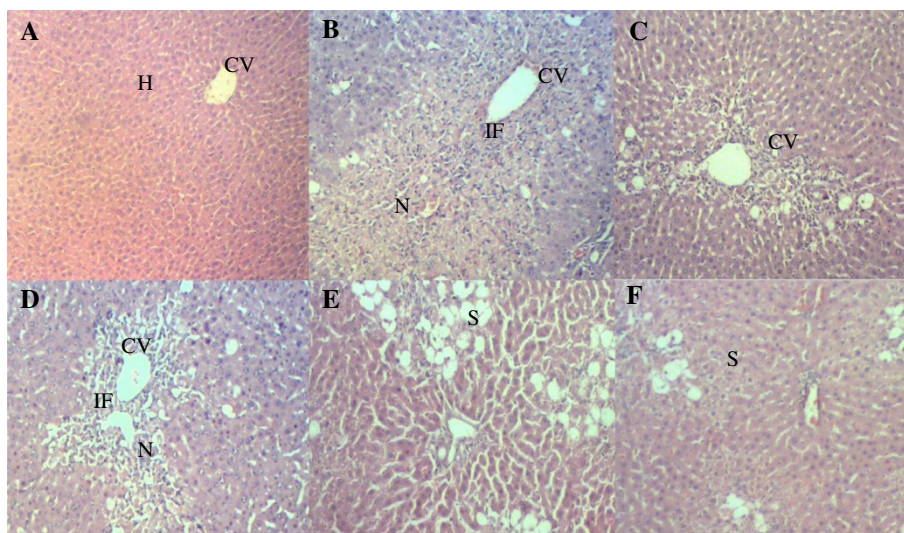


Figure 2 Liver photomicrographs. **A) Vehicle control** showed normal architecture of normal liver histology, central vein (CV), hepatocytes (H). **B) Hepatotoxic liver** after treatment with CCl_4 showing ere necrosis (N) of the hepatocytes in parenchyma region, as well as macrovesicular steatosis (S). **C) Pre-treatment** with 200 mg/kg of Silymarin, positive control preserves normal architecture of the hepatocytes. **D) Pre-treatment** with 50 mg/kg of MEDL showing mild necrosis with mild infiltration of inflammatory cell **E) Pre-treatment** with 250 mg/kg of MEDL showing mild macrovesicular steatosis and absent to few degree of hepatocyte necrosis. **F) Pre-treatment** with 500 mg/kg of MEDL showing macrovesicular steatosis around central vein region. H & E staining, 40 × magnifications.

in the breakdown of cell integrity and the leakages of ALT and AST, and, subsequently, lead to the elevation of serum ALT and AST levels. Moreover, several remarkable pathological characteristics associated with CCl_4 -induced hepatotoxicity, namely fatty liver, cirrhosis and necrosis, could be seen and have been thought to result from the formation ad action of reactive intermediates (i.e trichlorometyl free radicals (CCl_3)) metabolized by the mixed function cytochrome P450 in the endoplasmic reticulum.

One of the ways to measure the extent of hepatic damage is through the determination of the level of cytoplasmic enzymes (i.e. ALT, AST and ALP) that leak into the blood circulation, which is associated with massive centrilobular necrosis, ballooning degeneration and cellular infiltration of the liver [31]. Measurement of ALT is more liver-specific to determine hepatocellular damage [32]. However, measurement of AST is still commonly used to assess liver function because it is a sensitive indicator of

mitochondrial damage, particularly in centrilobular regions of the liver [33]. According to Ahmed and Khater [34], transaminase levels return to normal due to the healing of hepatic parenchyma and the regeneration of hepatocytes. In the present study, CCl_4 -induced increase in the liver/body weight ratio indicating that the liver damage model had been successfully developed. This is further supported by the increase in the level of serum ALT, AST and ALP and histological scoring and microscopic findings. Interestingly, pretreatment with MEDL effectively protected the rodents against CCl_4 -induced hepatic intoxication, which are evidenced by significant reduction in the liver/body weight ratio, levels of serum liver enzymes. Furthermore, it is well established that intoxication with CCl_4 leads to extensive necrosis in the liver centrilobular regions around the central veins [9] and fatty infiltration [35]. Interestingly, the microscopic examination also revealed the ability of pre-treated MEDL to

Table 2 Histopathological scoring of the liver section of CCl_4 -induced hepatic injury rats pretreated with MEDL

Treatment	Dose (mg/kg)	Steatosis	Necrosis	Inflammation	Haemorrhage
Vehicle + Vehicle	-	-	-	-	-
Vehicle + CCl_4		++	+++	++	+
Silymarin + CCl_4	200	+	+	+	-
MEDL + CCl_4	50	++	+	++	-
	250	++	+	+	-
	500	+	+	+	-

The severity of various features of hepatic injury was evaluated based on those following scoring scheme: - normal, + mild effect, ++ moderate effect, +++ severe effect.

Table 3 Effects of MEDL on serum liver biomarkers of CCl₄- treated rats

Treatment	Dose (mg/kg)	ALT (U/L)	AST (U/L)	ALP (U/L)
Vehicle	-	16.00 ± 2.867	93.18 ± 6.239	114.7 ± 7.055
Vehicle + CCl ₄	-	4291 ± 665.3 ^a	3456 ± 633.2 ^a	460.0 ± 49.62 ^a
Silymarin + CCl ₄	200	249.1 ± 30.68 ^b	288.1 ± 25.32 ^b	190.2 ± 19.67 ^b
MEDL + CCl ₄	50	3283 ± 686.5	4291 ± 592.0	350.2 ± 36.80 ^b
	250	1886 ± 134.2 ^b	1853 ± 86.77 ^b	171.8 ± 13.04 ^b
	500	2298. ± 359.9 ^b	1850 ± 228.5 ^b	185.8 ± 10.23 ^b

Values are expressed as means ± S.E.M. of six replicates.

^aSignificant different as compared to the normal control group in the respective column, p < 0.05.

^bSignificant different as compared to negative control group in the respective column, p < 0.05.

reduce inflammation, steatosis and necrosis as indicated by decreased in histological scoring.

As described earlier, the basis of CCl₄-induced liver toxicity lies in its biotransformation to free radicals via the cytochrome P450 system [36]. Since free radicals play important role in CCl₄-induced hepatotoxicity, it seems rational to suggest that compounds with capability to neutralize such free radicals might also possess a hepatoprotective activity. In fact, various natural products (e.g extract of *Artemisia campestris* and pure compound like ginsenosides) with antioxidant potential have been reported to protect against CCl₄-induced hepatotoxicity [36]. In the present study, MEDL was proven to exhibit radicals scavenging activities using various *in vitro* antioxidant models suggesting that the extract perhaps protected the hepatocytes by ameliorating oxidative stress and inhibiting lipid peroxidation. In addition, it is also plausible to add anti-inflammatory activity as another possible mechanism through which MEDL exerts the hepatoprotective activity. This suggestion is based on previous reports that *D. linearis* possess anti-inflammatory activity, which might explained the ability of MEDL to reduce inflammation associated with CCl₄ as observed during microscopic examination.

MEDL has also been shown to contain high TPC value, which have been associated with high antioxidant activity [37,38] as well as anti-inflammatory activity [39,40]. These claims are in line with previous findings by Wu et al. [27] who reported that TPC-rich extract of *Laggera pterodonta* exerts both hepatoprotective and antioxidant activities when assessed using the *in vitro* primary cultured neonatal rat hepatocytes. Adetutu and Owoade [41] also reported that TPC-rich extract of *Hisbiscus sabdariffa* exhibits both hepatoprotective and antioxidant activities when assessed using *in vivo* CCl₄-induced rat hepatotoxic model. The positive correlations between the high antioxidant activity and high TPC have been reported elsewhere [27,41] and are parallel with our findings. Thus, the antioxidant activity attributed by the presence of high concentration of TPC in MEDL could be suggested to play significant role in the observed hepatoprotective activity. Interestingly, one class of compounds that

contributed to the high TPC reading is flavonoids, which have been known to play remarkable role in anti-inflammatory activity. Flavonoids have been detected in MEDL whereas MEDL has been shown to attenuate inflammation in CCl₄-induced liver injury. This seems to suggest the role of anti-inflammatory activity of *D. linearis* as reported previously in enhancing the observed hepatoprotective activity.

Phytochemical analysis of MEDL demonstrated the presence of several phytoconstituents (e.g. flavonoids, tannins, saponins and triterpenes) essentially associated with antioxidant and/or hepatoprotective effects. Earlier studies have claimed that phenolic compounds possess diverse pharmacological effects (i.e. antioxidant, anti-inflammatory, and hepatoprotective) [27,30,42]. MEDL exerted prominent hepatoprotective effects against CCl₄-induced liver damage possibly via the antioxidant- and anti-inflammatory-modulated mechanisms, which is in compliance with the description on the pharmacological properties of phenolic compounds in the aforementioned reports. HPLC analysis of MEDL demonstrated the presence of four major peaks with their λ_{max} value that fall in the region of 192-348.2, 192-349.4, 192-349.4, and 264.9-347 nm, respectively. Based on report made by Tsimogiannis et al. (2007), each of the peaks represents flavonoid-based compounds. According to Tsimogiannis et al. (2007), flavonoids are divided into several subgroups, namely flavonols, flavones, dihydroflavonols, flavanols and flavanones based on the UV-Vis spectra within which they fall. The UV-Vis spectra of flavonoids falls within two absorbance bands, labeled as Band A and Band B wherein Band A represents flavones or flavonols and lies in the range of 310–350 nm or 350–385 nm, respectively. Meanwhile Band B falls in the range of 250 and 290 nm and is much the same in all the aforementioned flavonoid subgroups. As for the flavanones and dihydroflavonols subgroup, Band A falls between 300–330 nm while Band B was detected in the range of 277–295 nm. Interestingly, the presence of low amount of flavonoids in MEDL is concurrent with the HPLC profile of MEDL that shows only four

major peaks. Based on previous report, at least flavonoids such as rutin and quercitrin have been isolated from *D. linearis* and, interestingly, rutin and quercitrin have also been reported to exert antioxidant activity [43,44] and hepatoprotective activity [44,45]. Hence, flavonoids, like rutin and quercitrin, in addition to other polyphenolic constituents may be the prominent bioactive compounds responsible for antioxidant and hepatoprotective activities of MEDL.

It is also noteworthy to highlight on the inconsistency with regards to the presence of low amount of flavonoids in MEDL as detected in the phytochemical screening and the high TPC value of MEDL, and to provide possible explanation for this inconsistency. It is plausible to suggest that the high TPC value is attributed to the presence of other types of flavonoids, particularly, the flavonol 3-*O*- glycosides [46]. This suggestion, which is supported by the UV spectra characteristics of major peaks as detected in the HPLC, is based on the fact that flavonoid glycosides are soluble in methanol:water and acetone:water solvent systems, but not very soluble in water alone [47-49]. With the high presence of saponin in MEDL, the existence of flavonoids glycosides could be attributed to the tensioactive effect of saponins, which are present in relatively high quantities when compared to the flavonoids [50].

Conclusions

The hepatoprotective potential of MEDL were evaluated for the first time. The results obtained demonstrated that MEDL possessed significant protection against CCl₄-induced hepatotoxicity, which could be due, partly, to its high TPC value and, antioxidant and anti-inflammatory properties through scavenging free radicals to ameliorate oxidative stress and inhibit lipid peroxidation. Moreover, phytochemical screening revealed the presence of various phenolic compounds, with rutin and quercitrin identified, which may also contribute to the hepatoprotective activity of MEDL.

Competing interest

The authors declare that there is no competing interest.

Authors' contribution

FHK, FY, SSM and MFFK carried out the animal studies, phytochemical screening, HPLC analysis, biochemical analysis and draft the manuscript. NM involved in the macroscopic and microscopic analysis and helped to draft the manuscript. LKT and MZS involved in the antioxidant study and statistical analysis. MNS participated in the design of the study and involved in the statistical analysis. ZAZ conceived of the study, participated in its design and helped to draft the manuscript. All authors read and approved the final manuscript.

Acknowledgement

This study was supported by the Science Fund Research Grant (Reference no. 06-01-04-SF1127) awarded by the Ministry of Science Technology and Innovation (MOSTI), Malaysia and the Research University Grant Scheme (Reference no. 04-02-12-2019RU) from the Universiti Putra Malaysia, Malaysia.

The authors thanked the Faculty of Medicine and Health Sciences, Universiti Putra Malaysia, Malaysia for providing the facilities to carry out this study.

Author details

¹Department of Biomedical Science, Faculty of Medicine and Health Sciences, Universiti Putra Malaysia, 43400 UPM Serdang, Selangor, Malaysia. ²Department of Pathology, Faculty of Medicine & Health Sciences, Universiti Putra Malaysia, 43400 UPM Serdang, Selangor, Malaysia. ³Integrative Pharmacogenomics Institute (iPROMISE), Level 7, FF3, Universiti Teknologi MARA, Puncak Alam Campus, 42300 Puncak Alam, Selangor, Malaysia.

Received: 10 October 2013 Accepted: 25 March 2014

Published: 4 April 2014

References

1. Kumar CH, Ramesh A, Suresh Kumar JN, Mohammed Ishaq B: **A review on hepatoprotective activity of medicinal plants.** *Int J Pharmaceut Sci Res* 2011, **23**:501-515.
2. Ahsan R, Islam KM, Musaddik A, Haque E: **Hepatoprotective activity of methanol extract of some medicinal plants against carbon tetrachloride-induced hepatotoxicity in rats.** *Eur J Sci Res* 2009, **37**(2):302-310.
3. Chattopadhyay RR: **Possible mechanism of hepatoprotective activity of *Azadirachta indica* leaf extract: part II.** *J Ethnopharmacol* 2003, **89**:217-219.
4. Sargent S: *Liver Diseases: An Essential Guide for Nurses and Health Care Professionals.* United Kingdom: John Wiley & Sons; 2009:352.
5. WHO: *Guidelines on the conservation of medicinal plants.* Gland, Switzerland: The International Union for Conservation of Nature and Natural Resources (IUCN); 1993:1.
6. White CP, Hirsch G, Patel S, Adams F, Peltekian KM: **Complementary and alternative medicine use by patients chronically infected with hepatitis C virus.** *Can J Gastroenterol* 2007, **21**(9):589-595.
7. Bhawna S, Kumar SU: **Hepatoprotective activity of some indigenous plants.** *Int J Pharm Tech Res* 2009, **4**:1330-1334.
8. Babu BH, Shylesh BS, Padikkala J: **Antioxidant and hepatoprotective effect of *Acanthus ilicifolius*.** *Fitoterapia* 2001, **72**:272-277.
9. Bhoopat L, Srichairatanakool S, Kanjanapothi D, Taesotikul T, Thananchai H, Bhoopat T: **Hepatoprotective effects of lychee (*Litchi chinensis* Sonn.): a combination of antioxidant and anti-apoptotic activities.** *J Ethnopharmacol* 2011, **136**(1):55-66.
10. Fakurazi S, Sharifudin SA, Arulseelan P: ***Moringa oleifera* hydroethanolic extracts effectively alleviate acetaminophen-induced hepatotoxicity in experimental rats through their antioxidant nature.** *Molecules* 2012, **17**(7):8334-8350.
11. Derus ARM: *Pengenalan dan Penggunaan Herba Ubatan.* Kuala Lumpur: Multiple triple vision; 1998:75.
12. Zakaria ZA, Ghani ZD, Nor RN, Gopalan HK, Sulaiman MR, Jais AM, Somchit MN, Kader AA, Ripin J: **Antinociceptive, anti-inflammatory, and antipyretic properties of an aqueous extract of *Dicranopteris linearis* leaves in experimental animal models.** *J Nat Med* 2008, **62**(2):179-187.
13. Chin WY: **Ferns and fern allies.** In *The Encyclopedia of Malaysia: plants.* Edited by Soepadmo E. Singapore: Didier Millet; 1998:44.
14. Hussaini J, Othman NA, Abdulla MA, Majid NA, Farooq HM, Ismail S: **Gastroprotective effects of *Dicranopteris linearis* leaf extract against ethanol-induced gastric mucosal injury in rats.** *Sci Res Essays* 2012, **7**(18):1761-1767.
15. Zakaria ZA: **Free radical scavenging of some plants in Malaysia.** *Iranian J Pharmacol Ther* 2007, **6**:87-91.
16. Lai HY, Lim YY: **Evaluation of antioxidant activities of the methanolic extracts of selected ferns in Malaysia.** *Int J Environ Sci Tech* 2011, **2**(6):442-447.
17. Zakaria ZA, Mohamed AM, Mohd Jamil NS, Rofiee MS, Fatimah CA, Mat Jais AM, Sulaiman MR, Somchit MN: **In vitro anticancer activity of various extracts of the Malaysian, available but neglected, plants (*Muntingia calabura* and *Dicranopteris linearis*) against MCF-7 and HT-29 cancer cell lines.** *E-Pharmanexus* 2008, **1**(1):10-17.
18. Sadasivan S, Latha PG, Sasikumar JM, Rajashekarana S, Shyamal S, Shine VJ: **Hepatoprotective studies on *Hedyotis corymbosa* (L.) Lam.** *J Ethnopharmacol* 2006, **106**:245-249.
19. Dash DK, Yeligar VC, Nayak SS, Ghosh T, Rajalingam D, Sengupta P: **Evaluation of hepatoprotective and antioxidant activity of *Ichnocarpus frutescens***

- (Linn.) R.Br. on paracetamol-induced hepatotoxicity in rats. *Trop J Pharm Res* 2007, **6**:755–765.
20. Ikhirri K, Boureima D, Dan-Kouloudo D: Chemical screening of medicinal plants used in the traditional pharmacopoeia of Niger. *Int J Pharmacog* 1992, **30**:251–262.
 21. Yahya F, Mamat SS, Kamarolzman MFF, Seyedan AA, Jakius KF, Mahmood ND, Shahril MS, Suhaili Z, Mohtarrudin N, Susanti D, Somchit MN, Teh LK, Salleh MZ, Zakaria ZA: Hepatoprotective Activity of Methanolic Extracts of Leaves of *Bauhinia purpurea* in Paracetamol-induced Hepatic Damage in Rats. *Evid-Based Compliment Alternat Med* 2012, **2012**:636580. 10.1155/2013/636580.
 22. Singleton VL, Rossi JA Jr: "Colorimetry of total phenolics with phosphomolybdic-phosphotungstic acid reagents". *Am J Enol Vitic* 1965, **16**:144–158.
 23. Blois MS: Antioxidant determinations by the use of a stable free radical. *Nature* 1958, **18**:1199–1200.
 24. Liu F, Ooi VE, Chang ST: Free radical scavenging activities of mushroom polysaccharide extracts. *Life Sci* 1997, **60**:763–771.
 25. Huang D, Ou B, Hampsch-Woodill M, Flanagan JA, Prior RL: High throughput assay of oxygen radical absorbance capacity (ORAC) using a multichannel liquid handling system coupled with a microplate fluorescence reader in 96-well format. *J Agric Food Chem* 2002, **5**:4437–4444.
 26. El-Beshbishy HA, Mohamadin A, Nagy A, Abdel-Naim A: Amelioration of tamoxifen-induced liver injury in rats by grape seed extract, black seed extract and curcumin. *Indian J Exp Biol* 2010, **48**:280–288.
 27. Wu Y, Yang L, Wang F, Wu X, Zhou C, Shi S, Mo J, Zhao Y: Hepatoprotective and antioxidative effects of total phenolics from *Lagdera pterodonta* on chemical-induced injury in primary cultured neonatal rat hepatocytes. *Food Chem Toxicol* 2007, **45**(8):1349–1355.
 28. Hsiao G, Shen MY, Lin KH, Lan MH, Wu LY, Chou DS, Lin CH, Su CH, Sheu JR: Antioxidative and hepatoprotective effects of *Antrodia camphorata* extract. *J Agric Food Chem* 2003, **51**(11):3302–3308.
 29. Jain A, Soni M, Deb L, Jain A, Rout SP, Gupta VB, Krishna KL: Antioxidant and hepatoprotective activity of ethanolic and aqueous extracts of *Momordica dioica* Roxb. leaves. *J Ethnopharmacol* 2008, **115**(1):61–66.
 30. Ranawat L, Bhatt J, Patel J: Hepatoprotective activity of ethanolic extracts of bark of *Zanthoxylum armatum* DC in CCl₄-induced hepatic damage in rats. *J Ethnopharmacol* 2010, **127**(3):777–780.
 31. Ramaiah SK: A toxicologist guide to the diagnostic interpretation of hepatic biochemical parameters. *Food Chem Toxicol* 2007, **45**(4):1551–1557.
 32. Shyamal S, Latha PG, Shine VJ, Suja SR, Rajasekharan S, Devi TG: Hepatoprotective effects of *Pittosporum neelgherense* Wight&Arn., a popular Indian ethnomedicine. *J Ethnopharmacol* 2006, **107**:151–155.
 33. Panteghini M: Aspartate aminotransferase isoenzymes. *Clin Biochem* 1990, **23**(4):311–319.
 34. Ahmed MB, Khater MR: Evaluation of the protective potential of Ambrosia maritime extract on acetaminophen-induced liver damage. *J Ethnopharmacol* 2001, **75**:169–174.
 35. Naik SR, Panda VS: Antioxidant and hepatoprotective effects of Ginkgo biloba phytosomes in carbon tetrachloride-induced liver injury in rodents. *Liver Int* 2007, **27**(3):393–399.
 36. Gao J, Sun C-R, Yang J-H, Shi J-M, Du Y-G, Zhang Y-Y, Li J-H, Wan H-T: Evaluation of the hepatoprotective and antioxidant activities of *Rubus parvifolius* L. *J Zhejiang Univ Sci B* 2011, **12**(2):135–142.
 37. Korekar G, Stobdan T, Arora R, Yadav A, Singh SB: Antioxidant capacity and phenolics content of apricot (*Prunus armeniaca* L.) kernel as a function of genotype. *Plant Foods Hum Nutr* 2011, **66**(4):376–383.
 38. Stanković MS: Total phenolic content, flavonoid concentration and antioxidant activity of *Marrubium peregrinum* L. extracts. *Kragujevac J Sci* 2011, **33**(2011):63–72.
 39. Sone Y, Moon JK, Mai TT, Thu NN, Asano E, Yamaguchi K, Otsuka Y, Shibamoto T: Antioxidant/anti-inflammatory activities and total phenolic content of extracts obtained from plants grown in Vietnam. *J Sci Food Agric* 2011, **91**:2259–2264.
 40. Alhakmani F, Kumar S, Khan SA: Estimation of total phenolic content, in-vitro antioxidant and anti-inflammatory activity of flowers of *Moringa oleifera*. *Asian Pac J Trop Biomed* 2013, **3**:623–627.
 41. Adetutu A, Owoade AO: Hepatoprotective and antioxidant effect of Hibiscus Polyphenol Rich Extract (HPE) against carbon tetrachloride (CCl₄) -induced damage in rats. *Br J Medic Med Res* 2013, **3**(4):1574–1586.
 42. Oh H, Kim DH, Cho JH, Kim YC: Hepatoprotective and free radical scavenging activities of phenolic petrosins and flavonoids isolated from *Equisetum arvense*. *J Ethnopharmacol* 2004, **95**(2–3):421–424.
 43. Boyle SP, Dobson VL, Duthie SJ, Hinselwood DC, Kyle JA, Collins AR: Bioavailability and efficiency of rutin as an antioxidant: a human supplementation study. *Eur J Clin Nutr* 2000, **54**(10):774–782.
 44. Hubert DJ, Dawe A, Florence NT, Gilbert KD, Angele TN, Buonocore D, Finzi PV, Vidari G, Bonaventure NT, Marzatico F, Paul MF: In vitro hepatoprotective and antioxidant activities of crude extract and isolated compounds from *Ficus gnaphalocarpa*. *Inflammopharmacology* 2011, **19**(1):35–43.
 45. Domitrović R, Jakovac H, Vasiljev Marchesi V, Vladimir-Knežević S, Cvijanović O, Tadić Z, Romić Z, Rahelić D: Differential hepatoprotective mechanisms of rutin and quercetin in CCl(4)-intoxicated BALB/cN mice. *Acta Pharmacol Sin* 2012, **33**(10):1260–1270.
 46. Raja DP, Manickam VS, de Britto AJ, Gopalakrishnan S, Ushioda T, Satoh M, Tanimura A, Fuchino H, Tanaka N: Chemical and chemotaxonomical studies on *Dicranopteris* species. *Chem Pharm Bull* 1995, **43**:1800–1803.
 47. Vilegas W, Sanommiya M, Rastrelli L, Pizzi C: Isolation and structure elucidation of two new flavonoid glycosides from the infusion of *Maytenus aquifolium* leaves. Evaluation of the antiulcer activity of the infusion. *J Agri Food Chem* 1999, **47**:403–406.
 48. Yeşilada E, Takaishi Y: A saponin with anti-ulcerogenic effect from the flowers of *Spartium junceum*. *Phytochemistry* 1999, **51**:903–908.
 49. Yadav S, Bhadoria BK: Two dimeric flavonoids from *Bauhinia purpurea*. *Indian J Chem* 2005, **44B**:2604–2607.
 50. Zakaria ZA, Abdul Hisam EE, Rofiee MS, Norhafizah M, Somchit MN, Teh LK, Salleh MZ: Antiulcer activity of the aqueous extract of *Bauhinia purpurea* leaf. *J Ethnopharmacol* 2011, **137**(2):1047–1054.

doi:10.1186/1472-6882-14-123

Cite this article as: Kamisan et al.: Effect of methanol extract of *Dicranopteris linearis* against carbon tetrachloride- induced acute liver injury in rats. *BMC Complementary and Alternative Medicine* 2014 **14**:123.

Submit your next manuscript to BioMed Central and take full advantage of:

- Convenient online submission
- Thorough peer review
- No space constraints or color figure charges
- Immediate publication on acceptance
- Inclusion in PubMed, CAS, Scopus and Google Scholar
- Research which is freely available for redistribution

Submit your manuscript at
www.biomedcentral.com/submit

