

Effect of Prefrontal Repetitive Transcranial Magnetic Stimulation in Obsessive-Compulsive Disorder: A Preliminary Study

Benjamin D. Greenberg, M.D., Ph.D., Mark S. George, M.D., Juliet D. Martin, B.S., Jonathan Benjamin, M.D., Thomas E. Schlaepfer, M.D., Margaret Altemus, M.D., Eric M. Wassermann, M.D., Robert M. Post, M.D., and Dennis L. Murphy, M.D.

***Objective:** Prefrontal mechanisms are implicated in obsessive-compulsive disorder. The authors investigated whether prefrontal repetitive transcranial magnetic stimulation influenced obsessive-compulsive disorder symptoms. **Method:** Twelve patients with obsessive-compulsive disorder were given repetitive transcranial magnetic stimulation (80% motor threshold, 20 Hz/2 seconds per minute for 20 minutes) to a right lateral prefrontal, a left lateral prefrontal, and a midoccipital (control) site on separate days, randomized. The patients' symptoms and mood were rated for 8 hours afterward. **Results:** Compulsive urges decreased significantly for 8 hours after right lateral prefrontal repetitive transcranial magnetic stimulation, but there were nonsignificant increases in compulsive urges after repetitive transcranial magnetic stimulation of the midoccipital site. A shorter-lasting (30 minutes), modest, and nonsignificant reduction in compulsive urges occurred after left lateral prefrontal repetitive transcranial magnetic stimulation. Mood improved during and 30 minutes after right lateral prefrontal stimulation. **Conclusions:** These preliminary results suggest that right prefrontal repetitive transcranial magnetic stimulation might affect prefrontal mechanisms involved in obsessive-compulsive disorder.*

(Am J Psychiatry 1997; 154:867-869)

Functional neuroimaging studies have consistently observed prefrontal hypermetabolism or hyperperfusion in untreated patients with obsessive-compulsive disorder and after provocation of obsessive-compulsive symptoms. Medication or neurosurgical treatment normalizes prefrontal hyperactivity (1, 2).

Directly altering prefrontal activity with repetitive transcranial magnetic stimulation might affect obsessive-compulsive disorder symptoms. A pulsed magnetic field induces electrical currents in cortical structures, influencing their function. Repetitive transcranial magnetic stimulation of the motor cortex produces muscle potentials or movement, occipital repetitive transcranial magnetic stimulation produces phosphenes or visual extinction, and stimulation of Broca's area produces speech arrest (3). Prefrontal repetitive transcranial magnetic stimulation can affect memory (3) and mood (4) in healthy individuals and may act as an antidepressant (5).

We investigated whether prefrontal repetitive transcranial magnetic stimulation influenced obsessive-compulsive disorder symptoms.

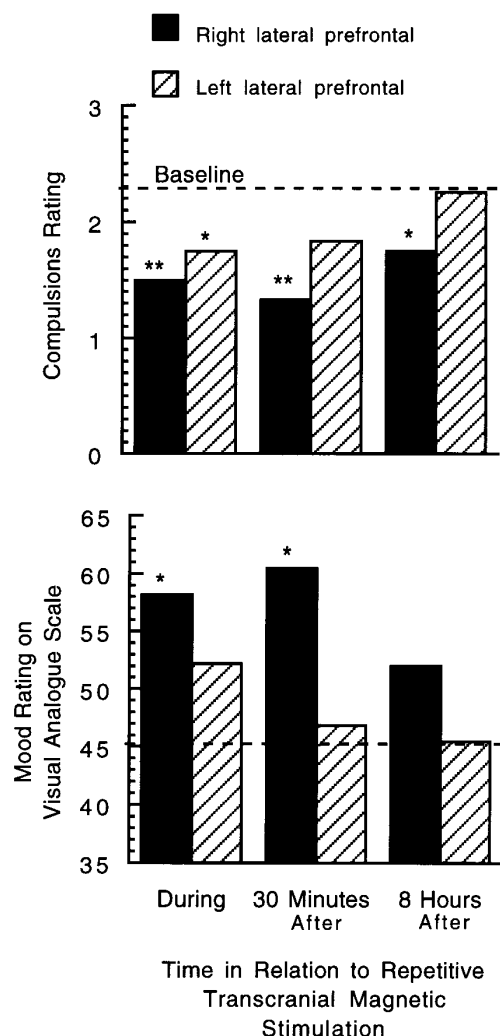
METHOD

Twelve right-handed patients with DSM-III-R-diagnosed obsessive-compulsive disorder participated in the study. Six were women, and the mean age of all 12 patients was 36.9 years (SD=10.2). Four were unmedicated; eight remained on stable regimens of paroxetine (three patients were taking 30-40 mg/day) or fluoxetine (five patients were taking 40-100 mg/day). The medicated patients had been receiving the drugs for at least 8 weeks. Mean Yale-Brown Obsessive Compulsive Scale, Hamilton Depression Rating Scale, and Hamilton Anxiety Rating Scale scores were 19.8 (SD=9.7), 9.1 (SD=7.5), and 8.6 (SD=6.3), respectively. Six patients met criteria for current or past major depression. All gave written informed consent. Because of the seizure risk induced by repetitive transcranial magnetic stimulation, individuals with a history of seizure or head trauma and those receiving medications that lower the seizure threshold (e.g., tricyclics) were excluded from study. Patients were told that their symptoms might remain unchanged, worsen, or improve after stimulation.

We used a Cadwell High Speed Magnetic Stimulator and a figure-eight-shaped coil (3) to administer the repetitive stimulation (80% motor threshold, 20 Hz/2 seconds per minute for 20 minutes). Stimulation sites were located in relation to the optimal left motor cortex site for producing a right abductor pollicis brevis contraction with single pulses. The left lateral prefrontal site was de-

Received May 15, 1996; revision received Oct. 28, 1996; accepted Nov. 5, 1996. From the Laboratory of Clinical Science and the Biological Psychiatry Branch, NIMH, and the Human Motor Control Section, National Institute of Neurological Diseases and Stroke, Bethesda, Md. Address reprint requests to Dr. Greenberg, Laboratory of Clinical Science, NIMH, Bldg. 10, Rm. 3D41, 10 Center Dr., MSC 1264, Bethesda, MD 20892-1264; bdg@helix.nih.gov (e-mail).

FIGURE 1. Effect of Repetitive Transcranial Magnetic Stimulation on Compulsive Urges and Mood in 12 Patients With Obsessive-Compulsive Disorder^a



^aSignificant difference between baseline and poststimulation ratings according to repeated measures analysis of variance: * $p < 0.05$, ** $p < 0.01$.

fined as 5 cm anterior and 2 cm inferior to this; the right lateral prefrontal site was the contralateral site equidistant from the midline. The occipital cortex site was midline, 10 cm posterior to the abductor pollicis brevis site. The motor threshold, determined individually by sequentially reducing pulse intensity, was set at 2% below the value at which five successive pulses produced no visible abductor pollicis brevis contraction. Thirty minutes after each session, patients left the clinic, allowing expression of situationally dependent obsessive-compulsive disorder symptoms.

For symptom ratings we used a modified National Institute of Mental Health self-rating scale, including an anxiety subscale, two 7-point obsession and compulsion ratings, and a 100-mm visual analogue scale describing mood (worst ever to best ever), administered by a researcher blind to stimulation site.

For statistical analysis we used repeated measures analysis of variance (ANOVA) for site, with Huynh-Feldt adjustments for nonsphericity, and single-degree-of-freedom contrasts to evaluate specific time-dependent changes. Repeated measures ANOVA of baseline ratings revealed no significant carryover effects.

RESULTS

All patients completed the study. Discomfort (rated with a 100-mm visual analog scale) was nonsignificantly higher after right and left lateral prefrontal than after occipital repetitive transcranial magnetic stimulation. Two patients reported mild headache 1–3 hours after stimulation. One experienced a patchy vibratory central vision distortion during each occipital stimulation train.

Compulsive urges decreased from baseline after right lateral prefrontal repetitive transcranial magnetic stimulation ($F = 7.00$, $df = 3, 33$, $p < 0.01$); specifically, during stimulation ($F = 13.34$, $df = 1$, $p < 0.01$), 30 minutes afterward ($F = 17.76$, $df = 1$, $p < 0.01$), and 8 hours afterward ($F = 7.89$, $df = 1$, $p < 0.02$) (figure 1). Compulsions were modestly but not significantly decreased after left lateral prefrontal stimulation ($F = 2.85$, $df = 3, 33$, $p = 0.05$), mainly reflecting a reduction during stimulation ($F = 5.56$, $df = 1$, $p < 0.03$), but not later. Compulsions increased nonsignificantly after occipital stimulation ($F = 3.19$, $df = 3, 33$, $p = 0.07$), maximally 8 hours afterward ($F = 4.13$, $df = 1$, $p = 0.07$). Obsessive thoughts did not change significantly after stimulation.

There was a modest increase in positive mood after right lateral prefrontal repetitive transcranial magnetic stimulation ($F = 2.85$, $df = 3, 33$, $p = 0.05$), mainly during stimulation ($F = 5.65$, $df = 1$, $p < 0.03$) and 30 minutes afterward ($F = 6.69$, $df = 1$, $p < 0.02$) (figure 1). Left lateral prefrontal and occipital stimulation did not affect mood. Positive mood ratings were higher after right than after left lateral prefrontal stimulation 30 minutes ($F = 5.65$, $df = 1, 11$, $p < 0.01$) and 8 hours ($F = 8.52$, $df = 1, 11$, $p < 0.05$) after stimulation.

DISCUSSION

Prefrontal repetitive transcranial magnetic stimulation had modest, site-dependent effects on compulsions, which were reduced during right lateral prefrontal stimulation and for at least 8 hours afterward. In contrast, effects of left lateral prefrontal and occipital stimulation on compulsive urges were transient and nonsignificant. The improved mood after right lateral prefrontal stimulation is consistent with effects in healthy volunteers (4).

Obsessions appeared unaffected by repetitive transcranial magnetic stimulation. Although compulsions were reduced more than obsessions in one neurosurgical treatment series (6), obsessions and compulsions usually respond equally to neurosurgery (2).

Neuroanatomical influences in obsessive-compulsive disorder may be lateralized. In one study (7), right and left orbitofrontal perfusion had opposite correlations with symptom provocation. Other studies (1, 8) suggested that obsessive-compulsive disorder treatment produces predominantly right-sided changes in cerebral activity or in correlations between prefrontal and basal ganglia metabolism. A retrospective analysis of capsu-

lotomy effects (P. Mindus, personal communication) found improvement after specific right-sided but not left-sided lesions.

Although placebo effects were possible, we found no significant effects of repetitive transcranial magnetic stimulation at an occipital site not implicated in obsessive-compulsive disorder, and we found few effects after left compared with right prefrontal stimulation. Moreover, neither patients nor investigators anticipated the lateralized effect on compulsions. The effects were statistically significant but relatively small in magnitude. Whether larger effects are possible in more severely affected patients, or with different site placement and stimulus measures, remains to be further explored. Direct stimulation of the orbitofrontal cortex, an area consistently implicated in obsessive-compulsive disorder, is not possible with this technique. Precise site localization likely varied because we used a standard distance from the motor cortex.

Since most studies find hyperfrontality in obsessive-compulsive disorder, our results suggest that right prefrontal stimulation possibly disrupted compulsion-related activity. Other measures of prefrontal function could provide important confirmatory information in subsequent stimulation investigations. These preliminary findings suggest that repetitive transcranial magnetic stimulation, apparently a safe probe of cortical mechanisms, might have affected structures influencing obsessive-compulsive disorder symptoms.

REFERENCES

1. Hoehn-Saric R, Benkelfat C: Structural and functional brain imaging in OCD, in *Current Concepts in OCD*. Edited by Hollander E, Zohar J, Marazziti D. New York, John Wiley & Sons, 1994, pp 183–211
2. Mindus P, Rauch SL, Nyman H, Baer L, Edman G, Jenike M: Capsulotomy and cingulotomy as treatments for malignant obsessive compulsive disorder: an update. *Ibid*, pp 244–276
3. Pascual-Leone A, Grafman J, Cohen LG, Roth BJ, Hallett M: Transcranial magnetic stimulation: a new tool for the study of higher cognitive function in humans, in *Handbook of Neuropsychology*. Edited by Grafman J, Boller N. Amsterdam, Elsevier, 1997, pp 267–290
4. George MS, Wasserman EM, Williams WA, Steppel J, Pascual-Leone A, Basser P, Hallett M, Post RM: Changes in mood and hormone levels after rapid-rate transcranial magnetic stimulation (rTMS) of the prefrontal cortex. *J Neuropsychiatry Clin Neurosci* 1996; 8:172–180
5. Pascual-Leone A, Rubio B, Pallardo F, Catala MC: Beneficial effect of rapid-rate transcranial magnetic stimulation of the left dorsolateral prefrontal cortex in drug-resistant depression. *Lancet* 1996; 348:233–238
6. Bridges PK, Goktepe EO, Maratos J, Browne A, Young L: A comparative review of patients with obsessional neurosis and with depression treated by psychosurgery. *Br J Psychiatry* 1973; 123:663–674
7. Rauch SL, Jenike MA, Alpert NM, Baer L, Breiter HC, Savage CR, Fischman AJ: Regional cerebral blood flow measured during symptom provocation in obsessive-compulsive disorder using oxygen 15-labeled carbon dioxide and positron emission tomography. *Arch Gen Psychiatry* 1994; 51:62–70
8. Schwartz JM, Stoessel PW, Baxter LRJ, Martin KM, Phelps ME: Systematic changes in cerebral glucose metabolic rate after successful behavior modification treatment of obsessive-compulsive disorder. *Arch Gen Psychiatry* 1996; 53:109–113