

Effect of *Silybum marianum* on acute hepatic damage caused by carbon tetrachloride in rats

M. Ozturk^{1*}, M. Akdogan², I. Keskin³, A.N. Kisioglu¹, S. Oztas⁴ and K. Yildiz⁵,

¹Department of Public Health, Faculty of Medicine, Suleyman Demirel University, Isparta, Turkey

²Department of Biochemistry, Faculty of Medicine, Sakarya University, Sakarya, Turkey

³Department of Histology and Embryology, Faculty of Medicine, Selcuk University, Konya, Turkey

⁴Department of Midwifery, Faculty of Health Sciences, Suleyman Demirel University, Isparta, Turkey

⁵Chairman of Public Health Laboratory, Provincial Health Directorate, Isparta, Turkey

Abstract

The study was designed to test the efficiency of *Silybum marianum* in different doses to treat carbon tetrachloride (CCl₄) induced liver damage. Thirty-five Wistar albino rats were divided randomly into five groups as follows: Control Group: 4 ml saline; CCl₄ Group: 4 ml saline plus 2 ml/kg CCl₄; 2.5% Infusion Group: 2 ml/kg CCl₄ plus 2.5% infusion of *Silybum marianum*; 5% Infusion Group: 2 ml/kg CCl₄ plus 5% infusion of *Silybum marianum*; 10% Infusion Group: 2 ml/kg CCl₄ plus 10% infusion of *Silybum marianum*. Infusions were given once a day for 5 consecutive days. CCl₄ was administered intraperitoneally (2 ml/kg) on days 2 and 3. At the end of the 5th day, animals sacrificed and their bloods were drawn for biochemical tests and liver samples were taken for histopathologic investigation. CCl₄ caused to increase in glucose and to decrease in albumin, total cholesterol and triglyceride levels. *Silybum Marianum* treatment improved these changes. All liver function tests were elevated by of CCl₄ administration and than reduced, by *Silybum Marianum* treatment. CCl₄ caused to hepatocyte degeneration, central ven dilatation, congestion, and to increase in the number of Kupffer cells and histopathological injury scores. Treatment with *Silybum marianum* infusion showed slightly preventive effect on CCl₄ induced liver damage by biochemically and histologically.

Key words: *Silybum marianum*, carbon tetrachloride, hepatic damage, hepatoprotection.

Accepted January 17 2012

Introduction

Silybum marianum (*Cardus marianus*), commonly known as milk thistle or St. Mary thistle or deve diken (Turkish), is one of the oldest and thoroughly researched plants in the treatment of liver diseases [1]. The active constituent of milk thistle is silymarin, a mixture of flavonolignans comprised of 4 isomers: silibinin, isosilibinin, silichristin, and silidianin. Most supplements are standardized according to their silibinin (often called silybin) content, the main component of the silymarin [2]. Silymarin/silybin has been currently used for the treatment of cirrhosis, chronic hepatitis and liver diseases associated with alcohol consumption and environmental toxin exposure [3]. In the United States, milk thistle is commonly used to treat viral infections and cirrhosis of the liver [4] and the most frequently sold herbal products [2]. Phytoterapy or herbal medicine has also been used for several centuries in eastern cultures [5]. *Silybum marianum* was cited in 17th century in a medical dictionary written in Ottoman Turkish [6].

Isparta, a city in the mediterranean region of Turkey, is rich in herbal plants [7] including *Silybum marianum* used for herbal medicine. Therefore, we aimed to test hepatoprotective effect of *Silybum marianum*, grown from this region, on CCl₄ induced liver damage in rats.

Material and Methods

Animals

Adult Male Wistar albino rats weighing about 200–250 g were used in the present study. All animal fed with standard laboratory feed and water *ad libitum*. All experiments were carried out according to the guidelines for the care and use of experimental animals, and approved by the Animals Ethical Committee of Süleyman Demirel University (Number: 27.07. 2010- 01).

Drug and chemicals

Carbon tetrachloride (CCl₄), (BDH Chemicals, England) and *Silybum marianum* feeds (Semazen-Arzen Herbal Drug, Cosmetic and Food Company, Isparta-Turkey) were used in the experiments.

Infusion preparation

Boiling water (100 ml for each dose) was poured over ground seeds of *Silybum marianum* (2.5, 5 and 10 g) and left to brew for 10-15 min [8]. The cooled and filtered infusion was given to rats by gavage. Infusion was prepared daily. CCl₄ was given i.p. (2 ml/kg) to the rats.

Animal Study Protocol

Thirty-five animals were used in this study and divided randomly into five groups (7 animals for each). The groups were organised as follows: Control Group: 4 ml saline; CCl₄ Group: 4 ml saline plus CCl₄; 2.5% Infusion Group: CCl₄ plus 2.5% infusion of *Silybum marianum*; 5% Infusion Group: CCl₄ plus 5% infusion of *Silybum marianum* and 10% Infusion Group: CCl₄ plus 10% infusion of *Silybum marianum*. Only one of the rats in the 2.5% infusion group died during the experiment.

Saline and infusions were daily given by gavage with the amount of 4 ml. Infusions were given daily for 5 consecutive days. Two hours after the infusion treatments, 50% CCl₄ (2 ml/kg of bw) was administered intraperitoneally on days 2 and 3 [9,10]. End of the 5th day, the rats were decapitated under anesthesia (Ketamine 90 mg/kg + Xylazine 10 mg/kg). The bloods were drawn from abdominal aorta for biochemical tests. Liver was taken for histopathologic investigation.

Biochemical Assessments

Sera were obtained for detection of liver function tests: aspartate aminotransferase (AST), alanine transaminase (ALT), alkaline phosphatase (ALP) and some biochemical parameters (glucose, albumin, uric acid, urea, creatinine and total cholesterol). Olympus AU2700 autoanalyser (Japan) was used for biochemical detections by commercial kits.

Histopathological Analysis

The liver tissues specimens taken from the rats were fixed

in Buffered Neutral Formalin 10%. The liver tissues were blocked in paraffin, sectioned at 5 - 10 microns thickness with a microtome and stained with Hematoxylin-Eosin; Microscopic images were taken with Olympus BX51 light microscope and captured digitally with Olympus DP2-BSW imaging program. The histopathological scoring of liver sections was modified from French et al. [11] as follows: 0 = no visible change/damage or; 1= mild change/damage (<25% of tissue); 2 = moderate change/damage (<25–50% of the tissue); 3 = extensive or global change/damage. The morphology of any lesions observed was interpreted according to Geller et al. [12]. Different cellular, vascular and morphological changes were evaluated. These parameters were included: sinusoidal or central ven dilatation and congestion, enlargement and inflammation of periportal area, proliferation of bile duct or Kupffer cells, degeneration, pleomorphism and steatosis of liver cells and picnotic hepatocyte nuclei. The histopathological examinations were blinded to the study treatments.

Statistical Analysis

Statistical analyses were performed using the SPSS for Windows Version 9.05 program. Biochemical results were reported as mean ± standart deviation (SD) and histopathologic results were given as median (min-max). The pairwise comparisons were conducted using the “Mann-Whitney U” test. The significance level was accepted as p<0.05.

Results

As seen in Table 1, all liver function tests were elevated by of CCl₄ administration and reduced by *Silybum marianum* treatment. Among these reductions of the tests, only AST were significant (p<.05) and dose dependent manner.

Table 1. Liver function tests of the groups (Mean ± SD).

Parameters	Control (n=7)	CCl ₄ (n=7)	2.5% Infusion (n=6)	5% Infusion (n=7)	10% Infusion (n=7)
AST (U/L)	139.1 ± 28.8	161.4 ± 34.7	123.5 ± 12.6 ^a	119.1 ± 8.9 ^a	143.9 ± 21.2
ALT (U/L)	59.3 ± 3.6	104.0 ± 86.6	67.2 ± 11.1	57.1 ± 5.4	78.7 ± 33.6
ALP (U/L)	132.7 ± 22.8	141.8 ± 50.3	125.0 ± 37.4	119.4 ± 31.0	148.6 ± 49.1

Mann-Whitney U test, a: p<0.05 compared to CCl₄ group.

Table 2. Some biochemical parameters of the groups (Mean \pm SD).

Parameters*	Control (n=7)	CCl ₄ (n=7)	2.5% Infusion (n=6)	5% Infusion (n=7)	10% Infusion (n=7)
Glucose (mg/dl)	208 \pm 30	265 \pm 58	235 \pm 67	236 \pm 25	207 \pm 57
Albumin (g/dL)	3.71 \pm 0.13	3.37 \pm 0.29 ^a	3.78 \pm 0.19 ^b	3.43 \pm 0.17	3.37 \pm 0.22
Creatinine (mg/dL)	0.34 \pm 0.08	0.37 \pm 0.12	0.36 \pm 0.12	0.31 \pm .04	0.33 \pm 0.05
Uric acid (mg/dL)	0.74 \pm 0.10	2.01 \pm 2.18	1.87 \pm 2.06	0.67 \pm 0.10	1.26 \pm 1.27
Urea (mg/dL)	45.57 \pm 4.47	45.14 \pm 4.85	37.17 \pm 4.45 ^b	40.71 \pm 4.82	39.57 \pm 5.62
TC (mg/dL)	59.02 \pm 8.36	38.57 \pm 12.27 ^a	53.83 \pm 11.79	46.29 \pm 7.74	46.29 \pm 11.03

*TC: Total cholesterol. Mann-Whitney U test, a: $p < 0.05$ compared to Control group, b: $p < 0.05$ compared to CCl₄ group.

Table 3. Histopathological scores of liver under different doses of silymarin in rats treated with CCl₄ (Median (min-max)).

Parameters	Control (n=7)	CCl ₄ (n=7)	2.5% Infusion (n=6)	5% Infusion (n=7)	10% Infusion (n=7)
Hepatocyte degeneration	0 (0-1)	2 (0-2) ^a	2 (1-2)	1 (1-2)	1 (1-2)
Sinusoidal dilatation	0 (0-1)	1 (0-2)	1 (0-1)	1 (0-1)	1 (1-1)
Central ven dilatation	1 (0-1)	2 (1-2) ^a	1 (1-2)	1 (0-2)	0 (0-1) ^b
Bile duct proliferation	0 (0-1)	1 (0-2)	0 (0-1)	0 (0-1)	1 (0-2)
Pleomorphism of liver cell	0 (0-0)	1 (0-1)	1 (0-2)	1 (0-1)	1 (0-2)
Picnotic hepatocyte nuclei	0 (0-0)	0 (0-1)	0 (0-1)	1 (0-1)	0 (0-0)
Periportal inflammation	0 (0-0)	1 (0-1)	1 (0-1)	0 (0-1)	1 (0-2)
Steatosis	0 (0-0)	0 (0-2)	1 (1-2)	0 (0-1)	1 (0-2)
Increasing in the number of Kupffer cells	0 (0-0)	1 (1-2) ^a	1 (1-2)	1 (1-1)	1 (0-1)
Kongestion	0 (0-0)	1 (0-2) ^a	1 (0-2)	1 (1-2)	1 (1-2)

Mann-Whitney U test, a: $p < 0.05$ compared to Control group, b: $p < 0.05$ compared to CCl₄ group.

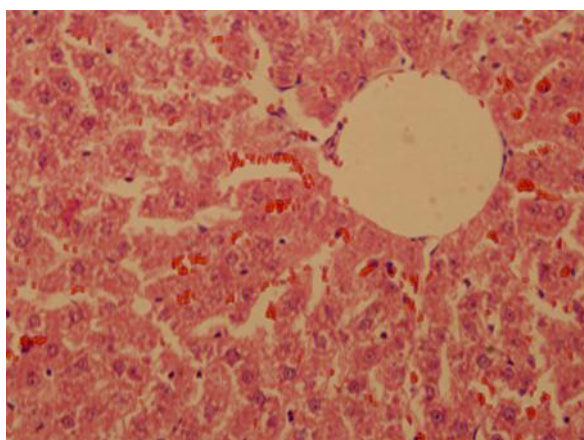
The scoring was modified as follows: 0 = no visible change/damage or; 1= mild change/damage (<25% of tissue); 2= moderate change/damage (<25–50% of the tissue); 3= extensive or global change/ damage.

Although statistically insignificant, glucose and uric acid levels increased due to CCl₄ intoxication and treatment of *Silybum marianum* caused to decrease (Table 2). Albumin caused to be decreased by CCl₄ administration and increased by low dose *Silybum marianum* ($p < 0.05$). CCl₄ did not affect kidney function tests (urea and creatinine).

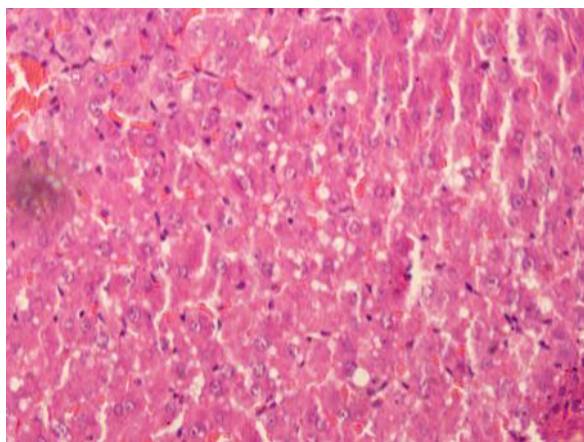
Total cholesterol level was found to be significantly lowered by CCl₄ intoxication. *Silybum marianum* caused to

slightly increase though this was not significant.

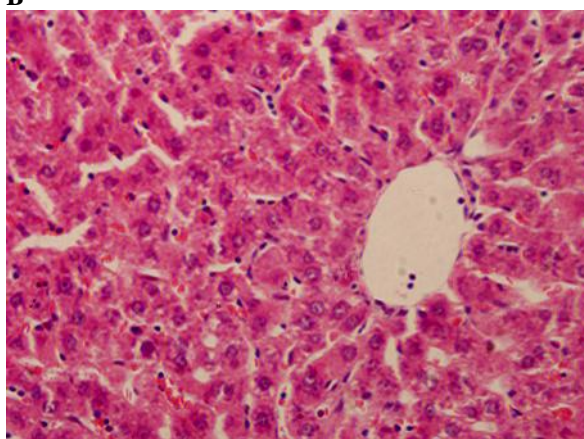
Table 3 shows histopathological scores of the groups. Administration of CCl₄ induced liver damage causing the elevated score of hepatocyte degeneration, central ven dilatation, increase in the number of Kupffer cell, and kongestion ($p < 0.05$). Treatment with *Silybum marianum* improved CCl₄ caused damages, though improvement only on central ven dilatation was significant (Figure 1).



A



B



C

Figure 1. The photomicrographs of liver section taken from rats. (A) Control group, liver cells of normal rats. (B) CCl_4 group, liver cells of rats intoxicated with CCl_4 . (C) 2.5% Infusion group, Liver cells of rats treated with 2.5% infusion of *Silybum marianum* plus with CCl_4 .

Discussion

The silymarin content in fruits of milk thistle depends on the variety and geographic and climatic conditions in which they grow. It is found at several concentrations ranging from 1 to 6 % in the ripe fruit [13]. It was suggested by The European Pharmacopoeia (Ph. Eur.5.0) silymarin content should be at least 1.5% in dry drug. In our region, previous studies revealed that silymarin content was around 3% [14]. Therefore, we investigated the efficacy of different doses of *Silybum marianum* grown in our region on hepatotoxicity in rats.

In this experiment CCl_4 intoxication impaired liver function tests (AST, ALT and ALP) glucose and uric acid levels. Histopathologically, CCl_4 caused hepatocyte degeneration, central vein dilatation, increase in the number of Kupffer cell, and kongestion demonstrating liver damage. Treatment with *Silybum marianum* attenuated these adverse effects.

Hepatotoxic and nephrotoxic effects of CCl_4 and protective effects of Silymarin were widely investigated in different models. Abdel Salam et al conducted three experiment investigating ameliorating effect of various agents comparing with silimarin on hepatic damage induced by orally administered CCl_4 (0.28 mL/kg). In one of their experiments [15], *Viscum album* alone or with silymarin, or silymarin alone had been orally received for 1 month, starting at the time of administration of CCl_4 . The levels of ALT, AST, and ALP were elevated and histopathologic findings such as loss of liver tissue architecture; severe dilatation and concession of blood vessels were shown in CCl_4 -treated rats, indicating hepatic injury. Treatment with either *Viscum album* with silymarin or silymarin alone has been biochemically and histopathologically exerted repairing effect. In their other two experiments misoprostol [16] and vinpocetine [17] were used instead of *Viscum album*. Treatment with them, alone or combination with silymarin, markedly ameliorated histopathological and biochemical alterations caused by CCl_4 .

Suja et al. [10] also used CCl_4 to induce hepatic damage and used silimarin and *Helminthostachys zeylanica* (HZ) to treat it. The model was similar to our experiment. Treatment contioned 5 consecutive days and CCl_4 were applied on days 2 and 3. In accordance with our findings, hepatic injury induced by CCl_4 increased AST, ALT, ALP, bilirubin levels and caused histopathological alterations such as massive fatty changes, gross necrosis, and broad infiltration of lymphocytes and Kupffer cells around the central vein and loss of cellular boundaries. Tretament with HZ and silymarin showed similar positive effect on these changes.

Lee et al. [9] carried out different model than other studies to test the preventive effect of silymarin and tea seed oil (*Camellia oleifera Abel.*) against CCl₄-induced oxidative damage in rats. For this reason, the two agents were administered for 6 weeks. On the last day of treatment CCl₄ were given. AST, ALT and lactate dehydrogenase (LDH) elevated because of CCl₄ intoxication. Pretreatment with silymarin and tea seed oil reduced liver function tests. They found that CCl₄ caused the lymphocytic infiltration in the central vein and fatty degeneration, necrosis, cytoplasmic vacuolization and mitosis in the hepatic cells. Treatment with tea seed oil and silymarin histologically showed preventive effect on CCl₄-induced hepatotoxicity. Like this, Merlin and Parthasarathy [18] used chloroform and ethanol extracts of *Gmelina asiatica* instead of tea seed oil. Silymarin was used as standard reference and exhibited significant the hepatoprotective activity against CCl₄ induced hepatotoxicity in rats.

Silymarin has also been used for the treatment of hepatotoxicity caused by agents other than CCl₄. Gopi et al. [19] constituted hepato- and nephrotoxicity by acetaminophen resulted in significant elevation of serum triglycerides, total cholesterol, blood urea nitrogen, serum creatinine, and aspartate transaminase activity. In their study, post-treatment with silymarin (25 mg/kg) significantly reversed the alterations. They had produced liver damage by giving acetaminophen in day 1-3. Then, silymarin treatment had been applied in day 4-14.

Shalan et al. [20] gave lead for 2, 4 and 6 weeks to produce liver damage. Accompanying to lead, silymarin (1 mg/100 body weight) plus vitamin C were given three times per week. Significant lead-induced elevations in serum ALT, AST, and ALP activities had been observed after 2, 4 and 6 weeks of treatment. Dilatation and congestion of terminal hepatic veins and portal vein branches were observed after 2 weeks. Hepatocyte proliferation, portal inflammatory infiltrate with disruption of the limiting plates (interface hepatitis), steatosis, apoptosis and mild fibrosis had been detected at the end of the sixth week. Combined treatment of Vitamin C and silymarin had been shown marked improvement of the biochemical and histopathological findings.

Mansour et al. [21] made hepatotoxicity by cisplatin (CDDP) administration, which is a widely used anticancer drug. They showed that silymarin attenuated serum ALT, AST, liver nitric oxide (NO) and malondialdehyde (MDA) level, previously increased by CDDP. Silymarin caused to increase the activities of superoxide dismutase (SOD), glutathione peroxidase (GSHPx) reduced glutathione (GSH) and serum NO level, which were previously decreased by CDDP. Likewise, CDDP was reported to cause liver damage in high doses via involvement of oxidative stress, lipid peroxidation, and mitochondria dysfunction [22].

Shaarawy et al. [23] induced hepatic destruction by N-nitrosodiethylamine (NDEA) plus CCl₄. In their experiment, liver function enzymes and hepatic lipid peroxidation (LPO) was found to be increased and superoxide dismutase (SOD), and GSH-dependent enzymes decreased. Pradeep et al. [24] also showed that another N-nitroso alkyl compound, Diethylnitrosamine, induced alterations in the liver tissue and silymarin reversed these negative changes by improving antioxidant capacity. Protective effect of silymarin has also been shown on hepatic damage by many agents such as ethanol [25] and anti-tuberculosis drugs [26].

In this experiment, kidney function tests, BUN and creatinine, were increased by CCl₄ and reduced by silymarin though insignificant. Turgut et al. [27] showed that silymarin had a protective effect on ischemia and reperfusion injury in the kidney tissues.

We found glucose level increased by CCl₄ administration and normalized by silymarin in an insignificant manner. In similar to our findings, Vessal et al. [28] found no significant effect on blood glucose of silymarin. On the other hand, Maghrani et al. [29] showed that *Silybum marianum* exhibited potent hypoglycemic effects on streptozotocin-induced diabetic rats. Soto et al [30] also indicated that silymarin blunts the sustained increment in plasma glucose in alloxan-induced pancreatic damage in rats. Similarly, Huseini et al [31] showed an effective treatment of silymarin in type II diabetes patients lowering blood glucose levels.

In summary, CCl₄ administration caused hepatotoxicity and *Silybum marianum* treatment, though insignificant, exert protective effects. According to literature, these effects can mainly be attributed to its antioxidant effects. In accordance with our results, silymarin has clear effects in experimental animal models; however, it has not been proved effectiveness in human liver disease yet [13,32]. Another point is that, in humans, though the side effects of silymarin are uncommon, and serious toxicity has rarely been reported [13], it should be taken into account that the numbers of toxicological studies are few. Therefore, clinical and community oriented investigations to reveal possible side effects of silymarin would be useful.

Acknowledgements

The authors thank Dr. Fatih Gultekin, Chairman of Biochemistry Department, Faculty of Medicine, Suleyman Demirel University, Isparta, for the helpful commands and constructive discussions on the manuscript, and to reading English proof.

References

1. Pradhan SC, Girish C. Hepatoprotective herbal drug, silymarin from experimental pharmacology to clinical medicine. Indian J Med Res 2006; 124: 491-504.

- Post-White J, Ladas EJ, Kelly KM. Advances in the use of milk thistle (*Silybum marianum*). *Integr Cancer Ther* 2007; 6: 104-109.
- Gazák R, Walterová D, Kren V. Silybin and silymarin--new and emerging applications in medicine. *Curr Med Chem* 2007; 14: 315-338.
- Rainone, F. Milk Thistle. *Am Fam Physician* 2005; 72: 1285-1288.
- Gilani AH, Rahman AU. Trends in ethnopharmacology. *J Ethnopharmacol* 2005; 100: 43-49.
- Kucuker P. Turkish Plant Names in Lügât-i Müskilat-i Ecza, The Journal of International Social Research 2010; 3: 401-415 (in Turkish).
- Do anoglu O, Gezer A, Yucedag C. Studies on Some Important Medicinal and Aromatic Plant Taxons in Yenisarbademli Locality of Lakes District. *SDU J Natural and Applied Sciences* 2006; 0: 66-73 (in Turkish)
- Raskovic A, Jakovljevic V, Popovic M, Sabo A and Piljevic O. Effect of Methoxsalen and an Infusion of *Silybum marianum* on Enzymes Relevant to Liver Function. *Pharmaceutical Biology* 2002; 40: 70-73
- Lee CP, Shih PH, Hsu CL, Yen GC. Hepatoprotection of tea seed oil (*Camellia oleifera* Abel.) against CCl₄-induced oxidative damage in rats. *Food Chem Toxicol* 2007; 45: 888-895.
- Suja SR, Latha PG, Pushpangadan P, Rajasekharan S. Evaluation of hepatoprotective effects of *Helminthostachys zeylanica* (L.) hook against carbon tetrachloride-induced liver damage in Wistar rats. *J Ethnopharmacol* 2004; 92: 61-66.
- French SW, Miyamoto K, Ohta Y, Geoffrion Y. Pathogenesis of experimental alcoholic liver disease in the rat. *Methods and Achievements in Experimental Pathology* 2000; 13: 181-207.
- Geller SA, Petrovic LM. *Biopsy Interpretation of the Liver*, 2nd ed. Lippincott Williams & Wilkins 2009.
- Corchete P. *Silybum marianum* (L.) Gaertn: the Source of Silymarin. In: Ramawat KG, Merillon JM (eds.) *Bioactive Molecules and Medicinal Plants*. Springer, 2008, p 123-149.
- Kan Y, Kartal M, Orhan I, Sayar SA, Abu-Asaker M. Agricultural and industrial properties of milk thistle (*Silybum marianum*) in Turkey. The 8th Turkish Congress on Field Crops, 19-22 October 2009 Hatay, Turkey, Proceeding Book, p 73-76 (in Turkish).
- Abdel Salam OME, Sleem AA, Shaffie NM. Effect of *Viscum album* on acute hepatic damage caused by carbon tetrachloride in rats. *Turk J Med Sci* 2010; 40 (3): 421-426
- Abdel Salam OME, Sleem AA, Omara EA, Hassan NS. Hepatoprotective effects of misoprostol and silymarin on carbon tetrachloride-induced hepatic damage in rats. *Fundam Clin Pharmacol* 2009; 23: 179-188.
- Abdel Salam OM, Oraby FH, Hassan NS. Vinpocetine ameliorates acute hepatic damage caused by administration of carbon tetrachloride in rats. *Acta Biol Hung* 2007; 58: 411-419.
- Merlin NJ, Parthasarathy V. Antioxidant and hepatoprotective activity of chloroform and ethanol extracts of *Gmelina asiatica*. aerial parts. *J Med Plant Res* 2011; 5: 533-538
- Gopi KS, Reddy AG, Jyothi K, Kumar BA. Acetaminophen-induced Hepato- and Nephrotoxicity and Amelioration by Silymarin and *Terminalia chebula* in Rats. *Toxicol Int* 2010; 17: 64-66.
- Shalan MG, Mostafa MS, Hassouna MM, El-Nabi SE, El-Refaie A. Amelioration of lead toxicity on rat liver with Vitamin C and silymarin supplements. *Toxicology* 2005; 206: 1-15.
- Mansour HH, Hafez HF, Fahmy NM. Silymarin modulates Cisplatin-induced oxidative stress and hepatotoxicity in rats. *J Biochem Mol Biol* 2006; 39 (6): 656-661
- Yilmaz HR, Sogut S, Ozyurt B, Ozugurlu F, Sahin S, Isik B, Uz E, Ozyurt H. The activities of liver adenosine deaminase, xanthine oxidase, catalase, superoxide dismutase enzymes and the levels of malondialdehyde and nitric oxide after cisplatin toxicity in rats: protective effect of caffeic acid phenethyl ester. *Toxicol Ind Health* 2005; 2: 67-73.
- Shaarawy SM Tohamy AA, Elgendy SM, Elmageed ZY, Bahnasy A, Mohamed MS, Kandil E, Matrougui K. Protective effects of garlic and silymarin on NDEA-induced rats hepatotoxicity. *Int J Biol Sci* 2009; 5: 549-557.
- Pradeep K, Mohan CV, Gobianand K, Karthikeyan S. Silymarin modulates the oxidant-antioxidant imbalance during diethylnitrosamine induced oxidative stress in rats. *Eur J Pharmacol* 2007; 560: 110-116.
- Song Z, Deaciuc I, Song M, Lee DY, Liu Y, Ji X, McClain C. Silymarin protects against acute ethanol-induced hepatotoxicity in mice. *Alcohol Clin Exp Res* 2006; 30: 407-413.
- Eminzade S, Uraz F, Izzettin FV. Silymarin protects liver against toxic effects of anti-tuberculosis drugs in experimental animals. *Nutr Metab* 2008; 5: 18.
- Turgut F, Bayrak O, Catal F, Bayrak R, Atmaca AF, Koc A, Akbas A, Akcay A, Unal D. Antioxidant and protective effects of silymarin on ischemia and reperfusion injury in the kidney tissues of rats. *Int Urol Nephrol* 2008; 40: 453-460.
- Vessal G, Akmalı M, Najafi P, Moein MR, Sagheb MM. Silymarin and milk thistle extract may prevent the progression of diabetic nephropathy in streptozotocin-induced diabetic rats. *Ren Fail* 2010; 32: 733-739.
- Maghrani M, Zeggwagh NA, Lemhadri A, El Amraoui M, Michel JB, Eddouks M. Study of the hypoglycaemic activity of *Fraxinus excelsior* and *Silybum marianum* in an animal model of type 1 diabetes mellitus. *J Ethnopharmacol* 2004; 91: 309-316.
- Soto CP, Perez BL, Favari LP, Reyes JL. Prevention of alloxan-induced diabetes mellitus in the rat by silymarin. *Comp Biochem Physiol C Pharmacol Toxicol Endocrinol* 1998; 119: 125-129.

31. Huseini HF, Larijani B, Heshmat R, Fakhrzadeh H, Radjabipour B, Toliat T, Raza M. The efficacy of Silybum marianum (L.) Gaertn. (silymarin) in the treatment of type II diabetes: a randomized, double-blind, placebo-controlled, clinical trial. *Phytother Res* 2006; 20: 1036-1039.
32. Kren V, Walterová D. Silybin and silymarin--new effects and applications. *Biomed Pap Med Fac Univ Palacky Olomouc Czech Repub* 2005; 149: 29-41.

***Correspondence to:**

Mustafa OZTURK
Suleyman Demirel University, School of Medicine,
Departments of Public Health
32260 Isparta
Turkey