

# Effect of Topical Application of Hydro-Ethanollic Extract of *Acacia nilotica* Pods on Second-Degree Cutaneous Infected Burns

Kossi Metowogo<sup>1,\*</sup>, Tchinn Darré<sup>1,2</sup>, François Daubeuf<sup>3</sup>, Povi Lawson-Evi<sup>1</sup>, Kwashi Eklugadegbeku<sup>1</sup>, Kodjo A. Aklikokou<sup>1</sup>, Gado Napo-Koura<sup>2</sup>, Nelly Frossard<sup>3</sup> and Messanvi Gbeassor<sup>1</sup>

<sup>1</sup>Centre de Recherche et de Formation sur les Plantes Médicinales (CERFOPLAM), Laboratoire de Physiologie-Pharmacologie, Faculté des Sciences, Université de Lomé, Togo

<sup>2</sup>Laboratoire d'Anatomie et Cytologie Pathologiques, Faculté Mixte de Médecine et de Pharmacie, Université de Lomé, Togo

<sup>3</sup>UMR 7200, Laboratoire d'Innovation Thérapeutique, Equipe Chimie Biologie intégrative, Faculté de Pharmacie, Université de Strasbourg, Illkirch, France

**Abstract:** *Acacia nilotica* is a medicinal plant used traditionally in Togo to treat various diseases including burn wounds. The aim of this study was to evaluate experimentally *Acacia nilotica* burn wound healing effect.

Cutaneous burn wounds were symmetrically caused on depilated areas of rat skin through contact with an aluminum bar (r = 10 mm), preheated at 80°C for 30 sec. Five groups of animal were constituted and each group contained 8 mice. Four groups of animal's burn wounds were infected by *Staphylococcus aureus*. One group burn wound is uninfected and serves as negative control. Burn wounds were assessed by planimetry and histological parameters of healing. Twelve days after burn wound induction, wound contraction in the uninfected groups (negative control) was 19.9% for topical application against -2.43% for infected control. In the infected groups treated with extract, wound contraction was generally stimulates. Histological examination showed granulated tissue developing over the wounds treated with the extract of *A. nilotica* at 2.5% and 5% where the proliferation of fibroblasts and neo-blood vessels was very marked.

In conclusion, *A. nilotica* pod contents tannin, flavonoids, alkaloids and protein reduces DPPH solution and significantly accelerates wound healing of burns, and this is the case even if wounds are infected with 10<sup>9</sup>CFU/mL of *S. aureus*.

**Keywords:** Burns wound, *A. nilotica*, histology, wound infection, wound healing.

## INTRODUCTION

The skin is the largest organ of the body with the purpose to serve as a barrier against external agents like micro-organism and chemical substance. The loss of skin tissue integrity may cause lesions or illnesses that can lead to death [1] because disruption of the skin generally increases fluid loss, infection, hypothermia, scarring, compromised immunity and change in the body image. The mortality rate from burns has declined in the past decade; however, it is still high, if more than 70% of the body surface is injured or burned [2]. Burns are classified according to lesion severity (depth of the injury) into superficial or first degree, when lesion is restricted to the epidermis or skin causing redness; partial thickness or second degree that can be superficial when reaching the epidermis and superficial dermis, showing hypersensitivity and pain, or deep when it extends to the deepest layer of the dermis and may have reduced sensitivity with red and/or white coloration of the tissue; full-thickness or third degree when lesion involves the subcutaneous layer, with no sensitivity and white coloring [3]. In superficial second-

degree burns, burns are very painful and generally caused by thermal injuries. Burn and trauma wounds are very common in both developed and developing countries; however, in developing countries, burn constitutes a major health problem because the incidence of severe complications like infections is high and financial resources are limited [4]. Infected burns wound cicatrization is generally complicated. The use of traditional medicinal plants in the treatment of burn wounds are an important aspect of health treatment and at the same time a way to reduce the financial burden. Among several plants used as traditional healing remedies in Togolese folk medicine, pods of *A. nilotica* have been reported. In order to revalorize use of medicinal plants, we had early demonstrated uninfected burns wound properties of *A. nilotica* pods extract [5]. This study was conducted to investigate the action of hydro-ethanollic extract of *A. nilotica* pods on second-degree infected burns in mice.

## MATERIAL AND METHODS

### Material

#### Plant Material

*A. nilotica* pods were purchased at Tsevie market (35 km north of Lomé) and taken to the herbarium of

\*Address correspondence to this author at the Centre de Recherche et de Formation sur les Plantes Médicinales (CERFOPLAM), Laboratoire de Physiologie-Pharmacologie, Faculté des Sciences, Université de Lomé, Togo; Tel: 0022890946566; E-mail: kossi.metowogo@gmail.com

the Laboratory of Botany of University of Lome-Togo where they were authenticated (voucher specimen: n° Togo 04824/ Togo 04822/ Togo 04821). Pods were washed in water, freeze-dried and reduced to powder. To this powder (1980g), was added 4L of hydro-ethanollic solution (3:1). The mixture is stirred for 72 hours under manual intermittent then filtered. The filtrate was evaporated on Rota vapor (Buchi R-210) and the obtained extract was mixed to the gel for the tests.

### **Animals**

ICR mice (30-35 g weight) purchased from Nogoschi Memorial Medical Research Institute of The University of Ghana were used for this study. They were housed for 10 days at Laboratoire de Physiologie Animale of Université de Lomé (Togo) for acclimatization. They were maintained on standard experimental conditions of temperature, 12h light/dark cycle and fed on normal pallet diet, and water allowed *ad libitum* throughout the experiment. Except the agents under study, no topical or systemic therapy was given to animals.

Five groups of animal were constituted and each group contained 8 mice. Group -I burn's wound are uninfected and serves as negative control receiving Carbopol empty gel. Three days after burns created, wounds of the fours last group were infected by *Staphylococcus aureus*.  $10^9$  CFU/mL of *Staphylococcus* solution were used and 100  $\mu$ L of this solution is inoculated in the wounds. Group II serves as positive control, and then his burn wound is treated by Carbopol empty gel. Groups-III and IV were locally applied with Carbopol gel containing 2.5% and 5% of *A. nilotica* pods extract respectively. Group-V received the standard treatment with Brulex® (Baily-Creat, France).

### **Methods**

#### **Qualitative Phytochemical Analysis**

Phytochemical screenings of the extract were carried out to identify the chemical constituents like tannins, flavonoids, saponosids, alkaloids, polysaccharides and protein using standard phytochemical methods. Dragendoff and Mayer's essays were done to determine the presence of alkaloids, 5% FeCl<sub>3</sub> solution and 10% lead acetate were used to identify tannins, 5% FeCl<sub>3</sub> and 10% NaOH solution to determine flavonoids presence in extract. Identification of Polysaccharides was evaluated by Mollish test and Protein presence by using Biuret test.

#### **Quantitative Determination of Total Phenolic and Flavonoids**

##### Total Phenolic Content

The amount of phenol in the aqueous extract was determined by Folin-Ciocalteu reagent method with some modifications. 60  $\mu$ L of 10% Folin-Ciocalteu reagent and 120  $\mu$ L of 2% solution of Na<sub>2</sub>CO<sub>3</sub> were added to 60  $\mu$ L of plant extract. The resulting mixture was incubated for 30 minutes at room temperature. The absorbance of the sample was measured at 760 nm. Gallic acid was used as standard (200 $\mu$ g/ml). All the tests were performed in triplicates. The results were determined from the standard curve and were expressed as Gallic acid equivalent (mgGAEq/g of extracted compound).

##### Total Flavonoid Content

Aluminium chloride colorimetric method was used with some modifications to determine flavonoid content. 20  $\mu$ L of sample plant extract was mixed with 70  $\mu$ L of ethanol 95°, 10  $\mu$ L of 10% aluminium chloride, 10  $\mu$ L of 1M sodium acetate and 140  $\mu$ L of distilled water and remains at room temperature for 30 minutes. The absorbance was measured at 415 nm. Quercetin was used as standard (0.8 mg/ml). All the tests were performed in triplicates. Flavonoid contents were determined from the standard curve and were expressed as quercetin equivalent (mgQEEq/g of extracted compound).

##### DPPH Essay

To evaluate radical scavenger effect of extract, DPPH essay was performed. About 100 mmol/l solution of DPPH (2mg of DPPH) in 100% methanol (50 ml) was prepared and 200  $\mu$ L of this solution was added to 10 $\mu$ L of the extract dissolved in methanol at different concentrations. The mixture was shaken and allowed to stand at room temperature for 30 min and the absorbance was measured at 517 nm using spectrophotometer. Inhibition percentage [I (%)] was calculated as follow:  $I (\%) = (A_0 - A_t) / A_0 \times 100$ , where A<sub>0</sub> is the absorbance of the control and A<sub>t</sub> is the absorbance of the test compound. IC<sub>50</sub> value (concentration of sample which reduced 50% of DPPH) was determined from inhibition percentage curve according to the concentration. The IC<sub>50</sub> value of the extract was compared with that of ascorbic acid, which was used as the standard.

##### Preparation of Gels

The gel was prepared as follows: 0.3 g of Carbopol 974P NF (Goodrich, USA) was dispersed in 27 g of

distilled water and mixed by stirring continuously on a magnetic stirrer (IKA-Combimag RCT) at 800 rpm for 1 h. The mixture under continuous stirring was neutralized by drop-wise addition of NaOH 1 mol/l. Mixing was continued until a transparent gel was formed [6, 7]. Three types of gel formulations were prepared: empty gel, gel containing 2.5% and 5% of *A. nilotica* pods extract. For standard treatment we used dermal Brulex<sup>®</sup> reference drugs.

### Burn Wound Induction

Mice were anesthetized by the open mask method with diethyl ether and their dorsal surface was shaved by using a shaving machine. Burns were symmetrically caused on depilated areas through contact with an aluminum bar (r = 10 mm), preheated at 80° C for 30 sec. The bar is maintained in contact with the animal skin on the dorsal proximal region for 20 sec, immediately after the procedure of burn wound induction, *A. nilotica* pods extract on carbopol gel or Brulex<sup>®</sup> was applied topically. The wounds were left undressed to the open environment and observed daily. The treatments were applied topically once a day, starting from the wound induction until day 12 post-excision.

### Burn Wound Infection

Wounds were infected by *Staphylococcus aureus* obtained from Laboratory of Microbiology and food hygiene of Université de Lomé on the 3<sup>rd</sup> day after burn induction according to the method of Kumar *et al.* (2008) [8] after slight modification. Briefly, Bacterial culture is made based bacterial strains of *Staphylococcus aureus* obtained in the Laboratory of Microbiology, Université of Lomé. A bacterial suspension was made from the liquid LB medium at 37 ° C and cultured for 16 hours to ensure that the density reaches 10<sup>9</sup> CFU / ml. An aliquot (100µL) of each bacterial inoculation was incubated at 37 ° C, and then wounds were infected on the third day post burn wounds.

### Measurement of Wound Area

The progressive changes in wound area were monitored by a camera (Pentax, Option E75, and

China) every other third day. Later on, wound area was evaluated by using Image J program. Wound contraction (WC) was calculated as a percentage of the reduction in wound area by using the mathematic expression:  $WCd = (1 - WAd/WA0) \times 100$  where WAd is the area of the wound on the day d and WA0 the wound area on day 0 [7, 9].

### Histological Studies

After wound area was measured, animals were killed under ether anesthesia and immediately skin samples from the wounds in each group were collected on day 8 for tree mice and day 12 for the rest. The specimens were fixed in 10% neutral buffered formalin, processed and included in paraffin. Five-micrometer skin sections were cut and stained with hematoxylin-eosin [10]. The tissues were qualitatively assessed under light microscopy (Olympus BX 51) at 200x or 400x magnification and graded as absent (-), mild (+), moderate (++) and severe (+++) for epidermal or dermal remodeling. Epithelialization, ulceration and necrosis in epidermis, congestion edema, fibroblast proliferation, mononuclear and polynuclear cells and neovascularization in dermis were analyzed [11].

### Statistical Analysis

Results are reported as means ± standard errors. The statistical significance between values in the treated groups and controls was evaluated with a one way ANOVA followed by Bonferroni's multiple comparison tests. P values less than 0.05 were considered to be statistically significant.

## RESULTS

### Qualitative and Quantitative Phytochemical Analysis Results

Phytochemical analysis using standard colorimetric methods revealed presence of tannin, flavonoid, alkaloids and proteins. Folin-ciocalteu methods used permits to determine the amount of polyphenols in the extract. 182.49 ± 5.19 mg GAEq/g of extract compound of polyphenols was in the extract. 12.8 ± 1.33 mg

**Table 1: Amount of Polyphenols and Flavonoids in *A. nilotica* Pods Extract and his Antioxidants Activity**

	Polyphenols (mg GAEq/g of extract)	Flavonoids (mg QEq/g of extract)	DPPH Essay IC <sub>50</sub> (µg/mL)
<i>A. nilotica</i> Pods hydroalcoholic extract	182.49 ± 5.19	12.8 ± 1.33	63.20
Ascorbic acid			80.33

mg GAEq/g: milligram gallic acid equivalents/gram.  
mg QEq/g: milligram quercetin equivalents/gram.

QE/g of extract compound of flavonoids was determined in the extract (Table 1).

### Radical Scavenger Activity

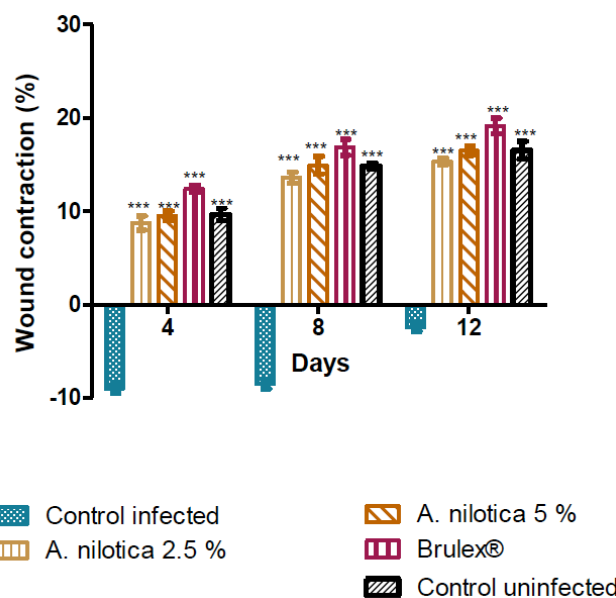
*A. nilotica* pods hydroalcoholic extract possess radical scavenger properties. This extract reduces DPPH solution by discoloring rose color to yellow. IC<sub>50</sub> value of extract is 63.20 µg/ml vs 80.33 µg/ml for ascorbic acid (Table 1).

### Burn Wound Healing Effect

Topical application of gel of *A. nilotica* pods extract at 5% and 2.5% enhances cutaneous burn wounds healing by stimulating wound contraction. This was observed macroscopically with increased contraction of the wound in mice topically treated with *A. nilotica* extract gel as compared to controls. Wound contraction is one parameter used to assess wound healing. Significant wound contraction was initiated from day 4 in treated groups versus positive controls (infected control). Comparison between negative control (Group-I: uninfected) and positive control (Group-II: infected) wound contraction values showed that infection of burn wound delayed wound healing. Wound contraction for Group-I, 4<sup>th</sup>, 8<sup>th</sup> and 12<sup>th</sup> days of experiment is respectively  $9.65 \pm 0.65$ ,  $14.85 \pm 0.34$ ,  $16.55 \pm 0.94$  against  $-9 \pm 0.5$ ,  $-8.5 \pm 0.5$ ,  $-2.43 \pm 0.43$  for Group-II. Comparison between treated groups (Group III and IV treated respectively by *A. nilotica* gel at 2.5% and 5%) and Group I on day 12 show that extract inhibits staphylococcus proliferation and promote wound healing. For example wound contraction for group I on day 12 is  $16.55 \pm 0.94$  against  $15.35 \pm 0.34$  and  $16.5 \pm 0.5$  respectively for Group III and IV (Figure 1).

### Histological Studies

Histological sections performed for uninfected control (Group-I) and treated groups (Group- III, IV, V) on day 8 after induction of burn show epidermal ulceration and the presence of necrotic tissue debris interspersed with inflammatory cells with polymorphic congestion and edema of the dermis in control mice. In infected control (Group-II) we noted exacerbation of necrosis, congestion, edema and proliferation of inflammatory cells. On day 12 after induction of burn, histological sections for uninfected group show in control mice, a low epithelialization of epidermal ulceration in some mice (Figure 2A). It was still a polymorphic inflammatory infiltrate in the dermis with edema, witness of an incomplete healing. By contrast, in infected mice by day 12 after induction of burn,



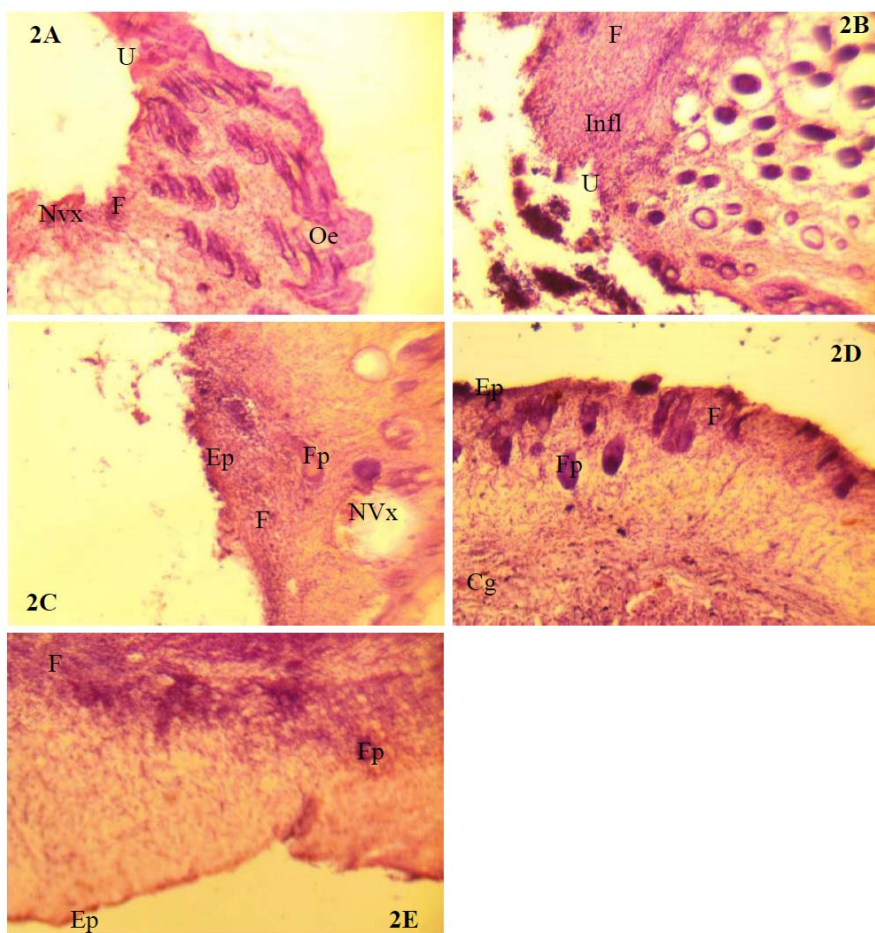
**Figure 1: Effect of topical application of *A. nilotica* pods on infected cutaneous burn wound.**

Wound contraction was expressed as percentage of wound closure using wound area on day d compared with wound area on the first day. Results are expressed as means  $\pm$  SEM of n=8 mice per group. \*\*\*indicates  $p < 0.001$  for the treated groups as compared with controls.

histological sections for control (Figure 2B) show epidermal ulceration, polymorphic inflammatory infiltrate in the dermis with edema. In groups of mice treated with the extract of *A. nilotica* 2.5, 5% and (Brulex® (respectively Figure 2C, 2D and 2E), an early epithelialization was observed with hair follicles and fibroblastic elements, despite the infection (Table 2).

### DISCUSSION

Burns remain a huge public health issue, at least in terms of morbidity and long term disability, throughout the world, especially in the developing countries [12]. Burn wound healing is a complex process characterized by re-epithelialization and formation of granulated tissue and remodeling of the extracellular matrix. It causes discomfort and is prone to infection, a major complication of burn injury responsible for 50-75% of hospital deaths [13]. Though healing process takes place by itself and does not require much help, various risk factors such as infection and delay in healing have brought attention to promote this process. The results obtained show that topical application of *A. nilotica* extract gel at the wound site produces significant wound healing activity, by 1) its capacity to promote wound contraction, 2) formation of granulated tissues and 3) re-epithelialization in infected burn wounds. We first show that uninfected burn wound contraction was increased in animals treated with



**Figure 2: Histological sections of wounded skin treated topically with the vehicle alone (Carbopol empty gel), *A. nilotica* pods extracts at 2.5 and 5%, and Brulex® on D12.**

Uninfected group (A: control; B, C; D: treated respectively by *A. nilotica* 2.5, 5% and Brulex), Infected group (E: control; F, G, H: treated respectively by *A. nilotica* 2.5, 5% and Brulex) U: ulceration; Oe: edema; Infl: presence of inflammatory cells; Cg: congestion; Ep: epithelialization; Fp: hair follicle; F: fibroblast proliferation; NVx: congestive vessels of the dermis. (Hematoxylin-eosin staining, x100).

**Table 2: Histological Evaluation of Wound Healing Process of *A. nilotica* Gel and Brulex® on Burn Wound**

Traitement	C	Ed	PMN	MNC	N	FP	NV	Ep	U
Uninfected control	+	+	++	++	-	+	++	++	+
Infected control	++	++	++	++	-	-	+++	+	++
<i>A. nilotica</i> 2,5%	++	+	+	+	+	+	+	++	+
<i>A. nilotica</i> 5%	++	+	+	+	-	+	+	++	+
Brulex®	+	+	+	+	-	++	+	++	+

*A. niloticageland* Brulex® were administrated topically an infected burn wound once per day during the 12.post burn wound days. Hematoxiin-eosin stained sections were scored as mild (+), moderate (++) and severe (+++) for epidermal and/or dermal remodeling. Epithelialization and ulceration were scored as present (+) and absent (-). C: congestion; Ed: edema; PMN: polymorphonuclear cells; MNC: mononuclear cells; N: necrosis; FP: fibroblast proliferation; NV: neovascularization; Ep: epithelialization; U: ulceration.

*A. nilotica* [5], as visualized by the method described by Amegbor *et al.* (2012) [7]. According to this method wound contraction or wound closure was determined by using the initial and final areas monitored by camera and evaluated by *Image J* programme during the experiments, with percentage wound closure calculated as  $[(\text{initial}-\text{final})/\text{initial}]\times 100$ . Similarly, formation of

granulated tissue was also increased in burn wound healing treated with *A. nilotica* as compared with controls treated with carbopol gel alone. Epithelialization also was increased in *A. nilotica* treated group than controls. The prohealing activity was marked as all the parameters observed were significantly affected.

*A. nilotica* extract gel accelerates uninfected [5] or infected burn wound healing. As reported by Kumar *et al.* (2006) [14] and Pereira *et al.* (2012) [15], burn wounds were usually infected by bacteria gram positive like *S. aureus* and this infection delays wound healing. The significant burn wound healing effect of *A. nilotica* extract observed in the infected group associates with delay wound healing observed after wound infection by *staphylococcus aureus* in controls indicating that *A. nilotica* pods extract are responsible for an effective antimicrobial activity. This confirms the findings by Arias *et al.* 2004 [16] and Al-Fatimi *et al.* 2007 [17] demonstrating antimicrobial effect of *A. nilotica* on gram-positive bacteria.

Extract compounds are responsible of wound healing and antimicrobial effect. Our study demonstrated that extract contained polyphenols. We have also demonstrated extract have radical scavenger activity. Radicals scavenger contributes to accelerate wound healing.

## CONCLUSION

Topical application of gel containing *A. nilotica* extract exhibited significant prohealing activity in burn wound on mice by affecting various stages of healing process. The result of the present study offers pharmacological evidence on the folkloric use of *A. nilotica* pods for healing wounds.

## REFERENCES

- [1] Jorge MP, Madjarof C, Ruiz ALTG, Fernandes AT, Rodrigues RAF, Sousa IMO, Foglio MA, Ernesto De Carvalho J. Evaluation of wound healing properties of *Arrabidaeaachica* Verlot extract. *J Ethnopharmacol* 2008; 118: 361-366. <http://dx.doi.org/10.1016/j.jep.2008.04.024>
- [2] Alemdaroglu C, Degim Z, Celebi N, Zor F, Ozturkand S, Erdogan D. An investigation on burn wound healing in rats with chitosan gel formulation containing epidermal growth factor. *Burns* 2006; 32: 319-327. <http://dx.doi.org/10.1016/j.burns.2005.10.015>
- [3] Pereira DST, Lima-Ribeiro MHM, Nicodemus TPF, Carneiro-Leao AMA, Correia MTS. Development of Animal Model for Studying Deep Second-Degree Thermal Burns. *J Biomed Biotechnol* 2012a; 2012: 7 p. <http://dx.doi.org/10.1155/2012/460841>
- [4] Gurung S, Skalko-Basnet N. Wound healing properties of *Carica papaya* latex: *In vivo* evaluation in mice burn model. *J Ethnopharmacol* 2009; 121: 338-341. <http://dx.doi.org/10.1016/j.jep.2008.10.030>
- [5] Darré T, Metowogo K, Lawson-Evi P, Eklü-Gadegbeku K, Aklikokou AK, Napo-Koura G, Gbeassor M. Effet topique de l'extrait hydro-ethanolique de l'acacia nilotica sur la cicatrisation cutanée des brulures de second degre. *European Scientific Journal* 2014; 10: 1857-7881.
- [6] Trombetta D, Puglia C, Perri D, Licata A, Pergolizzi S, De Pasquale A, Saija A, Bonina FP. Effect of polysaccharides from *Opuntia ficus-indica* (L.) clatodes on the healing of dermal wounds in the rat. *Phytomedicine* 2006; 13: 352-358. <http://dx.doi.org/10.1016/j.phymed.2005.06.006>
- [7] Amegbor K, Metowogo K, Eklü-Gadegbeku K, Agbonon A, Aklikokou AK, Napo-Koura G, Gbeassor M. Preliminary evaluation of the wound healing effect of vitexdonianasweet (verbenaceae) in mice. *Afr J Tradit Complement Altern Med* 2012; 9: 584-590. <http://dx.doi.org/10.4314/ajtcam.v9i4.16>
- [8] Kumar MS, Kirubanandan S, SriPriya R, Sehgal PK. Triphala Promotes Healing of Infected Full-Thickness Dermal Wound. *J Surg Res* 2008; 144: 94-101. <http://dx.doi.org/10.1016/j.jss.2007.02.049>
- [9] Sadaf F, Saleem R, Ahmed M, Ahmadand SI, Navaid-UI Z. Healing potential of cream containing extract of *Sphaeranthusindicius* on dermal wounds in Guinea pigs. *J Ethnopharmacol* 2006; 107: 161-163. <http://dx.doi.org/10.1016/j.jep.2006.02.022>
- [10] Mcmanus JFA, Mowry RW. Stanning methods, histologic and histochemical. Haper Raw, New York, Evanston, Lodon 1965.
- [11] Akkol EK, Koca U, Pe Sin I, Yilmazer D, Tokerand G, Yesilada E. Exploring the wound healing activity of *Arnebiadensiflora* (Nordm.) Ledeb by *in vivo* models. *J Ethnopharmacol* 2009; 124: 137-141. <http://dx.doi.org/10.1016/j.jep.2009.03.019>
- [12] Priya KS, Gnanamani A, Radhakrishnan N, Babu M. Healing potential of *Datura alba* on burn wounds in albino rats. *J Ethnopharmacol* 2002; 83: 193-199. [http://dx.doi.org/10.1016/S0378-8741\(02\)00195-2](http://dx.doi.org/10.1016/S0378-8741(02)00195-2)
- [13] Mokaddas EVO, Sanyal SC. *In vitro* activity of piperacillin/tazobactam versus other broad antibiotics against nosocomial gram negative pathogens isolated from burn patients. *J Chemotherapy* 1998; 10: 208-214. <http://dx.doi.org/10.1179/joc.1998.10.3.208>
- [14] Kumar MS, Kirubanandan S, SriPriya R, Raghavan HV, Sehgal PK. Wound Healing Potential of *Cassia fistula* on Infected Albino Rat Model. *J Surg Res* 2006; 131: 283-289. <http://dx.doi.org/10.1016/j.jss.2005.08.025>
- [15] Pereira DST, Lima-Ribeiro MHM, Santos-Oliveira R, Cavalcanti CLB, Teles De Pontes-Faldo N, Coelho LCBB, Carneiro-Leao AMA, Correia MTS. Topical Application Effect of the Isolectin Hydrogel (Cramoll 1,4) on Second-Degree Burns: Experimental Model. *J biomed biotechnol* 2012b; 2012: 11p. <http://dx.doi.org/10.1155/2012/184538>
- [16] Arias ME, Gomez JD, Cudmani NM, Vattuone MA, Isla MI. Antibacterial activity of ethanolic and aqueous extracts of *Acacia aroma* Gill. ex Hook et Arn. *Life Scie* 2004; 75: 191-202. <http://dx.doi.org/10.1016/j.lfs.2003.12.007>
- [17] Al-Fatimi M, Wurster M, Schroder G, Lindequist U. Antioxidant, antimicrobial and cytotoxic activities of selected medicinal plants from Yemen. *J Ethnopharmacol* 2007; 111: 657-666. <http://dx.doi.org/10.1016/j.jep.2007.01.018>