

Journal of the Hellenic Veterinary Medical Society

Vol 71, No 3 (2020)



Effect of trans-resveratrol or ubiquinol supplementation on the sperm morphology of CD-1 mice subjected to forced swimming

Δ. VAAMONDE, A. SÁNCHEZ DE MEDINA, B. CORTÉS, A. DÍAZ, I. RODRÍGUEZ

doi: [10.12681/jhvms.25096](https://doi.org/10.12681/jhvms.25096)

To cite this article:

VAAMONDE Δ., SÁNCHEZ DE MEDINA, A., CORTÉS B., DÍAZ A., & RODRÍGUEZ I. (2020). Effect of trans-resveratrol or ubiquinol supplementation on the sperm morphology of CD-1 mice subjected to forced swimming. *Journal of the Hellenic Veterinary Medical Society*, 71(3), 2349–2356. <https://doi.org/10.12681/jhvms.25096>

Effect of trans-resveratrol or ubiquinol supplementation on the sperm morphology of CD-1 mice subjected to forced swimming.

D. Vaamonde¹, A. Sánchez de Medina², B. Cortés², A. Díaz², I. Rodríguez²

¹ Morphological Sciences Department, School of Medicine and Nursing, Universidad de Córdoba, Spain.

² Animal Surgery and Medicine Department, School of Veterinary Medicine, Universidad de Córdoba, Spain.

ABSTRACT: This study was undertaken to assess the effect of a three-minute forced swimming protocol for 50 days, with and without antioxidant administration on sperm morphology in CD-1 mice. Seventy-five mice were randomly allocated to one of the following five groups: no exercise (control group; CG), swimming without antioxidant administration (EX), swimming with trans-resveratrol administration (EX-Resv), swimming with ubiquinol and excipient administration (Kaneka's ubiquinol) (EX-Ubiq), and swimming with just only the excipient for Kaneka's ubiquinol administration (EX-Excp). The EX group showed that 53.03±4.83% of sperm had abnormal morphology, with significant differences with regards to CG (46.47±10.57%) (p<0.05). The number of sperm with abnormal morphology decreased in all groups treated with either antioxidants or with excipient; this was most noticeable in EX-Ubiq (p<0.05). The percentage of midpiece and tail, as well as multiple anomalies were greater in EX than in CG (p<0.05). While both antioxidants, as well as the excipient, decreased midpiece and head anomalies, only trans-resveratrol and ubiquinol had an effect on multiple anomalies. Furthermore, only trans-resveratrol had an effect upon tail anomalies. The imposed exercise caused alterations in CD-1 mice sperm morphology, and antioxidant treatment seems suitable to decrease morphological anomalies. Both trans-resveratrol and ubiquinol were effective in decreasing simple as well as multiple sperm anomalies.

Keywords: swimming exercise; sperm morphology; ubiquinol; trans-resveratrol

Corresponding Author:
Diana Vaamonde, Facultad de Medicina y Enfermería- Universidad de Córdoba.
Avenida Menéndez Pidal s/n.14004. Córdoba
E-mail address: fivresearch@yahoo.com

Date of initial submission: 30-11-2019
Date of revised submission: 21-02-2020
Date of acceptance: 06-04-2020

INTRODUCTION

There are many couples in the world with fertility problems. Male factor is usually a problem in about 40% of cases (Brugh and Lipshultz, 2004). Hormones, radiation, tobacco consumption, varicocele, infections, nutritional deficit, oxidative stress, and exercise have been linked to fertility problems (Arce et al., 1993; du Plessis et al., 2011). For several decades, the relationship between physical activity and human fertility has been studied reporting different alterations in sperm parameters such as sperm concentration, motility and morphology among others (De Souza et al., 1994; De Souza and Miller, 1997; Vaamonde et al., 2006, 2009).

In animal models, the reproductive potential has been altered as a consequence of forced swimming at different levels of intensity (Manna et al., 2003, 2004; Mingoti et al., 2003; Saki et al., 2009, 2010; Nirupama et al., 2013). A decrease in fertility rates was observed with a three-minute daily program of forced swimming for 50 days (Saki et al., 2009, 2010). It has been hypothesized that an imbalance between free radicals and body's antioxidants (oxidative stress) plays a role in these changes. Reactive oxygen species (ROS) damage cellular macromolecules, like polyunsaturated fatty acids present in the cell membrane (PUFAs); due to such damage, alterations in cell function may occur (Gozalvez et al., 2017). Sperm cells are especially vulnerable to oxidative degradation of lipids produced by ROS due to the large amount of PUFAs present in their plasma membrane (Griveau and Le Lannou, 1997). Although small amounts of ROS are necessary for sperm to acquire their fertilizing capacity (Aitken, 1997; Griveau and Le Lannou, 1997), when produced in excess such that the antioxidant capacity of the reproductive tract is exceeded, oxidative damage may occur. This may cause, among others, alterations in sperm morphology (Aziz et al., 2004; Agarwal et al., 2008; Tremellen, 2008; Jana et al., 2014). Moreover, it has been reported that abnormal spermatozoa are a source of ROS production, existing a positive correlation between ROS and sperm anomalies (Aziz et al., 2004; Sabeti et al., 2016). The sperm morphology is an important parameter related to fertility potential (Gatimel et al., 2017). In this regards, it has been reported that when the percentage of simple anomalies and, above all, multiple anomalies, increases the fertility decreases (Jouannet et al., 1988; Slama et al., 2002).

To counteract oxidative damage, the body increas-

es its own antioxidant capacity; this can also be aided by exogenous supplementation with antioxidant agents (Agarwal et al., 2004; Tremellen, 2008). Antioxidants counteract the presence of ROS and decrease lipid peroxidation, thereby maintaining the integrity of the PUFAs present in the sperm membrane and, thus, supporting sperm function.

Resveratrol is a natural antioxidant that acts by reducing lipid peroxidation, oxidation and protein nitration (Olas and Wachowicz, 2005). Additionally, resveratrol activates sirtuin-1 and protects mitochondrial function (Price et al., 2012). At the reproductive level, it has been used in animal models where it has been observed to increase the concentration of gonadotropins and testosterone in blood, resulting in increased epididymal sperm output (Juan et al., 2005). Resveratrol has also been reported to protect against testicular damage produced by various oxidizing agents (Jiang et al., 2008) and stress (Bitgul et al., 2013). In humans, the relationship of dietary resveratrol supplementation with regards to fertility has not been studied, yet some studies have reported a protective effect of resveratrol addition to human ejaculates against oxidizing agents such as butylhydroperoxide (Collodel et al., 2011) and the reduction of cryopreservation-induced sperm injury (Li et al., 2018).

In an exercise model, it has been previously used by our group, and was found to reverse the deleterious morphological effects of imposed exercise (Rodriguez et al., 2016).

Ubiquinol (the reduced form of coenzyme Q10) is a liposoluble substance with roles in bioenergetic pathways and antioxidant mechanisms (Litarru, 2007). As an antioxidant, it scavenges free radicals and prevents the initiation and propagation of lipid peroxidation in cell membranes, also helping with the regeneration of other antioxidants such as tocopherol and ascorbate (Crane, 2001). Its activity as an antioxidant has been studied in different tissues, like the testes (Ognjanovic et al., 2010; Fouad et al., 2011; Nadjarzadeh et al., 2013). As a bioenergetic molecule, it is an essential member of the mitochondrial electron transport chain and has a fundamental role in the production of ATP. Coenzyme Q10 deficits can impair mitochondrial capacity (Crane, 2001). Despite its poor solubility, it has been shown that the oral exogenous administration of ubiquinol increases levels of coenzyme-Q10 and ubiquinol in seminal plasma and sperm cells (Balercia et al., 2009; Safarinejad et al.,

2012). Ubiquinol has been reported to improve semen parameters in human patients with fertility problems (Balercia et al., 2009; Safarinejad et al., 2012). However, its effectiveness in subjects undergoing exercise has not yet been assessed.

Different compounds, including vitamin C, which is a water-soluble vitamin, have been used as an excipient to facilitate the absorption of ubiquinol. Vitamin C is present at higher concentrations in seminal fluid compared to blood plasma (Jacob et al., 1992), suggesting an important role. It is essential for the proper progression of spermatogenesis, partly due to its ability to reduce α -tocopherol and maintain this antioxidant in an active state (Aitken and Roman, 2008). Vitamin C also reduces lipid peroxidation and increases testosterone levels. As a result, sperm membrane integrity is protected, and sperm production increases, improving semen parameters (Sönmez et al., 2005; Akmal et al., 2006; Sanghishetti et al., 2014).

The objective of this study was to assess the effect of antioxidant supplementation with either trans-resveratrol or Kaneka's ubiquinol on sperm morphology of mice subjected to a forced swimming exercise protocol.

MATERIAL AND METHODS

Animals

Seventy-five adult (65-day-old) CD-1 male mice (average weight: 40 g) provided by Janvier Labs (France) were used in this study. The total sample size was calculated by using the G*power 3.1.9.4. (Faul et al., 2009). Mice were housed in the Centralized Animal Experimentation Service of the University of Cordoba. A five-day adaptation period was implemented before the study. The animals were housed in individual cages under constant conditions: $21\pm 1^{\circ}\text{C}$, 55% relative humidity and a 12-h light/12-h dark cycle. Mice were given ad libitum access to food and water. Food was pellet chow with a composition of 4% animal-derived protein, 8% vegetable-derived protein, 4.10% minerals and vitamins and 83.90% cereals (barley, wheat, wheat bran, maize, soybean meal) (Panlab S.L. Augy, France).

The animals ($n = 75$) were randomly allocated to one of five groups, with 15 mice per group: non-exercise control group (CG), swimming exercise group without antioxidant supplementation (EX), swimming exercise group with administration of trans-resveratrol (EX-Resv), swimming exercise group with

administration of Kaneka's ubiquinol (EX-Ubiq), swimming exercise group with administration Kaneka's ubiquinol excipient (EX-Excp). The latter group was included in order to determine if the effect of ubiquinol was really due to ubiquinol or to the excipient used, which includes vitamin C. The animals were clinically assessed every day, following the principles of laboratory animal care and always treating them appropriately, in order to exclude any problem that could make them unsuitable for the experiment. The study was approved by the Institutional Animal Care and Use Committee of University of Cordoba (N°7623)

Training protocol

The animals of the EX, EX-Resv, EX-Ubiq and EX-Excp groups were subjected to a daily exercise session of three minutes of forced swimming for 50 days, in circular swimming pools measuring 60 cm in diameter and 80 cm deep with smooth and opaque walls and water with controlled temperature ($33^{\circ}\text{C} - 35^{\circ}\text{C}$). The order in which each animal swam was different and randomly chosen. Once the exercise session was finished, mice were dried with a paper towel and returned to their cages. The animals of the CG group were handled in the same manner as the rest, except for the swimming exercise.

Administration of antioxidants

Besides regular pellets, all mice were given a daily one-gram feed cake made from commercial feed with a caloric intake of 2900 kcal /kg (Panlab S.L.); it was assessed that mice ate the whole cake every day. Prior to the experimental phase, the cakes had been prepared and stored in the freezer until use. The ingredients for the cakes were ground up and moistened with double-distilled water. The CG and EX groups did not receive antioxidant supplementation in the cake. EX-Resv, EX-Ubiq and EX-Excp received antioxidant supplementation that was mixed with the cake as described below. In the EX-Resv group, a dose of 100 mg/kg of trans-resveratrol (Caiman Chemical Company) was added; in the EX-Ubiq group, a dose of 200 mg/kg of a compound elaborated by Kaneka was used (to improve ubiquinol absorption, this compound also included an excipient composed of 73.93% gum Arabic, 20.44% dextrin and 4.63% vitamin C); in the EX-Excp group, the proportion of the excipient corresponding to 200 mg of Kaneka's ubiquinol was used. Twenty cakes were randomly chosen from each batch to verify the anti-

oxidant quantitative content. Trans-resveratrol cakes were analyzed by an extraction method by high performance liquid chromatography (HPLC), with detection by a diode detector array (Rodriguez-Bernaldo et al., 2009). The ubiquinol cakes were analyzed by extraction of the lipid fraction of the feed (with hexane) and separation by HPLC with an electrochemical detector (Lopez-Dominguez et al., 2013). The cakes were administered together with the feed at the end of the exercise period. In the case of trans-resveratrol, these were administered in the afternoon with the beginning of the dark cycle to avoid isomerization of the product by light.

Sample collection and evaluation

The animals were sacrificed by cervical dislocation and subsequent decapitation 24 hours after the final training session. The testes were extracted and the secretion from the cauda epididymis was obtained using a sterile 22 G needle and placed into sterile tube for analysis. An eosin-nigrosin stain was performed for the assessment of sperm morphology (200 sperm assessed for each parameter) (Vital Screen™, FertiPro®). Ten microliters of the sperm sample were mixed in a sterile tube with 20µl of 1% eosin and subsequently mixed with 30µl of 5% nigrosine. Afterwards, the mix was homogenized and finally a 10µl of semen-stain mixture was used for assessment under optical microscopy (Olympus BH-2) at 100x magnification under oil immersion. Sperm morphology was classified, following the criteria of WYROBEK and BRUCE (1975) into normal and abnormal spermatozoa. Abnormalities were classified into four categories: head, midpiece, tail and multiple anomalies. Any spermatozoa exhibiting an abnormality in at least one segment was considered abnormal, when two or more segments were abnormal, sperm were considered as having multiple anomalies. Sperm morphology was always assessed by the same experienced observer to minimize possible inter-observer variability. The data obtained were collected in Microsoft Office Excel

spreadsheets for further statistical analysis.

Statistical analysis

The statistical analysis was carried out with the statistical program STATGRAPHICS Centurion XVI (Stat Point Technologies Inc, 2009). The Pearson Chi-Square test was used to compare differences between groups on sperm morphology. For weight gain and daily intake one-way ANOVA was used to compare if there were differences between groups. The statistical significance level was set at $p < 0.05$.

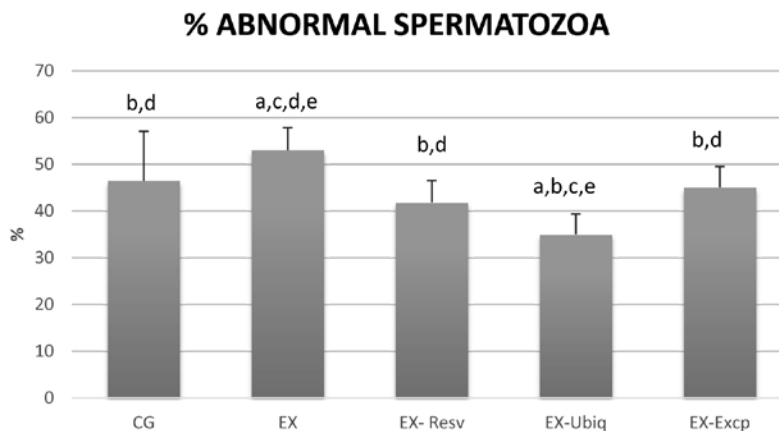
RESULTS

All animals maintained good general health throughout the study period. The body weight gain and food intake did not show any significant difference among groups (Table 1).

Exercise produced an increase in overall abnormal forms (EX:53.03±4.83 Vs CG: 46.47±10.57) ($p < 0.05$) (Figure 1). Moreover, an increase in multiple anomalies was also observed as a result of the exercise intervention (EX:178(5.93%) Vs CG: 126(4.2%)) ($p < 0.05$) (Table 2). With regards to the different segments, midpiece and tail anomalies were statistically greater in EX group than in and CG (Table 2). The administration of either one of the antioxidants or the excipient decreased the percentage of abnormal forms in all treated groups with regards to EX (no antioxidants). Among the different antioxidants, EX-Ubiq exhibited the most noticeable changes, with statistical differences in comparison to the other compounds (Figure 1). Both antioxidants and excipient decreased midpiece anomalies; moreover, although no differences were observed in head anomalies as a result of exercise, the antioxidants were able to decrease the anomalies in this segment (Table 2). However, the only antioxidant able to decrease tail anomalies was trans-resveratrol. With regards to multiple anomalies, both trans-resveratrol and ubiquinol were able to decrease them, while the excipient was not (Table 2).

Table 1. Daily intake, initial weight and final weight in the different groups. (CG = Control group, EX = Exercise group, EX-Resv = Exercise + Resveratrol, EX-Ubiq = Exercise + Ubiquinol, EX-Excp = Exercise + Excipient). Values are mean ± SD. There were no statistical differences between groups.

GROUP	CG(n=15)	EX(n=15)	EX-Resv(n=15)	EX-Ubiq(n=15)	EX-Excp(n=15)
Daily intake (gr)	5.8±1.13	5.4±1.10	5.61±1.04	5.46±1.07	5.34±1.11
Initial weight (gr)	39.3±0.05	41.22±0.17	42.78±0.32	41.76±0.41	38.48±0.47
Final weight (gr)	39.75±1.01	42.57±2.15	43.46±1.47	42.84±1.08	39.82±1.38

Figure 1. Percentage of abnormal spermatozoa observed in different groups.

(CG = Control group; EX = Exercise group; EX-Resv = Exercise + Resveratrol, EX-Ubiq = Exercise + Ubiquinol, EX-Excp = Exercise + Excipient). Values are mean \pm SD for fifteen animals per group ($p < 0.05$).

Superscript letters (a,b,c,d,e) indicates significant differences ($p < 0.05$), with regard to CG (a), with regard to EX (b), with regard to EX-Resv (c), with regard to EX-Ubiq (d), with regard to EX-Excp (e).

Table 2. Number of abnormal sperm with percentages of head, midpiece, tail and multiple anomalies observed in the different groups. (CG = Control group, EX = Exercise group, EX-Resv = Exercise + Resveratrol, EX-Ubiq = Exercise + Ubiquinol, EX-Excp = Exercise + Excipient). Two hundred spermatozoa per mice were assessed, 3000 in total in each group)

GROUP	Head anomalies	Midpiece anomalies	Tail anomalies	Multiple anomalies
CG (n=15)	95(3.16%) ^{cde}	687(22.9%) ^{bd}	486(16.2%) ^{bde}	126(4.2%) ^{be}
EX (n=15)	74(2.46%) ^{cde}	756(25.2%) ^{acde}	583(19.43%) ^{ac}	178(5.93%) ^{acd}
EX-Resv (n=15)	8 (0.26%) ^{ab}	568(18.93%) ^{bd}	526(17.53%) ^b	153(5.1%) ^b
EX-Ubiq (n=15)	12(0.4%) ^{ab}	370(12.33%) ^{abce}	549(18.3%) ^a	120(4.0%) ^{be}
EX-Excp (n=15)	17(0.56%) ^{ab}	579(19.3%) ^{bd}	574(19.13%) ^a	182(6.06%) ^{ad}

Superscript letters (a,b,c,d,e) indicates significant differences ($p < 0.05$), with regard to CG (a), with regard to EX (b), with regard to EX-Resv (c), with regard to EX-Ubiq (d), with regard to EX-Excp (e).

DISCUSSION

In the current study, a three-minute daily forced swimming exercise for 50 days resulted in sperm morphological alterations. A swimming exercise with controlled temperature was employed in this study in such a way as to minimize the changes in testicular temperature. The relationship between exercise and sperm alterations has been studied in animal models reporting alterations in sperm parameters (Mingoti et al., 2003; Saki et al., 2009, 2010; Minaii et al., 2014; Moayeri et al., 2017). One of the parameters that has been reported to be altered as a result of exercise is morphology (Jana et al., 2014; Minaii et al., 2014); this parameter is of essential importance for fertility (Ombelet et al., 1995; Gatimel et al., 2017) and it may be a sensitive tool to measure reproductive potential (Menkveld et al., 2011). Some authors have used a three-minute forced swimming exercise model for 50 days, and, despite not assessing morphology, a decrease in the number and motility of sperm, as well as in in vivo fertilizing capacity, has been reported (Mingoti et al., 2003; Saki et al., 2009, 2010). However,

authors using other models of forced swimming have shown that exercise affects morphology in a manner similar to our study (Jana et al., 2014; Minaii et al., 2014). The physiopathological mechanisms by which exercise causes sperm alterations or fertility problems are not entirely clear. On one hand, exercise may cause alterations in the hypothalamic-pituitary-gonadal axis (HPG) due to physiological stress, decreasing testosterone levels and affecting spermatogenesis (Manna et al., 2003, 2004; Jana et al., 2008). Although hormonal parameters were not evaluated in this study, alterations in this axis could not be ruled out. On the other hand, since sperm membranes are rich in PUFAs, rendering these cells vulnerable to oxidative stress attack (Alvarez and Storey, 1995), exercise-induced oxidative stress may cause increased lipid peroxidation. Numerous studies have demonstrated that oxidative stress causes damage to the epithelium of the seminiferous tubules, altering spermatogenesis and, therefore, increasing the number of spermatozoa with abnormal morphology (Aziz et al., 2004; Aitken and Baker, 2006); in this regard, increased levels of ROS in the

testes have been observed as a result of exercise (Manna et al., 2003, 2004; Nirupama et al., 2013).

When considering the different types of anomalies by the segment involved, it could be observed that midpiece was the main segment affected followed by tail anomalies, results similar to those previously reported by our group (Rodriguez et al., 2016). The midpiece is a fundamental component in sperm due to its mitochondrial content; these organelles are the main source of sperm energy for motility. Thus, midpiece alterations could reflect alterations in the mitochondrial apparatus of the sperm and, thus, changes in sperm energetics. Moreover, while damage in the sperm mitochondria leads to an increase in ROS production, this increase in ROS levels in turn alter mitochondria (Sabeti et al., 2016).

The percentage of multiple anomalies was greater in EX than in CG. It must be highlighted that the presence of multiple anomalies has an important relationship with fertility; as such, it has been observed abnormal sperm correlate with altered functionality as well as with chance of conception (this latter parameter negatively), whether in vivo or in vitro (Slama et al., 2002). Previous studies conducted in exercise models, including ours, have assessed sperm morphology but not the presence of multiple anomalies (Jana et al., 2014; Minaii et al., 2014; Rodriguez et al., 2016)

In the present study, daily oral supplementation with 100 mg/kg of trans-resveratrol resulted in a decreased percentage of abnormal forms with respect to EX group. It seems to protect against damage produced by exercise in the midpiece, tail and multiple anomalies while also decreased head alterations. Whereas a dose of 200 mg/kg was previously found by our group (Rodriguez et al., 2016) to decrease the percentage of head, midpiece and tail anomalies, the dose of 100 mg/kg trans-resveratrol used in the present study, offered the same effect. To the best of our knowledge, the effect of this antioxidant in exercise models has only been assessed by our group so far. There are several mechanisms by which trans-resveratrol could decrease anomalies caused by exercise. One of these could be mediated by the estrogen-like growth-promoting characteristics of the compound, improving the HPG axis and, therefore, spermatogenesis (Juan et al., 2005). This effect has been previously demonstrated, although morphology was not assessed, in healthy mice given an oral supplementation of 20 mg/kg resveratrol; as a result, increased gonadotrophin and testosterone secretion was observed,

along with increased epididymal sperm output (Juan et al., 2005). Similar results have been reported in other animal models (Shin et al., 2008). Another proposed mechanism could be its antioxidant and ROS scavenging activity, which would protect the testis. As such, trans-resveratrol induced an improvement in sperm morphology in a model using rats with induced varicocele (Mendes et al., 2016). Finally, improved mitochondrial function could also be responsible for the observed changes since mitochondria, a fundamental organelle for sperm energetics, are the main source of intracellular ROS (Gibellini et al., 2015). A combination of these different properties is possibly the cause of the observed protection against the damage produced in the exercise condition.

Ubiquinol is another potent antioxidant. In the present study, a daily 200 mg/kg dose of Kaneka's ubiquinol was found to be the antioxidant that best protected against sperm morphological damage. Its effect was similar to that of trans-resveratrol, decreasing head anomalies and protecting against damage in the midpiece caused by exercise, even with statistical significance with regards to the other antioxidant compounds. Also, it decreases multiple anomalies caused by exercise. To the best of our knowledge, this is the first study to assess the effect of ubiquinol on testicular function in mice subjected to a forced exercise model. In human rest models, Safarinejad (2009) reported improved Sertoli cell function and spermatogenesis, but controversial results have been observed in relation to sperm morphology; some authors have showed improved sperm morphology (Safarinejad et al., 2012; Cakiroglu et al., 2014), while others have reported improved sperm motility and density, but not morphology (Safarinejad, 2009). This variation in the results could be due to the lack of homogenization in terms of dosage and administration protocols, as well as differences in commercial forms of the coenzyme Q10. In the present study, the commercial form of ubiquinol has been shown to be readily absorbed (Ikematsu et al., 2006; Ozaki et al., 2010). Ubiquinol, though it involves multiple pathways, likely worked through a similar mechanism to that of resveratrol, decreasing sperm anomalies by either increasing testosterone (Ghanbarzadeh et al., 2014), scavenging ROS, improving the electron transport chain or a combination of pathways (Crane, 2001).

The excipient alone also improved sperm morphology, but to a lesser extent than Kaneka's ubiquinol (which includes the excipient). While it decreases

head and midpiece anomalies, it was ineffective with regards to tail and multiple anomalies. This effect was possibly due to its high content of vitamin C, which is known to have antioxidant capacity (Samanta et al., 2006). As such, it has been shown to improve semen parameters, including morphology, in subfertile individuals (Akmal et al., 2006); similar results were reported in rat models where the observed increased testosterone levels could be responsible for the improvements (Sanghishetti et al., 2014; Okon and Utuk, 2016). Therefore, the combination of the excipient and ubiquinol was the most effective treatment for improving sperm morphology.

It has been shown that both Kaneka's ubiquinol and trans-resveratrol decreased both individual as well as multiple morphological anomalies in sperm. With regards to ubiquinol, while it was the best compound in decreasing total number of abnormal forms, it was not effective for tail anomalies. Conversely, trans-resveratrol was able to decrease anomalies in all segments.

CONCLUSIONS

The present study confirms that the three-minute forced swimming model for 50 days results in

sperm morphological alterations being the midpiece the segment mainly affected. Additionally, antioxidant supplementation with trans-resveratrol, ubiquinol or Kaneka's ubiquinol excipient prevented such anomalies. Lower doses of trans-resveratrol were as effective as higher ones previously used. While the administration of just Kaneka's ubiquinol excipient protected against sperm damage, Kaneka's ubiquinol was the compound that best protected, even exhibiting abnormal morphology percentages lower than those of control group; it is worth mentioning that this is the first time that the effect of ubiquinol has been studied with regards to exercise and sperm morphology. Future studies should focus on investigating the underlying mechanisms by which antioxidant supplementation improves these parameters.

ACKNOWLEDGMENTS

The authors would like to thank Kaneka for providing ubiquinol and excipient, and Prof. Dr. Juan Manuel Serrano and Prof. Dr. Antonio Molina for help with statistics.

CONFLICT OF INTEREST

The authors declare no conflicts of interest.

REFERENCES

- Agarwal A, Nallella KP, Allamaneni SS, Said TM (2004) Role of antioxidants in treatment of male infertility: an overview of the literature. *Reprod Biomed Online* 8:616-627.
- Agarwal A, Makker K, Sharma R (2008) Clinical relevance of oxidative stress in male factor infertility: an update. *Am J Reprod Immunol* 59:2-11.
- Ahmadi S, Bashiri R, Ghadiri-Anari A, Nadjarzadeh A (2016) Antioxidant supplements and semen parameters: An evidence-based review. *Int J Reprod Biomed (Yazd)* 14:729-736.
- Aitken RJ (1997) Molecular mechanisms regulating human sperm function. *Mol Hum Reprod* 3:169-173.
- Aitken RJ, Baker MA (2006) Oxidative stress, sperm survival and fertility control. *Mol Cell Endocrinol* 250:66-69.
- Aitken RJ, Roman SD (2008) Antioxidant systems and oxidative stress in the testes. *Oxy Med Cell Long* 1:15-24.
- Akmal M, Qadri JQ, Noori S, Shahiya T, Afrozul H, Khelod, Y (2006) Improvement in human semen quality after oral supplementation of vitamin C. *J Med Food* 9:440-442.
- Alvarez JG, Storey BT (1995) Differential incorporation of fatty acids into and peroxidative loss of fatty acids from phospholipids of human spermatozoa. *Mol Reprod Dev* 42:334-346.
- Arce JC, De Souza MJ, Pescatello LS, Luciano AA (1993) Subclinical alterations in hormone and semen profile in athletes. *Fertil Steril* 59:398-404.
- Aziz N, Saleh RA, Sharma RK, Lewis-Jones I, Esfandiari N, Thomas AJ, et al (2004) Novel association between sperm reactive oxygen species production, sperm morphological defects, and the sperm deformity index. *Fertil Steril* 81:349-354.
- Balercia G, Buldreghini E, Vignini A, Tiano L, Paggi F, Amoroso S, et al (2009) Coenzyme Q10 treatment in infertile men with idiopathic asthenozoospermia: a placebo-controlled, double-blind randomized trial. *Fertil Steril* 91:1785-1792.
- Bitgul G, Tekmen I, Keles D, Oktay G (2013) Protective effects of resveratrol against chronic immobilization stress on testis. *ISRN Urology* 1-10.
- Brugh VM, Lipshultz LI (2004) Male factor infertility: evaluation and management. *Med Clin North Am* 88:367-385.
- Cakiroglu B, Eyyupoglu SE, Gozukucuk R, Uyanik BS (2014) Ubiquinol Effect on Sperm Parameters in Subfertile Men Who Have Asthenozoospermia with Normal Sperm Concentration. *Nephro Urol Mon* 10 e16870.
- Collodel G, Federico MG, Geminiani M, Martini S, Bonechi C, Rossi C, Figura N, Moretti E (2011) Effect of trans-resveratrol on induced oxidative stress in human sperm and in rat germinal cells. *Reprod Toxicol* 31:239-346.
- Crane FL (2001) Biochemical functions of coenzyme Q10. *J Am Coll Nutr* 20:591-598.
- De Souza MJ, Arce JC, Pescatello LS, Scherzer HS, Luciano AA (1994) Gonadal hormones and semen quality in male runners a volume threshold effect of endurance training. *Int J Sport Med* 15:383-391.
- De Souza MJ, Miller BE (1997) The effect of endurance training on reproductive function in male runners. A 'volume threshold' hypothesis. *Sport Med* 23:357-374.
- du Plessis SS, Kashou A, Vaamonde D, Agarwal A (2011) Is There a Link between Exercise and Male Factor Infertility? *Open Reprod Sci J* 3:105-113.
- Faul F, Erdfelder E, Buchner A, Lang AG (2009) Statistical power analyses using G*Power 3.1: Tests for correlation and regression analyses. *Behav Res Methods* 41: 1149-1160.
- Fouad AA, Al-Sultan AI, Yacoubi M (2011) Coenzyme Q10 counteracts testicular injury induced by sodium arsenite in rats. *Eur J Pharmacol* 655:91-98.
- Gatimel N, Moreau J, Parinaud J, Leandri R (2017) Sperm morphology: assessment, pathophysiology, clinical relevance, and state of the art in 2017. *Andrology* 5:845-862.

- Ghanbarzadeh S, Garjani A, Ziaee M, Khorrami A (2014) Effects of L-carnitine and coenzyme Q10 on impaired spermatogenesis caused by isoproterenol in male rats. *Drug Res* 64:449-453.
- Gibellini L, Bianchini E, De Biasi S, Nasi M, Cossarizza A, Pinti M (2015) Natural Compounds Modulating Mitochondrial Functions. *Evid Based Complement Alternat Med* 527209.
- Gozalvez J, Tvrda E, Agarwal A (2017) Free radical and superoxide reactivity detection in semen quality assessment: past, present, and future. *J Assist Reprod Genetics* 34:697-707.
- Griveau JF, Le Lannou D (1997) Reactive oxygen species and human spermatozoa: physiology and pathology. *Int J Andrology* 20:61-69.
- Ikematsu H, Nakamura K, Harashima S, Fujii K, Fukutomi N (2006) Safety assessment of coenzyme Q10 (Kaneka Q10) in healthy subjects: A double-blind, randomized, placebo-controlled trial. *Reg Tox Pharm* 44:212-218.
- Jacob RA, Pianalto FS, Agee RE (1992) Cellular ascorbate depletion in healthy men. *J Nutr* 122:1111-1118.
- Jana K, Samanta PK, Manna I, Ghosh P, Singh N, Khetan RP, Ray BR (2008) Protective effect of sodium selenite and zinc sulfate on intensive swimming-induced testicular gametogenic and steroidogenic disorders in mature male rats. *Appl Physiol Nutr Metab* 33:903-914.
- Jana K, Dutta A, Chakraborty P, Manna I, Firdaus SB, Bandyopadhyay D, Chattopadhyay R, Chakravarty B (2014) Alpha-lipoic acid and N-acetylcysteine protects intensive swimming exercise mediated germ-cell depletion, pro-oxidant generation, and alteration of steroidogenesis in rat testis. *Mol Reprod Dev* 81:833-850.
- Jiang Y, Peng T, Luo Y, Li MC, Lin, YH (2008) Resveratrol reestablishes spermatogenesis after testicular injury in rats caused by 2,5-hexanedione. *Chin Med J* 121:1204-1209.
- Jouannet P, Ducot B, Feneux D, Spira A (1988) Male factors and the likelihood of pregnancy in infertile couples. I. Study of sperm characteristics. *Int J Androl* 11(5):379-394.
- Juan ME, Gonzalez-Pons E, Munuera T, Ballester J, Rodriguez JE, Planas JM (2005) Trans-Resveratrol, a natural antioxidant from grapes, increases sperm output in healthy rats. *J Nutr* 135:757-760.
- Li SJ, Su WD, Qiu LJ, Wang X, Liu J (2018) Resveratrol protects human sperm against cryopreservation-induced injury. *Zhonghua Nan Ke Xue* 24:499-503.
- Litaru GP (2007) Bioenergetic and Antioxidant Properties of Coenzyme Q10: Recent Developments. *Mol Biotechnology* 37:31-37.
- López-Domínguez JA, Khaiwesh H, González-Reyes JA, López-Lluch G, Navas P, Ramsey JJ, de Cabo R, Burón MI, Villalba, JM (2013) Dietary fat modifies mitochondrial and plasma membrane apoptotic signaling in skeletal muscle of calorie-restricted mice. *Age* 35:2017-2044.
- Manna I, Jana K, Samanta PK (2003) Effect of intensive exercise-induced testicular gametogenic and steroidogenic disorders in mature male Wistar strain rats: a correlative approach to oxidative stress. *Acta Physiol Scand* 178:33-40.
- Manna I, Jana K, Samantha PK (2004) Effect of different intensities of swimming exercise on testicular oxidative stress and reproductive dysfunction in mature male albino Wistar rats. *Indian J Exp Biol* 42:816-822.
- Mendes TB, Paccola CC, de Oliveira Neves FM, Simas JN, da Costa Vaz A, Cabral RE, Vendramini V, and Miraglia SM (2016) Resveratrol improves reproductive parameters of adult rats varicocele in peripuberty. *Reproduction* 152:23-35.
- Menkveld R, Holleboom CA, Rhemrev JP (2011) Measurement and significance of sperm morphology. *Asian J Androl* 13:59-68.
- Minaii B, Moayeri A, Shokri S, Habibi Roudkenar M, Golmohammadi T, Malek F, Barbarestani M (2014) Melatonin improves the sperm quality in forced swimming test induced oxidative stress in nandrolone treated Wistar rats. *Acta Med Iran* 52:496-504.
- Mingoti GZ, Pereira RN, Monteiro CM (2003) Fertility of male adult rats submitted to forced swimming stress. *Braz J Med Biol Res* 36:677-681.
- Moayeri A, Mokhtari T, Hedayatpour A, Abbaszadeh HA, Mohammadpou S, Ramezanihah H, Shokri S (2017) Impact of melatonin supplementation in the rat spermatogenesis subjected to forced swimming exercise. *Andrologia* 18:1-9.
- Nadjarzadeh A, Shidfar F, Amirjannati N, Vafa MR, Montevalian SA, Gohari MR, Nazeri SA, Akhondi MM, Sadeghi MR (2013) Effect of Coenzyme Q10 supplementation on antioxidant enzymes activity and oxidative stress of seminal plasma: a double-blind randomised clinical trial. *Andrologia* 46:177-183.
- Nirupama M, Devaki M, Nirupana R, Yajurvedi HN (2013) Chronic intermittent stress-induced alterations in the spermatogenesis and antioxidant status of the testis are irreversible in albino rat. *J Physiol Biochem* 69:58-68.
- Ognjanovic BI, Markovic SD, Dorđević NZ, Trbojevic IS, Andras AS, Saicic ZS: Cadmium-induced lipid peroxidation and changes in antioxidant defense system in the rat testes (2010) Protective role of coenzyme Q10 and Vitamin E. *Reprod Toxicol* 29:191-197.
- Okon UA, Utuk II (2016) Ascorbic acid treatment elevates follicle stimulating hormone and testosterone plasma levels and enhances sperm quality in albino Wistar rats. *Nig Med J* 57:31-36.
- Olas B, Wachowicz B (2005) Resveratrol, a phenolic antioxidant with effects on blood platelet functions. *Platelets* 16:251-260.
- Ombelet W, Menkveld R, Kruger TF, Steeno O (1995) Sperm morphology assessment: historical review in relation to fertility. *Hum Reprod Update* 1:543-557.
- Ozaki A, Muromachi A, Sumi M, Sakai Y, Morishita K, Okamoto T (2010) Emulsification of Coenzyme Q10 using gum Arabic increase bioavailability in rats and human and improves food-processing suitability. *J Nutr Sci Vitaminol* 56:41-47.
- Price NL, Gomes AP, Ling AJ, Duarte FV, Martin-Montalvo A, North BJ, et al (2012) SIRT1 is required for AMPK activation and the beneficial effects of resveratrol on mitochondrial function. *Cell Metab* 15:675-690.
- Rodríguez-Bernaldo A, Lage-Yusty MA, Lopez-Hernandez J (2009) HPLC-analysis of polyphenolic compounds in Spanish white wines and determination of their antioxidant activity by radical scavenging assay. *Food Res Int* 42:1018-1022.
- Rodríguez I, Díaz A, Vaamonde D (2016) Assessment of the effect of prolonged forced swimming on CD-1 mice sperm morphology with and without antioxidant supplementation. *Andrologia* 48:277-281.
- Sabeti P, Pourmasumi S, Rahiminia T, Akyash F, Talebi AR (2016) Etiologies of sperm oxidative stress. *Int J Reprod Biomed* 14:231-240.
- Safarinejad MR (2009) Efficacy of coenzyme Q10 on semen parameters, sperm function and reproductive hormones in infertile men. *J Urol* 182:237-248.
- Safarinejad MR, Safarinejad S, Shafiee N, Safarinejad S (2012) Effects of reduced form of Coenzyme Q10 (Ubiquinol) on semen parameters in men with idiopathic infertility a double-blind, placebo controlled, randomized study. *J Urol* 188:526-531.
- Saki G, Rahim F, Alizadeh K (2009) Effect of forced swimming stress on count, motility and fertilization capacity of the sperm in adult rats. *J Hum Reprod Sci* 2:72-75.
- Saki G, Rahim F, Kaysi OA (2010) Effect of forced swimming stress on In-vivo fertilization capacity of rat and subsequent offspring quality. *J Hum Reprod Sci* 3:32-34.
- Samanta PK, Manna I, Jana K (2006) Effect of L- ascorbic acid supplementation on testicular oxidative stress and endocrine disorders in mature male rats exposed to intensive swimming exercise. *Reprod Med Biol* 5:145-153.
- Sanghishetti V, Ghongane BB, Nayak BB (2014) Effect of vitamin C on male fertility in rats subjected to forced swimming stress. *J Clin Diagn Res* 8: HC05-HC08.
- Slama R, Eustache F, Ducot B, Jensen TK, Jørgensen N, Horte A, Irvine S, Suominen J, Andersen AG, Auger J, Vierula M, Toppari J, Andersen AN, Keiding N, Skakkebaek NE, Spira A, Jouannet P (2002) Time to pregnancy and semen parameters: a cross-sectional study among fertile couples from four European cities. *Hum Reprod* 17:503-515.
- Sönmez M, Türk G, Yüce A (2005) The effect of ascorbic acid supplementation on sperm quality, lipid peroxidation and testosterone levels of male Wistar rats. *Theriogenology* 63:2063-2072.
- Tremellen K (2008) Oxidative stress and male infertility-a clinical perspective. *Hum Reprod Update* 14:243-258.
- Vaamonde D, Da Silva ME, Poblador MS, Lancho, JL (2006) Reproductive profile of physically active men after exhaustive endurance exercise. *Int J Sport Med* 27:680- 689.
- Vaamonde D, Da Silva- Grigoletto ME, Garcia- Manso JM, Vaamonde- Lemors R, Swanson RJ, Oehninger SC (2009) Response of semen parameters to three training modalities. *Fertil Steril* 92:1941-1946.
- Wyrobek AJ, Bruce, WR (1975) Chemical induction of sperm abnormalities in mice. *Proc Natl Acad Sci USA* 72:4425-4429.