

Journal section: Oral Medicine and Pathology  
 Publication Types: Research

doi:10.4317/medoral.17029  
<http://dx.doi.org/doi:10.4317/medoral.17029>

## Effects of *Chamomilla recutita* (L.) on oral wound healing in rats

Carina-Magalhães-Esteves Duarte <sup>1</sup>, Maria-Rozelide-Souza Quirino <sup>2</sup>, Mônica-César Patrocínio <sup>2</sup>, Ana-Lia Anbinder <sup>3</sup>

<sup>1</sup> DDS, Department of Dentistry, Taubaté University, Taubaté -SP - Brazil

<sup>2</sup> PhD, Assistant Professor, Department of Dentistry, Taubaté University, Taubaté-SP-Brazil

<sup>3</sup> PhD, Assistant Professor, Department of Bioscience and Oral Diagnosis, School of Dentistry of São José dos Campos, UNESP-Universidade Estadual Paulista, São José dos Campos-SP-Brazil

### Correspondence:

R. Engenheiro Francisco José Longo, 777,  
 Jardim São Dimas,  
 São José dos Campos CEP 12245-000,  
[ana.anbinder@fosjc.unesp.br](mailto:ana.anbinder@fosjc.unesp.br)

Duarte CM, Quirino MR, Patrocínio MC, Anbinder AL. Effects of *Chamomilla recutita* (L.) on oral wound healing in rats. Med Oral Patol Oral Cir Bucal. 2011 Sep 1;16 (6):e716-21.  
<http://www.medicinaoral.com/medoralfree01/v16i6/medoralv16i6p716.pdf>

Received: 03/04/2010  
 Accepted: 04/06/2010

Article Number: 17029 <http://www.medicinaoral.com/>  
 © Medicina Oral S. L. C.I.F. B 96689336 - pISSN 1698-4447 - eISSN: 1698-6946  
 eMail: [medicina@medicinaoral.com](mailto:medicina@medicinaoral.com)

### Indexed in:

Science Citation Index Expanded  
 Journal Citation Reports  
 Index Medicus, MEDLINE, PubMed  
 Scopus, Embase and Emcare  
 Índice Médico Español

### Abstract

**Objectives.** The purpose of this study was to evaluate the effect of *Chamomilla recutita* on the healing of ulcers in rats.

**Study Design.** A 5-mm wound was inflicted on the tongue of 36 rats. Treatment group animals were treated topically with 0.04 mL/day of chamomile ointment, whereas control group animals were not treated. Animals were sacrificed after 3, 7 or 10 days. Semi-quantitative analysis of the degree of inflammation, fibroblast count and wound size was performed, as well as histometric analysis of re-epithelialization and percentage of collagen fibers of the lesion.

**Results.** Animals treated with chamomile showed the best results regarding epithelialization and percentage of collagen fibers after 10 days. As expected, time had a statistically significant effect ( $p < 0.05$ ) on fibroblast count, epithelialization, inflammation and wound size; animals sacrificed at 3 days showed the worst results.

**Conclusions.** Chamomile stimulated re-epithelialization and the formation of collagen fibers after 10 days of treatment; it did not, however, influence inflammation or fibroblast count.

**Key words:** Chamomile, wound repair, oral ulcer.

### Introduction

The most common lesions of the oral cavity include ulcers caused by trauma, designated traumatic ulcers, and recurrent aphthous ulcers (1-3). The loss of epithelium and exposure of connective tissue that characterize ulcers cause pain and discomfort, affecting the quality of life of patients.

There are various options of topical therapy for ulcers, which can be used in isolation or in combination: anti-

inflammatory medications, antimicrobial agents, anesthetics, protective films and laser. Over the last decades, an increasing number of patients have used medicinal plants and sought medical guidance for their use (4). Particularly in developing countries, herbal medications are extremely popular for historical and cultural reasons (5).

Chamomile, also known as *Chamomilla recutita* (L.) Rauschert (synonymous with *Matricaria recutita* L.,

*M. chamomilla* L. and *M. suaveolens* L.), of the Asteraceae family, is one of the tea ingredients most used worldwide. It is a well-known medicinal plant that has been used for centuries, particularly because of its anti-inflammatory, antimicrobial, antispasmodic and sedative effects (4). The principal chemical components of the flowers include several phenolic compounds, primarily the flavonoids apigenin, quercetin, patuletin, luteolin and their glucosides. The main components of the essential oil extracted from the flowers are the terpenoids alpha-bisabolol and its oxides and azulenes, including chamazulene (5-9). Anti-inflammatory, antimicrobial and antioxidant medications are good choices for the treatment of wounds (10).

There are few studies in the field of dentistry that investigate the effects of chamomile. The plant has proven effective in reducing methotrexate-induced oral mucositis (11), in removing the smear layer during root canal preparation in *in vitro* studies (12) and in accelerating oral ulcer healing in animals (13) and in humans (14). The purpose of this study was to evaluate the effect of treatment with chamomile extract ointment on the healing of tongue ulcers in rats, at three different time points.

## Material and Methods

Thirty-six adult male Wistar rats (*Rattus norvegicus albinus*) weighing approximately 300 g each were used in the present study. The rats were kept in cages at room temperature and were given *ad libitum* access to food and water. The present study was approved by the Animal Research Ethics Committee of the University of Taubaté.

All animals were anesthetized with a mixture of 13 mg/kg of xylazine (2%) and 33 mg/kg of ketamine via intramuscular injection. After anesthesia, the tongue was pulled and a wound was inflicted in the central region, 3 mm from the tip, using a punch of 5 mm in diameter. The lesion had 1 mm in depth and was limited to the mucosa, without muscular involvement.

The animals were randomly assigned to two groups, treatment and control, using a table of random numbers. The animals of the treatment group received topical application of 0.02 mL of chamomile fluid extract ointment 10% (Ad Muc; Biolab, Taboão da Serra, SP, Brazil) twice daily, with 12-h intervals between applications. The first dose of the ointment was administered on the day after the surgery. The animals were restrained and their mouths were kept open for ointment application using an adapted rubber dam clamp forceps. In the control group, the wounds were not treated, but the animals were handled in the same manner as were those from the treatment group in order to simulate surgical stress.

Each of the two groups was randomly subdivided into

three subgroups, as follows: animals sacrificed at 3 days, animals sacrificed at 7 days and animals sacrificed at 10 days. The animals were anesthetized and subsequently decapitated using a guillotine. The tongues were removed, fixed and stained with hematoxylin and eosin (H&E) for histological examination. Samples from animals sacrificed at 10 days were also stained with picrosirius red in order to evaluate the percentage of collagen fibers in the center of wound area.

The histological images of sections stained with H&E were digitized (magnification,  $\times 200$ ), with the care to locate the center of the wound in the center of the microscopic field. The area of epithelium covering the experimental lesion on the digitized images was evaluated using the ImageJ 1.31p image processing software (National Institutes of Health, Bethesda, MD, USA). The images of the sections stained with picrosirius red and obtained by polarization microscopy were digitized (magnification,  $\times 400$ ). The percentage of collagen fibers in the subepithelial granulation tissue was assessed using the ImageJ and AdobePhotoshop 7.0.1 (Adobe Systems Incorporated, San Jose, CA, USA) programs. First, the image of red hue collagen fibers were selected with the aid of the AdobePhotoshop 7.0.1 image processing software. The selected image was then transferred to the ImageJ 1.31p software, where it was binarized, and the percentage of area occupied by collagen fibers was calculated.

The degree of inflammation, fibroblast counts, and wound size were evaluated in a semi-quantitative manner. The degree of inflammation was evaluated according to the following scores: 0 = none; 1 = mild; 2 = moderate; and 3 = severe. Fibroblast count was evaluated according to the following scores: 0 = absence of fibroblasts; 1 = few fibroblasts; 2 = presence of disorganized fibroblasts; and 3 = presence of fibroblasts parallel to the wound surface. The size of the wound was evaluated according to the following scores: 0 = closed wound; 1 = small; 2 = medium; and 3 = large. The scores for wound size were attributed according to the width and depth of inflamed tissue that differed from the standard of normality for the tongue. Therefore, two scores for wound size were attributed to each section: one for width and another for depth. The final score (ranging from 0 to 9) resulted from the multiplication of the scores attributed to each of the dimensions.

All analyses were performed by the same calibrated examiner, who did not know to which group the sections belonged.

For statistical analysis, the independent variables were time and treatment, whereas the dependent variables were epithelialization, percentage of collagen fibers, degree of inflammation, fibroblast count and wound size. The data regarding percentage of collagen fibers were submitted to the Student's t-test; the remaining

data were submitted to the Kruskal-Wallis and Man-Whitney tests. The significance level was set at 5% for all tests performed. The tests were performed using the Bioestat 2.0 (Sociedade Civil Mimirauá, Belém, Brazil) and GraphPad Prism 4.0 (GraphPad Softwares Inc., San Diego, CA, USA) programs.

## Results

Due to technical difficulties, one of the treated animals sacrificed at 10 days was excluded from all analyses.

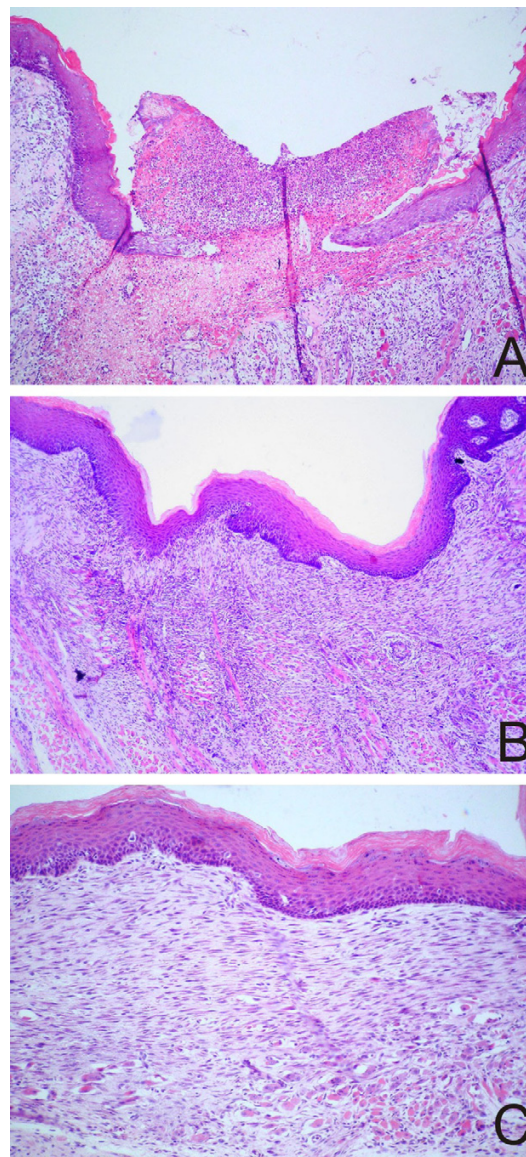
### *Histomorphologic analysis*

The most significant effects observed during histomorphologic analysis were related to the experimental period; differences due to the treatment were rarely perceived.

In animals sacrificed at 3 days, a wide ulcerated lesion, covered by a fibrinopurulent membrane, was observed. In the connective tissue, severe acute inflammation and a high number of polymorphonuclear cells, as well as few lymphocytes and plasma cells amid areas of edema, were observed (Fig. 1A). Few mast cells were observed in the inflammatory infiltrate. In various samples, a thin lining of orthokeratinized stratified squamous epithelium began to proliferate from the wound edge, in order to cover the connective tissue (Fig 1A). Fibroblast proliferation was observed at the base of the ulcer; few plump fibroblasts were scattered irregularly, accompanied by newly formed blood vessels, characterizing quite immature granulation tissue.

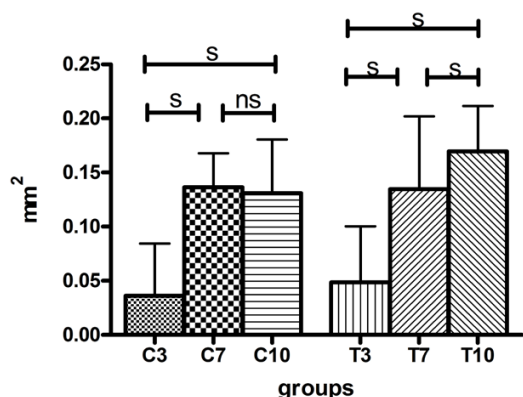
In most animals sacrificed at 7 days, the ulcer was covered by thin, orthokeratinized stratified squamous epithelium. A flattened basal layer was observed, and there was no formation of lingual papillae (Fig. 1B). No fibrinopurulent membrane or edema was observed. The intense acute inflammation observed at 3 days had been widely replaced by less immature granulation tissue. A moderate number of mononuclear cells, few polymorphonuclear cells, newly formed blood vessels and many plump fibroblasts were observed (Fig. 1B). Fibroblasts were arranged in a more disorganized manner in control samples than in treatment samples. In treatment samples, fibroblasts and fibers were parallel to the surface.

In all samples from animals sacrificed at 10 days, the surgical wound was covered by orthokeratinized stratified squamous epithelium. However, differentiation of lingual papillae was more pronounced in samples from treated animals. Granulation tissue was more mature; fibroblasts were less plump and more abundant. They were parallel to the surface and amid delicate fibers, which were also parallel to the surface (Fig. 1C). In some cases, the granulation tissue had been replaced with fibrous connective tissue presenting normal characteristics. Mononuclear inflammatory cells were occasionally observed.



**Fig. 1. A.** Ulcer covered by a fibrinopurulent membrane and epithelium proliferation from the wound edges, in the control group at 3 days (Original magnification,  $\times 100$ ; Hematoxylin and eosin staining). **B.** Orthokeratinized stratified squamous epithelium in the treatment group at 7 days, without formation of papillae. Note the flattened basal layer covering the wounded area. Granulation tissue showing fibroblasts arranged in different directions and muscular tissue at the base of the lesion (Original magnification,  $\times 100$ ; Hematoxylin and eosin staining). **C.** Surgical wound covered by orthokeratinized stratified squamous epithelium without formation of papillae in the control group at 10 days. Granulation tissue showing fibroblasts parallel to the surface, less plump than those observed at previous time points (Original magnification,  $\times 200$ ; Hematoxylin and eosin staining).





**Fig. 2.** Mean and standard-deviation of epithelialization area over the experimental lesion (mm<sup>2</sup>). C: control group; T: treatment group. s: statistically significant difference (p<0.05); ns: statistically non-significant difference (p>0.05).

*Quantitative analysis*

No significant differences were observed between control and treated animals sacrificed at 3 days, or between control and treated animals sacrificed at 7 days. Treated animals sacrificed at 10 days showed greater re-epithelialization (mean ± SD; 0.1696 ± 0.0418 mm<sup>2</sup>) than did control animals sacrificed at 10 days (mean ± SD; 0.1309 ± 0.0497 mm<sup>2</sup>; p = 0.008). Time had a significant effect on epithelialization in control and treatment groups (p = 0.001), as expected. The worst results regarding epithelialization were observed in animals sacrificed at 3 days (Fig. 2). In the treatment group, a significant difference in epithelialization was observed between animals sacrificed at 7 days and animals sacrificed at 10 days; in the control group, this difference was not observed (Fig. 2).

Percentage of collagen fibers was only assessed in animals sacrificed at 10 days. Treated animals showed a greater percentage of collagen fibers (mean ± SD; 8.255 ± 2.9955%) than did control animals (mean ± SD; 6.025 ± 3.1815%; p = 0.022).

*Semi-quantitative analysis*

Descriptive statistics were used in the analysis of the scores for inflammation, fibroblast count and wound size (Table 1).

No significant differences were observed between control and treated animals, after 3, 7 or 10 days, regarding to the scores for inflammation, fibroblast count and wound size. As expected, again, according to the Kruskal-Wallis test, the experimental period had a significant effect on all dependent variables evaluated semi-quantitatively, in treatment and control groups (p = 0.001). Animals sacrificed at 3 days showed a greater degree of inflammation and larger wound size, as well as the lowest fibroblast count scores (Table 1). No significant difference in the degree of inflammation, fibroblast count or wound size was observed between animals sacrificed at 7 days and those sacrificed at 10 days.

**Discussion**

Wound healing constitutes a perfectly coordinated cascade of cellular and molecular events that interact in order to promote tissue repair. Various authors have investigated medications that might accelerate wound healing, reduce painful symptoms associated with oral ulcers and have an optimal cost-benefit ratio.

Various methods and formulations have been used to investigate the effect of chamomile on tissue repair in animals. Nayak et al. (15) evaluated the effects of oral administration of 120 mg/Kg of chamomile flower ex-

**Table 1.** Descriptive statistics of the scores for inflammation (I), fibroblast count (FC) and wound size (WS). C: control group; T: treatment group. The numbers 3, 7 and 10 refer to observation period.

	I	FC	WS	I	FC	WS	I	FC	WS
	Median			Mean			Standard Deviation		
C3	3	1	9	3	0.889	8.111	0	0.323	1.779
C7	2	3	4	2	2.667	4.556	0.686	0.594	2.307
C10	1	3	3	1.5	2.722	3.222	0.618	0.575	1.833
T3	3	1	6	2.944	0.889	7.056	0.236	0.323	1.955
T7	2	2	4	2	2.333	3.667	0.908	0.594	2.142
T10	2	3	2	1.667	2.533	2.467	0.488	0.640	1.685

tract in drinking water. They observed more rapid epithelialization, reduced wound size, increased number of fibroblasts and hydroxyproline content, an indicator of collagen turnover, as well as reduced inflammation in the animals treated with chamomile flower extract. In the present study, greater epithelialization and percentage of collagen were associated with the use of chamomile after 10 days of topical treatment. However, no statistically significant improvement occurred after 3 or 7 days of treatment. Dose schedule tested was based on manufacturer's instructions. The amount of ointment used at each application (0.02 mL) was enough to cover the wound.

Some authors (10) noted accelerated healing of extensive skin burns, beginning at 20 days, in rats treated topically with chamomile in olive oil. Martins et al. (13) evaluated the effects of chamomile on 3-mm wide ulcers in rat tongues, employing the same pharmaceutical form used in the present study and quite similar methodology. The authors noted that the group of animals treated with chamomile showed complete ulcer healing on day 5, whereas animals treated with corticosteroids only reached that stage of repair on day 14. Corticosteroids are widely used in the topical treatment of canker sores (3) and traumatic ulcers and, despite the route of administration, can have adverse systemic effects (13). Therefore, in order to avoid such adverse effects (and also due to low cost, easy access, low toxicity and easy administration) some practitioners prefer to prescribe herbal medications such as chamomile (13). Despite the positive outcomes of chamomile treatment regarding tissue repair, the exact mechanism of action of the plant remains unclear (10).

We did not find significant differences between the control and treatment groups regarding the degree of inflammation and the size of the wound. This is in disagreement with the results obtained by other authors, who noted the anti-inflammatory effects of chamomile (13,15). The lack of significant difference between the groups in the semi-quantitative analysis might indicate that quantitative evaluations are more accurate. Although chamomile treatment had no effect on fibroblast counts at any of the time points considered in the present study, higher collagen content (a product of fibroblast secretion) was observed in animals treated with chamomile after 10 days of treatment. Some authors have suggested that collagen type I, with thicker fibers, presented a red color in polarization microscopy while collagen type III, with thinner fibers, appeared green (16). However, although type III fibers are usually thinner than type I fibers, it may not be valid to state that green fibers are type III and orange fibers type I. It is possible that a green fiber may be an immature, thin type I. In our work, we only evaluated the predominant red hue collagen fibers. The chamomile treatment had

a greater influence on fibroblast activity than it did on fibroblast count. Since flavonoids, such as quercetin and apigenin present in chamomilla, are known to inhibit matrix-metalloproteinase-1 (MMP-1) and down-regulate MMP-1 expression via an inhibition of the activator protein-1 (AP-1) activation (17), the increased level of collagen could result from the inhibition of metalloproteinases activity. The percentage of collagen fibers was not assessed at 3 days or at 7 days because the formation of fibers was not evident at those time points.

In the present study, there was not a group which received placebo ointment. However, a research (18) investigated the healing of 5mm wounds of rat tongues treated with three different medications (propolis in propylene glycol, triamcinolone acetonide in oromucosal paste and oromucosal paste). The authors, who used methods similar to ours, and sacrificed animals after 3, 7 or 10 days, concluded that the control group (animals that did not receive treatment) and the oromucosal paste group showed similar healing patterns throughout the 10-day experimental period (18). This confirms the absence of placebo effect in this methodology and supports the hypothesis that the medication effects observed in the present study were due to the active principles of chamomile, not to the physical protection of the wound.

Despite the promising results of studies *in vitro* and in animal models, few studies have investigated the effect of chamomile on oral tissue repair in humans, often showing controversial results. Although some authors (11) have reported improvement of methotrexate-induced mucositis using mouth rinses of chamomile, Fidler et al. (19), who investigated 164 patients with 5-fluoracil-induced mucositis, found no significant differences between the group treated with chamomile and the placebo group. With regard to the relief of painful symptoms of canker sores, the analgesic effects of the ointment used in the present study were considered excellent by 82% of the population investigated by Ramos-e-Silva et al. (14). Further studies investigating the effects of chamomile on oral lesions in humans are needed, as well as studies aimed at elucidating the mechanisms of action of the plant.

The use of chamomile extract ointment according to the methodology of the present study stimulated re-epithelialization and formation of collagen fibers after 10 days of treatment; chamomile did not, however, influence the degree of inflammation, fibroblast count or wound size.

## References

*References with links to Crossref - DOI*

1. Martínez Díaz-Canel AI, García-Pola Vallejo MJ. Epidemiological study of oral mucosa pathology in patients of the Oviedo School of Stomatology. *Med Oral*. 2002;7:4-9, 10-6.
2. Rioboo-Crespo Mdel R, Planells-del Pozo P, Rioboo-García R. Epidemiology of the most common oral mucosal diseases in children. *Med Oral Patol Oral Cir Bucal*. 2005;10:376-87.
3. Femiano F, Lanza A, Buonaiuto C, Gombos F, Nunziata M, Pic-

- colo S, et al. Guidelines for diagnosis and management of aphthous stomatitis. *Pediatr Infect Dis J.* 2007;26:728-32.
4. O'Hara M, Kiefer D, Farrell K, Kemper K. A review of 12 commonly used medicinal herbs. *Arch Fam Med.* 1998;7:523-36.
  5. World Health Organization. Monographs on selected medicinal plants. v.1. Geneva (Switzerland): WHO; 1999. [cited 2009 Jun 12]; Available from: <http://whqlibdoc.who.int/publications/2002/9241545178.pdf>.
  6. Jakovlev V, Isaac O, Thiemer K, Kunde R. [Pharmacological investigations with compounds of chamomile ii. new investigations on the antiphlogistic effects of (-)-alpha-bisabolol and bisabolol oxides (author's transl)]. *Planta Med.* 1979;35:125-40.
  7. Avallone R, Zanolli P, Puia G, Kleinschnitz M, Schreier P, Baraldi M. Pharmacological profile of apigenin, a flavonoid isolated from *Matricaria chamomilla*. *Biochem Pharmacol.* 2000;59:1387-94.
  8. Szoke E, Máday E, Tyihák E, Kuzovkina IN, Lemberkovics E. New terpenoids in cultivated and wild chamomile (in vivo and in vitro). *J Chromatogr B Analyt Technol Biomed Life Sci.* 2004;800:231-8.
  9. McKay DL, Blumberg JB. A review of the bioactivity and potential health benefits of chamomile tea (*Matricaria recutita* L.). *Phytother Res.* 2006;20:519-30.
  10. Jarrahi M. An experimental study of the effects of *Matricaria chamomilla* extract on cutaneous burn wound healing in albino rats. *Nat Prod Res.* 2008;22:422-7.
  11. Mazokopakis EE, Vrentzos GE, Papadakis JA, Babalis DE, Ganotakis ES. Wild chamomile (*Matricaria recutita* L.) mouthwashes in methotrexate-induced oral mucositis. *Phytomedicine.* 2005;12:25-7.
  12. Sadr Lahijani MS, Raoof Kateb HR, Heady R, Yazdani D. The effect of German chamomile (*Matricaria recutita* L.) extract and tea tree (*Melaleuca alternifolia* L.) oil used as irrigants on removal of smear layer: a scanning electron microscopy study. *Int Endod J.* 2006;39:190-5.
  13. Martins MD, Marques MM, Bussadori SK, Martins MA, Pavesi VC, Mesquita-Ferrari RA, et al. Comparative analysis between *Chamomilla recutita* and corticosteroids on wound healing. An in vitro and in vivo study. *Phytother Res.* 2009;23:274-8.
  14. Ramos-e-Silva M, Ferreira AF, Bibas R, Carneiro S. Clinical evaluation of fluid extract of *Chamomilla recutita* for oral aphthae. *J Drugs Dermatol.* 2006;5:612-7.
  15. Nayak BS, Raju SS, Rao AV. Wound healing activity of *Matricaria recutita* L. extract. *J Wound Care.* 2007;16:298-302.
  16. Junqueira LC, Cossermelli W, Brentani R. Differential staining of collagens type I, II and III by Sirius Red and polarization microscopy. *Arch Histol Jpn.* 1978;41:267-74.
  17. Lim H, Kim HP. Inhibition of mammalian collagenase, matrix metalloproteinase-1, by naturally-occurring flavonoids. *Planta Med.* 2007;73:1267-74.
  18. Lemos-Júnior CA, Pinto Junior DS, Lotufo MA, Amorim CG, Silveira FRX. Análise da cicatrização de lesões traumáticas em língua de ratos com uso da própolis, Omcilon-A e orabase. *Braz Oral Res.* 2005; 19:238. Available from: [http://iadr.confex.com/iadr/brazil05/preliminaryprogram/abstract\\_86575.htm](http://iadr.confex.com/iadr/brazil05/preliminaryprogram/abstract_86575.htm)
  19. Fidler P, Loprinzi CL, O'Fallon JR, Leitch JM, Lee JK, Hayes DL, et al. Prospective evaluation of a chamomile mouthwash for prevention of 5-FU-induced oral mucositis. *Cancer.* 1996;77:522-5.

#### **Acknowledgments**

We would like to thank the University of Taubaté for the financial support and the technician Maria de Fátima Pacheco, of the Histology Laboratory of the Basic Institute of Biosciences of the University of Taubaté, Taubaté, Brazil, for her invaluable contribution to the preparation of histological slides.