

Effects of *Corchorus Olitorius* and Protocatechuic Acid on Cadmium-Induced Rat Testicular Tissue Degeneration

✉ Katriye Komili¹, ✉ Gizem Söyler², ✉ Pelin Toros¹, ✉ İhsan Çalıř³, ✉ Aysel Kükner¹

¹Department of Histology and Embryology, Near East University Faculty of Medicine, Nicosia, Cyprus

²Department of Histology and Embryology, Koç University, School of Health Sciences and School of Medicine, İstanbul, Turkey

³Department of Pharmacognosy, Near East University Faculty of Pharmacy, Nicosia, Cyprus

Abstract

BACKGROUND/AIMS: Cadmium element, a heavy metal, has toxic effects on the reproductive system. The current study investigates the possible therapeutic effects of *Corchorus olitorius* (CO) and Protocatechuic acid (PCA) on the damage caused by cadmium chloride on rat testicular tissue.

MATERIALS AND METHODS: Control, CO, PCA, cadmium chloride, cadmium chloride + PCA and cadmium chloride + CO was formed groups. CO and PCA was administered orally 250 mg/kg and 20 mg/kg respectively. Cadmium chloride dose of 3.5 mg/kg was administered intraperitoneally. At the end of the three-week experiment period, body weight of rats was measured then testicular tissues were removed and weighed separately. Testicular tissue sections were stained with, Hematoxyline & Eosin, Periodic Acid Schiff, Masson trichrome and terminal deoxynucleotidyl transferase dUTP nick end labeling (TUNEL). TUNEL (+) apoptotic cells were counted and evaluated statistically.

RESULTS: Testicular weights of the cadmium-given group decreased significantly compared to the control groups. In the cadmium-administered group, basal membrane structures and seminiferous tubules were disrupted, tubules without sperm were observed, connective tissue and inflammatory cell increase and oedema occurred in the interstitial space. It was determined that degeneration was continuing in the treatment groups, but inflammatory cell numbers and oedema in the interstitial tissue were reduced. Additionally, the same seminiferous tubules with sperm were also observed. It was observed that apoptotic cells increased significantly in the cadmium-administered group compared to the control groups and decreased in the treatment groups.

CONCLUSION: PCA and CO were realized to be unable to completely prevent but reduce the toxic effects of cadmium on testicular tissue.

Keywords: Testis, cadmium chloride, protocatechuic acid, *Corchorus olitorius*

INTRODUCTION

Cadmium (Cd) is a toxic substance included in the list of heavy metals that is hazardous to the human health published by the World Health Organization and is frequently encountered in daily life. The half-life in humans is about 20–30 years, the rate of excretion from the body is low and accumulates primarily in the liver and kidneys. Cadmium is absorbed from cigarettes,

food, contaminated water and air in significant quantities and has many undesirable effects in living organisms. Professions such as mining, nickel-cadmium battery production, electro plating and pigmented paint also expose people to cadmium.¹⁻³ Cadmium has been reported that it reduces male fertility, impair reproductive capacity and play an important role in the pathogenesis of infertility. Testicular tissue is very sensitive to the

To cite this article: Komili K, Söyler G, Toros P, Çalıř İ, Kükner A. Effects of *Corchorus Olitorius* and Protocatechuic Acid on Cadmium-Induced Rat Testicular Tissue Degeneration. Cyprus J Med Sci 2022;7(1):87-93

ORCID iDs of the authors: K.K. 0000-0003-1309-0431; G.S. 0000-0002-8192-906X; P.T. 0000-0002-8733-2096; İ.Ç. 0000-0001-5489-3420; A.K. 0000-0001-5387-2628.



Address for Correspondence: Aysel Kükner

E-mail: akukner@hotmail.com

ORCID ID: orcid.org/0000-0001-5387-2628

Received: 09.04.2020

Accepted: 24.08.2020



©Copyright 2022 by the Cyprus Turkish Medical Association / Cyprus Journal of Medical Sciences published by Galenos Publishing House. Content of this journal is licensed under a Creative Commons Attribution 4.0 International License

toxic effect of cadmium. Cadmium reduces testicular weights, causes structural disorders in seminiferous tubules, disrupts the blood-testicle barrier, causes the death of germ cells and inhibits the production of testosterone from Leydig cells and generates oedema. It negatively affects sperm production, sperm count, and morphology.^{4,5} Extended exposure to cadmium, hence increased accumulation, causes DNA methylation in the testicle that can result in epigenetic changes.⁶

Cadmium induces oxidative stress, causing irreversible damage to organs. Protocatechuic acid (PCA), which has an antioxidant effect, has a protective effect against toxic substances in the body. PCA is mainly found in fruits, nuts, vegetables.⁷ PCA reduces apoptosis caused by cadmium and has an anti-inflammatory effect. It has been reported that PCA increases sperm count, prevents changes in morphology, reduces the presence of weak sperms and prevents infertility.⁸ It has been observed to increase the level of testosterone and sperm function.⁹ It has also been reported that degenerative changes and oxidative stress occurring in testicular tissue due to cadmium are reduced by PCA.¹⁰

Experimental studies are conducted on protective effects of plants and herbal extracts and their roles in reducing or preventing tissue damage.¹¹ One of the ethnic plants with antioxidant properties is *Corchorus olitorius* and it is widely used in Mediterranean Countries. This plant known as “Molehiya” and consumed as food in their dietary habits. It is very rich in protein, carbohydrate, calcium, potassium, iron, sodium, vitamins A, C, and E. Because of the studies, it was found that it reduces oxidative stress due to its anti-inflammatory effect.¹²

Today, an effective treatment method or an effective component against Cd toxicity has not been found yet. In cadmium-bound tissues, the effects of various antioxidant substances are studied to prevent or alleviate degeneration in organs. The current study investigates the effects of *Corchorus olitorius* and antioxidant PCA on the damage caused by cadmium chloride on testicular tissue. There have been a limited number of studies on this subject in the literature review.

MATERIALS AND METHODS

In the study, young adolescent male (2 months old) Wistar albino rats, weighing an average of 170–250 gr, were used. Rats contained at 22°C temperature in 12 h of dark/light care rooms and fed at controlled amounts with standard feed and water as ad libitum. Rats were randomly divided into six groups:

Group 1 (n=6): Control group

Group 2 (n=6): 3.5 mg/kg intraperitoneal CdCl₂ administration (Sigma-Aldrich USA) twice a week.

Group 3 (n=6): 20 mg/kg oral Protocatechuic Acid administration.

Group 4 (n=6): 250 mg/kg oral *Corchorus olitorius* administration.

Group 5 (n=6): 3.5 mg/kg intraperitoneal CdCl₂ administration twice a week and 250 mg/kg oral *Corchorus olitorius* administration daily.

Group 6 (n=6): 3.5mg/kg intraperitoneal CdCl₂ administration twice a week and 20 mg/kg oral PCA administration daily.

Corchorus Olitorius Extraction

CO plant was freshly collected from Demirhan Region of Northern Cyprus and its extract was prepared in the Pharmacognosy laboratory of NEU Faculty of Pharmacy.

Cultured *Corchorus olitorius*, the leaves were separated from the stems, and kept at shade until dry. Air dried plant material (500 g) subjected to EtOH (96%) by using percolator for 24 h. After filtration, the extract was transferred into a tared flask and extract was concentrated under reduced pressure to dryness at 40 °C. Finally, the yield was calculated.

Histology

At the end of three-week experiment period, testes were removed from the subjects under anesthesia of ketamine and xylazine. Body and testes weights of subjects were measured. Testis fixation was done with 10% neutral formaldehyde and paraffin blocks were prepared. 5 µm thick sections were stained with Hematoxyline-Eosin, Periodic Acid Schiff, and Masson Trichrome. Additionally, to determine apoptotic cells Terminal-deoxynucleotidyl Transferase Mediated Nick end-labeling (TUNEL, Apop Tag, S7101, Merck) staining was performed. TUNEL (+) stained cells were counted in 20 seminiferous tubules belonging to the testicle sections of each subject.

Statistical Analysis

According to the data distribution, the groups were compared by performing Kruskal-Wallis analysis, and pairwise post hoc comparisons were made using Mann-Whitney U tests with Bonferroni correction. Statistical Package for Social Sciences 25.0 for Windows (SPSS Inc., Chicago, Illinois, USA) was used for conducting the analysis. Statistical significance was set at p<0.05.

RESULTS

At the end of the experiment, it was determined that the body weights of the cadmium-administered group was lower than the other groups, however the difference was not statistically significant. When the testicular weights of the subjects in the groups were evaluated, the cadmium-administered group without treatment and with PCA and CO (p<0.05) treatment showed significant decrease compared to the control, PCA and CO groups. While the cadmium-administered group with PCA treatment

showed a significant increase in testicular weight compared to the cadmium administered group without treatment, no significant difference with the CO treated group was observed. Testicular weights of the control group were similar to the PCA-only and CO-only treatment groups (Table 1). In the testicular tissue of the control group (Figure 1a); spermatogenetic, Leydig cells in the interstitial space and Sertoli cells (Figure 1b) were detected to be normal. Seminiferous tubule basal membrane structures (Figure 1c) and connective tissue of interstitial compartment among tubules (Figure 1d) were methodically distinguished. The seminiferous tubule cells, Leydig cells, basal membrane and interstitial tissue of PCA-only and CO-only treatment groups were observed to be similar as the control group. In the subject group with generated cadmium toxicity, it was observed that seminiferous tubules were highly degenerated, the spermatogenetic cell lines were not clearly distinguishable (Figure 2a), cellular debris was present in the seminiferous tubule lumens due to degeneration (Figure 2b), the number of inflammatory cells was high and substantial amount of oedema was existent in the interstitial tissue (Figure 2c). The increased amount of connective tissue in the interstitial tissue (Figure 2d) and basal membrane structures (Figure 2e) was disrupted. In particular, Leydig cells were indistinguishable. It was observed that inflammatory cell numbers and oedema decreased in the interstitial areas, furthermore sperm heads and tails were prominent in seminiferous tubule lumens in the Cd toxicity generated group with PCA treatment compared to the Cd administered group without treatment (Figure 3a). The testicular structure of the Cd-administered group with CO treatment was similar to the group treated with PCA. The number of inflammatory cells decreased in the CO-treated group; however, it was observed that their numbers were higher than the group treated with PCA (Figure 3b). Compared to the control group (Figure 4a), it was observed that TUNEL (+) stained cells were increased in the seminiferous tubule cells in the Cd-administered group (Figure 4b) and decreased in the groups of Cd + PCA (Figure 4c) and Cd

Table 1. Testis weight of rats in groups

Groups (n=6)	Testis weight gr (%)
Control	0.60±0.03
PCA	0.65±0.05
CO	0.66±0.05
Cd+ PCA	0.32±0.15 ^{abcd}
Cd + CO	0.17±0.03 ^{abc}
Cd	0.16±0.02 ^{abc}

Values are mean ± standard deviation of six rats from each group (significance value is $p < 0.05$);

^avalues when compared to control statistically significant $p < 0.05$,

^bvalues when compared to PCA statistically significant $p < 0.05$,

^cvalues when compared to CO statistically significant $p < 0.05$,

^dvalues when compared to Cd statistically significant $p < 0.05$.

CO: Corchorus olitorius, Cd: cadmium, PCA: protocatechuic acid, n: number.

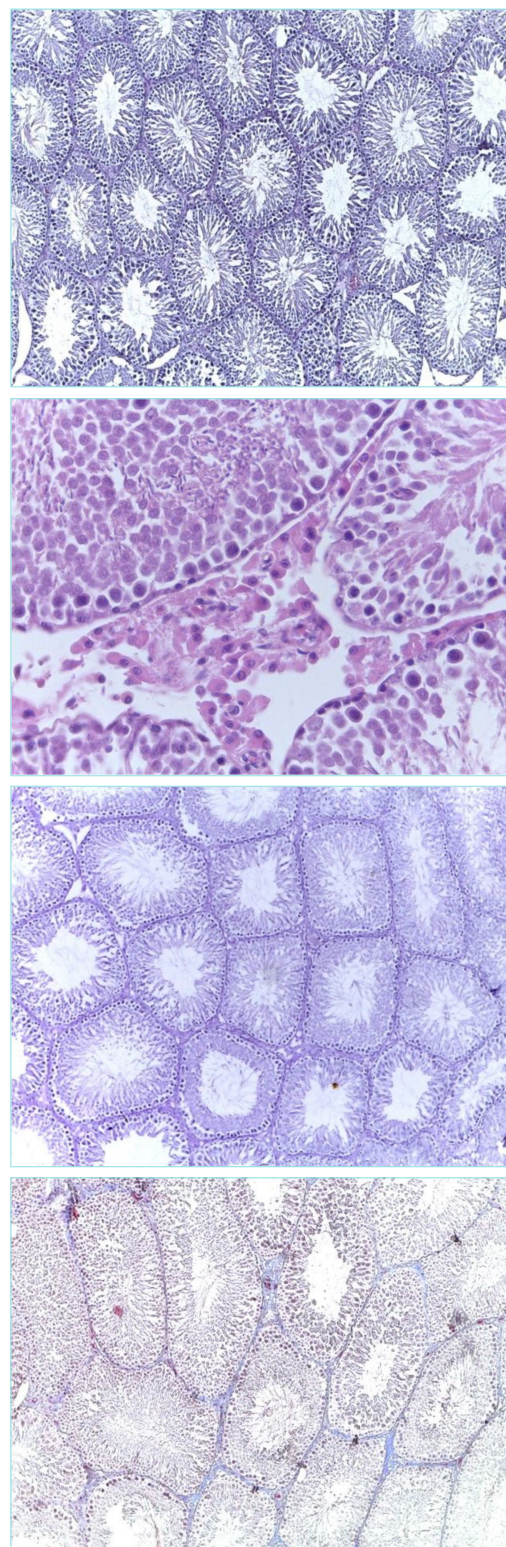


Figure 1. Testicular seminiferous tubules belonging to the control group have normal structure (H&E x10) (a), eosinophilic stained Leydig cells are in high numbers (H&E x40) (b), tubular basal membranes are normal (PAS x10) (c), and there is no increase in connective tissue in the interstitial space (Masson Trichrome x10) (d).

H&E: Hematoxylin and Eosin stain, PAS: Periodic Acid Schiff

+ CO (Figure 4d), however their numbers were not at the control group level. The data obtained using light microscopy inspections are statistically presented in Table 2.

DISCUSSION

Spermatozoa are affected in men exposed to cadmium, and apoptotic cell deaths are increased.^{1,13,14} The toxic effect of cadmium on the testicles varies depending on the dose. As the dose increases, the number of degeneration and apoptotic cells in the seminiferous tubules increases.¹⁵⁻¹⁷ In the seminiferous tubules, clustered cell debris in the lumen, atrophy in the tubules, congestion and vascular dilatation in the interstitial tissue is observed due to cell degeneration.¹⁸ Depending on the level of cadmium accumulated in the body, testicle and body weight, sperm count and motility decreases. In some studies, cadmium-related decreases in body weights and testicle weights have been reported.^{16,19} In the result analysis of our study, it was found that testicular weights decreased significantly compared to the control group, but there was no decrease in body weights depending on cadmium administration. While Adamkovicova et al.¹⁸ reported that there was no significant decrease in body weights of the Cd-administered test subjects, Nna et al.²⁰ and Mahmoudi et al.²¹ reported a decrease in body weights. Because of Cd accumulation, structure of Sertoli cells were disrupted, the blood-testicle barrier was impaired and resulted in infertility.²² Light microscopic examinations on rat testicular tissue were consistent with the results of this study, in which test subjects were administered with ip 3.5 mg/kg cadmium twice a week for three weeks. In the seminiferous tubules; degenerate

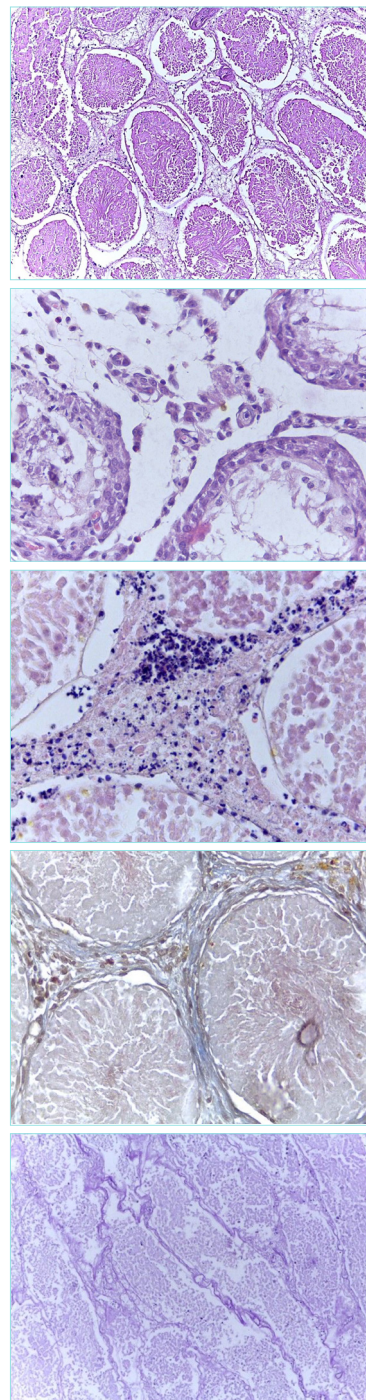


Figure 2. In the Cd applied group, high degree of degeneration in testicular seminiferous tubules, an increase in inflammatory cells and connective tissue in the interstitial tissue and presence of oedema (HE x10) (a), reduced amount of spermatogenic cells and cell debris in the lumen (HE x40) (b), elevated levels of inflammatory cells in the interstitial tissue, especially neutrophil granulocytes (HE x40) (c), increased connective tissue (Masson trichrome x40) (d) and disrupted basal membrane structures (PAS x10) (e) was observed.

Cd: cadmium, H&E: Hematoxylin and Eosin stain, PAS: Periodic Acid Schiff

Table 2. TUNEL (+) cells in groups

Groups (n=6)	TUNEL (+) cell
Cd	15.17±4.40 ^{abcde}
Cd + CO	4.67±3.78 ^{afgh}
Cd + PCA	4.00±1.67 ^{bijk}
CO	0.33±0.51 ^{di}
Control	0.00±0.00 ^{dgi}
PCA	0.33±0.52 ^{ehk}

Values are mean ± standard deviation of six rats from each group (significance value is p <0.05);

^aSignificance between Cd and Cd + CO group,

^bSignificance between Cd and Cd + PCA group,

^cSignificance between Cd and CO group,

^dSignificance between Cd and control group,

^eSignificance between Cd and PCA group,

^fSignificance between Cd + CO and CO group,

^gSignificance between Cd + CO and control group,

^hSignificance between Cd + CO and PCA group,

ⁱSignificance between Cd + PCA and CO group,

^jSignificance between Cd + PCA and control group,

^kSignificance between Cd + PCA and PCA group.

TUNEL: terminal deoxynucleotidyl transferase dUTP nick end labeling, CO: Corchorus olitorius, Cd: cadmium, PCA: protocatechuic acid, n: number.

spermatogenic cells, clusters of cell debris in the lumens, indistinguishable Sertoli cells, absence or very few sperm presence, loss of smoothness of the basal membrane structure, increased connective tissue among interstitial compartment, numerous inflammatory cells, mainly neutrophils and oedema were observed. Leydig cells could not be distinguished in interstitial tissue.

There is still no effective treatment method for eliminating and preventing the toxic effects of cadmium in the tissues.⁵ Various ethnic plants,²³⁻²⁶ have been used for antioxidant effects on cadmium testicular toxicity. Protocatechuic Acid (PCA) is a powerful antioxidant and protects the body against the harm of toxic substances. Adedara et al.⁸ observed that PCA increases the level of hormones and sperm production in testicles in pre-pubertal rats and positively affects sexual maturity. In testicular toxicity created with Methotrexate, PCA treatment has decreased apoptosis in seminiferous tubule cells and increase FSH, LH, and testosterone hormone levels.²⁷ During literature search, any studies regarding to the effect of PCA on cadmium-related testicular degeneration have not been found. The results of this study showed that in the

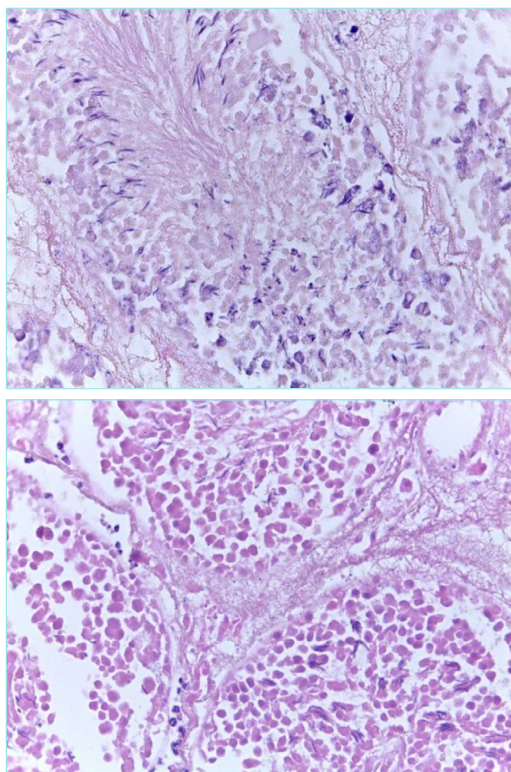


Figure 3. In the cadmium group treated with PCA, the inflammatory cells in the interstitial tissue are reduced, the sperms are clearly distinguished in the seminiferous tubules (a), and the inflammatory cells are in higher numbers in the CO-treated group (b). HE x40.

PCA: protocatechuic acid, CO: *Corchorus olitorius*, H&E: Hematoxylin and Eosin stain

cadmium-administered group with PCA treatment, the number of seminiferous tubules containing sperm was increased, the number of inflammatory cells in the interstitial tissue and apoptotic cells was decreased. We observed that the increase in testicular weight in this group was statistically significant compared to the cadmium administered and Cd + CO groups, hence the effect of PCA on cadmium toxicity was concluded. *Corchorus olitorius* is grown in various parts of the world, consumed in ethnic cuisines and used as a supplement.²⁸ Chemical contents of *Corchorus olitorius* vary according to the region it is grown. The CO identified to contain Caffeoyl glucose, 3-Caffeoylquinic acid, Quercetin glucoside, Quercetin acetylglucoside, 3,5-Dicaffeoylquinic acid, 1,3-Dicaffeoylquinic acid and Luteolin/kaempferol acetylglucoside.²⁹ It was shown that when the extrusion of CO leaves was administered as 250 and 500 mg/kg in male rats, the number of mature spermatozoon increased in seminiferous tubules, but when 1000 mg/kg was delivered, sperm count decreased and high dose CO inhibited reproductive functions.³⁰ In recent studies, it has been shown that CO has a good anti-inflammatory effect.³¹ Furthermore, it has been reported that CO extract can be used as a food supplement against arsenic toxification.³² Literature search revealed that the effects of CO extract on Cadmium-dependent degeneration in the testicles has not been studied. Because of our study, it was observed that degeneration in seminiferous tubules continued, but inflammation and oedema in the interstitial tissue decreased when the rat testicle tissue in the group treated with CO 250 mg/kg was compared with the cadmium administered group. The improvement was less effective than the group treated with PCA. It was identified that apoptotic cell numbers were higher than the PCA-treated group. When the testicular weights were examined, there was no significant increase in the CO-treated group and the values were very similar to the cadmium-administered group. It was thought that the desired protective effect did not occur because of CO dosages used in the study.

CONCLUSION

Three weeks of Cadmium administration and accumulation in rats caused degeneration in testicles. In cadmium groups treated with antioxidant PCA and CO, slight prevention of degeneration was observed. The PCA treatment was identified to be significantly more effective than the CO treatment. The anti-inflammatory and antiapoptotic effects of these compounds have been prominently detected. The results of this study are published by us for the first time. It is in our belief that further molecular studies focusing on the application of different doses and experimental time durations will surely provide a more precise information on this research. We hope that the results of our study will be the source of new studies that will help reduce the destructive effects of Cadmium on testicular tissue.

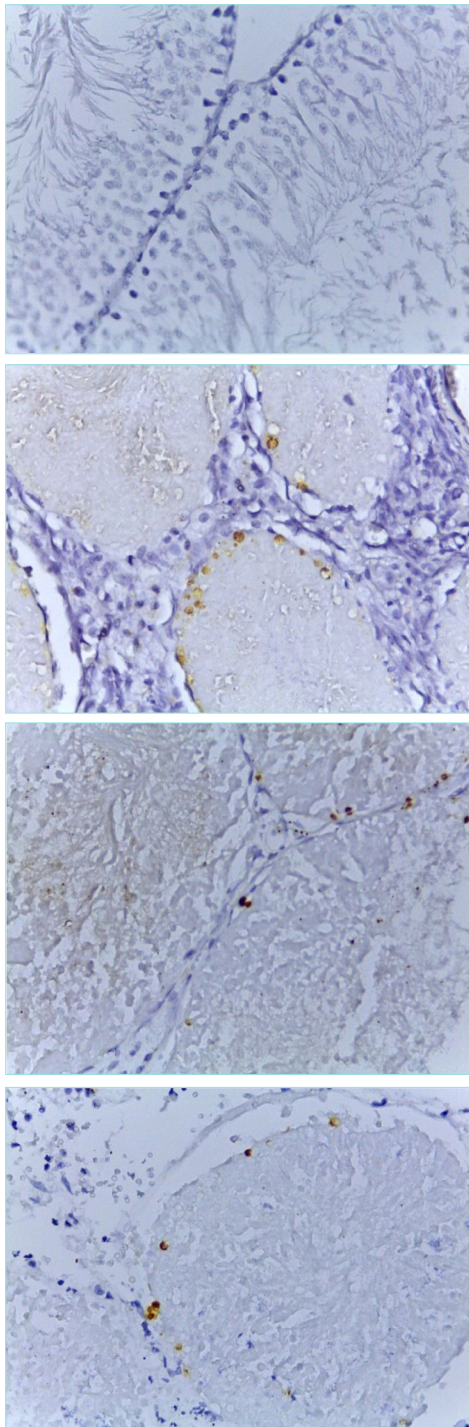


Figure 4. Testis tissues belonging to the experimental groups with TUNEL staining are as presented. In the control group, TUNEL (+) stained cells were not observed (a), in the cadmium administered group, apoptotic cell numbers were increased (b) whereas in the PCA- and CO-treated groups, apoptotic cell numbers were decreased (c, d). The number of apoptotic cells were higher in CO-treated group when compared to the PCA-treated group (d). TUNEL staining x40. TUNEL: terminal deoxynucleotidyl transferase dUTP nick end labeling, CO: *Corchorus olitorius*, PCA: protocatechuic acid

MAIN POINTS

- One of the primary target organs of affected by cadmium, which is one of the heavy metals, is the testicle organ in men. Cadmium causes infertility.
- In this study, it was determined that toxic effects of cadmium on the testicles cause degeneration in tubules where sperms are made and testicle weights decreased. Apoptotic cell death increased in cells. PCA and CO substances used against emerging degeneration reduce cell death and infection, but degeneration was not fully prevented at the administered doses.

ETHICS

Ethics Committee Approval: The study was conducted with the permission of Near East University, Experimental Animals Ethics Committee (20018/20-36).

Informed Consent: Animal experiment study.

Peer-review: Externally peer-reviewed.

Authorship Contributions

Concept: A.K., K.K., Design: A.K., K.K., Data Collection and/or Processing: İ.Ç., K.K., G.S., P.T., Analysis and/or Interpretation: K.K., G.S., A.K., Literature Search: K.K., A.K., P.T., İ.Ç. Writing: K.K., A.K., Critical Review: A.K.

DISCLOSURES

Conflict of Interest: The authors declare no conflict of interest.

Financial Disclosure: This research was supported by the Near East University Scientific Research Project, North Cyprus (project no. SAG-2018-01-042).

REFERENCES

1. Rani A, Kumar A, Lal A, Pant M. Cellular mechanisms of cadmium-induced toxicity: a review. *Int J Environ Health Res.* 2014;24:378-399.
2. Imafidon CE, Risikat OT, Samuel BF, Esther OO, Aderonke AK. Cadmium-induced testicular toxicity oxidative stress and histopathology in wistar rats: sustained effects of polyphenol-rich extract of vernonia amygdalina. *J Interdiscip Histopathol.* 2016;4:54-62.
3. Bernhoft RA. Cadmium toxicity and treatment. *Sci World J.* 2013; 3:394652.
4. de Souza FP, Diamante MA, Dolder H. Testis response to low doses of cadmium in Wistar rats. *Int J Exp Pathol.* 2010;91:125-131.
5. Rinaldi M, Micali A, Marini H, et al. Cadmium, Organ Toxicity and Therapeutic Approaches: A Review on Brain, Kidney and Testis Damage. *Curr Med Chem.* 2017;24:3879-3893.
6. Nakayama SMM, Nakata H, Ikenaka Y, et al. Oneyear exposure to Cd- and Pb-contaminated soil causes metal accumulation and alteration of global DNA methylation in rats. *Environ Pollut.* 2019;252:1267-1276.
7. Kakkar S, Bais S. A Review on Protocatechuic Acid and Its Pharmacological Potential. *ISRN Pharmacology.* 2014;1-9.

8. Adedara IA, Omole O, Okpara ES, et al. Impact of prepubertal exposure to dietary protocatechuic acid on the hypothalamic-pituitary-testicular axis in rats. *Chem Biol Interact.* 2018;290:99-109.
9. Owumi SE, Ochaoga SE, Odunola OA, Farombi EO. Protocatechuic acid inhibits testicular and epididymal toxicity associated with methotrexate in rats. *Andrologia.* 2019;51:e13350.
10. Olorunfemi RM, Adeyanju AA, Adefegha SA, Akomolafe SF. Protocatechuic acid mitigates adriamycin-induced reproductive toxicities and hepatocellular damage in rats. *Comp Clin Path.* 2018;27:128-141.
11. Khafaga AF, Abd El-Hack ME, Taha AE, Elnesr SS, Alagawany M. The potential modulatory role of herbal additives against Cd toxicity in human, animal, and poultry: a review. *Environ Sci Pollut Res Int.* 2019;26:4588-4604.
12. Islam, MM. Biochemistry, medicinal and food values of jute (*Corchorus capsularis* L. and *C. olitorius* L.) leaf: a review. *Int J Enhanc Res Sci Technol Eng.* 2013;35-44.
13. Siu ER, Mruk DD, Porto CS, Cheng CY. Cadmium-induced Testicular Injury. *Toxicol Appl Pharmacol.* 2009;238:240-249.
14. Habib R, Wahdan SA, Gad AM, Azab SS. Infliximab abrogates cadmium-induced testicular damage and spermiotoxicity via enhancement of steroidogenesis and suppression of inflammation and apoptosis mediators. *Ecotoxicol Environ Saf.* 2019;182:109398.
15. Cupertino MC, Novaes RD, Santos EC, et al. Differential Susceptibility of Germ and Leydig Cells to Cadmium-Mediated Toxicity: Impact on Testis Structure, Adiponectin Levels, and Steroidogenesis. *Oxid Med Cell Longev.* 2017;1-11.
16. de Angelis C, Galdiero M, Pivonello C, et al. The environment and male reproduction: The effect of cadmium exposure on reproductive function and its implication in fertility. *Reprod Toxicol.* 2017;73:105-127.
17. Ohta H, Qi Y, Ohba K, Toyooka T, Wang RS. Role of metallothionein-like cadmium-binding protein (MTCdBP) in the protective mechanism against cadmium toxicity in the testis. *Industrial Health.* 2019;57:570-579.
18. Adamkovicova M, Toman R, Cabaj M, et al. Effects of Subchronic Exposure to Cadmium and Diazinon on Testis and Epididymis in Rats. *Sci World J.* 2014;1-9.
19. Ige SF, Olaleye SB, Akhigbe RE, Akanbi TA, Oyekunle OA, Udoh UA. Testicular toxicity and sperm quality following cadmium exposure in rats. Ameliorative potentials of *Allium cepa*. *J Hum Reprod Sci.* 2012;5:37-42.
20. Nna VU, Ujah GA, Mohamed M, et al. Cadmium chloride-induced testicular toxicity in male wistar rats; prophylactic effect of quercetin, and assessment of testicular recovery following cadmium chloride withdrawal. *Biomed Pharmacother.* 2017;94:109-123.
21. Mahmoudi R, Azizi A, Abedini S, Jahromi VH, Abidi H, Barmak MJ. Green tea improves rat sperm quality and reduced cadmium chloride damage effect in spermatogenesis cycle. *J Med Life.* 2018;11:71-380.
22. Cheng CY, Mruk DD. The blood-testis barrier and its implications for male contraception. *Pharmacol Rev.* 2012;64:16-64.
23. Mouro VGS, de Melo FCSA, Martins ALP, et al. Euterpe oleracea (Martius) Oil Reverses Testicular Alterations Caused after Cadmium Administration. *Biol Trace Elem Res.* 2020;197:555-570.
24. Elblehi SS, El Euony OI, El-Nahas AF. Partial ameliorative effect of Moringa leaf ethanolic extract on the reproductive toxicity and the expression of steroidogenic genes induced by subchronic cadmium in male rats. *Environ Sci Pollut Res Int.* 2019;26:23306-23318.
25. Saleemi MK, Tahir MW, Abbas RZ, et al. Amelioration of toxicopathological effects of cadmium with silymarin and milk thistle in male Japanese quail (*Coturnix japonica*). *Environ Sci Pollut Res Int.* 2019;26:21371-21380.
26. Faraji T, Momeni HR, Malmir M. Protective effects of silymarin on testis histopathology, oxidative stress indicators, antioxidant defence enzymes and serum testosterone in cadmium-treated mice. *Andrologia.* 2019;51:e13242.
27. Owumi SE, Ochaoga SE, Odunola OA, Farombi EO. Protocatechuic acid inhibits testicular and epididymal toxicity associated with methotrexate in rats. *Andrologia.* 2019;51:e13350.
28. Youssef AF, Younes NA, Youssef M. Genetic diversity in *Corchorus olitorius* L. revealed by morphophysiological and molecular analyses. *Mol Biol Rep.* 2019;46:2933-2940.
29. Soykut G, Becer E, Çaliş I, Yucecan S, Vatansver S. Apoptotic effects of *Corchorus olitorius* L. leaf extracts in colon adenocarcinoma cell lines. *Progress in Nutrition.* 2018;20:689-698.
30. Orieke D, Ohaeri OC, Ijeh II, Ijioma SN. Semen quality, hormone profile and histological changes in male albino rats treated with *Corchorus olitorius* leaf extract. *Avicenna J Phytomed.* 2019;9:551-562.
31. Orieke D, Ohaeri OC, Ijeh II, Ijioma SN. Gastrointestinal and uterine smooth muscles relaxant and anti-inflammatory effects of *corchorus olitorius* leaf extract in laboratory animal models. *J Ethnopharmacol.* 2020;247:112224.
32. Hosen SM, Das D, Kobi R, et al. Study of arsenic accumulation in rice and evaluation of protective effects of *Chorchorus olitorius* leaves against arsenic contaminated rice induced toxicities in Wistar albino rats. *BMC Pharmacol Toxicol.* 2016;17:46.