

Effects of *Gum acacia* aqueous extract on the histology of the intestine and enzymes of both the intestine and the pancreas of albino rats treated with Meloxicam

Ahmed M. A. Abd El-Mawla^{1,2}, Husam Eldien H. Osman³

¹Department of Pharmacognosy, Faculty of Pharmacy, Assiut University, Assiut 71526, Egypt, ²Department of Pharmacognosy, Faculty of Pharmacy, Taif University, Taif 21974, Saudi Arabia, ³Department of Anatomy and Histology, Faculty of Medicine and Medical Sciences, Taif University, Taif 21974, Saudi Arabia

Submitted: 18-10-2010

Revised: 02-12-2010

Published: 08-06-2011

ABSTRACT

Background: Non-steroidal anti-inflammatory drugs (NSAIDs) cause gastrointestinal damage both in the upper and lower gastrointestinal tract, in addition to their undesirable side effects on the pancreas. Meloxicam like all NSAIDs has damaging effects on the gastrointestinal tract including perforations, ulcers and bleeding. **Objective:** The present work describes the effects of *Gum acacia* aqueous extract on the histology of intestine and enzymes of both intestine and Pancreas of albino rats treated with Meloxicam. **Materials and Methods:** This study was performed on four groups of equally weighed male rats, each group included ten animals; the first group was received a diet containing 0.2 mg/kg bw meloxicam per day; the second was given 1gm *Gum acacia* per day in its diet; the third was given meloxicam followed by gum in the same doses per day; while the fourth group (control rats) was placed on a normal diet and water. All rats were received their diet for a period of 21 days. **Results:** A considerable protective effect of *Gum acacia* aqueous extract on the histology of intestine of albino rats treated with meloxicam was recorded. In addition, the study displayed a significant increase ($P < 0.001$) in the intestinal enzymes; lipase, amylase, alkaline phosphatase (ALP) and lactate dehydrogenase (LDH) in the 1st and 3rd groups animals while these enzymes were significantly decreased ($P < 0.001$) in the 2nd group when compared with the 4th control group. **Conclusion:** This study concluded that *Gum acacia* provides a protection and defense against the harmful effects of meloxicam therapy used as one of the novel anti-Cox-1 and Cox-2 NSAIDs.

Key words: *Gum acacia*, ileum, lipase, meloxicam, NSAID drugs

INTRODUCTION

Non-steroidal anti-inflammatory drugs (NSAIDs) cause intestinal damage as an adverse reaction in both experimental animals and humans.^[1,2] Although a number of elements such as bacterial flora, neutrophils and inducible nitric-oxide synthase (iNOS) are involved in the pathogenesis of these lesions,^[3-5] a deficiency of endogenous prostaglandins (PGs) is of prime importance in the background for the ulcerogenic response to meloxicam as a novel NSAID. This contention is supported by the fact that meloxicam-induced gastric and

intestinal damage has been prevented by supplementations of exogenous PGs.^[6,7]

Meloxicam acts primarily through the inhibition of cyclooxygenase (COX) enzyme, which is involved in arachidonic acid metabolism and exists as a constitutive COX-1 and an inducible COX-2 isoform.^[8,9]

On the other hand, Guar gum has been used to treat diabetes to curb the appetite and to carry toxins out of the body. Consumption of *Gum acacia* stimulated the intestinal and splenic immune system function in rats. The effects of *Gum acacia* consumption on the cholesterol levels have been equivocal as one study documented lowered serum cholesterol levels,^[10] while another one documented no or inconsistent effects.^[11]

Access this article online

Website:
www.phcogres.com

DOI:
10.4103/0974-8490.81959

Quick Response Code:



Address for correspondence:

Dr. Ahmed M. A. Abd El-Mawla, Department of Pharmacognosy, Faculty of Pharmacy, Assiut University, Assiut 71526, Egypt.
E-mail: ahmedpha2000@yahoo.com

This study aims to clarify the role of gum aqueous extracts in their therapeutic dose, as pancreatic and intestinal enzymes in meloxicam-treated rats as well as to illustrate the functional and biochemical changes together with the associated histopathological alterations following meloxicam therapy.

MATERIALS AND METHODS

Animal groups

This work was designed to examine the effect of meloxicam on the pancreatic and intestinal juice of the albino rats and the effect of meloxicam on the ileum of the albino rats. Forty male and female albino rats weighing 200 g were divided into four groups, each of which contained 10 animals. The first group was receiving in its diet 0.2 mg/kg bw meloxicam per day, the second was given 1 g/day *Gum accacia* and the third was administered gum followed by meloxicam in the same doses mentioned before. The drug was given in each group for a period of 21 days. The fourth group (control) was placed on normal diet and water *ad libitum*.

Both control and treated rats were killed and their ileum was histologically examined with hematoxylin and eosin for the general histological structure. All rats were exposed to the same condition in relation to nutrition, temperature and humidity.

Enzyme determination

Rats receiving medication(s) will be decapitated after 24 h of the last dosage. The pancreas and jejunum (5–7-cm-long segment) will be immediately excised. The intestinal segments will be flushed with ice cold 0.9% saline. The segments will be then cut open longitudinally and the mucosa will be scraped with a microscopic slide.^[12] The pancreas and mucosal scrapings will be homogenized in 0.9% saline. The homogenates will be centrifuged at 3000 rpm for 10 min and the supernatant will be used for the enzymatic assays. Studies on organelle-specific marker enzymes will be carried out as described previously.^[13] Finally, alkaline phosphatase and lactate dehydrogenase (mmd/L) together with amylase and lipase will be measured photometrically.^[14]

Histopathologic technique

Ileum specimens will be fixed in Bouin's solution for 24 h, dehydrated in ascending grades of ethyl alcohol (70%, 80%, 90% and 95%), then cleared in terpinol and embedded in paraffin and sectioned at 6 μ m. The sections will be deparaffinized in xylene, embedded in descending grades of ethyl alcohol, washed in water and then stained with hematoxylin and eosin.^[2]

Ultrastructural microscopic examination

An adjacent section of the ileum was removed and placed in 0.1M cacodylate buffer containing 3% glutaraldehyde for electron microscopy.

After fixation, the sections were dehydrated in a series of ethanol rinses, cleared with propylene oxide and embedded in epon. Semithin sections were cut and stained with toluidine blue and ultrathin sections were cut and stained with uranyl acetate and lead citrate. The ultrastructure of the tissues was examined under the transmission electron microscope.^[15]

Statistical analysis

Results will be compiled, tabulated and statistically analyzed using a program dealing with data management and calculation of means, standard deviations and standard errors and giving the correlations and *T*-test significance.

RESULTS

Control group

Histological picture

The microscopic examination of the ileac sections of the control animals revealed their characteristic layers; serosa, musculosa submucosa and mucosa. The mucosa, the most important absorptive layer, had numerous evaginations into the gut lumen (villi). Each villus had a core of lamina propria connective tissue containing capillaries and smooth muscles [Figure 1].

A few numbers of lymphocytes were seen in this propria. The main absorptive cells of these villi, the enterocytes, were tall columnar cells with basal oval nuclei. Among these

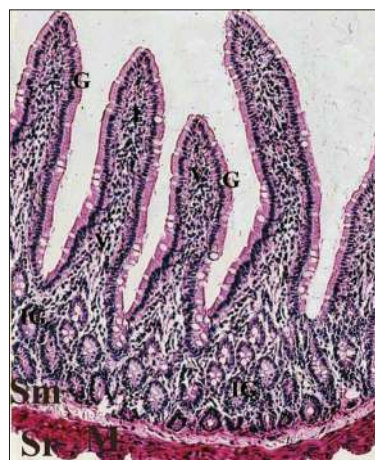


Figure 1: A photomicrograph of the control group of normal ileum mucosa showing its characteristic layers; the mucosa showing long villi, lined by tall columnar cells with goblet cells (G), sub mucosal layer (Sm) with intestinal gland (IG), muscular layer (M) and Sserous layer (Sr). (H and E, $\times 128$)

enterocytes, numerous mucus cells of goblet shape were distributed [Figure 2].

Ultrastructural picture

At the ultrastructural level, the enterocytes were united at their uppermost lateral membrane by a well-developed tight junction. The supranuclear region of these enterocytes had several spherical mitochondria and numerous cisternae of rough endoplasmic reticulum, the luminal surface of the enterocytes possessed many closely packed parallel finger-like microvilli. Each microvillus had a striated filamentous microtubular core that was united with the other cores forming the terminal web [Figure 3].

Meloxicam-treated group

Histological picture

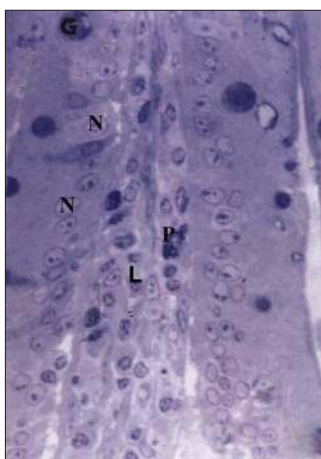


Figure 2: A photomicrograph of a semithin section of the control group of normal ileum showing the enterocytes with their oval nuclei (N), the lamina propria (L) with its lymphocytes (P) and the darkly -stained goblet cells (G). (Toluidine blue, x900)




Figure 3: Transmission electron photomicrograph of a control rat villus showing: An enterocyte with its microvillar brush (Mv), goblet cells (G). Mitochondria (M) and rough endoplasmic reticulum (RER). (Uranyl acetate and lead citrate, x2800)

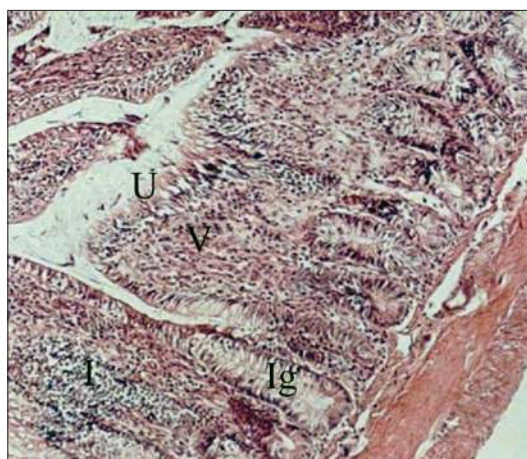


Figure 4: Light micrographs of ileum in the group II after meloxicam represents severe villar fusion (V), degeneration of apical surface epithelium (U), congested cells in the intestinal glands (IG) and inflammatory cell infiltration (I). (Hematoxylin and eosin, x150)

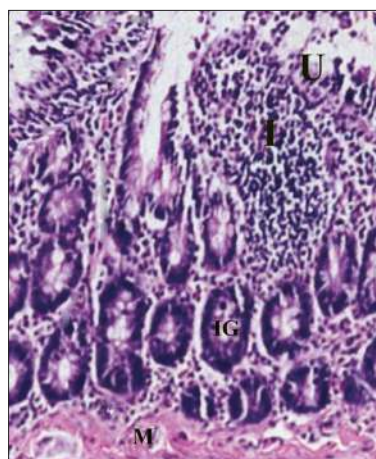


Figure 5: Ulceration of the lining epithelial layer of mucosa of the rat ileum treated with meloxicame (U) and diffuse infiltration of inflammatory cells (I) in the lamina propria muscularis (M). (Hematoxylin and Eosin, -X200)

The light microscopic examination of the ileac sections of the rats treated with meloxicam only showed mucosal and villar atrophy, necrosis and desquamation of the lining of the epithelium, especially at the villar tips. There was a severe villar fusion, degeneration of the apical surface of the epithelium and congested cells in the intestinal glands [Figure 4].

The lamina propria and the muscular layer showed diffuse infiltration of the inflammatory cells and lymphocytes [Figure 5].

There were many multinucleated hypertrophied enterocytes and detached epithelial layer with apoptotic epithelial cells [Figure 6].

There were, also, destruction of the crypt cells and

the mucosal layer of the villi with focal aggregation with numerous goblet cells with cytoplasm vacuolation [Figure 7].

Ultrastructural picture

At the ultrastructural level, a number of enterocytes of this group lost their microvilli and showed severe destructive changes of their cellular organelles, including degenerated mitochondria and rough endoplasmic reticulum. The nuclei were condensed and fragmented. Characteristic apoptotic changes of the epithelial cell were seen with degeneration of the apical surface epithelium and irregularities in the microvilli [Figure 8].

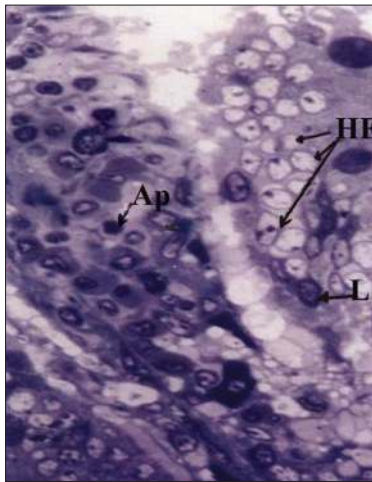


Figure 6: A semithin section of an ileum villus of the meloxicam-treated rat showing a large number of multinucleated hypertrophied enterocytes (HE) with apoptotic epithelial cells (AP), intraepithelial and lamina propria lymphocytes (L) and detached epithelial layer. (Toluidine blue, - X900)

Gum a acacia and meloxicam-treated group

Histological picture

Specimens of most gum-treated animals revealed great improvement but could not completely restore their normal histological architecture. There was vilar fusion, epithelial cell proliferation and crypt proliferation and the submucosal hyalinization with serosa and muscula were thickened. Some lymphocyte nodules were still noticed [Figures 9 and 10].

There were also a higher number of goblet cells than that noticed in the control group [Figure 11].

Ultrastructural picture

At the ultrastructural level, a few number of the enterocytes of the group treated with gum had some vacuoles, normal nuclei, nearly normal mitochondria with short cristae and mucous glands with homogenously electron-lucent

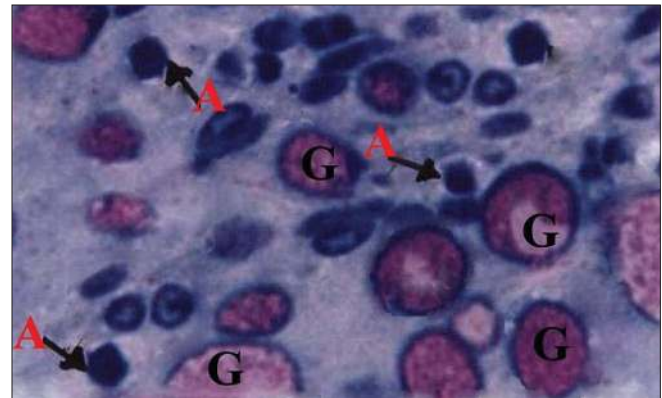


Figure 7: A semithin section of a crypt of Lieberkühn of the rat ileum treated with meloxicam showing having numerous goblet cells (G) and apoptotic epithelial cells (A). (Toluidine blue, x1280)

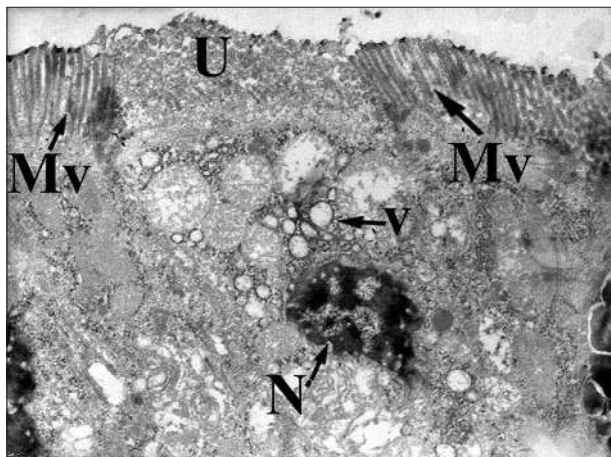


Figure 8: Transmission electron photomicrograph of villus treated with meloxicam showing characteristic apoptotic changes of condensed and fragmented nuclei in ileum epithelial cell (N), increased vacuolization (v), degeneration of apical surface epithelium (U) and irregularities in microvilli (Mv). (Uranyl acetate and lead citrate, x2800)

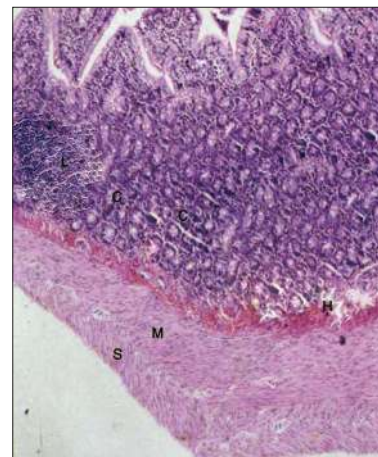


Figure 9: A photomicrograph of a mucosa of the of ileum of the rat treated with gum and meloxicam showing serosal (S) and muscular thickening (M) with sub-mucosal hyalinization (H) with crypt proliferation (C) and lymphoid hyperplasia in the mucosal layer (L) (Hematoxylin and eosin, x128)

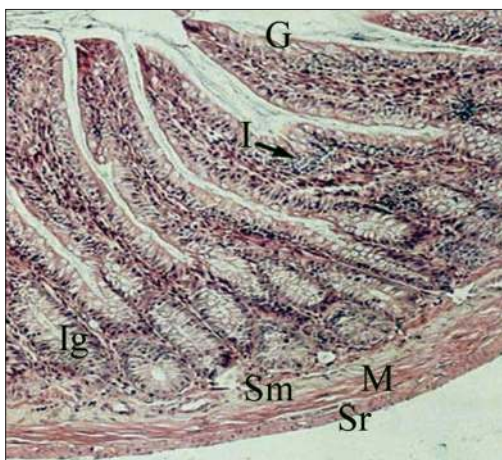


Figure 10: A photomicrograph of a mucosa of the ileum of the rat treated with gum and meloxicame showing slight villar fusion (V) with increase in the number of goblet cells (G) and intestinal glands (Ig) and inflammatory cell infiltration (I). hHypertrophy in the sub mucosa (Sm), musculosa (M) and serosa (Sr). (Hematoxylin and eosin, x150)

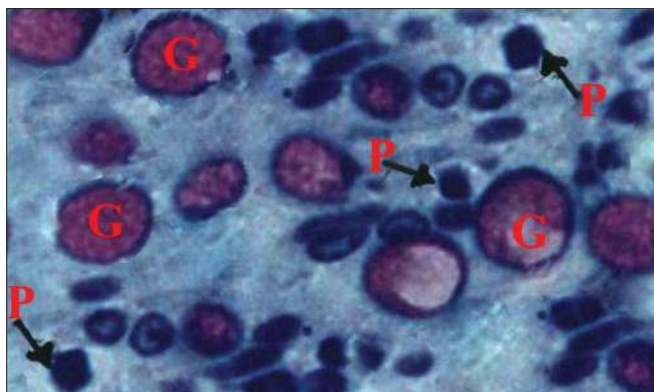


Figure 11: A photomicrograph of Aa semithin section of a crypt of Lieberkühn of mucosa of the of ileum of the rat treated with gum and meloxicame showing a higher number of goblet cells (G) than in the control and many apoptotic epithelial cells (P). (Toluidine blue, x1280)

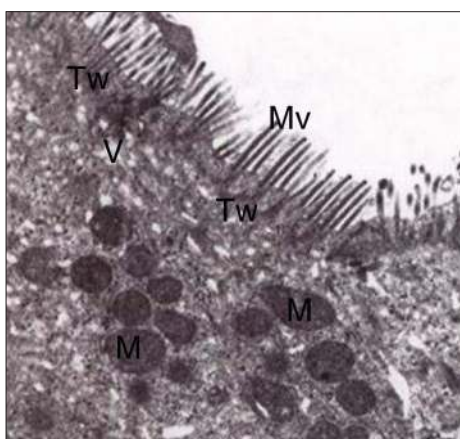


Figure 12: Transmission electron photomicrograph of a mucosa of the of ileum of the rat treated with gum and meloxicame showing, a few number of vacuoles (V), nearly normal mitochondria (MI) and, long intact microvilli (MV) with their terminal web (Tw). (Uranyl acetate and lead citrate, x2800)

granules. Also, few enterocytes possessed destructed mitochondria and degenerated microvilli but nearly normal nuclei at certain areas of the luminal surface. Nevertheless, the great majority of the enterocytes were with intact long microvilli, normal cell organelles and organized elements [Figure 12].

Enzymatic studies

From the enzymatic view in this study, the first group of animals treated with meloxicam alone showed a significant decrease ($P < 0.001$) in pancreatic lipase [Table 1], and pancreatic amylase [Table 2], however, the second and third groups revealed a significant increase ($P < 0.001$) in these pancreatic enzymes [Tables 1 and 2] when compared with the control group (fourth group). In addition, the study displayed a significant increase ($P < 0.001$) in the intestinal enzymes lipase, amylase, alkaline phosphatase (ALP) and lactate dehydrogenase (LDH) in the first and third group of animals while these enzymes were significantly decreased ($P < 0.001$) in the second group when compared with the

Table 1: Comparison of the mean pancreatic lipase levels in all groups (n = 40)

Parameters	Gr. 1	Gr. 2	Gr. 3
Mean pancreatic lipase level*	16.32	35.82	27.74
Standard deviation (SD)*	0.7624	2.0934	1.4580
Groups comparison	Gr1:Gr4	Gr2:Gr4	Gr3:Gr4
Correlation	0.143	0.048	0.652
T-value	11.291	-12.781	-11.663
Significance (P-value)	0.59	0.83	0.26

*Note that the mean pancreatic lipase level in the control (fourth) group was 20.82 and its SD was 0.8711.

Table 2: Comparison of the mean pancreatic amylase levels in all groups (n = 40)

Parameters	Gr. 1	Gr. 2	Gr. 3
Mean pancreatic amylase level*	37.75	50.82	45.93
Standard deviation (SD)*	0.5281	1.8656	2.1023
Groups comparison	Gr1:Gr4	Gr2:Gr4	Gr3:Gr4
Correlation	0.252	0.318	0.049
T-value	2.997	-6.214	-1.613
Significance (P-value)	0.614	0.391	0.75

*Note that the mean pancreatic amylase level in the control (fourth) group was 41.72 and its SD was 2.1356.

Table 3: Comparison of the mean intestinal lipase levels in all groups (n = 40)

Parameters	Gr. 1	Gr. 2	Gr. 3
Mean intestinal lipase level*	42.16	25.13	43.44
Standard deviation (SD)*	2.0261	3.1581	5.9715
Groups comparison	Gr1:Gr4	Gr2:Gr4	Gr3:Gr4
Correlation	-0.123	0.261	-0.355
T-value	-8.120	6.081	-4.121
Significance (P-value)	0.713	0.439	0.472

*Note that the mean intestinal lipase level in the control (fourth) group was 33.49 and its SD was 1.4092.

Table 4: Comparison of the mean intestinal amylase levels in all groups (n = 40)

Parameters	Gr. 1	Gr. 2	Gr. 3
Mean intestinal amylase level*	13.74	7.52	14.81
Standard deviation (SD)*	0.4683	1.0511	1.2671
Groups comparison	Gr1:Gr4	Gr2:Gr4	Gr3:Gr4
Correlation	0.412	-0.568	0.011
T-value	-15.96	3.462	-7.917
Significance (P-value)	0.171	0.188	0.815

*Note that the mean intestinal amylase level in the control (fourth) group was 10.99 and its SD was 0.5982

Table 6: Comparison of mean intestinal lactate dehydrogenase in all groups (n = 40)

Parameters	Gr. 1	Gr. 2	Gr. 3
Mean intestinal LDH level*	95.300	35.819	64.6121
Standard deviation (SD)*	4.2913	2.3011	2.175
Groups comparison	Gr1:Gr4	Gr2:Gr4	Gr3:Gr4
Correlation	-0.531	-0.137	0.814
T-value	-15.472	13.413	-18.249
Significance (P-value)	0.315	0.819	0.071

LDH = Lactate dehydrogenase; *Note that the mean intestinal LDH in the control (fourth) group was 55.800 mmol/h/l and its SD was 1.7521

fourth (control) group [Tables 3–6].

DISCUSSION

This study displayed affection of both intestinal mucosa and brush border together with a significant increase in the activities of the brush border enzymes (lipase, amylase, alkaline phosphatase and lactate dehydrogenase) after 21 days of meloxicam therapy, either alone or in combination with gum, compared with either the control or the gum only treated groups. These results coincided with those reported earlier.^[2,16] which confirmed that inhibition of both Cox-1 and Cox-2 is required for the induction of intestinal damage and, furthermore, that the Cox-1 inhibition, despite causing intestinal hypermotility, bacterial invasion and inducible nitric oxide synthase (iNOS) expression, up regulates Cox-2 expression and the prostaglandin E₂ (PGE₂) produced by Cox-2 may counteract subsequent events such as increases in myeloperoxidase (MPO) and iNOS activity and maintain the mucosal integrity. This sequence of events may explain why intestinal damage occurs only when both Cox-1 and Cox-2 are inhibited.

The published studies^[17] suggested that NSAIDs have a detergent-like action, which disrupts the mucus gel and/or all membrane integrity of the gastrointestinal tract. The decreased activity of the brush border enzyme alkaline phosphatase is consistent with this suggestion, although no significant structural changes were seen on electron microscopy. Moreover, acidic NSAIDs may concentrate

Table 5: Comparison of the mean intestinal alkaline phosphatase in all groups (n = 40)

Parameters	Gr. 1	Gr. 2	Gr. 3
Mean intestinal ALP level*	1.82	0.41	0.79
Standard deviation (SD)*	0.2971	5.601 E-02	0.1082
Groups comparison	Gr1:Gr4	Gr2:Gr4	Gr3:Gr4
Correlation	0.019	-0.196	0.298
T-value	-9.367	4.483	-4.281
Significance (P-value)	0.966	0.691	0.450

ALP = Alkaline phosphatase; *Note that the mean intestinal ALP in the control (fourth) group was 0.69 mmol/h/l and its SD was 6.761 E-02

in the mucosa.^[18]

NSAIDs can damage the stomach as well as the small and large intestines causing ulceration, chronic bleeding and, eventually, iron deficiency.^[19,20] Also, iron deficiency may be associated with oxidative DNA damage, cognitive dysfunction, anemia and compromised immune function.^[21]

In contrast, our study revealed a significant decrease in the pancreatic enzymatic activity (lipase and amylase) after 21 days of meloxicam therapy when compared with the control, gum or meloxicam-gum combined therapy groups. These findings mimicked what was published before.^[22,23]

Conventional NSAIDs at an ulcerogenic dose caused a marked hypermotility in the rat small intestine. This change in the motility occurred within 20–30 min, much sooner than the onset of bacterial invasion and other inflammatory changes as well as development of intestinal damage. Because abnormal contraction of the intestinal wall results in disruption of the unstirred mucus layer over the epithelium, leading to increased mucosal susceptibility to pathogens and irritants, the intestinal hypermotility may play a role in the pathogenic mechanism of meloxicam-induced small intestinal lesions. When the intestinal hypermotility as well as the bacterial invasion and other inflammatory changes were potently inhibited, this would prevent the intestinal damage.^[6,24]

It was reported that SC-560 (a selective Cox-1 inhibitor) produced a decrease in the gastric mucosal blood flow, suggesting that the effect of NSAIDs on the mucosal blood flow is brought about by suppression of Cox-1.^[25] Also, intestinal hypermotility induced by the Cox-1 inhibitor caused mucosal hypoxia and microvascular injury due to smooth muscle contraction.^[26]

Moreover, It has been found that celecoxib (a selective Cox-2 inhibitor) increased the neutrophil adherence in mesenteric venules.^[25] These blood cells play a permissive role in NSAID-induced intestinal damage that was significantly prevented by antineutrophil serum.^[5] In

addition, neutrophils are a source of oxygen radicals and inducible nitric oxide synthase (iNOS). The interaction of nitric oxide with oxygen radicals forms peroxy nitrates that may be detrimental in the above-mentioned gastrointestinal lesion model.^[27] Thus, the previous studies^[2] assumed that Cox-2 contributes to maintaining the integrity of the intestinal mucosa through inhibition of neutrophil migration under the inhibition of Cox-1.

Most protease activities reduced in the presence of 0.5% gum sonicate with trypsin-like activities of *B. gingivalis* and *B. intermedia* organisms. The gum-soluble fraction was nearly always less inhibitory than the sonicate one. Acacia gum is an anti-ulcer drug by virtue of its various effects on the mucosal offensive and defensive factors. Also, its action against these periodontal pathogens and their enzymes suggests that it may be of clinical value.^[28]

Gum resins are applied to the inspissated milky juices of certain plants. When they are finely powdered and rubbed down with water, they form emulsions and are used chiefly in medicine.^[29] Gums are a high-energy food source composed mainly of water, complex polysaccharides, calcium and trace minerals (iron, aluminum, silicon, potassium, magnesium and sodium). Arabic gum (Acacia gum) has a property to bind cations, especially divalent ones. As a result, the amount of calcium and magnesium in the caecum rises considerably to be efficiently absorbed from the large bowel, enhancing the healing of the gastrointestinal ulcers. This is provided by a fact that gum was found to be transformed into a gelatinous state at a higher level in the intestine and to be transported more rapidly through the alimentary tract.^[30]

Histopathology in our study was carried out on the principle tissue, intestinal tract, and revealed marked changes; ulceration and inflammatory infiltration in the intestinal wall of rats treated with meloxicam and mild pathological changes, superficial ulceration and minor inflammation in the animals receiving combined meloxicam and gum therapy. However, those treated with gum alone showed an incomparable picture to the control ones. These data were similar to those published earlier.^[2,6,31] The former studies also found that gum does not disintegrate or decompose appreciably in the alimentary tract and it absorbs a large quantity of water, therefore, acting as a mechanical laxative. In addition, gum tends to increase the faecal nitrogen excretion, does not affect starch digestion and does not inhibit the utilization of vitamin A, one of the essential factors in ulcer healing.

CONCLUSION

This study concluded that *Gum accacia* provides a protection

and defense against the harmful effects of meloxicam therapy used as one of the novel anti-Cox-1 and Cox-2 NSAIDs.

REFERENCES

1. Bjarnason I, Zanelli G, Smith T, Prouse P, Williams P, Levi AJ. Nonsteroidal anti-inflammatory drug-induced intestinal inflammation in humans. *Gastroenterology* 1998;93:480-9.
2. Tanaka A, Hase S, Miyazawa T, Ohno R, Takeuchi K. Role of cyclooxygenase Cox-1 and Cox-2 inhibition in nonsteroidal anti-inflammatory drug-induced intestinal damage in rats: Relation to various pathogenic events. *J Pharmacol* 2002a;303:1248-54.
3. Asako H, Kubes P, Wallace JL, Granger DN. NSAID-induced leukocyte adhesion in mesenteric venules: Role of lipoxygenase products. *Am J Physiol* 1992;262:903-8.
4. Yamada T, Deitch E, Specian RD, Perry MA, Sartor RB, Grisham MB. Mechanisms of acute and chronic intestinal inflammation induced by indomethacin. *Inflammation* 1993;17:641-62.
5. Konaka A, Nishijima M, Tanaka A, Kato S, Takeuchi K. Roles of enterobacteria, nitric oxide and neutrophil in pathogenesis of NSAID-induced small intestinal lesions in rats. *Pharmacol Res* 1999;40:517-24.
6. Kunikata T, Miyazawa T, Kanatsu K, Kato S, Takeuchi K. Protective effect of thiaton, the antispasmodic drug against NSAID-induced intestinal ulceration in rats. *Jpn J Pharmacol Am* 2002;88:45-54.
7. Tanaka A, Hase S, Migazawa T, Takeuchi K. Up-regulation of Cox-2 b inhibition of Cox-1: A key to NSAID-induced intestinal damage. *J Pharmacol Exp Ther* 2002;300:754-61.
8. Vane JR. Inhibition of prostaglandin synthesis as a mechanism of action for aspirin-like drugs. *Nat New Biol* 1971;231:232-5.
9. Tanaka A, Araki H, Hase S. Takeuchi inhibition of both cox-1 and cox-2 is required for development of gastric damage in response to non-steroidal anti-inflammatory drugs. *J Physiol London* 2001;95:21-7.
10. Ross AH, Eastwood MA, Brydon WG, Anderson JR. A study of the effects of dietary gum Arabic in humans. *Am J Clin Nutr* 1983;37:368-75.
11. Eastwood MA, Brydon WG, Anderson DM. The effect of the polysaccharide composition and structure of dietary fibers on coecal fermentation and foecal excretion. *Am J Clin Nutr* 1986;44:51-5.
12. Sharathchandra JN, Platel K, Srinivasan K. Digestive enzymes of rat pancreas and small intestine in response to orally administered mint leaf and garlic. *Indian J Pharmacol* 1995;27:156-70.
13. Peters JJ. Investigation of tissue organelles by a combination of analytical subcellular fractionation and enzymic micro-analysis: A new approach to pathology. *J Clin Pathol* 1981;34:1-12.
14. Smith B, Roe J. Enzyme assays. *J Boil Chem* 1957;227:367.
15. Bancroft JD, Gamble M. Theory and practice of histological techniques, 5th ed. New York, Edinburgh and London: Churchill Livingstone; 2002. p. 126, 173-5.
16. Dory S, Michael W, Susan MF, Nikil I, Frank AS. Ados-finding study of NSAIDs for chemoprevention utilizing rectal mucosal prostaglandin E2 levels as a biomarker. *Cancer Epidemiol Biomarkers Prevent* 2002;11:275-9.
17. Lichtenberger LM, Wang ZM, Romero JJ, Ulloa C, Perez JC, Giraud MN. Non-steroidal anti-inflammatory drugs (NSAIDs) associate with zwitterionic phospholipids: Insight into the mechanism and reversal of NSAID-induced gastrointestinal injury. *Nat Med* 1999;1:154-8.
18. Szabo S, Spill WF, Rainsford KD. Non-steroidal anti-inflammatory

- drug-induced gastroenteropathy. *Med Tox Adverse Drug Exp* 1989;4:77-94.
19. Davies NM. Toxicity of nonsteroidal anti-inflammatory drugs in the large intestine. *Dis Colon Rectum* 1995;38:1311-21.
 20. Bertschinger P, Zala GF, Fried M. Effect of non-steroidal antirheumatic agents on the gastrointestinal tract: Clinical aspects and pathophysiology. *Schweiz Med Wochenschr* 1996;126:1566-8.
 21. Ames BN. Micronutrient deficiencies; A major cause of DNA damage. *Ann Acad Sci* 2000;889:87-106.
 22. Insel. Analgesic antipyretics and anti-inflammatory agents: Drugs employed in the treatment of rheumatoid arthritis and gou. *Dig Dis Sci* 1993;25:97-9.
 23. Garavito RM. The three-dimensional structure of cyclo-oxygenases. *Am J Dig Dis* 1996;5:315-21.
 24. Kunikata T, Umeda M, Tanaka A, Kato S, Takeuchi K. 16, 16-Dimethyl prostaglandin E2 inhibits NSAIDs-induced small intestinal lesions. *Dig Dis Sci Br* 2002;47:894-904.
 25. Wallace JL, McKnight W, Reuter BK, Vergnolle N. NSAID-induced gastric damage in rats: Requirement for inhibition of both cyclo-oxygenase 1 and 2. *Gastroenterology* 2000;119:706-14.
 26. Anthony A, Pounder RE, Dhillon AP, Wakefield AJ. Vascular anatomy defines sites of anti-Cox-1 –induced jejunal ulceration along the mesenteric margin. *Gut* 1997;41:763-70.
 27. Beckman JS, Beckman TW, Chen J, Marshall PA, Freeman BA. Apparent hydroxyl radical production by peroxynitrite: Implication for endothelial injury from nitric oxide and superoxide. *Proc Natl Acad Sci USA* 1990;87:1620-4.
 28. Clark DT, Gazi MI, Cox SW, Eley BM, Tinsley GF. The effects of Acacia Arabica gum on the *in-vitro* growth and protease activities of periodontopathic bacteria. *J Clin Periodontol* 1993;20:238-43.
 29. Han LK, Kimura Y, Okuda H. Reduction in the fat storage during chitin-chitosan treatment in mice fed a high-fat diet. *Int J Obestet Metab Disord* 1999;23:174-9.
 30. Wapinir RA, Teichberg S, Go JT, Wingertzahn MA, Harper RG. Oral rehydrations: Enhanced sodium absorption with gum Arabic. *J Am Coil Nutr* 1996;15:337.
 31. Goel RK, Bhattacharya SK. Gastroduodenal mucosal defense and mucosal protective agents. *Indian J Exp Biol* 1991;29:701-14.

Cite this article as: Abd El-Mawla AM, Osman HH. Effects of *Gum acacia* aqueous extract on the histology of the intestine and enzymes of both the intestine and the pancreas of albino rats treated with Meloxicam. *Phcog Res* 2011;3:114-21.

Source of Support: Nil, **Conflict of Interest:** None declared.

New features on the journal's website

Optimized content for mobile and hand-held devices

HTML pages have been optimized of mobile and other hand-held devices (such as iPad, Kindle, iPod) for faster browsing speed.

Click on [**Mobile Full text**] from Table of Contents page.

This is simple HTML version for faster download on mobiles (if viewed on desktop, it will be automatically redirected to full HTML version)

E-Pub for hand-held devices

EPUB is an open e-book standard recommended by The International Digital Publishing Forum which is designed for reflowable content i.e. the text display can be optimized for a particular display device.


Click on [**EPub**] from Table of Contents page.

There are various e-Pub readers such as for Windows: Digital Editions, OS X: Calibre/Bookworm, iPhone/iPod Touch/iPad: Stanza, and Linux: Calibre/Bookworm.

E-Book for desktop

One can also see the entire issue as printed here in a 'flip book' version on desktops.

Links are available from Current Issue as well as Archives pages.

Click on  View as eBook